

# Reliability and Validity of a 1-Person Technique to Measure Humeral Torsion Using Ultrasound

Daniel C. Hannah, MS, LAT, ATC\*†; Jason S. Scibek, PhD, LAT, ATC‡; Christopher R. Carcia, PhD, PT, OCS, SCS§; Amy L. Phelps, PhD||

\*Department of Orthopaedic Surgery, Augusta University, GA; †Rehabilitation Science Program, ‡Department of Athletic Training, §Department of Physical Therapy, and ||Palumbo Donahue School of Business, Duquesne University, Pittsburgh, PA

**Context:** Knowledge of the bilateral difference in humeral torsion (HT) enables clinicians to implement appropriate interventions for soft tissue restrictions of the shoulder to restore rotational motion and reduce injury risk. Whereas the current ultrasound method for measuring HT requires 2 assessors, a more efficient 1-person technique (1PT) may be of value.

**Objective:** To determine if a 1PT is a reliable and valid alternative to the established 2-person technique (2PT) for indirectly measuring HT using ultrasound.

**Design:** Descriptive laboratory study.

**Setting:** Biomechanics laboratory.

**Patients or Other Participants:** A convenience sample of 16 volunteers (7 men, 9 women; age = 26.9 ± 6.8 years, height = 172.2 ± 10.7 cm, mass = 80.0 ± 13.3 kg).

**Main Outcome Measure(s):** We collected the HT data using both the 1PT and 2PT from a total of 30 upper extremities (16 left, 14 right). Within-session intrarater reliability (intraclass correlation coefficient; ICC [3,1]) and standard error of measurement (SEM) were assessed for both techniques. Simple

linear regression and Bland-Altman analysis were used to examine the validity of the 1PT when compared with the established 2PT.

**Results:** The 1PT (ICC [3,1] = 0.992, SEM = 0.8°) and 2PT (ICC [3,1] = 0.979, SEM = 1.1°) demonstrated excellent within-session intrarater reliability. A strong linear relationship was demonstrated between the HT measurements collected with both techniques ( $r = 0.963$ ,  $r^2 = 0.928$ ,  $F_{1,28} = 361.753$ ,  $P < .001$ ). A bias of  $-1.2^\circ \pm 2.6^\circ$  was revealed, and the 95% limits of agreement indicated the 2 techniques can be expected to vary from  $-6.3^\circ$  to  $3.8^\circ$ .

**Conclusions:** The 1PT for measuring HT using ultrasound was a reliable and valid alternative to the 2PT. By reducing the number of testers involved, the 1PT may provide clinicians with a more efficient and practical means of obtaining these valuable clinical data.<sup>a</sup>

**Key Words:** humeral retroversion, ultrasonography, reliable, valid

## Key Points

- The 1-person technique for measuring humeral torsion using ultrasound was a reliable technique and a valid alternative to the 2-person technique.
- Using the 1-person technique improved efficiency by reducing the number of assessors needed to obtain the measurement.
- Increasing the efficient collection of humeral-torsion data may improve the feasibility of incorporating these measures into research studies and clinical settings, particularly when circumstances prevent access to another examiner.

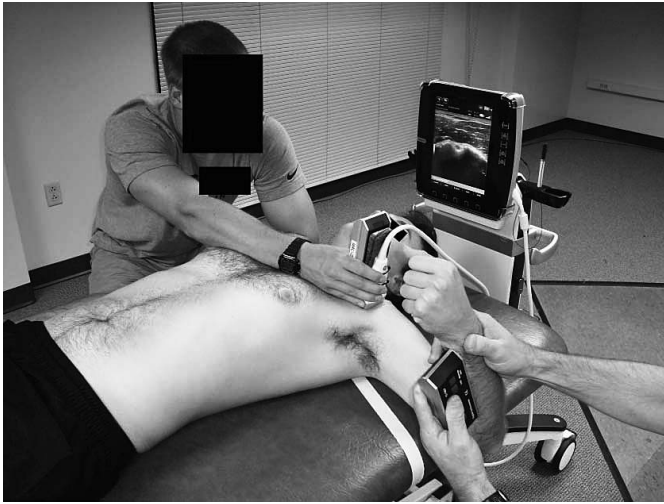
The incidence of injury to the shoulder and elbow is increasing among overhead athletes.<sup>1</sup> Researchers<sup>1–4</sup> have proposed several risk factors for injury, of which the simplest explanation may be that children and adolescents are participating in the same sports more frequently than in years past. As a consequence, these young athletes experience various bony and soft tissue adaptations to the upper extremity.<sup>5–7</sup> It is not well known whether these adaptations lead to improved performance,<sup>8,9</sup> increased risk of injury,<sup>1–3,10–12</sup> or both.

One of the most common adaptations found in overhead-throwing athletes is an alteration in the available range of internal and external shoulder rotation. These athletes

frequently have greater external rotation and less internal rotation in the throwing than in the nonthrowing shoulder.<sup>12–16</sup> Initially, changes in the laxity of the capsular tissues of the glenohumeral joint were thought to be the cause<sup>14,15,17</sup>; however, these claims have been refuted.<sup>18</sup> Nonetheless, evidence has suggested that soft tissue adaptations occur in overhead-throwing athletes.<sup>2,6,10</sup> Interestingly, these adaptations, which may result in deficits in either internal or external rotation (or both), have been identified as risk factors for upper extremity injury.<sup>2,10,11,19,20</sup>

Investigators<sup>5,7,21–29</sup> have demonstrated that osseous adaptations may account for a larger part of the adaptations observed in internal-rotation deficits and external-rotation gains in the overhead-throwing shoulder. In fact, research-

<sup>a</sup> This Abstract is adapted from *J Athl Train*. 2017;52(suppl 6):S-285 with permission from the National Athletic Trainers' Association.



**Figure 1.** Setup for the 2-person technique to measure humeral torsion using ultrasound.

ers<sup>5,30,31</sup> have reported that decreases in humeral torsion (HT) accounted for internal-rotation deficits of the glenohumeral joint. Whereas a large amount of the variance in internal-rotation deficits may be accounted for by decreases in HT, motion deficits may still exist after accounting for HT.<sup>6,32</sup> However, it is difficult to determine the direction of the rotational deficit if the amount of HT is unknown. Therefore, clinicians would benefit from knowing the amount of HT when treating overhead athletes with range-of-motion (ROM) deficits.

The current criterion-standard method for measuring HT uses computed tomography (CT) imaging.<sup>26</sup> However, this method is impractical, cost prohibitive, and invasive, as patients are exposed to ionizing radiation. A safer alternative using musculoskeletal ultrasound (US) to indirectly measure HT has been reported to be reliable<sup>25</sup> and valid,<sup>26</sup> yet this method requires 2 assessors. Clinicians may find a more efficient 1-person technique (1PT) valuable when a second assessor is unavailable. Therefore, the purpose of our study was to determine if a 1-person HT US measurement technique was a reliable and valid alternative to the established 2-person technique (2PT)<sup>25,26</sup> for indirectly measuring HT. We hypothesized that a 1PT would be a reliable and valid method for collecting HT measurements.

## METHODS

### Participants

A convenience sample of 16 volunteers (7 men, 9 women; age = 26.9 ± 6.8 years, height = 172.2 ± 10.7 cm, mass = 80.0 ± 13.3 kg) was recruited to participate.

Humeral-torsion data were measured using indirect US techniques from a total of 30 upper extremities (16 left, 14 right), and each extremity was considered an independent measure. Measurements from an upper extremity were excluded if the participant reported any known history of fractures to the forearm or humerus, elbow or shoulder surgery within the 6 months before the study or disease that could affect normal bony anatomy (eg, osteogenesis imperfecta, Paget disease [osteitis deformans], bone cancer, or tumor). Two right-side extremities were excluded from the study because the participants reported a history of fractures to the forearm. All participants provided written informed consent, and the study was approved by the Duquesne University Institutional Review Board.

### Procedures


To ascertain HT measurements, data were collected with participants lying supine on a treatment table for both the 1PT and 2PT. For the established 2PT,<sup>25,26</sup> participants lay with the involved upper extremity in 90° of shoulder abduction and elbow flexion and the forearm in a supinated position (Figure 1). Tester 1 (not an author) placed an 8- to 13-MHz linear-array US transducer (model Venue 40; GE Healthcare, Milwaukee, WI) on the anterior aspect of the proximal humerus to achieve a transverse-sectional (short-axis) view of the lesser and greater tubercles. To maintain consistency of the measurement among participants, the transducer was held perpendicular to the long axis of the humerus.<sup>25</sup> The head of the transducer was maintained in a horizontal position as verified by an attached digital inclinometer (Baseline Digital Inclinometer model 12-1057; Fabrication Enterprises, White Plains, NY). The US transducer was firmly attached to the inclinometer with multiple zip-tie fasteners. A piece of polystyrene was custom molded to fit the contour of the transducer and was affixed to both the transducer and inclinometer using double-sided tape. To calibrate the orientation of the transducer, the inclinometer was manually set to 0° while the transducer head was placed on a level surface. Our transducer setup was consistent with that of previous researchers (Figure 2).<sup>33,34</sup>

Tester 2 (D.C.H.) positioned the forearm of the participant by internally or externally rotating the humerus to align the apexes of the lesser and greater tubercles parallel with the head of the US transducer. To assist with aligning the tubercles, a transparent film with printed horizontal gridlines spaced 0.5 cm apart was affixed to the US unit's display. When the desired orientation of the humerus was achieved, tester 2 recorded the angular position of the forearm with respect to the horizontal plane using a second digital inclinometer (Baseline Digital Inclinometer model 12-1057; Fabrication Enterprises). This

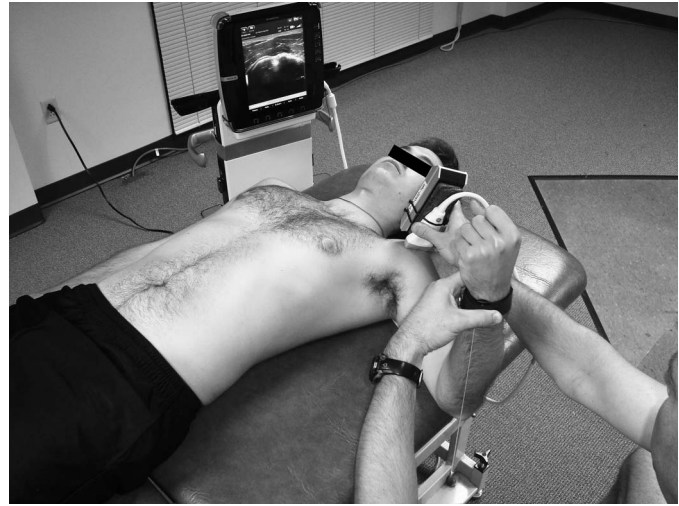**Table.** Descriptive and Reliability Statistics for Measuring Humeral Torsion Using Musculoskeletal Ultrasound

Technique <sup>a</sup>	Humeral Torsion, ° (Mean ± SD)			Intraclass Correlation Coefficient	Standard Error of Measurement
	Left	Right	Total		
1 Person	60.4 ± 7.3	69.0 ± 9.8	64.4 ± 9.5	0.992	0.8
2 Person	59.8 ± 7.8	67.0 ± 10.2	63.1 ± 9.6	0.979	1.1

<sup>a</sup> Different references of origin were used to measure the angle of humeral torsion for the 2 ultrasound techniques. For data analysis, the humeral-torsion data for the 1-person technique were corrected by subtracting the recorded value from 90°.



**Figure 2.** The attachment of the ultrasound transducer to the digital inclinometer.



**Figure 3.** Setup for the 1-person technique to measure humeral torsion using ultrasound.

inclinometer was held firmly against the medial aspect of the distal ulna.

For the 1PT, we used a tilting technique with the US transducer similar to an established method used for measuring torsion of the femur (Figure 3).<sup>33,34</sup> Again, participants lay with the involved upper extremity in 90° of elbow flexion and the forearm supinated. Tester 2 positioned the forearm vertically by aligning the ulna with a plumb line. The plumb line was secured to the wrist at the most medial aspect of the distal ulna using a hook-and-loop cinch strap and was allowed to hang freely, thereby creating a vertical reference line. While maintaining the vertical alignment of the forearm, the same investigator manipulated the US transducer to locate the lesser and greater tubercles of the humerus. The transducer was tilted about the long axis of the humerus until it was aligned parallel with the tubercles as verified on the display of the US unit. The orientation of the US transducer was measured by an attached digital inclinometer using the same setup as the 2PT. In reference to the long axis of the humerus, positive values of HT were recorded when the US transducer was tilted lateral to the vertical plane, and negative values were recorded when it was tilted medial to the vertical plane. In contrast to the 2PT, we adjusted the shoulder-abduction angle to 70° to prevent any risk of the acromion obscuring the view of the tubercles of the humerus because the reference position (setting the forearm in a vertical position) of the 1PT shifted the humerus into a more externally rotated position. To reduce bias in the collection of torsion data, the US transducer was held so that the inclinometer faced away from tester 2, and the angular output was recorded by tester 1.

The measures of HT for the 1PT and 2PT were recorded using 2 different points of reference. To perform the 2PT, participants with a torsion angle of 60° had their arms positioned in what would be described clinically as 30° of shoulder internal rotation while the transducer was maintained perpendicular to the greater and lesser tubercles. To perform the 1PT on the same individual, the forearm must be externally rotated 30° to align the forearm vertically. This rearrangement of the forearm resulted in the bicipital tubercles being rotated posteriorly 30°. Realignment

of the US transducer so it was perpendicular to the tubercles resulted in the US transducer being posteriorly tilted 30°. Humeral-torsion data collected using the 1PT were corrected for data analysis by subtracting the recorded value from 90°. Therefore, to obtain the corrected value for the 1PT, we performed the following calculation to achieve a matching value:  $90^\circ - 30^\circ = 60^\circ$ .

The testing orders for both technique and limb were randomly assigned. Three consecutive trials were performed for each technique and limb. At the end of each trial, the upper extremity was returned to the anatomic position and positioned by the side. After 1 minute, the limb was repositioned for data collection. Each investigator was blinded to the results recorded by the other investigator for the 1PT and 2PT.

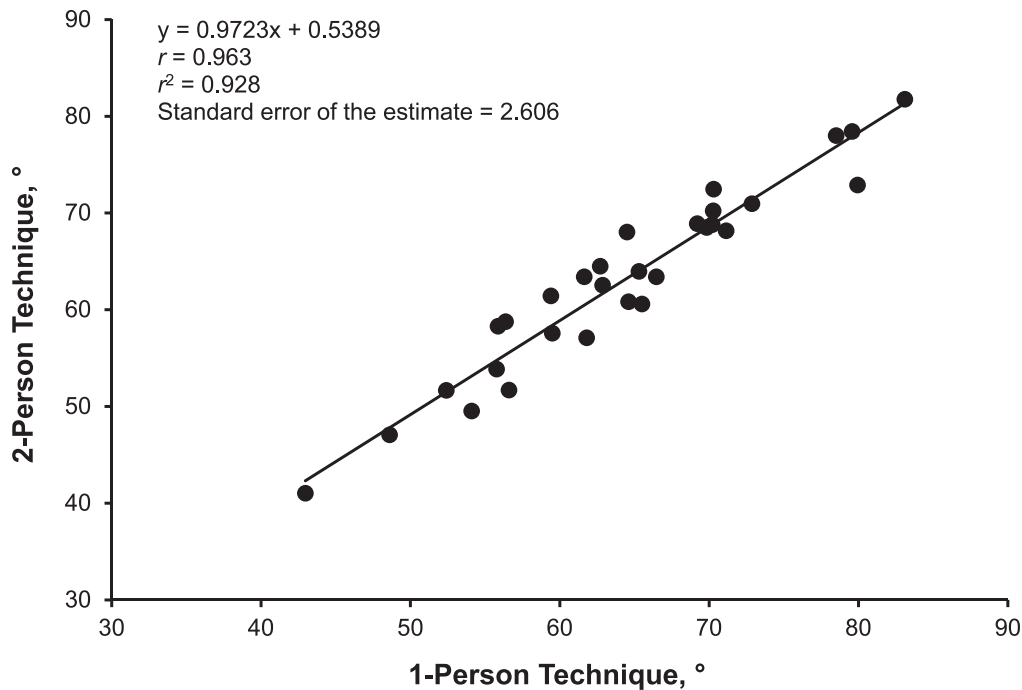
### Data Analysis

We used a 2-way mixed-model (intraclass correlation coefficient; ICC [3,1]) analysis with measures of absolute agreement to assess within-session intrarater reliability across all 3 trials for both the 1PT and 2PT. We assessed precision with the standard error of measurement (SEM) and used the following formula:  $SEM = SD\sqrt{1 - ICC}$ , where *SD* indicated the standard deviation.<sup>35</sup> Simple linear regression and Bland-Altman agreement analysis were used to examine the validity of the 1PT when compared with the established 2PT. The SEM, simple linear regression, and Bland-Altman agreement analysis were calculated using mean values from all 3 trials of each technique. We set the  $\alpha$  level at  $\leq .05$  and performed statistical analyses using SPSS (version 22.0; IBM Corp, Armonk, NY).

### RESULTS

Descriptive statistics are presented in the Table. Reliability and precision were similar for the 2 techniques. We observed excellent within-session intrarater reliability measures for both the 1PT (ICC [3,1] = 0.992) and 2PT (ICC [3,1] = 0.979). For the precision assessment, the SEM values were 0.8° for the 1PT and 1.1° for the 2PT (Table).

The results of the simple linear regression analysis demonstrated that HT measurements collected using the



**Figure 4.** Scatter plot and fitted regression line for the relationship between the 1- and 2-person techniques for collecting humeral-torsion measurements using ultrasound.

1PT had a strong linear relationship with measurements collected using the 2PT (Figure 4). According to the model, the 1PT was a predictor ( $r^2 = 0.928$ ,  $F_{1,28} = 361.753$ ,  $P < .001$ ), accounting for 93% of the total variance in the 2PT. The Bland-Altman agreement analysis showed a bias of  $-1.2^\circ \pm 2.6^\circ$  between the 2 techniques (Figure 5). In addition, the 95% limits of agreement indicated that the difference between the techniques could be expected to vary from  $-6.3^\circ$  to  $3.8^\circ$ .

## DISCUSSION

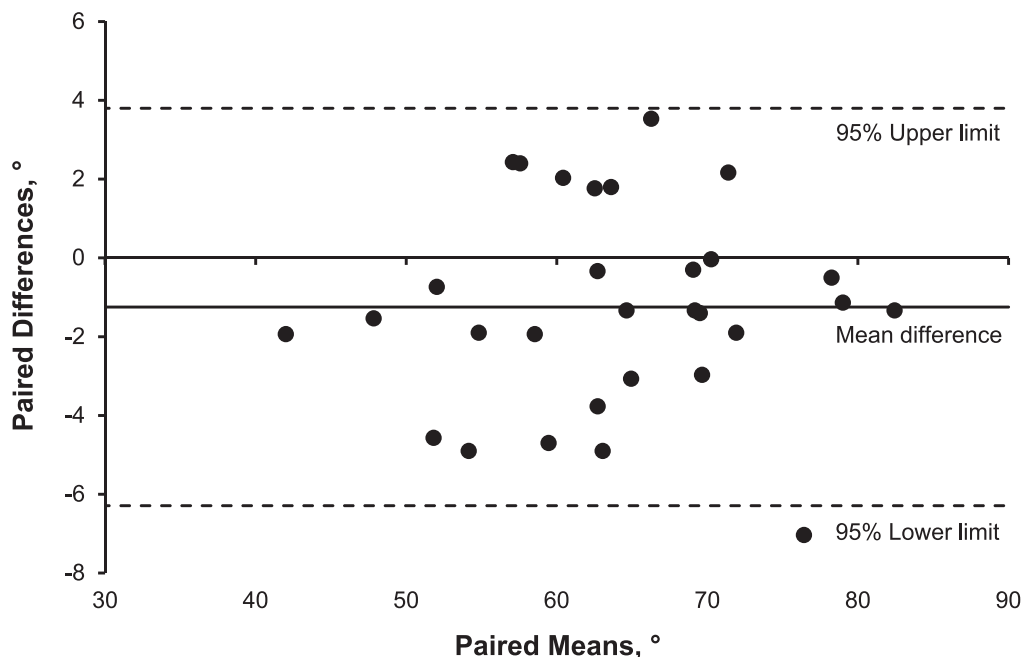
The purpose of our investigation was to determine whether a 1PT was a reliable and valid way to indirectly measure HT with US when using the established 2PT as the measurement criterion. Our results strongly supported using the 1PT as a reliable and valid alternative to the 2PT. As the evidence builds in support of the substantial HT adaptations that occur in overhead-throwing athletes, investigators should continue to explore how these adaptations affect performance and injury risk. Additionally, research is needed to help clinicians understand how these adaptations should be considered or incorporated, or both, when developing therapeutic interventions. Ultrasound provides a safe, relatively inexpensive, and practical means to measure HT. However, the established 2PT may be considered suboptimal because it requires 2 assessors; therefore, clinicians and researchers may find that the 1PT we have validated is valuable.

Regarding reliability, our results indicated that both the 1PT and 2PT had excellent repeatability (ICC [3,1] = 0.992 and 0.979, respectively) with minimal measurement error (SEM =  $0.8^\circ$  and  $1.1^\circ$ , respectively). To have confidence in the 2PT as the measurement criterion for validation purposes, we had to replicate measures of reliability and precision similar to those reported in the literature. The 2PT

has consistently demonstrated high measures of reliability, with intrarater ICCs ranging from 0.907 to 0.997, and tolerable measures of precision, with SEMs ranging from  $0.8^\circ$  to  $5.0^\circ$ .<sup>26,30,36,37</sup> Given that our reliability results could be characterized as excellent<sup>38</sup> and after achieving a comparatively high degree of precision, we were confident in moving forward with validation testing.

The 1PT demonstrated excellent criterion-related validity for measuring HT. The regression model revealed a strong, positive linear relationship ( $r = 0.963$ ), with the 1PT accounting for 93% of the total variance in the 2PT. As the regression model indicated, for each degree of HT measured by the 1PT, nearly  $1^\circ$  of HT was recorded by the 2PT. Therefore, the 1PT appears to be a statistically sound and practical alternative to the 2PT, especially when considering the improved efficiency of needing only 1 assessor.

When establishing the validity of the 2PT, Myers et al<sup>26</sup> reported considerable variability between CT and the 2PT based on their Bland-Altman agreement analysis ( $36^\circ$  of potential difference). However, given the clinical usefulness of the US method, it seemed only appropriate to use the 2PT as the criterion method for our validation study. In our study, the Bland-Altman agreement analysis indicated that the 2 techniques can be expected to vary by as much as  $\pm 5.0^\circ$ , and the data of all but 1 of our participants fell within the 95% limits of agreement of the difference scores. Whereas the potential difference between the 2 techniques may be clinically relevant, we believe a few elements may account for the variability between them. Some of the variability between the techniques may be due to measurement error associated with precisely locating the apices of the greater and lesser tubercles of the humerus. We observed a few situations in which the apices were not perfectly aligned when maintaining the US probe perpendicular to the long axis of the humerus. In these cases of



**Figure 5.** Bland-Altman plot showing the 95% limits of agreement between the 1- and 2-person techniques for collecting humeral-torsion measurements using ultrasound.

anatomic variation, we found that the apex of either tubercle was slightly more proximal or distal than the other. An additional source of variability may be due to inconsistencies in how the instruments were aligned with the forearm. With the 2PT, the inclinometer was pressed firmly against the medial border of the distal aspect of the ulna. However, with the 1PT, a plumb line was aligned with the most medial aspects of the distal and proximal ulna. Variability associated with the contour of the ulnar shaft, the amount of interposed soft tissue between the inclinometer and ulna, or misalignment of the plumb line with the ulnar shaft may have accounted for the variability observed between the 2 techniques.

When we compared the 2 techniques, the 1PT was favorable because of the overall improvement in efficiency. Most notably, the 1PT provides clinicians and researchers with a means of collecting HT data autonomously, particularly when another assessor is not available. In addition, we noted the 2PT required several bouts of repositioning the US probe and forearm to achieve the desired view and position for collecting the measurement. This was substantially reduced, if not completely eliminated, with the 1PT. It was our experience that, when the forearm was aligned with the plumb line, the fixed position was easily held during the assessment. Given that the arm was held stationary, only the probe needed to be manipulated to the desired position. The single drawback to using the 1PT that we can foresee would be when an assessor does not have sufficient upper extremity length to maintain control of the US probe while concurrently visualizing the plumb line, the inclinometer, and the US unit's display. In this circumstance, using the 2PT would be sensible; otherwise the 1PT may have an advantage in overall efficacy and efficiency.

In the clinical setting, the 1PT may be useful to clinicians implementing therapeutic interventions for mitigating

injury risk associated with ROM deficits. Researchers have demonstrated that side-to-side differences in glenohumeral ROM are linked to injury in overhead-throwing athletes, but evidence regarding the direction of rotational deficit is conflicting.<sup>2,10,11,19,20</sup> Traditionally, glenohumeral internal-rotation deficit (GIRD) has been considered the most influential link to shoulder conditions in overhead-throwing athletes.<sup>12</sup> However, greater awareness of GIRD may be shifting that focus, as Wilk et al<sup>10</sup> recently demonstrated that external-rotation deficits (dominant-side external-rotation gains of less than 5°), not GIRD, were linked with shoulder injuries and surgery. In any case, rotational deficits continue to exist. More importantly, many investigators<sup>2,10,11,19,20</sup> did not normalize ROM measurements based on HT despite the known influence it has on ROM measures.<sup>5,7,21–29</sup> As such, clinicians should be cautious when interpreting these studies and blindly implementing interventions to “improve” rotational deficits based on simple bilateral goniometric assessments. Incorporating HT measurements into ROM calculations as noted by others<sup>5,6,25,32</sup> will enable clinicians to accurately determine how much and in which direction interventions should be implemented to address deficits caused by soft tissue. Whereas implementing HT measurements has not become part of routine clinical practice, several authors<sup>7,23,25,31</sup> have suggested its implementation to accurately differentiate between bony and soft tissue adaptations that may affect rotation ROM measures in overhead athletes. The results of this implementation may be to prevent any deleterious effects that could result from stretching the glenohumeral joint beyond its physiological end ROM.

Our study had 2 limitations that require consideration. The first limitation was the use of a measurement criterion for validation that is not currently considered the criterion standard for measuring HT. However, we considered a comparison with CT imaging unnecessary because (1) CT

imaging is costly and exposes individuals to ionizing radiation, (2) the 2PT using US has been deemed a reliable<sup>25</sup> and valid alternative,<sup>26</sup> and (3) the purpose of our study was not to identify a new method of determining HT by identifying other anatomic landmarks but rather to alter the 2PT to improve efficiency. The second limitation of our study was that we assessed only within-session intrarater reliability. Establishing between-sessions reliability, as well as interrater reliability, of this new technique may be useful. Therefore, we suggest future investigations of these reliability measures.

## CONCLUSIONS

Our findings indicated that the 1PT for measuring HT using US was a reliable technique. Similarly, we believe that the 1PT is a valid alternative to the 2PT even when considering the variability that exists between the 2 techniques. Furthermore, using the 1PT improved efficiency by reducing the number of examiners needed to obtain the measurement. The improved efficiency for collecting HT data may enhance the feasibility of using these measures in research studies and clinical settings, particularly when circumstances prevent access to another examiner. Clinicians should consider integrating HT-corrected measures of internal and external shoulder rotation to correctly determine both the direction and extent of motion deficits, allowing for accurate interventions that may effectively reduce injury risk.

## ACKNOWLEDGMENTS

We thank Ian B. Shadle, ATC, for his assistance with data collection. The contents of this study were presented as a poster at the 2017 Eastern Athletic Trainer's Association Annual Meeting (Philadelphia, PA) and Clinical Symposium and 2017 National Athletic Trainers' Association Clinical Symposia (Houston, TX).

## REFERENCES

- Olsen SJ II, Fleisig GS, Dun S, Loftice J, Andrews JR. Risk factors for shoulder and elbow injuries in adolescent baseball pitchers. *Am J Sports Med.* 2006;34(6):905–912.
- Shanley E, Rauh MJ, Michener LA, Ellenbecker TS, Garrison JC, Thigpen CA. Shoulder range of motion measures as risk factors for shoulder and elbow injuries in high school softball and baseball players. *Am J Sports Med.* 2011;39(9):1997–2006.
- Lyman S, Fleisig GS, Waterbor JW, et al. Longitudinal study of elbow and shoulder pain in youth baseball pitchers. *Med Sci Sports Exerc.* 2001;33(11):1803–1810.
- Register-Mihalik JK, Oyama S, Marshall SW, Mueller FO. Pitching practices and self-reported injuries among youth baseball pitchers: a descriptive study. *Athl Train Sports Health Care.* 2012;4(1):11–20.
- Hibberd EE, Oyama S, Myers JB. Increase in humeral retrotorsion accounts for age-related increase in glenohumeral internal rotation deficit in youth and adolescent baseball players. *Am J Sports Med.* 2014;42(4):851–858.
- Oyama S, Hibberd EE, Myers JB. Changes in humeral torsion and shoulder rotation range of motion in high school baseball players over a 1-year period. *Clin Biomech (Bristol, Avon).* 2013;28(3):268–272.
- Whiteley RJ, Ginn KA, Nicholson LL, Adams RD. Sports participation and humeral torsion. *J Orthop Sports Phys Ther.* 2009;39(4):256–263.
- Whiteley R. Baseball throwing mechanics as they relate to pathology and performance: a review. *J Sports Sci Med.* 2007;6(1):1–20.
- Whiteley R, Adams R, Ginn K, Nicholson L. Playing level achieved, throwing history, and humeral torsion in Masters baseball players. *J Sports Sci.* 2010;28(11):1223–1232.
- Wilk KE, Macrina LC, Fleisig GS, et al. Deficits in glenohumeral passive range of motion increase risk of shoulder injury in professional baseball pitchers: a prospective study. *Am J Sports Med.* 2015;43(10):2379–2385.
- Dines JS, Frank JB, Akerman M, Yocum LA. Glenohumeral internal rotation deficits in baseball players with ulnar collateral ligament insufficiency. *Am J Sports Med.* 2009;37(3):566–570.
- Burkhart SS, Morgan CD, Kibler WB. The disabled throwing shoulder: spectrum of pathology. Part I: pathoanatomy and biomechanics. *Arthroscopy.* 2003;19(4):404–420.
- Brown LP, Niehues SL, Harrah A, Yavorsky P, Hirshman HP. Upper extremity range of motion and isokinetic strength of the internal and external shoulder rotators in Major League Baseball players. *Am J Sports Med.* 1988;16(6):577–585.
- Bigliani LU, Codd TP, Connor PM, Levine WN, Littlefield MA, Hershon SJ. Shoulder motion and laxity in the professional baseball player. *Am J Sports Med.* 1997;25(5):609–613.
- Downar JM, Sauers EL. Clinical measures of shoulder mobility in the professional baseball player. *J Athl Train.* 2005;40(1):23–29.
- Meister K, Day T, Horodyski M, Kaminski TW, Wasik MP, Tillman S. Rotational motion changes in the glenohumeral joint of the adolescent/Little League baseball player. *Am J Sports Med.* 2005;33(5):693–698.
- Jobe FW, Kvitne RS, Giangarra CE. Shoulder pain in the overhand or throwing athlete: the relationship of anterior instability and rotator cuff impingement. *Orthop Rev.* 1989;18(9):963–975.
- Borsa PA, Wilk KE, Jacobson JA, et al. Correlation of range of motion and glenohumeral translation in professional baseball pitchers. *Am J Sports Med.* 2005;33(9):1392–1399.
- Myers JB, Laudner KG, Pasquale MR, Bradley JP, Lephart SM. Glenohumeral range of motion deficits and posterior shoulder tightness in throwers with pathologic internal impingement. *Am J Sports Med.* 2006;34(3):385–391.
- Ruotolo C, Price E, Panchal A. Loss of total arc of motion in collegiate baseball players. *J Shoulder Elbow Surg.* 2006;15(1):67–71.
- Myers JB, Oyama S, Rucinski TJ, Creighton RA. Humeral retrotorsion in collegiate baseball pitchers with throwing-related upper extremity injury history. *Sports Health.* 2011;3(4):383–389.
- Hibberd EE, Oyama S, Tatman J, Myers JB. Dominant-limb range-of-motion and humeral-retrotorsion adaptation in collegiate baseball and softball position players. *J Athl Train.* 2014;49(4):507–513.
- Mihata T, Takeda A, Kawakami T, et al. Isolated glenohumeral range of motion, excluding side-to-side difference in humeral retroversion, in asymptomatic high-school baseball players. *Knee Surg Sports Traumatol Arthrosc.* 2016;24(6):1911–1917.
- Crockett HC, Gross LB, Wilk KE, et al. Osseous adaptation and range of motion at the glenohumeral joint in professional baseball pitchers. *Am J Sports Med.* 2002;30(1):20–26.
- Whiteley R, Ginn K, Nicholson L, Adams R. Indirect ultrasound measurement of humeral torsion in adolescent baseball players and non-athletic adults: reliability and significance. *J Sci Med Sport.* 2006;9(4):310–318.
- Myers JB, Oyama S, Clarke JP. Ultrasonographic assessment of humeral retrotorsion in baseball players: a validation study. *Am J Sports Med.* 2012;40(5):1155–1160.
- Chant CB, Litchfield R, Griffin S, Thain LM. Humeral head retroversion in competitive baseball players and its relationship to glenohumeral rotation range of motion. *J Orthop Sports Phys Ther.* 2007;37(9):514–520.

28. Reagan KM, Meister K, Horodyski MB, Werner DW, Carruthers C, Wilk K. Humeral retroversion and its relationship to glenohumeral rotation in the shoulder of college baseball players. *Am J Sports Med.* 2002;30(3):354–360.
29. Osbahr DC, Cannon DL, Speer KP. Retroversion of the humerus in the throwing shoulder of college baseball pitchers. *Am J Sports Med.* 2002;30(3):347–353.
30. Noonan TJ, Shanley E, Bailey LB, et al. Professional pitchers with glenohumeral internal rotation deficit (GIRD) display greater humeral retrotorsion than pitchers without GIRD. *Am J Sports Med.* 2015;43(6):1448–1454.
31. Myers JB, Oyama S, Goerger BM, Rucinski TJ, Blackburn JT, Creighton RA. Influence of humeral torsion on interpretation of posterior shoulder tightness measures in overhead athletes. *Clin J Sport Med.* 2009;19(5):366–371.
32. Reuther KE, Sheridan S, Thomas SJ. Differentiation of bony and soft-tissue adaptations of the shoulder in professional baseball pitchers [published online ahead of print]. *J Shoulder Elbow Surg.* 2018. doi: 10.1016/j.jse.2018.02.053.
33. Hudson D, Royer T, Richards J. Ultrasound measurements of torsions in the tibia and femur. *J Bone Joint Surg Am.* 2006;88(1):138–143.
34. Kulig K, Harper-Hanigan K, Souza RB, Powers CM. Measurement of femoral torsion by ultrasound and magnetic resonance imaging: concurrent validity. *Phys Ther.* 2010;90(11):1641–1648.
35. Denegar CR, Ball DW. Assessing reliability and precision of measurement: an introduction to intraclass correlation and standard error of measurement. *J Sport Rehabil.* 1993;2(1):35–42.
36. Schwab LM, Blanch P. Humeral torsion and passive shoulder range in elite volleyball players. *Phys Ther Sport.* 2009;10(2):51–56.
37. Feuerherd R, Sutherlin MA, Hart JM, Saliba SA. Reliability of and the relationship between ultrasound measurement and three clinical assessments of humeral torsion. *Int J Sports Phys Ther.* 2014;9(7):938–947.
38. Portney LG, Watkins MP. *Foundations of Clinical Research: Applications to Practice.* 3rd ed. Philadelphia, PA: F. A. Davis; 2015:594–595.

---

Address correspondence to Daniel C. Hannah, MS, LAT, ATC, Department of Orthopaedic Surgery, Augusta University, 1120 15th Street, BA-3300, Augusta, GA 30912. Address e-mail to [dahannah@augusta.edu](mailto:dahannah@augusta.edu).