

# Running a Marathon—Its Influence on Achilles Tendon Structure

Lucas Maciel Rabello, PhD\*; Iris Sophie Albers, MSc\*; Mathijs van Ark, PhD\*†‡; Ron L. Diercks, PhD§; Inge van den Akker-Scheek\*; Johannes Zwerver, PhD\*

\*Department of Sports and Exercise Medicine and §Department of Orthopedics, University of Groningen, University Medical Center Groningen, The Netherlands; †Department of Physiotherapy, Hanze University of Applied Sciences, Groningen, The Netherlands; ‡Centre of Expertise Primary Care Groningen (ECEZG), Peescentrum (Tendon Centre), The Netherlands

**Context:** Several studies have been conducted to better understand the effect of load on the Achilles tendon structure. However, the effect of a high cumulative load consisting of repetitive cyclic movements, such as those that occur during the running of a marathon, on Achilles tendon structure is not yet clear. Clinicians, coaches, and athletes will benefit from knowledge about the effects of a marathon on the structure of the Achilles tendon.

**Objective:** To investigate the short-term response of the Achilles tendon structure to running a marathon.

**Design:** Case series (prospective).

**Setting:** Sports medicine centers.

**Patients or Other Participants:** Ten male nonelite runners who ran in a marathon.

**Main Outcomes Measure(s):** Tendon structure was assessed before and 2 and 7 days after a marathon using ultrasound tissue characterization (UTC), an imaging tool that quantifies tendon organization in 4 echo types (I–IV). Echo type I

represents the most stable echo pattern, and echo type IV, the least stable.

**Results:** At 7 days postmarathon, both the insertional and midportion structure changed significantly. At both sites, the percentage of echo type II increased (insertion  $P < .01$ ; midportion  $P = .02$ ) and the percentages of echo types III and IV decreased (type III: insertion  $P = .01$ ; midportion  $P = .02$ ; type IV: insertion  $P = .01$ ; midportion  $P < .01$ ). Additionally, at the insertion, the percentage of echo type I decreased ( $P < .01$ ).

**Conclusions:** We observed the effects of running a marathon on the Achilles tendon structure 7 days after the event. Running the marathon combined with the activity performed shortly thereafter might have caused the changes in tendon structure. This result emphasizes the importance of sufficient recovery time after running a marathon to prevent overuse injuries.

**Key Words:** lower leg, ankle, men

## Key Points

- In contrast to the results of previous research in different populations, we found changes in the Achilles tendon structure at 7 days postactivity but not at 2 days postactivity.
- Despite the changes in the tendon structure at different sites (insertion and midportion), similar changes were present in both after the participants ran a marathon.
- Performing physical activity shortly after running a marathon might influence the changes in the Achilles tendon structure.

According to the 2017 Running USA annual report, more than half a million athletes participated in a marathon.<sup>1</sup> These high numbers might be explained by the low cost of marathon participation<sup>2</sup> and awareness of the benefits of being physically active.<sup>3</sup> Moderate aerobic exercise, such as running, results in health improvements such as reductions in the risks of chronic diseases including hypertension, hyperlipidemia, and diabetes.<sup>4</sup> Although regular moderate aerobic exercise has many benefits, participants who engage in running also frequently develop and report musculoskeletal injuries, especially to the lower limbs.<sup>5</sup> In fact, Achilles tendon disorders were among the 5 most common injuries sustained by runners.<sup>6</sup>

During running, the Achilles tendon is subjected to high loads and multiple tensile strain cycles.<sup>7,8</sup> Short-duration

exercise does not affect Achilles tendon structure,<sup>9,10</sup> but the effects of a marathon are not yet clear. Previous researchers showed that tendon stiffness did not change 1 hour postmarathon<sup>11</sup> but decreased 3 days postmarathon.<sup>12</sup> An increase in intratendinous Doppler signal was also observed 3 days postmarathon.<sup>12</sup>

Different imaging tools have been used to assess tendon structure, including ultrasound tissue characterization (UTC). This technique was introduced to objectively quantify changes in tendon structure by dividing them into echo types I through IV; these types are based on the stability of intensity and distribution of contiguous transverse images.<sup>13</sup> Investigators have used this imaging technique to study the effect of various loads on the Achilles tendon at various follow-up periods and in different populations.<sup>10,14–17</sup> However, the number of

studies assessing the changes in Achilles tendon structure after a single running bout (not related to other activities) is limited. Wong et al<sup>17</sup> found no change in Achilles tendon structure in participants with type 1 diabetes mellitus 4 days after a 10-km run. Other authors<sup>10</sup> identified no change in tendon structure 7 days after a single running bout (high and low loads). To our knowledge, no researchers have used UTC to determine the effect of running a marathon on tendon structure.

Elucidating the effect of high loads on the Achilles tendon structure is necessary given the importance of preventing injuries such as Achilles tendinopathy, a common and challenging condition to treat.<sup>18</sup> Hence, the aim of our study was to determine the short-term response of the Achilles tendon structure after running a marathon. Based on the continuum model proposed by Cook and Purdam,<sup>19</sup> which described the acute response of the tendon to load as a reactive stage, we hypothesized that echo patterns would change (decrease in echo type I and increase in echo type II) transiently on postmarathon day 2 and return to baseline a week later. Moreover, because the tendon overload is acute during a marathon, our hypothesis was that at a short-term follow-up of 1 week, no changes in the disorganized tendon structure (echo types III and IV) would be evident.

## METHODS

### Participants

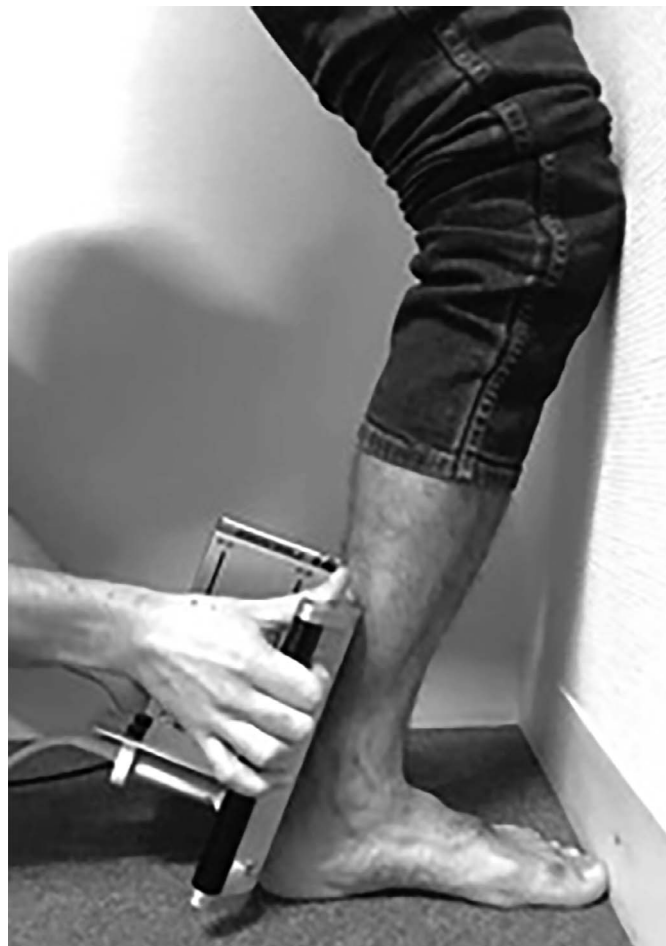Ten male nonelite marathon runners who participated in the 2014 Mar-athon in Sneek, The Netherlands, were recruited for this study. We included participants in the study if they had previous running experience and were training to run a marathon. We excluded participants if they had current complaints about the Achilles tendon or if they had been diagnosed with any systemic disease (eg, diabetes, rheumatoid arthritis). The study protocol was reviewed by the Medical Ethical Committee of University Medical Center Groningen (2014/138), and all participants provided written informed consent.

### Measurements

Two days before the marathon (VISIT1), participants visited the Sport Medicine Center of University Medical Center Groningen to undergo the UTC examination and complete a baseline questionnaire about anthropometric characteristics, medical history, and physical activity. At the end of this visit, participants were instructed to use a logbook to monitor their load in the remaining days before and the week after the marathon. After the marathon, participants underwent UTC examinations at 2 (VISIT2) and 7 (VISIT3) days after the marathon. We chose this design based on the expected physiological changes in tendon tissue structure postloading.<sup>20</sup> Using the same protocol, Rosengarten et al<sup>16</sup> observed changes in tendon structure 2 days after activity that returned to normal 4 days after activity. Like Heyward et al,<sup>10</sup> we investigated the effect of 2 load intensities on Achilles tendon structure.

### Ultrasound Tissue Characterization

The Achilles tendon structure was quantified using the UTC imaging tool. Two experienced examiners (M.v.A.



**Figure 1. Patient position during ultrasound tissue characterization examination.**

and I.S.A.) performed the scans, and the images were analyzed by a third examiner (L.M.R.) with experience in UTC imaging analysis. The images were acquired using a 7- to 10-MHz linear ultrasound transducer (model 2000+ SmartProbe 12L5-V; Teratech Corp, Burlington, MA), which was positioned in a tracking device (model UTC Tracker; UTC Imaging, Stein, The Netherlands). The tracker moved automatically along the long axis of the Achilles tendon over a distance of 12 cm so the transducer could record images at intervals of 0.2 mm. The tracker also standardized the transducer tilt, angle, gain, focus, and depth. The UTC is considered a reliable imaging tool for assessing the Achilles tendon structure and categorizes the structure into 4 echo types (I–IV); these types allow for excellent interobserver (intraclass correlation coefficient [ICC] = 0.92–0.95) and intraobserver (ICC = 0.88) reliability.<sup>21,22</sup>

Participants were positioned with the great toe and knee to the wall to ensure the same intraindividual degree of flexion for each scan (Figure 1), and only the left side was scanned (an a priori decision). Coupling gel was applied between the standoff pad, skin, and transducer to ensure maximum contact. The tracking device was placed on the posterior aspect of the calcaneal region perpendicular to the long axis of the Achilles tendon so that the calcaneus was visible on imaging. This bony landmark served as a reference point for analyzing the tendon structure. The

**Table 1. Participant Characteristics**

Characteristic	Mean ± SD	Range
Age, y	48 ± 4.1	31–70
Body mass index (calculated as kg/m <sup>2</sup> )	22.6 ± 0.4	20.7–25.3
Running experience, y	15.6 ± 2.8	3–25
Training volume per week		
Hours	5.5 ± 0.7	3–10
Kilometers	49.5 ± 4.7	30–75
Victorian Institute of Sport Assessment-Achilles Questionnaire score <sup>a</sup>	99 ± 0.5	95–100

<sup>a</sup> A Dutch version of the questionnaire was used to assess current Achilles tendon symptoms.<sup>5</sup>

recorded images were stored using UTC software (version 1.05; UTC Imaging), and the UTC algorithm quantified echo types across a rolling window of 17 continuous images.

Tendon structure was quantified from a region of interest that was contoured around the border of the Achilles tendon at its insertion and midportion. For both tendon parts, contours were drawn in areas of 2 cm at intervals of 5 mm. This method was based on previous UTC studies.<sup>10,16,23–25</sup> The *insertion of the tendon* was defined as the end of the calcaneus to the 2-cm point, and the *midportion* was defined as 2 to 4 cm from the calcaneus.

Using UTC, we divided the tendon structure into 4 echo types: echo type I, intact and aligned tendon bundles; echo type II, less integer and waving tendon bundles; echo type III, mainly fibrillar tissue; and echo type IV, a mainly amorphous matrix with loose fibrils, cells, or fluid.<sup>21</sup>

### Statistical Analysis

Because the data were not normally distributed, we calculated the medians and interquartile ranges for all 4 echo types at each measurement. To compare echo-type percentages, we performed a Wilcoxon signed rank test. All analyses were conducted using SPSS (version 22; IBM Corp, Armonk, NY), and significance was set at  $P < .05$ .

### RESULTS

Characteristics of the 10 participants are shown in Table 1. None had current symptoms of Achilles tendinopathy (an exclusion criterion). Five participants had a history of Achilles tendon symptoms but none showed pathologic changes at baseline. A total of 28 scans were conducted: 1 participant did not show up for the second scan, and the final scan of another participant could not be performed due to technical problems. Because the percentage of missing data in this study was low (around 5%), they were not replaced by imputation.<sup>26</sup>

During the week after the marathon and based on the logbooks, 2 participants ran twice, 7 participants ran once, and 1 participant did not perform any activity. The distances covered by the participants who ran once ranged from 5 to 10 km. The participants who ran twice covered a total of 20 km each. None of the runners reported pain after these activities.

The median and interquartile ranges for each echo type in the insertion and midportion areas are shown in Tables 2 and 3, respectively. Comparing the echo-type percentages at baseline of the insertion portion and the midportion, we

**Table 2. Insertion Echo Types at Each Measurement Time**

Insertion Echo Type	Measurement, Days Postmarathon	Median % (Interquartile Range)	<i>P</i> Values Compared With Baseline (Wilcoxon Signed Rank Test)
I	Baseline	73.1 (7.65)	.314
	2	72.7 (6.03)	.008
	7	63.9 (9.95)	
II	Baseline	26.1 (5.71)	.314
	2	25.9 (3.88)	.008
	7	35.4 (8.96)	
III	Baseline	0.73 (1.35)	.26
	2	0.69 (0.62)	.015
	7	0.42 (1.04)	
IV	Baseline	0.33 (0.74)	.374
	2	0.24 (0.45)	.011
	7	0.07 (0.17)	

observed a greater amount of echo type I in the midportion ( $P = .04$ ) and a greater amount of echo type II in the insertion ( $P = .038$ ).

At 2 days postmarathon, we found no changes in the percentages of any echo types for the insertion or midportion areas. In contrast, at 7 days postmarathon, the insertion showed decreases in the percentages of echo types I ( $P < .01$ ), III ( $P = .01$ ), and IV ( $P = .01$ ) as well as an increase in the percentage of echo type II ( $P < .01$ ); the midportion displayed a decrease in the percentage of echo types III ( $P = .02$ ) and IV ( $P < .01$ ) as well as an increase in the percentage of echo type II ( $P = .02$ ). An example of the UTC changes in the midportion of the Achilles tendon over the study period appears in Figure 2.


### DISCUSSION

To our knowledge, we are the first to use UTC equipment to determine whether the Achilles tendon structure (insertion and midportion) changed in participants after running a marathon. We observed no changes at 2 days postmarathon but significant changes at 7 days postmarathon. At both the insertion and midportion tendon sites, the percentage of echo type II increased and the percentages of echo types III and IV decreased.

Our results at 2 days postmarathon corroborated those of previous authors,<sup>10,17</sup> who also observed no changes in Achilles tendon structure on UTC 2 days after the activity;

**Table 3. Midportion Echo Types at Each Measurement Time**

Midportion Echo Type	Measurement, Days Postmarathon	Median % (Interquartile Range)	<i>P</i> Values Compared With Baseline (Wilcoxon Signed Rank Test)
I	Baseline	75.9 (5.88)	
	2	77.6 (5.90)	.26
	7	72.1 (11.99)	.051
II	Baseline	23.1 (5.35)	
	2	25.5 (5.43)	.594
	7	26.7 (12.08)	.021
III	Baseline	0.75 (0.67)	
	2	0.35 (0.82)	.314
	7	0.28 (0.46)	.028
IV	Baseline	0.43 (0.54)	
	2	0.16 (0.56)	.314
	7	0.10 (0.12)	.008



**Figure 2.** Ultrasound tissue characterization (transverse) images of the midportion Achilles tendon of a participant before and 2 and 7 days after a marathon showing the increase in the percentage of echo type II (blue). The changes in echo types III and IV were very small and cannot be seen in a single frame analysis.

those studies were of different populations after 10-km and 20-minute treadmill runs. However, our findings were not consistent with the results of Rosengarten et al,<sup>27</sup> who noted changes in the percentages of echo types I and II at 2 days after an Australian football game. Explanations for these divergent results might include the increased load<sup>28</sup> and the fact that Australian football involves more explosive bursts of running as well as jumping and cutting maneuvers. Moreover, the runners in this study were allowed to perform sport activities during the follow-up period. Most activities were performed at 3 to 7 days postmarathon, which might have influenced the changes in tendon structure at 7 days postmarathon.

At 7 days postmarathon, the increase in the percentage of echo type II (at the tendon insertion and midportion) and the decrease in the percentage of echo type I (at the tendon insertion) suggest a reactive response of the tendon to the cumulative load (marathon plus activities during the first week postmarathon). According to the continuum model proposed by Cook and Purdam,<sup>19</sup> the reactive stage is the first acute (short-term) response of the tendon to the load. The load performed by the participants in this study might have produced overload because most of the runners ran at least once shortly after the marathon. Based on previous investigations<sup>10,17</sup> that showed no changes in Achilles tendon structure after moderate activity (eg, a 10-km run), postmarathon activities alone would not cause changes in tendon structure. The response we observed might be a reaction to the cumulative load. The initial tendon response (at 2 days postmarathon) showed that running the marathon did not seem to exceed the tendon load capacity of the experienced runners (ie, no changes in tendon structure), yet the training sessions shortly after the marathon may have caused a net state of collagen catabolism instead of stimulated collagen synthesis (significant increase in the percentage of echo type II).<sup>29</sup> Thus, the recovery period may have been too short or the load performed after the marathon combined with the marathon load may have been too high, or both.

In addition to the changes in the percentages of echo types I and II, at 7 days postmarathon, decreases in the percentages of echo types III and IV were demonstrated in both the insertion and midportion areas. It is, however, important to stress that the changes observed were minimal: at baseline, the sum of echo types III and IV did not exceed 2%. This low percentage confirms that only participants with nonpathologic images (tendons without a large amount of disorganized structure) were included in this study. The fact that the participants were not novice runners (mean of 15 years' running experience)—which suggests that their tendons were adapted to high loads—might also explain the results.

Our data indicate that excessive load, such as that incurred from running a marathon, had an effect—albeit a late one—on the tendon structure of healthy male runners. Yet the activities performed immediately after the marathon (from days 2 to 7) should be taken into consideration when interpreting the results of this study. Moreover, our findings should not be generalized because only male runners were included. Previous authors<sup>23</sup> reported that tendon structures differed between men and women.

This study had several limitations: the small number of participants and its observational nature, which allowed runners to perform activities in the week after the marathon. Additionally, the results should be interpreted with caution due to the variability of the participant characteristics, including age, running experience, and training volume. The tendon reaction might be driven by a complex interaction of those factors. Hence, the late reaction of the tendon to the load might have been caused not only by load accumulation but also by individual characteristics. Another limitation was that we used absolute values to differentiate tendon portions in order to facilitate comparisons with previous research. Thus, without taking into account the participants' heights (and, consequently, different tendon lengths) during the analysis, we may have erred in differentiating between the insertions and midportions of the tendons.

## CONCLUSIONS

The structure of the Achilles tendon in recreational runners did not change 2 days after a marathon. However, by 7 days postmarathon, during which time additional running activities were performed, we identified changes at the insertion and midportion of the tendon, indicating an increase in the percentage of aligned tissue (especially echo type II) and decreases in the percentages of disorganized tissue (echo types III and IV). However, the changes in echo types III and IV were small (below the minimal detectable changes reported in a previous study<sup>30</sup>). The increase in the percentage of echo type II and decrease in the percentage of echo type I might represent the reactive stage of the continuum model. Our results provided new insights for clinicians, coaches, and athletes about the effect of load on Achilles tendon structure in terms of accumulation of load. Tendon structure seems to be influenced by the combination of running a marathon and the activities pursued shortly thereafter. This finding emphasizes the importance of an appropriate recovery period to prevent overuse injuries such as tendinopathy. Future investigators should evaluate the influences of different postmarathon activities and recovery periods on the tendon structure after running a marathon.

## ACKNOWLEDGMENTS

This work was supported by the National Council for Scientific and Technological Development – Brazil.

## REFERENCES

1. Road Running Information Center annual marathon report. Running USA Web site. <http://www.runningusa.org/node/16414>. Accessed March 5, 2018.
2. Fredericson M, Misra AK. Epidemiology and aetiology of marathon running injuries. *Sport Med.* 2007;37(4–5):437–439.
3. Dohrn IM, Kwak L, Oja P, Sjostrom M, Hagstromer M. Replacing sedentary time with physical activity: a 15-year follow-up of mortality in a national cohort. *Clin Epidemiol.* 2018;10:179–186.
4. Williams PT. Lower prevalence of hypertension, hypercholesterolemia, and diabetes in marathoners. *Med Sci Sports Exerc.* 2009;41(3):523–529.
5. Van Gent RN, Siem D, Van Middeloop M, Van Os AG, Bierma-Zeinstra SMA, Koes BW. Incidence and determinants of lower extremity running injuries in long distance runners: a systematic review. *Br J Sports Med.* 2007;41(8):469–480.
6. Lopes AD, Hespagnol LC, Yeung SS, Pena Costa LO. What are the main running related musculoskeletal injuries? A systematic review. *Sports Med.* 2012;42(10):892–905.
7. Scott SH, Winter DA. Internal forces of chronic running injury sites. *Med Sci Sports Exerc.* 1990;22(3):357–369.
8. Lichtwark GA, Bougoulas K, Wilson AM. Muscle fascicle and series elastic element length changes along the length of the human gastrocnemius during walking and running. *J Biomech.* 2007;40(1):157–164.
9. Farris DJ, Trewartha G, McGuigan MP. The effects of a 30-min run on the mechanics of the human Achilles tendon. *Eur J Appl Physiol.* 2012;112(2):653–660.
10. Heyward OW, Rabello LM, van der Woude L, et al. The effect of load on Achilles tendon structure in novice runners. *J Sci Med Sport.* 2018;21(7):661–665.
11. Peltonen J, Cronin NJ, Stenroth L, Finni T, Avela J. Achilles tendon stiffness is unchanged one hour after a marathon. *J Exp Biol.* 2012;215(pt 20):3665–3671.
12. Ooi CC, Schneider ME, Malliaras P, Counsel P, Connell DA. Prevalence of morphological and mechanical stiffness alterations of mid Achilles tendons in asymptomatic marathon runners before and after a competition. *Skeletal Radiol.* 2015;44(8):1119–1127.
13. van Schie HT, Bakker EM, Jonker AM van WP. Computerized ultrasonographic tissue characterization of equine superficial digital flexor tendons by means of stability quantification of echo patterns in contiguous transverse ultrasonographic images. *Am J Vet Res.* 2003;64(3):366–375.
14. Esmacili A, Stewart AM, Hopkins WG, Elias GP, Aughey RJ. Effects of training load and leg dominance on Achilles and patellar tendon structure. *Int J Sports Physiol Perform.* 2017;12(suppl 2):S122–S126.
15. Docking SI, Rosengarten SD, Cook J. Achilles tendon structure improves on UTC imaging over a 5-month pre-season in elite Australian football players. *Scand J Med Sci Sports.* 2016;26(5):557–563.
16. Rosengarten SD, Cook JL, Bryant AL, Cordy JT, Daffy J, Docking SI. Australian football players' Achilles tendons respond to game loads within 2 days: an ultrasound tissue characterisation (UTC) study. *Br J Sports Med.* 2015;49(3):183–187.
17. Wong AMY, Docking SI, Cook JL, Gaida JE. Does type 1 diabetes mellitus affect Achilles tendon response to a 10 km run? A case control study. *BMC Musculoskelet Disord.* 2015;16:345.
18. de Jonge S, van den Berg C, de Vos RJ, et al. Incidence of midportion Achilles tendinopathy in the general population. *Br J Sports Med.* 2011;45(13):1026–1028.
19. Cook JL, Purdam CR. Is tendon pathology a continuum? A pathology model to explain the clinical presentation of load-induced tendinopathy. *Br J Sports Med.* 2009;43(6):409–416.
20. Magnusson SP, Langberg H, Kjaer M. The pathogenesis of tendinopathy: balancing the response to loading. *Nat Rev Rheumatol.* 2010;6(5):262–268.
21. van Schie HTM, de Vos RJ, de Jonge S, et al. Ultrasonographic tissue characterisation of human Achilles tendons: quantification of tendon structure through a novel non-invasive approach. *Br J Sports Med.* 2010;44(16):1153–1159.
22. de Vos RJ, Weir A, Tol JL, Verhaar JAN, Weinans H, van Schie HTM. No effects of PRP on ultrasonographic tendon structure and neovascularisation in chronic midportion Achilles tendinopathy. *Br J Sports Med.* 2011;45(5):387–392.
23. Wezenbeek E, Mahieu N, Willems TM, et al. What does normal tendon structure look like? New insights into tissue characterization in the Achilles tendon. *Scand J Med Sci Sports.* 2017;27(7):746–753.
24. Waugh CM, Alktebi T, de Sa A, Scott A. Impact of rest duration on Achilles tendon structure and function following isometric training. *Scand J Med Sci Sports.* 2018;28(2):436–445.
25. De Sá A, Hart DA, Khan K, Scott A. Achilles tendon structure is negatively correlated with body mass index, but not influenced by statin use: a cross-sectional study using ultrasound tissue characterization. *PLoS One.* 2018;13(6):e0199645.
26. Graham JW. Missing data analysis: making it work in the real world. *Annu Rev Psychol.* 2009;60:549–576.
27. Rosengarten SD, Cook JL, Bryant AL, Cordy JT, Daffy J, Docking SI. Australian football players' Achilles tendons respond to game loads within 2 days: an ultrasound tissue characterisation (UTC) study. *Br J Sports Med.* 2015;49(3):183–187.
28. Heinemeier KM, Kjaer M. In vivo investigation of tendon responses to mechanical loading. *J Musculoskelet Neuronal Interact.* 2011;11(2):115–123.
29. Kjær M, Magnusson P, Krogsgaard M, et al. Extracellular matrix adaptation of tendon and skeletal muscle to exercise. *J Anat.* 2006;208(4):445–450.
30. Rabello LM, van den Akker-Scheek I, Kuipers IF, Diercks RL, Brink MS, Zwerver J. Bilateral changes in tendon structure of patients diagnosed with unilateral insertional or midportion Achilles tendinopathy or patellar tendinopathy [published online ahead of print April 1, 2019]. *Knee Surg Sport Traumatol Arthrosc.* doi:10.1007/s00167-019-05495-2.

Address correspondence to Lucas Maciel Rabello, PhD, University Medical Center Groningen, PO Box 30.001, 9700 RB Groningen, The Netherlands. Address e-mail to [rabello.lm@gmail.com](mailto:rabello.lm@gmail.com).