

## Brain Cancer

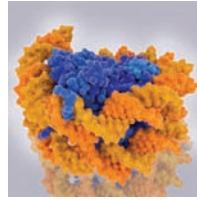
**Major Finding:** Posterior fossa A (PFA) ependymomas required a hypoxic environment to maintain their epigenomes.

**Concept:** PFA ependymoma epigenomes exhibited global histone 3 lysine 27 hypomethylation and hyperacetylation.

**Impact:** This work shows the link between hypoxia-driven aberrant metabolism and the epigenome in this cancer.

### HYPOXIA-INDUCED EPIGENETIC DYSREGULATION PROMOTES INFANTILE EPENDYMOMA

Posterior fossa A (PFA) ependymomas are the second most common hindbrain malignancies found in infants and toddlers, arising from a cell lineage present only during the first trimester. PFA ependymomas lack recurrent somatic mutations but have epigenetic dysregulation, and they develop in a low-oxygen environment and exhibit elevated hypoxic signaling, leading Michealraj, Kumar, Kim, and colleagues to investigate the link between hypoxia and the epigenome in this cancer. *In vitro* experiments using patient-derived PFA ependymoma cells showed that these cells strictly depended on hypoxic conditions for survival. Metabolic regulation was different in PFA ependymoma cells compared with other ependymomas or normal brain tissue—for example, glycolysis, nonoxidative pentose phosphate and polyamine metabolism were enriched in PFA ependymomas. PFA ependymomas also exhibited altered histone 3 lysine residue 27 methylation and acetylation (H3K27me and H3K27ac, respectively), with global reductions in H3K27me2 and H3K27me3 and increased H3K27ac. *In vitro* experiments showed that hypoxia was required to maintain this histone-modification profile and demonstrated that PFA ependymomas required high glucose levels, especially when exposed to higher oxygen levels. Mechanistically, hypoxia increased expression of genes encoding PRC2 inhibitors and reduced levels of S-adenosyl-L-methionine, a substrate for the histone methyltransferase and



PRC2 component EZH2, maintaining low H3K27me3 levels. Further contributing to global hypomethylation, hypoxia-induced glutaminolysis elevated the production of  $\alpha$ -ketoglutarate, increasing the activity of the H3K27 demethylases KDM6A/B. Concurrently, hypoxia-driven glutaminolysis followed by reductive carboxylation generated acetyl-Coenzyme A, increasing H3K27ac (and thus blocking EZH2-mediated methylation). Seemingly paradoxically, a CRISPR-Cas9-based knockout screen revealed that the genes encoding EZH2 and two other core components of PRC2 (EED and SUZ12) were most essential in PFA ependymomas, and deeper investigation supported a “Goldilocks” model in which PFA ependymomas are especially sensitive to perturbations to their low H3K27 methylation and high H3K27 acetylation levels. An analysis of normal murine fetal hindbrain cells showed that the characteristic metabolic phenotype observed in PFA ependymomas was similar to that of cells of the gliogenic lineage in the developing hindbrain. In summary, this work elucidates the molecular connection between hypoxic metabolism and epigenetic dysregulation in PFA ependymoma. ■

Michealraj KA, Kumar SA, Kim LJY, Cavalli FMG, Przelicki D, Wojcik JB, et al. *Metabolic regulation of the epigenome drives lethal infantile ependymoma*. *Cell* 2020;181:1329–45.e24.

## Clinical Trials

**Major Finding:** Patients with relapsed or refractory diffuse large B-cell lymphoma responded to a novel combination.

**Concept:** In a phase II trial, the CD19 antibody tafasitamab plus lenalidomide chemotherapy produced responses.

**Impact:** This combination may provide a new option for patients ineligible for stem-cell transplantation.

### DIFFUSE LARGE B-CELL LYMPHOMA RESPONDS TO TAFASITAMAB PLUS LENALIDOMIDE

Preclinical and early clinical data have shown that the Fc-enhanced, humanized, CD19-directed monoclonal antibody tafasitamab and the multimodal chemotherapeutic agent lenalidomide may each have single-agent activity against diffuse large B-cell lymphoma (DLBCL), and some work has suggested that the two treatments may exhibit synergistic effects. Salles, Duell, and colleagues conducted an open-label, single-arm, phase II clinical trial of tafasitamab plus lenalidomide in patients with relapsed or refractory DLBCL who were ineligible for high-dose chemotherapy with autologous stem-cell transplantation due to factors such as advanced age, chemorefractory disease, refusal, or comorbidities. These patients, all of whom had previously been treated with anti-CD20 therapy and anthracycline therapy and had a median age of 72 years, had poor prognoses, but the combination of tafasitamab plus lenalidomide showed promise. Of the 80 patients who received the dual therapy, 43% experienced complete responses and 18% exhibited partial responses, and the median duration of these responses was 21.7 months. The median follow-up period was 19.6 months, and over that time span the median overall survival

had not been reached; in fact, 38% of patients remained in remission at the time of data cutoff. With regard to safety and tolerability, all patients experienced treatment-emergent adverse events, with the most common adverse event being neutropenia. Nonhematologic adverse events were most often grade 1 or 2 and included diarrhea and rash. Notably, 12% of patients discontinued study treatment because of adverse events, and four patients died of treatment-emergent adverse events, although none of these deaths were deemed by the investigators to be due to the study treatment. In summary, the results of this trial demonstrate that treatment with tafasitamab plus lenalidomide is generally safe and exhibits encouraging signs of activity in patients with relapsed or refractory DLBCL who have few treatment options, suggesting that the combination therapy is worth investigating further in larger trials. ■

Salles G, Duell J, González Barca E, Tournilhac O, Jurczak W, Liberati AM, et al. *Tafasitamab plus lenalidomide in relapsed or refractory diffuse large B-cell lymphoma (L-MIND): a multicentre, prospective, single-arm, phase 2 study*. *Lancet Oncol* 2020;21:978–88.