

CONCISE REPORT

Progressive Preleukemia With a Chromosomally Abnormal Clone in a Kindred With the Estren-Dameshek Variant of Fanconi's Anemia

By P. Nowell, G. Bergman, E. Besa, D. Wilmoth, and B. Emanuel

One of two sisters with hypoplastic anemia and increased chromosomal fragility, but no clinical stigmata of Fanconi's anemia (FA), progressed to preleukemia (with a clone of chromosomally abnormal cells in the bone marrow), and then to acute nonlymphocytic leukemia. The findings indi-

cate that constitutional genetic instability can lead to karyotypically aberrant neoplastic clones in the Estren-Dameshek variant of FA as well as in the more typical chromosomal fragility syndromes.

IN PATIENTS with Fanconi's anemia (FA), ataxia telangiectasia (AT), and Bloom's syndrome (BS),¹⁻⁶ an association has been recognized for some time between constitutional chromosomal fragility, the development of karyotypically abnormal hemic cell clones, and ultimate progression to preleukemia and leukemia. Although other factors may contribute, it seems clear that the constitutional defects in DNA "housekeeping" in these individuals lead to chromosomal breakage and rearrangements, with such changes occasionally providing sufficient selective growth advantage to a cell and its progeny to permit expansion of a neoplastic clone.⁴

In addition to these well-documented chromosomal fragility syndromes, there are scattered reports of other individuals and families in which various combinations of chromosomal breakage, cytogenetically aberrant clones, and hematopoietic dysfunction (aplastic anemia or leukemia) have occurred. A number of these have involved patterns of familial leukemia, often preceded by aplastic anemia, with karyotypically abnormal clones in the bone marrow but no demonstrable evidence of increased chromosomal breakage by ordinary techniques.⁷⁻⁹ Another group of such patients are those with familial refractory anemia or leukemia as well as increased chromosomal breakage but without the phenotypic characteristics of classic FA or any evidence of the development of chromosomally altered clones.¹⁰⁻¹² Many of these latter cases appear to fall within the spectrum of the variant of Fanconi's anemia, originally described by Estren and Dameshek,¹³ characterized by familial hypoplastic anemia of childhood and increased chromosomal fragility, but without the congenital malformations of typical FA.

We have recently studied a family in which two young sisters developed hypoplastic anemia and also demonstrated increased chromosomal fragility in lymphocyte cultures. One sister had a cytogenetically aberrant clone in her bone marrow and has progressed from a dysmyelopoietic preleukemia to acute nonlymphocytic leukemia. The classic stigmata of Fanconi's anemia were absent, and so these observations appear

to extend to the Estren-Dameshek variant of FA the tripartite association of chromosomal fragility, karyotypically altered hemic clones, and progression to leukemia.

CASE REPORTS

B.M. was first examined at the age of 13 years in February 1980, because of her sister's hematologic problems (see below). She was one of five siblings (Fig 1). Hematologic studies demonstrated a hemoglobin level of 12 g/dL; a WBC of 4,000/ μ L with 36% polys; a platelet count of 135,000/ μ L; a reticulocyte count of 4.3%; a ferritin level of 280 ng/mL (normal, 20 to 300 ng/mL); a fetal hemoglobin level of 6.5%; and an MCV of 101 dL. These findings suggested a dyserythropoietic state. In September 1982 she fainted once, and her hematologic values had changed: hemoglobin, 10.1 g/dL, reticulocyte count, 6%, 4 NRBCs; WBC, 2,400/ μ L with 2% polys, 23% abnormal, single-lobed polymorphonuclear leukocytes (polys) (acquired Pelger-Huet anomaly); and platelets, 76,000/ μ L. An ¹¹¹InCl marrow scan in October 1982 revealed diminished to absent activity in the extremities but normal activity in the axial skeleton. Marrow aspirate from the iliac crest in October 1982 revealed erythroid hyperplasia, a maturation arrest in the myeloid series, and diminished iron stores. The peripheral blood had a few myeloblasts (2% to 4%), but the patient was only observed and not treated because she was asymptomatic. Her counts remained stable over the following twelve months without specific therapy, during which time she developed two deep-seated abscesses necessitating surgical drainage and prolonged intravenous antibiotic treatment.

In December 1983 there was evidence of progression of her hematologic abnormalities, with 10% to 25% myeloblasts in the peripheral blood, and an unsuccessful trial of treatment with 13-*cis*-retinoic acid was begun. Her leukemia has subsequently progressed.

The patient had normal physical findings without stigmata of Fanconi's anemia. Chromosome studies on her blood and bone

From the Departments of Pathology and Pediatrics, School of Medicine, University of Pennsylvania, Philadelphia, and the Departments of Pediatrics and Medicine, Medical College of Pennsylvania, Philadelphia.

Supported in part by National Institutes of Health grant No. CA 12779.

Submitted May 7, 1984; accepted June 30, 1984.

Address reprint requests to Dr P. C. Nowell, Pathology Department, School of Medicine/G3, University of Pennsylvania, Philadelphia, PA 19104.

© 1984 by Grune & Stratton, Inc.

0006-4971/84/6405-0030\$03.00/0

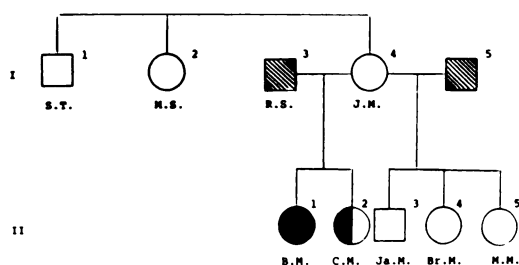


Fig 1. Partial pedigree of a kindred with the Estren-Dameshek variant of Fanconi's anemia. ●, Anemia and increased chromosomal fragility (female); ◐, leukemia and chromosomally abnormal clone; ▨, no chromosome data (male).

marrow were done in October 1982 and repeated on her peripheral blood in January and March 1984.

C.M. was first seen in August 1979 at the age of 9 years because of mycoplasma pneumonia and pancytopenia. Hematologic studies revealed a hemoglobin level of 4.5 g/dL, a WBC of 2,500/ μ L with 22% polys and 25% bands, and a platelet count of 117,000/ μ L. An anti-I antibody and spherocytes were present, and one unit of packed red cells was given. Follow-up after her pneumonia resolved revealed further lowering of her counts. Bone marrow examination showed decreased but normal-appearing marrow elements. An $^{111}\text{InCl}$ marrow scan showed minimal uptake, present only in the areas of the sacroiliac joints. A second transfusion of packed red cells was given in January 1981 and a third in May 1982. A repeat marrow scan in October 1982 showed essentially no erythroid activity. As of April 1984, she was receiving 100 mg oxymetholone and 10 mg prednisone daily, had no symptoms, and did not require further transfusions. She has no phenotypic dysmorphism or clinical stigmata of Fanconi's anemia. Chromosome studies on her peripheral blood were done in October 1982 and April 1983.

Three other siblings (Ja.M., age 23 years; Br.M., age 18 years; M.M., age 11 years) also had chromosome studies done on their peripheral blood in December 1982, as did their mother (J.M.) and two of her siblings (S.T. and M.S.). A pedigree of the family members studied is given in Fig 1.

As indicated in Fig 1, the two sisters with anemia (B.M., C.M.) had a different father (R.S.) than the other three siblings. R.S. died in 1982, aged 57 years, of subacute bacterial endocarditis. His twin brother is alive and well, as are four additional children of R.S. by another wife, all in their twenties. No other family history of anemia or leukemia could be elicited.

CYTOGENETIC METHODS

Standard methods were used to culture the peripheral blood from the eight individuals studied,¹⁴ with the cultures terminated at 48 to 54 hours for determination of chromosome breakage. At least 100 cells from each individual were examined for breaks and gaps, and these enumerated according to standard nomenclature (Table 1).

Additional chromosome fragility studies were done on patients B.M. and C.M. and their mother (J.M.). Chromosome breakage was determined in the presence of bleomycin,³ to investigate the effect of a clastogenic agent, and sister chromatid exchange (SCE) was also determined,¹⁵ with and without the presence of mitomycin-C.

The bone marrow study on patient B.M. was done with both direct preparations and 24-hour cultures. A total of 50 metaphase spreads were counted and three were karyotypically analyzed to characterize the abnormal clone in the bone marrow.

RESULTS

Chromosome breakage data on peripheral blood lymphocytes from the eight individuals studied are summarized in Table 1. Both breaks and gaps are enumerated, but the percentage of abnormal cells is based on breaks only, with chromatid gaps omitted. It is clear from the table that patients B.M. and C.M. had significantly increased levels of chromosome breakage (as well as gaps). There were no rings or dicentrics, but two chromatid exchange figures were noted in 158 metaphases examined from patient C.M.

The other six individuals studied showed no increase in chromosomal fragility, with the levels of breaks and gaps in the same range as three young adult control individuals studied concurrently (Table 1).

The special studies of the effect of bleomycin and of sister chromatid exchange (SCE) done on the lymphocytes of both patients and their mother (J.M.), did not provide additional significant information. The mother's cells did not show increased chromosomal fragility when stressed with bleomycin, and the SCE levels of all three individuals were in the expected range, both with and without the addition of mitomycin-C to the cultures.

Table 1. Chromosome Aberrations in a Kindred With the Estren-Dameshek Variant of Fanconi's Anemia

Patient	Total Metaphases	Metaphases With Aberrations (%)*	Chromosome Breaks	Chromatid Breaks	Total No. of Aberrations*	Chromatid Gaps
B.M. (II-1)	100	13 (13)	11	6	17	21
C.M. (II-2)	158	31 (20)	12	22	36†	10
J.M. (I-4)	100	0	0	0	0	5
Ja.M. (II-3)	100	1 (1)	1	0	1	2
Br.M. (II-4)	170	3 (2)	2	1	3	3
M.M. (II-5)	100	2 (2)	2	0	3	2
S.T. (I-1)	100	0	0	0	0	7
M.S. (I-2)	100	1 (1)	1	0	1	3
Control 1	100	2 (2)	0	2	2	1
Control 2	100	0	0	0	0	4
Control 3	100	2 (2)	1	1	2	3

*Chromatid gaps not included.

†Includes two chromatid exchange figures.




Fig 2. Representative Giemsa-banded karyotype from the bone marrow of patient B.M. (II-1) during the preleukemic phase of her disease, characterized as 46,XX,-17,t(10;7)(q26;?), del(12)(p11),+der(17).t(1;17)(q21;p13) All of the metaphases had the 10q+ and the 17p+ markers, and a minority also had the 12p- chromosome.

Among the dividing lymphocytes in the peripheral blood cultures of patients B.M. and C.M., there was no evidence of a chromosomally abnormal clone. In the bone marrow of patient B.M., however, all of the dividing cells constituted a pseudodiploid clone (Fig 2) with an abnormal chromosome 10 (10q+) and an abnormal chromosome 17 (17p+). The latter resulted from translocation of an extra copy of most of the long arm of chromosome 1. A proportion of the cells also had a deletion of the short arm of chromosome 12 (12p-).

DISCUSSION

The findings in this family are consistent with the Estren-Dameshek variant of Fanconi's anemia. Two sisters, without the stigmata of FA, developed anemia in late childhood, with one progressing clinically to preleukemia and then to acute nonlymphocytic leukemia. There was increased chromosome breakage in their lymphocyte cultures, as is seen in both typical and variant Fanconi's anemia.^{1,16,17} Although the family history is limited, the mother's lack of a hematologic abnormality or increased chromosomal fragility would be consistent with heterozygosity for an autosomal recessive gene, with the father of the two sisters presumably being similarly heterozygous. The lack of clinical and chromosomal abnormalities in the three other siblings studied (who had a different father), and in two siblings of the mother, is in agreement with this conclusion, as is the fact that the father's four other children by a different wife have reached the third decade of life without evidence of hematologic disease.

The present finding of a chromosomally abnormal marrow clone in one of the two affected girls appar-

ently represents the first instance in which the full triad of chromosomal fragility, karyotypically altered clone, and progression to leukemia has been described in the Estren-Dameshek variant of FA.¹⁰⁻¹² As noted above, such a combination has been reported in the more common fragility syndromes, including typical FA, and in some instances involving nonrandom chromosomal changes (such as monosomy 7) that are frequent in childhood leukemia.⁷⁻⁹ The particular cytogenetic alterations in our patient are not ones that have been related to specific hematopoietic disorders, although trisomy for 1q is common in many neoplasms, and the 12p- alteration seen in a proportion of her cells does appear to occur nonrandomly in various preleukemic and leukemic states.¹⁸

Our results reinforce the need for additional investigation, not only of the nature of the DNA defects in individuals with constitutional chromosomal instability, but also of the mode of inheritance of such disorders when they do not fall within the spectrum of the common fragility syndromes such as FA, AT, and BS. In some instances, familial patterns of hypoplastic anemia, progressing to leukemia, often with chromosomally abnormal clones, are being recognized in which it has not yet been possible to document defects in DNA "housekeeping," although they have been suspected.^{3,4} With the utilization of such clastogenic agents as bleomycin and mitomycin, as in this study, it may be possible to demonstrate genetic instability in some of these families as well.³

Such attempts to evaluate accurately the role of inherited defects in DNA synthesis or repair in the increased susceptibility of certain individuals and families to environmental insults seem worthwhile, because, as suggested by the present study, a relationship among such inherited defects, the development of somatic cell clones, and ultimately neoplasia, particularly in the hematopoietic system, may be more common in the population than currently is suspected.

ACKNOWLEDGMENT

The authors wish to thank J. Finan and J. Moore for expert assistance, and Louis Delpino for manuscript preparation and graphic artwork.

REFERENCES

1. Ray JH, German J: The chromosome changes in Bloom's syndrome, ataxia-telangiectasia, and Fanconi's anemia, in Arrighi FE, Rao PN, Stubblefield E (eds): *Genes, Chromosomes, and Neoplasia*. New York, Raven Press, 1981, pp 351-377
2. Auerbach AD, Weiner MA, Warburton D, Yeboa K, Lu L, Broxmeyer HE: Acute myeloid leukemia as the first hematologic manifestation of Fanconi anemia. *Am J Hematol* 12:289, 1982
3. Hsu TC: Genetic instability in the human population: A working hypothesis. *Hereditas* 98:1, 1983
4. Nowell P: Tumor progression and clonal evolution: The role of

genetic instability, in German J (ed): *Chromosome Mutation and Neoplasia*. New York, Alan R. Liss, 1983, pp 413–432

5. Hecht F, Kaiser-McCaw B: The interrelationships in ataxia-telangiectasia of immune deficiency, chromosome instability, and cancer, in German J (ed): *Chromosome Mutation and Neoplasia*. New York, Alan R. Liss, 1983, pp 193–202

6. Stivrins TJ, Davis RB, Sanger W, Fritz J, Purtilo DT: Transformation of Fanconi's anemia to acute non-lymphocytic leukemia associated with emergence of monosomy 7. *Blood* 64:173, 1984

7. Li FP, Potter NU, Buchanan GR, Vawter G, Whang-Peng J, Rosen RB: A family with acute leukemia, hypoplastic anemia, and cerebellar ataxia. *Am J Med* 65:933, 1978

8. Nowell P: Cytogenetics of preleukemia. *Cancer Genet Cytogenet* 5:265, 1982

9. Chitambar CR, Robinson WA, Glode L: Familial leukemia and aplastic anemia associated with monosomy 7. *Am J Med* 75:756, 1983

10. Hirschman RJ, Shulman NR, Abuelo JG, Whang-Peng J: Chromosome aberrations in two cases of inherited aplastic anemia with unusual clinical features. *Ann Intern Med* 71:109, 1969

11. Schmid W, Fanconi G: Fragility and spiralization anomalies of the chromosomes in three cases, including fraternal twins, with

Fanconi's anemia, type Estren-Dameshek. *Cytogenet Cell Genet* 20:141, 1978

12. Dosik H, Steir W, Lubiniecki A: Inherited aplastic anaemia with increased endoreduplications: A new syndrome or Fanconi's anaemia variant? *Br J Haematol* 41:83, 1979

13. Estren S, Dameshek W: Familial hypoplastic anemia of childhood. *Am J Dis Child* 73:671, 1947

14. Moorhead P, Nowell P, Mellman W, Battips D, Hungerford D: Chromosome preparations of leukocytes cultured from human peripheral blood. *Exp Cell Res* 20:613, 1960

15. Latt SA: Sister chromatid exchange formation. *Ann Rev Genet* 15:11, 1981

16. Cervenka J, Hirsch BA: Cytogenetic differentiation of Fanconi anemia, "idiopathic" aplastic anemia, and Fanconi anemia heterozygotes. *Am J Med Genet* 15:211, 1983

17. Dallapiccola B, Alimena G, Brinchi V, Isacchi G, Gandini E: Absence of chromosomal heterogeneity between classical Fanconi's anemia and the Estren-Dameshek type. *Cancer Genet Cytogenet* 2:349, 1980

18. Wilmoth D, Feder M, Finan J, Nowell PC: Preleukemia and leukemia with 12p- and 19q+ chromosome alterations following Alkeran therapy. *Cancer Genet Cytogenet* (in press)