

Lack of Apoptotic Protease Activating Factor-1 Expression and Resistance to Hypoxia-Induced Apoptosis in Cervical Cancer

Cornelia Leo,¹ Lars-Christian Horn,² Cora Rauscher,¹ Bettina Hentschel,³ Christine E. Richter,¹ Alexander Schütz,² Chandra Paul Leo,¹ and Michael Höckel¹

Abstract Purpose: Clinical observations suggest that intratumoral hypoxia increases the aggressiveness of tumors through clonal selection of cancer cells that have lost their apoptotic potential. The aim of this study, therefore, was to investigate the expression of the proapoptotic protein apoptotic protease activating factor-1 (Apaf-1) in cervical cancers and to analyze its relation to intratumoral hypoxia and apoptosis. Furthermore, the effect of hypoxia and apoptosis on survival was examined.

Experimental Design: In 56 patients, intratumoral oxygenation measurements and subsequent needle biopsies were done. The obtained tissue was analyzed by terminal deoxynucleotidyl transferase – mediated dUTP nick end labeling assays and by immunohistochemistry with an Apaf-1 antibody.

Results: Apaf-1 was expressed in 86% of cancers. The median apoptosis rate was 1.0%. There was no correlation between Apaf-1 expression and intratumoral hypoxia. However, Apaf-1 expression was negative in 37.5% of hypoxic cervical cancers ($pO_2 \leq 10$ mmHg) with low apoptosis rates ($\leq 1.0\%$) compared with only 5.0% in nonhypoxic cancers and hypoxic cancers with high apoptosis ($P = 0.005$; Fisher's exact test). With a median follow-up period of 44 months, there was a nonsignificant trend toward worse prognosis in the hypoxic low-apoptotic group ($P = 0.08$).

Conclusions: Although Apaf-1 is expressed in the vast majority of cervical cancers, a significant proportion of tumors with low apoptosis rates despite intratumoral hypoxia showed a lack of Apaf-1 expression. This finding suggests that loss of Apaf-1 expression is a mechanism by which hypoxic cervical cancers acquire resistance to apoptosis. Thus, low Apaf-1 expression in hypoxic tumors may be an unfavorable prognostic factor.

Hypoxia is a driving force in the malignant progression of solid tumors. Hypoxic microregions have been detected in a wide variety of solid tumors, including cervical cancer, head and neck cancer, as well as soft tissue sarcomas (1–3). In previous clinical studies, our group showed that patients with hypoxic cervical cancers had a significantly worse prognosis compared with patients with better oxygenated tumors regardless of treatment modality (2). Mechanisms by which sustained tumor hypoxia may increase aggressiveness include differential regulation of gene expression (4) and clonal selection of tumor cells that have lost their apoptotic potential (5, 6).

Physiologically, hypoxia serves as a stimulus for apoptosis (7, 8). However, in a previous study, we showed the occurrence of hypoxic cervical cancers with a low fraction of apoptotic cells and showed that these tumors were highly aggressive compared with hypoxic tumors with high apoptosis rates and nonhypoxic tumors (9). The mechanisms by which hypoxia gives rise to this apoptosis resistance have only partially been elucidated. Graeber et al. (5) showed in a mouse model that hypoxic conditions select for apoptosis-resistant p53^{-/-} mouse embryonic fibroblasts. One critical regulator of apoptosis under hypoxia is the apoptotic protease activating factor-1 (Apaf-1). Apaf-1 is a crucial part of the apoptosome that is assembled in response to several cellular stresses (e.g., hypoxia, DNA damage, oncogene, activation, etc.). Activation by these signals finally leads to caspase activation via the intrinsic mitochondrial pathway resulting in apoptotic cell death (10–12). Apaf-1 knockout mice showed severe defects in the apoptotic response to hypoxic stimulation (13). This finding shows that Apaf-1 is an essential component of the apoptotic response to hypoxia *in vitro*. Recently, we have shown that Apaf-1 is expressed in cervical cancer and that an absent or weak Apaf-1 expression correlates significantly with the presence of lymph node metastasis at time of surgery (14). Furthermore, Apaf-1 deficiency was shown in several malignancies, including pancreatic cancer (15), malignant melanoma (16), and

Authors' Affiliations: ¹Department of Gynecology, ²Division of Gynecologic Pathology, Department of Pathology, and ³Institute for Medical Informatics, Statistics and Epidemiology, Leipzig University, Leipzig, Germany
Received 9/26/06; revised 11/11/06; accepted 11/30/06.

Grant support: Deutsche Krebshilfe grant 106795 (M. Höckel and C. Leo).
The costs of publication of this article were defrayed in part by the payment of page charges. This article must therefore be hereby marked *advertisement* in accordance with 18 U.S.C. Section 1734 solely to indicate this fact.

Requests for reprints: Cornelia Leo, Department of Gynecology, Leipzig University, Philipp-Rosenthal-Strasse 55, 04103 Leipzig, Germany. Phone: 49-341-97-23400; Fax: 49-341-97-23409; E-mail: leo@medizin.uni-leipzig.de.

© 2007 American Association for Cancer Research.

doi:10.1158/1078-0432.CCR-06-2371

Table 1. Patient and tumor characteristics at the time of pretherapeutic pO₂ measurements

	No. patients	Apaf-1 negative/positive	TUNEL median (range)
FIGO stage			
I	13	2/11	1.0 (0.4-3.4)
II	18	5/13	1.1 (0.4-2.5)
III	19	0/19	1.0 (0.5-1.6)
IV	6	1/5	0.95 (0.3-1.4)
Grade			
1	8	1/7	1.05 (0.4-1.8)
2	34	6/28	1.0 (0.4-3.4)
3	14	1/13	1.0 (0.3-2.5)
pT stage			
pT _{1b1}	15	3/12	0.9 (0.4-3.4)
pT _{1b2}	2	0/2	1.65 (0.4-2.9)
pT _{2b}	5	2/3	1.0 (0.8-1.4)
pT ₄	1	0/1	0.3
NA	33		
pN stage			
N ₀	19	3/16	0.9 (0.3-3.4)
N ₁	4	2/2	1.0 (0.8-1.4)
NA	33		
LVSI			
L ₀	21	1/20	1.0 (0.4-3.4)
L ₁	35	7/28	1.0 (0.3-2.9)
Tumor oxygenation pO ₂ (mmHg)*		6.9 (0.8-33.3)	
≤10	33	7/26	1.1 (0.4-2.9)
>10	23	1/22	0.9 (0.3-3.4)
Tumor diameter (mm)*		45 (17-100)	
Patient age (y)*		47 (24-79)	
Treatment modality			
Radical hysterectomy with pelvic ± paraaortic lymph node dissection	22		
Primary exenteration	1		
Radiation therapy	33		

Abbreviations: pT stage, pathologic tumor stage; pN stage, pathologic nodal status; NA, not applicable (treated by radiation therapy); LVSI, lymphovascular space involvement.

*Median (range).

leukemia, in the last of which it was associated with poor survival (17). To our knowledge, this is the first study investigating the relationship between Apaf-1 expression, intratumoral pO₂ levels, and apoptosis rates in human malignant tumors. We show that a significant proportion of cervical cancers with low apoptosis rates despite intratumoral hypoxia showed a lack of Apaf-1 expression.

Materials, Patients, and Methods

Patients, pO₂ measurement, and tissue specimens

All patients were part of a prospective clinical study evaluating the significance of intratumoral hypoxia in cervical cancer that commenced in 2001 at the Department of Gynecology at Leipzig University (18). Intratumoral oxygenation measurement was done with the Eppendorf histography system (Eppendorf, Hamburg, and Germany) according to the standard procedure described earlier (19). The procedure was done after informed written consent was obtained from each patient. The study was approved by the medical ethics committee of Leipzig University. pO₂ measurement was done pretherapeutically in the conscious patient along at least two distinct tracks within the macroscopically vital tumor. Per track, ~30 data points were collected starting at a tissue depth of 5 mm. To confirm that the measurement was done within the tumor and not in necrotic or tumor-free areas, a needle core biopsy of ~2 mm in diameter and 20 mm in length was taken of each

measured track after the procedure. The biopsies were formalin fixed and paraffin embedded according to standard protocols followed by an evaluation by a gynecologic pathologist. Of the patients enrolled in the study between January 2001 and February 2003, sufficient material for analysis was available in 56 cases. The median pO₂ of each track was correlated to Apaf-1 expression as well as to the apoptosis rate in the corresponding biopsy (see below).

Immunohistochemical staining for Apaf-1

Immunohistochemical staining was done as described previously (14) using a polyclonal rabbit anti-Apaf-1 antibody (ProSci, Poway, CA) and the catalyzed signal amplification system from DAKO (Glostrup, Denmark). Negative controls were done by omitting the anti-Apaf-1 antibody in the primary antibody incubation.

Terminal deoxynucleotidyl transferase-mediated dUTP nick end labeling assays

Apoptotic cells were detected by terminal deoxynucleotidyl transferase-mediated dUTP nick end labeling (TUNEL). Slides were treated with the DeadEnd Colorimetric Apoptosis Detection System (Promega, Madison, WA) according to the instructions of the manufacturer. As a positive control, DNase-treated lymph node sections were used and for negative controls, the TdT enzyme was omitted.

Evaluation of immunostaining

Evaluation of Apaf-1 immunostaining. For the assessment of cytoplasmic staining results for Apaf-1, a predefined scoring system

based on the product of staining intensity and percentage of positive tumor cells was used (20). Staining intensity was evaluated as negative (0), weak (1), moderate (2), and strong (3) and the percentage of positive tumor cells was categorized as follows: 0, 0%; 1, 1% to 10%; 2, 11% to 50%; 3, 51% to 80%; and 4, >80%. By multiplying both components, an expression score (0-12) was obtained. A section was only counted as negative when an internal control (endothelial or peritumoral inflammatory cells) was positive for Apaf-1. Evaluation of the samples was done by two independent investigators (L.C.H. and A.S.) who were blinded to the patient data. In cases of discrepant assessment, an agreement was obtained after collegial revision using a multiheaded microscope. Cases with an expression score of 0 to 2 were considered negative, whereas all specimens with a score >2 were counted as positive.

Evaluation of TUNEL assays. To assess apoptosis, cells with clear brown nuclear labeling were counted as TUNEL positive. To determine the apoptosis rate of a tumor, the number of TUNEL-positive cells per 1,000 tumor cells was expressed in percent.

Statistical analysis

The Mann-Whitney *U* test and Fisher's exact test were used for comparisons between different groups. Correlations between two variables were described by Spearman's rank correlation coefficient (*r*). Overall survival (OS), with deaths due to any cause as event, and relapse-free survival (RFS), with relapse and metastases as events, were analyzed by log-rank test. Three-year survival rates are presented. *P* values <0.05 were considered to indicate statistical significance. A retrospective power analysis was calculated for the survival statistics. Statistical analysis was done using the statistics package SPSS (version 11.5 for Windows; SPSS GmbH, Munich, Germany), StatXact-5 (version 5.0.3), and NCSS Trial and PASS 2002.

Results

Patient characteristics and clinicopathologic features. All cervical carcinomas were clinically staged according to International Federation of Gynecologists and Obstetricians (FIGO) criteria. The median age at diagnosis was 47 years (range, 24-79 years). In 22 of the examined cases, the tumor was resected by total mesometrial resection along with pelvic/paraortic lymph

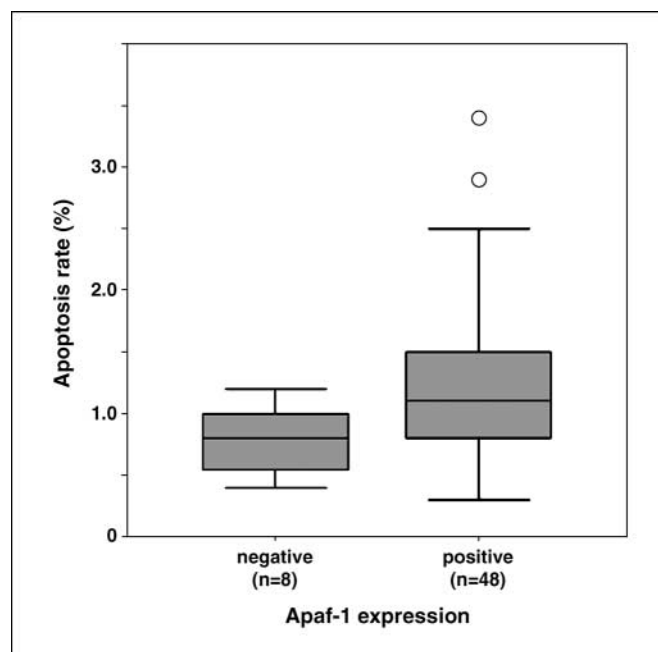


Fig. 2. Apaf-1-positive cervical cancers have significantly higher apoptosis rates ($P = 0.046$). Apaf-1 expression scores of 0 to 2 are considered negative, whereas Apaf-1 expression scores of 3 to 12 are counted as positive.

node dissection (21). In one case (FIGO IV), the tumor was treated with curative intent by laterally extended endopelvic exenteration (22). For the surgically treated patients, the tumors were additionally staged according to the pathological tumor-node-metastasis system. Thirty-three patients were treated by radiation therapy. The distribution of FIGO and tumor-node-metastasis stages is shown in Table 1. Forty-nine tumors were of squamous cell origin, six represented adenocarcinomas and one was an adenosquamous cell carcinoma.

Apaf-1 protein expression and apoptosis rates in cervical cancers. Immunohistochemistry for Apaf-1 was done in all 56 cervical cancer samples. Cytoplasmic Apaf-1 expression was found in 86% of the investigated cases. Positive tumor cells presented a diffuse, cytoplasmic staining (Fig. 1). There was a lower rate of Apaf-1 positivity among the FIGO I/II cases (24 of 31) compared with the FIGO III/IV cervical cancers (24 of 25). Thus, seven of the eight Apaf-1-negative cancers belonged to the FIGO stages I and II ($P = 0.063$; Table 1).

The median apoptosis rate was 1.0% (range, 0.3-3.4%) as determined by TUNEL assays (Table 1). Apaf-1-positive cancers exhibited significantly higher apoptosis rates compared with Apaf-1-negative cases ($P = 0.046$, Fig. 2). This effect was even more pronounced when only regarding the group of hypoxic cervical cancers ($P = 0.039$).

Apaf-1 expression, apoptosis, and intratumoral pO_2 . For the 56 tumors, the median oxygenation along the histologically confirmed single tracks was 6.9 mmHg (range, 0.8-33.3 mmHg). There was no correlation between Apaf-1 expression and intratumoral oxygenation ($r = 0.004$; $P = 0.975$) or between the apoptosis rates and intratumoral oxygenation ($r = -0.049$; $P = 0.722$). However, there was a group of 16 cervical cancers that exhibited low apoptosis rates despite being hypoxic (Fig. 3). To define hypoxia, the commonly used threshold of 10 mmHg was used (2) and low apoptosis was

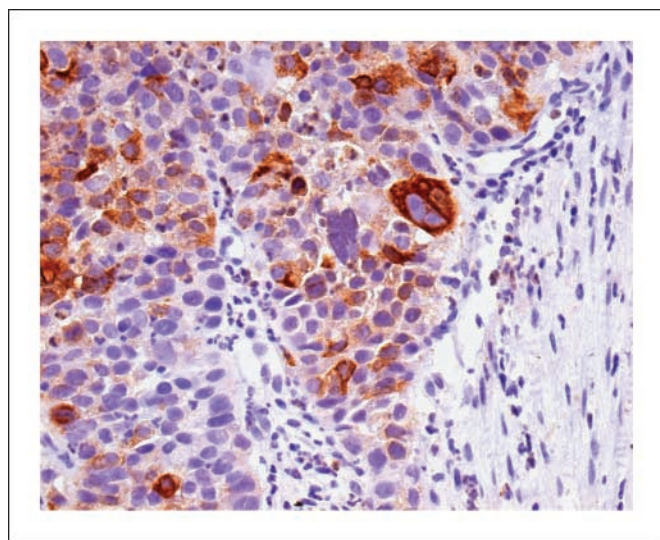


Fig. 1. Strong cytoplasmic Apaf-1 expression in a cervical cancer specimen. Magnification, $\times 214$.

defined as an apoptosis rate below or at the median of 1.0%. Six of the eight Apaf-1-negative cervical cancers belonged to that group. Thus, 37.5% (95% confidence interval, 15.2-64.6%) of the cervical cancers in the hypoxic low-apoptotic group were Apaf-1 negative compared with only 5.0% (95% confidence interval, 0.61-16.9%) in the group with hypoxic high-apoptotic or nonhypoxic cervical cancers ($P = 0.005$, Fisher's exact test; Fig. 3).

Hypoxia, apoptosis, and survival. The median follow-up period was 44 months. For one patient, no follow-up data were available for survival analysis. Furthermore, five patients (four with disease progression and one with unknown relapse status) were not included in the analysis for RFS. There were no significant differences in OS and RFS comparing patients having hypoxic high-apoptotic or nonhypoxic tumors with patients having hypoxic low-apoptotic tumors [OS (3-year rate), 74.4% versus 50.0%; $P = 0.08$; power of the analysis, 45%; RFS (3-year rate), 66.3% versus 50.0%; $P = 0.29$]. More specifically, the comparison in OS between patients having hypoxic high-apoptotic tumors with those having hypoxic low-

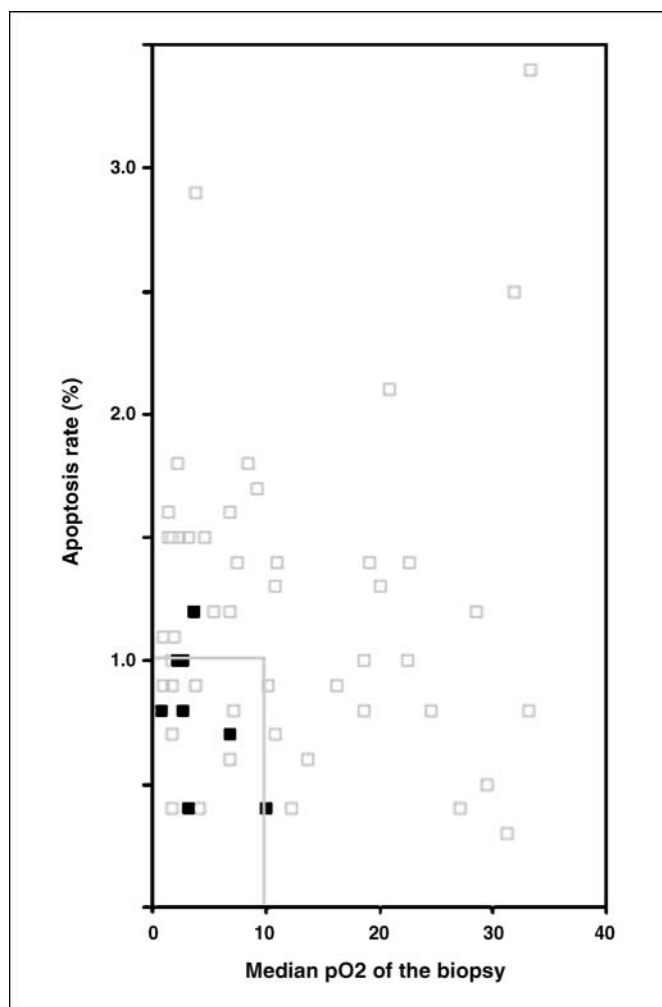


Fig. 3. Lack of correlation between the apoptosis rates (%) and the median pO_2 (mmHg) of the respective tumors. A group of 16 cervical cancers that despite hypoxia ($pO_2 \leq 10$ mmHg) exhibits low apoptosis rates ($\leq 1.0\%$). Six of the eight (75%) Apaf-1-negative cervical cancers are found in the group of hypoxic low-apoptotic tumors.

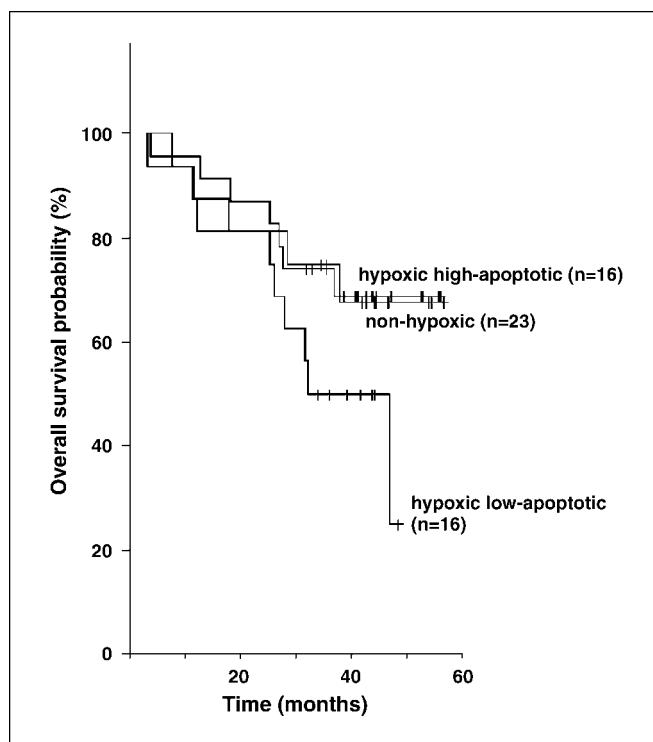


Fig. 4. Using Kaplan-Meier analysis and log-rank test, hypoxic low-apoptotic tumors showed no significant differences in OS to hypoxic high-apoptotic tumors ($P = 0.18$) or nonhypoxic tumors ($P = 0.12$), respectively.

apoptotic cancers showed a trend toward a worse prognosis for the latter group that did not reach statistical significance [OS (3-year rate), 75.0% versus 50.0%; $P = 0.18$; Fig. 4]. Similarly, patients with nonhypoxic tumors showed a nonsignificant trend toward a better prognosis when compared with patients having hypoxic low-apoptotic cervical cancers [OS (3-year rate), 73.9% versus 50.0%; $P = 0.12$].

There were no survival differences between Apaf-1-positive and Apaf-1-negative cervical cancers [OS (3-year rate), 65.9% versus 75.0%; $P = 0.55$; RFS (3-year rate), 64.5% versus 41.7%; $P = 0.52$].

Discussion

To our knowledge, this is the first study analyzing the relationship between Apaf-1 expression, intratumoral pO_2 levels, and apoptosis rates in cervical cancer.

Hypoxia is commonly regarded as a stimulus for apoptotic cell death (7). However, a subset of cervical cancers seems to be able to escape hypoxic induction of apoptosis. In a previous study, we found that hypoxic cervical cancers with low apoptosis rates were associated with a more aggressive phenotype resulting in poorer survival when compared with the remaining tumors (9). Likewise, in the present study, patients with hypoxic low-apoptotic tumors also had lower survival rates when compared with those with other tumors, although this trend did not reach statistical significance. As might be expected, Apaf-1-negative cervical cancers had significantly lower apoptosis rates compared with those with Apaf-1 expression. However, this effect did not translate into a survival disadvantage for patients with Apaf-1-negative

cancers, possibly because their tumors almost exclusively belonged to the earlier FIGO stages I and II.

The mechanisms underlying an acquired resistance to hypoxia-induced apoptosis have been addressed in *in vitro* studies and animal models (5, 6). In the present clinical study, we identified a group of 16 cervical cancers that exhibit low apoptosis rates despite intratumoral hypoxia. These 16 cervical cancers may be assumed to have grown resistant to hypoxia-induced apoptosis. One major regulator that plays a role in hypoxia-mediated apoptosis is Apaf-1. Apaf-1 knockout mice showed severe defects in the apoptotic response to hypoxic stimulation (13). We found Apaf-1 expression in 86% of our investigated cervical cancer samples. This finding is consistent with previous published data by our group that found Apaf-1 positivity in 78% of cervical cancers (14). Although the vast

majority of cervical cancers express Apaf-1, 75% of the Apaf-1–negative tumors were found in the group of hypoxic low-apoptotic tumors, suggesting a mechanism by which hypoxic cervical cancers acquire resistance to apoptosis. In conclusion, one mechanism by which hypoxic cervical cancers avoid apoptosis seems to be the loss of Apaf-1 expression. Thus, low expression of Apaf-1 in hypoxic tumors may be an unfavorable prognostic factor.

Acknowledgments

We thank Regina Scherling and Kathleen Fahr for technical assistance; Carola Koschke and Andrea Rothe for assisting in the oxygenation measurements; and Drs. André Liebmann and Guido Hildebrandt from the Department of Radiation Oncology for giving us access to patient follow-up data.

References

1. Brizel DM, Scully SP, Harrelson JM, et al. Tumor oxygenation predicts for the likelihood of distant metastases in human soft tissue sarcoma. *Cancer Res* 1996; 56:941–3.
2. Höckel M, Schlenger K, Aral B, Mitze M, Schäffer U, Vaupel P. Association between tumor hypoxia and malignant progression in advanced cancer of the uterine cervix. *Cancer Res* 1996;56:4509–15.
3. Nordsmark M, Overgaard M, Overgaard J. Pretreatment oxygenation predicts radiation response in advanced squamous cell carcinoma of the head and neck. *Radiother Oncol* 1996;41:31–9.
4. Denko NC, Fontana LA, Hudson KM, et al. Investigating hypoxic tumor physiology through gene expression patterns. *Oncogene* 2003;22:5907–14.
5. Graeber TG, Osmanian C, Jacks T, et al. Hypoxia-mediated selection of cells with diminished apoptotic potential in solid tumours. *Nature* 1996;379:88–91.
6. Kim CY, Tsai MH, Osmanian C, et al. Selection of human cervical epithelial cells that possess reduced apoptotic potential to low-oxygen conditions. *Cancer Res* 1997;57:4200–4.
7. Harris AL. Hypoxia—a key regulatory factor in tumour growth. *Nat Rev Cancer* 2002;2:38–47.
8. Greijer AE, van der Wall E. The role of hypoxia inducible factor 1 (HIF-1) in hypoxia induced apoptosis. *J Clin Pathol* 2004;57:1009–14.
9. Höckel M, Schlenger K, Hockel S, Vaupel P. Hypoxic cervical cancers with low apoptotic index are highly aggressive. *Cancer Res* 1999;59:4525–8.
10. Ferraro E, Corvaro M, Cecconi F. Physiological and pathological roles of Apaf1 and the apoptosome. *J Cell Mol Med* 2003;7:21–34.
11. Hajra KM, Liu JR. Apoptosome dysfunction in human cancer. *Apoptosis* 2004;9:691–704.
12. Hill MM, Adrain C, Martin SJ. Portrait of a killer: the mitochondrial apoptosome emerges from the shadows. *Mol Interv* 2003;3:19–26.
13. Soengas MS, Alarcon RM, Yoshida H, et al. Apaf-1 and caspase-9 in p53-dependent apoptosis and tumor inhibition. *Science* 1999;284:156–59.
14. Leo C, Richter C, Horn LC, Schutz A, Pilch H, Hockel M. Expression of Apaf-1 in cervical cancer correlates with lymph node metastasis but not with intratumoral hypoxia. *Gynecol Oncol* 2005; 97:602–6.
15. Kimura M, Furukawa T, Abe T, et al. Identification of two common regions of allelic loss in chromosome arm 12q in human pancreatic cancer. *Cancer Res* 1998;58:2456–60.
16. Soengas MS, Capodieci P, Polsky D, et al. Inactivation of the apoptosis effector Apaf-1 in malignant melanoma. *Nature* 2001;409:207–11.
17. Roman-Gomez J, Jimenez-Velasco A, Castillejo JA, et al. Promoter hypermethylation of cancer-related genes: a strong independent prognostic factor in acute lymphoblastic leukemia. *Blood* 2004;104: 2492–8. Epub 2004 Jun 24.
18. Leo C, Horn LC, Hockel M. Hypoxia and expression of the proapoptotic regulator BNIP3 in cervical cancer. *Int J Gynecol Cancer* 2006;16:1314–20.
19. Höckel M, Schlenger K, Knoop C, Vaupel P. Oxygenation of carcinomas of the uterine cervix: evaluation by computerized O₂ tension measurements. *Cancer Res* 1991;51:6098–102.
20. Winter SC, Shah KA, Campo L, et al. Relation of erythropoietin and erythropoietin receptor expression to hypoxia and anemia in head and neck squamous cell carcinoma. *Clin Cancer Res* 2005;11: 7614–20.
21. Höckel M, Horn LC, Fritsch H. Association between the mesenchymal compartment of uterovaginal organogenesis and local tumour spread in stage IB–IIB cervical carcinoma: a prospective study. *Lancet Oncol* 2005;6:751–6. Epub 2005 Sep 2008.
22. Höckel M, Horn LC, Hentschel B, Höckel S, Naumann G. Total mesometrial resection: high resolution nerve-sparing radical hysterectomy based on developmentally defined surgical anatomy. *Int J Gynecol Cancer* 2003;13:791–803.