

ALEUKEMIC LEUKEMOID RESPONSE IN MILIARY TUBERCULOSIS

By J. S. STAFFURTH, M.D. (LOND.), M.R.C.P., AND H. SPENCER, M.D. (LOND.),
F.R.C.S.

ABNORMAL peripheral blood pictures have been reported as occurring in some patients with miliary tuberculosis and all varieties of leukemia have been mistakenly diagnosed for this condition. Most of the cases were reported before sternal marrow puncture became a routine procedure and in many of the more recent cases this investigation was not performed.

We report a case of miliary tuberculosis which presented with pyrexia of unknown origin and a marked leukopenia, which was finally diagnosed in life as acute aleukemic lymphatic leukemia on the basis of the sternal marrow picture and the result of a lymphatic gland biopsy.

CASE REPORT

A married woman, aged 55, was admitted to hospital with pyrexia of unknown origin. The illness began three weeks before admission with symptoms of general weakness which had steadily become worse; she died after one week in hospital. Two days before admission she fell out of bed, cutting her left temple. On the day of admission she complained of abdominal distention but there was no headache, no pain, no cough or other symptoms. She had previously been healthy and there was no family history of tuberculosis.

On examination, she appeared seriously ill, orthopneic, slightly drowsy but well-orientated. Temperature was 102 F., pulse rate 104, respiration rate 36, and the tongue was furred and dry. The mouth and pharynx were normal, there was no jaundice and no glandular enlargement. There was a small cut on the left temple and a few bruises were present on the legs and in the right loin. There was dullness at the base of the right lung and the breath sounds were vesicular; numerous rales were present at both bases. There was no abnormality in the cardiovascular system, and the blood pressure was 140 mm. Hg. systolic and 70 mm. Hg. diastolic. The abdomen was distended with a moderate degree of ascites; neither the liver nor spleen was palpable and there was no abdominal tenderness. There was no neck rigidity, the fundi and pupils were normal, the knee jerks were just obtained, ankle jerks were absent and the plantar responses were flexor.

Laboratory investigations soon after admission showed: RBC 3.5 M, hemoglobin 52 per cent, WBC 1,400 per cu. mm. (polymorphonuclears 50 per cent, lymphocytes 46 per cent, monocytes 2 per cent, unclassifiable mononuclear cells 2 per cent). Agglutination tests were negative to the enteric group of organisms, blood culture was sterile, urine culture sterile and stool culture showed no pathogenic organisms. The urine contained a trace of albumin but no cells or casts were present. Blood chemistry showed the following: a blood urea 26 mg. per 100 cc. of blood, icteric index 6 units, thymol turbidity 8 units, plasma proteins 5.25 Gm. per cent (albumin 2.5 Gm. per cent, globulin and fibrinogen 2.75 per cent), and the urine urobilinogen was 2.4 mg. per 100 cc. Chest examination by portable x-ray yielded an unsatisfactory result but showed no gross changes in the lung fields.

Ascitic fluid obtained by paracentesis was faintly turbid and contained a few red cells and many leukocytes, 90 per cent of which were lymphocytes; no tubercle bacilli and no malignant cells were seen and the fluid was sterile on culture. Blood count (fifth day after admission) showed RBC 3,280,000 per cu. mm., Hb. 50 per cent, WBC 2,400 per cu. mm. (polymorphonuclears 36 per cent, lymphocytes 63 per cent, unclassifiable mononuclear cells 1 per cent). A sternal marrow puncture showed a great reduction in normal constituents with lymphocytic infiltration (megaloblast 0.2 per cent, normoblast A 0.6 per cent, normoblast C 3.8 per cent, myelocyte 0.6 per cent, metamyelocyte 1.0 per cent, polymorpho-

From the Department of Pathology, St. Thomas's Hospital, London, England.

nuclear 2.0 per cent, small lymphocytes 87.6 per cent, primitive cells—probably transitional lymphoblasts—3.8 per cent, monocytes 0.2 per cent, Ferrata cells 0.2 per cent).

A lymph node biopsy was performed. The cut surface was a uniform yellowish-white, with no visible necrotic areas. Microscopic examination of the node showed complete destruction of the normal architecture of the tissue and a generalized lymphocytic infiltration throughout the section. There were also areas of necrosis showing no surrounding histiocytic or giant cell reaction. Unfortunately a Ziehl-Neelsen stain was not carried out and the nature of the necrotic areas was not appreciated.

The drowsiness increased, edema of the ankles developed and there was an increase in the bruising on the legs and bleeding occurred around the sites of injections. Blood transfusion was given but the patient's condition continued to deteriorate and she died in coma eight days after admission.

The clinical diagnosis at the time of death was acute aleukemic lymphatic leukemia.

Postmortem Examination

Postmortem examination showed generalized miliary tuberculosis and appearances suggestive of lymphatic leukemia. The body was that of a well developed, middle-aged woman with a recent incision in the right side of the neck, abrasions over the left eyebrow and bruising over the front of both legs. There was generalized enlargement of the cervical, mediastinal and abdominal lymphatic glands. The glands were soft and pinkish-grey in color. There were miliary tubercles scattered over the peritoneum, omentum and parietal pleura; both serous sacs contained dark yellow fluid. Miliary tubercles were seen in the enlarged congested spleen, and throughout the pale fatty liver. The bone marrow was greyish-red and occupied three-quarters of the shaft of the right femur. Of the other viscera, the myocardium was pale and flabby, the great vessels were normal, the lower half of the trachea and both bronchi contained thick mucopus and there was partial collapse of the lower lobes of both lungs. The stomach contained a small quantity of blood-stained fluid, the small intestine was normal, and there were greyish-white pinpoint nodules in the mucosa of the large intestine. The biliary, urinary, genital and endocrine systems were normal. There was no evidence of tuberculous meningitis and the brain appeared normal.

The chief findings included the presence of miliary tubercles on the surface of the peritoneum and parietal pleura, also in the substance of the spleen and liver. There was slight generalized lymph gland enlargement, together with enlargement of the spleen, and transformation and hyperplasia of the bone marrow which was similar in appearance to that found in leukemic states.

Microscopic Examination

There was a lymphocytic infiltration and complete replacement of the normal lymph gland architecture in both the mesenteric and mediastinal glands examined. Also, both these glands contained ill-defined necrotic areas which were found to be caseous foci with no surrounding histiocytic or giant cell response (fig. 1); the caseous areas contained innumerable acid fast bacilli in Ziehl-Neelsen stained sections (fig. 2). There were also numerous caseous tubercles in the omentum, liver, spleen and on the peritoneal surface of the colon, all of which showed an absence of the usual histiocytic and giant cell cellular reaction. The bone marrow showed a generalized lymphocytic infiltration and replacement of the normal hemopoietic cells and could not be distinguished from the bone marrow found in lymphatic leukemia (figs. 3 and 4). There were no tubercles seen in either the lung or kidney, both of which were congested. There were focal areas of fibrosis and subendocardial lymphocytic infiltration in the heart muscle.

The microscopic appearances were those of an acute generalized caseating form of tuberculosis unassociated with the usual histologic features found in miliary tuberculosis. The presence, however, of acid-fast bacilli in the caseous zones confirmed the diagnosis. The unusual lymphocytic response excited by the tuberculous process had produced appearances in the bone marrow and lymph glands identical with those found in lymphatic leukemia, but the absence of leukemic infiltration in the kidney, liver and spleen differentiated the condition from a true leukemia.

DISCUSSION

Coley and Ewing¹ were probably the first to describe a case of generalized tuberculosis associated with a leukemic type of blood picture. Krumbhaar⁴ introduced

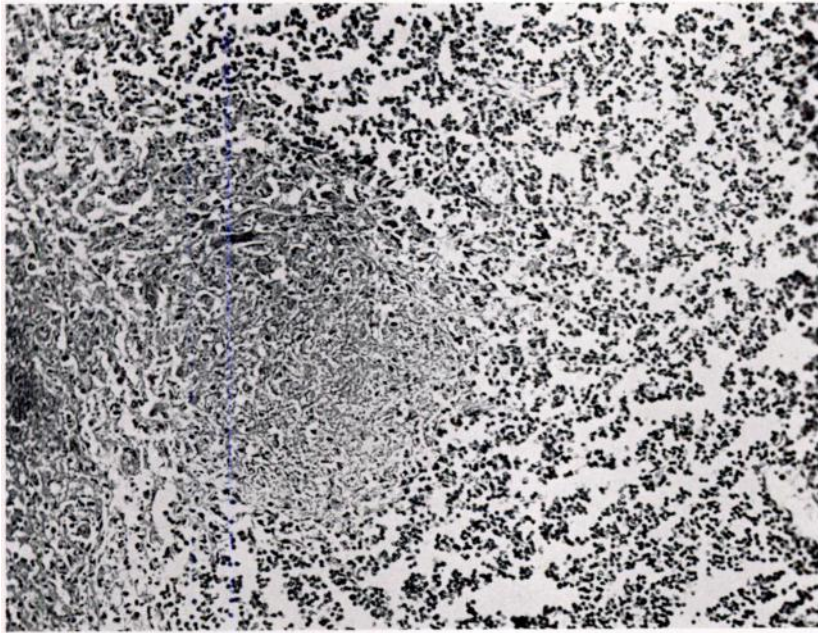


FIG. 1.—Section of a hilar lymph gland showing lymphocytic infiltration and the resemblance to the appearances seen in lymphatic leukemia, except for the area of caseous destruction near the center. (Stained H. & E., $\times 480$.)

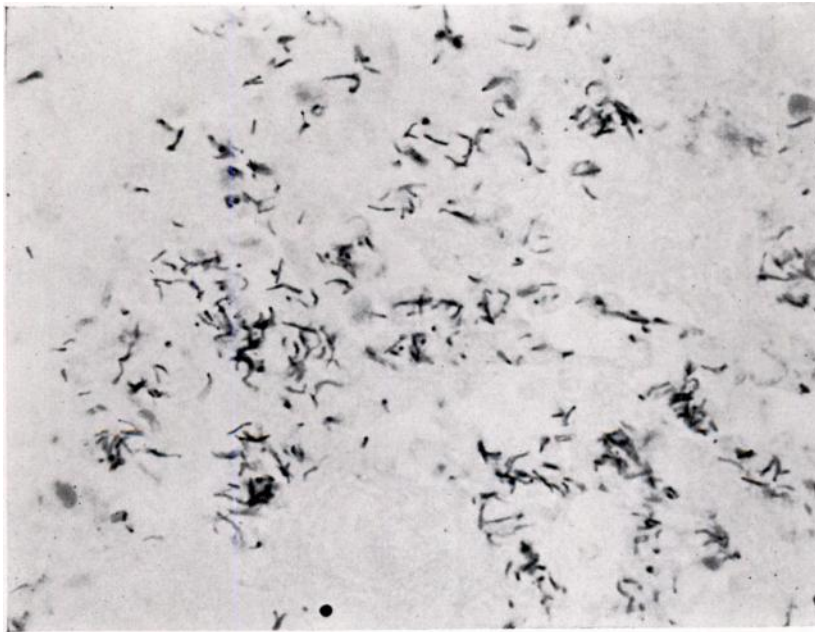


FIG. 2.—Caseous area from the same lymph gland as shown in figure 1, stained to show the presence of acid-fast bacilli. (Stained Ziehl-Neelsen $\times 1040$.)

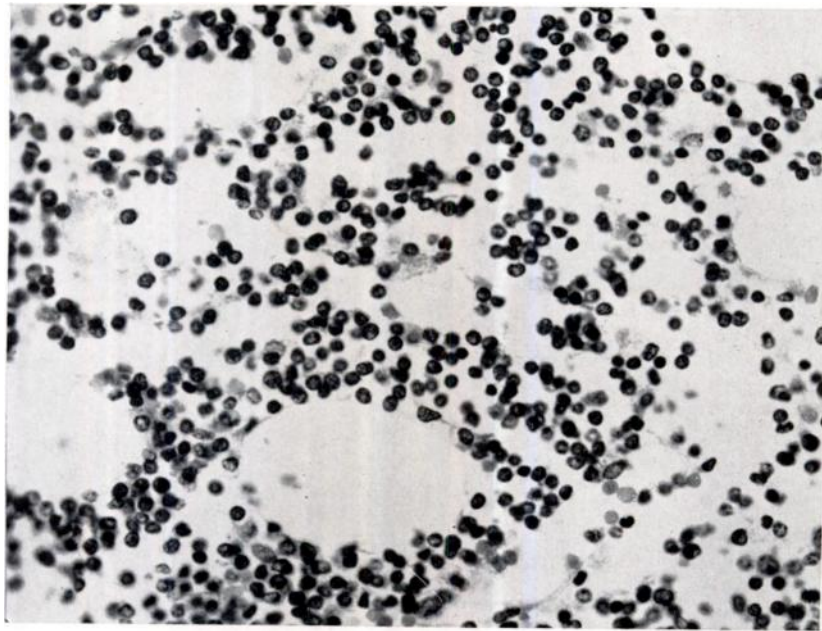


FIG. 3.—Section of bone marrow showing lymphocytic infiltration and replacement of the normal bone marrow cells. The appearances are histologically indistinguishable from those found in lymphatic leukemia. (Stained H. & E., $\times 480$.)

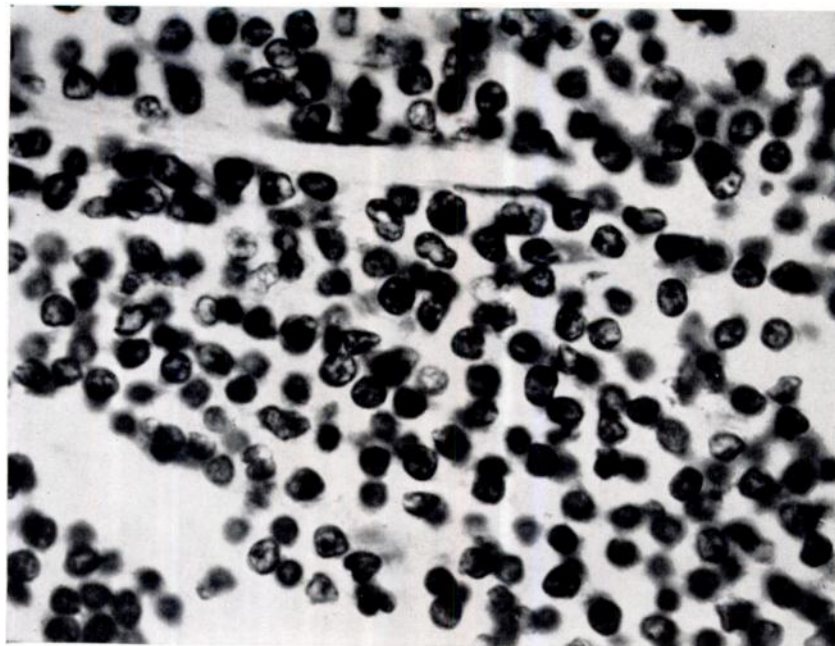


FIG. 4.—Higher magnification of same section as shown in figure 3. (Stained H & E., $\times 1000$.)

the term leukemoid reaction to denote a leukemic type of blood response to a variety of conditions which could include miliary tuberculosis. Since then several cases of both myeloid and lymphatic leukemoid blood pictures in association with generalized tuberculosis have been reported in the literature.^{2, 6} In the case reported above, a clinical diagnosis of aleukemic lymphatic leukemia was made in view of the histologic appearances of the gland removed at biopsy and the sternal marrow picture. The lymphatic gland removed at biopsy showed one unusual feature in that there were focal areas of caseation, an unusual finding in lymphatic leukemia or lymphosarcoma, but the significance of this feature was not appreciated. Although the ascitic fluid was cultured, the report of the growth of acid-fast bacilli was not available until after the death of the patient.

In retrospect, certain of the clinical features of the case appear noteworthy: first, the rapid onset and course of the illness in a middle-aged woman who previously had been in good health without any evidence of a pre-existent active tuberculous infection. Also the very rapid enlargement of the lymph glands, which were not felt at the time of her admission to hospital but were palpably enlarged four days later, might have served to differentiate the condition from a true leukemia in which glandular enlargement is never so rapid.

The histologic appearances of the lymphatic glands and bone marrow were almost identical with those found in lymphatic leukemia, except that there were several areas of necrosis which, when stained with Ziehl-Neelsen stain, were found to contain numerous acid-fast bacilli, and the spleen still retained visible discrete malpighian corpuscles.

The complete absence of the normal histologic picture seen around an area of tuberculous caseation was a feature common to previously reported cases.⁵ Also, the absence of demonstrable miliary tubercles in the lung, kidney and meninges and the presence of tubercles especially associated with the fixed reticulo-endothelial system, has been noted in similar cases previously.

It would appear that any of the three common forms of leukemic response, including the monocytic reaction,³ may complicate the acute necrotic and rapidly fatal form of miliary tuberculosis.

SUMMARY

A case of miliary tuberculosis associated with an aleukemic lymphatic blood picture has been reported. The histologic appearances of tissue removed at autopsy confirmed the leukemic picture and also showed diffuse tuberculous lesions of a necrotic type containing innumerable acid-fast bacilli.

ACKNOWLEDGMENTS

We wish to thank Sir Lionel Whitby and Dr. J. S. Richardson for their interest in the case, and advice in the preparation of this paper.

REFERENCES

- ¹ COLEY, W. B., AND EWING, J.: Acute lymphatic tuberculosis with purpura haemorrhagica. *Tr. A. Am. Physicians* 26: 178, 1911.

- ² GARDNER, F. H., AND METTIER, S. R.: Lymphocytic leukemoid reaction of the blood associated with miliary tuberculosis. *Blood* 4: 767, 1949.
- ³ GIBSON, A.: Monocytic leukaemoid reaction with tuberculosis and a mediastinal teratoma. *J. Path. & Bact.* 58: 469, 1946.
- ⁴ KRUMBHAR, E. B.: Leukemoid blood pictures in various clinical conditions. *Am. J. M. Sc.* 172: 519, 1926.
- ⁵ LEIBOWITZ, S.: Tuberculous sepsis with a myeloblastic blood picture. *Arch. Path.* 25: 365, 1938.
- ⁶ MILLS, E. S., AND TOWNSEND, S. R.: Leukaemoid blood picture in tuberculosis. *Canad. M.A.J.* 37: 56, 1937.