

## Cephalometric Characteristics of Korean Children with Class III Malocclusion in the Deciduous Dentition

Hyung-Jun Choi<sup>a</sup>; Ji-Yeon Kim<sup>b</sup>; Seung Eun Yoo<sup>c</sup>; Jang-Hyuk Kwon<sup>d</sup>; Kitae Park<sup>e</sup>

### ABSTRACT

**Objective:** To compare the cephalometric characteristics of children with Class III malocclusion to those of children with normal occlusion during the deciduous dentition phase.

**Materials and Methods:** Cephalometric measurements of 27 children (mean age: 5.03 years) diagnosed with Class III malocclusion were compared with 32 children (mean age: 4.85 years) diagnosed with normal occlusion in the following four categories: sagittal skeletal analysis, vertical skeletal analysis, dentoalveolar analysis, and soft tissue analysis.

**Results:** Significant differences were seen in all categories except vertical skeletal analysis. Sagittal skeletal measurements included ANB (Class III group:  $-0.91 \pm 1.60$ ; normal group:  $5.28 \pm 1.29$ ), facial convexity (Class III group:  $0.47 \pm 4.32$ ; normal group:  $13.65 \pm 3.44$ ), Wits appraisal (Class III group:  $-5.54 \pm 2.36$ ; normal group:  $-0.84 \pm 1.91$ ), and A to N-perpendicular (Class III group:  $-2.94 \pm 3.05$ ; normal group:  $0.78 \pm 2.53$ ). Dentoalveolar measurements included U1 to NA (Class III group:  $11.98 \pm 5.25$ ; normal group:  $8.12 \pm 5.43$ ), IMPA (Class III group:  $81.34 \pm 7.40$ ; normal group:  $86.57 \pm 5.67$ ), and interincisal angle (Class III group:  $152.65 \pm 8.82$ ; normal group:  $145.03 \pm 7.34$ ). Soft tissue measurements included soft tissue convexity (Class III group:  $2.47 \pm 4.20$ ; normal group:  $12.71 \pm 3.95$ ), nasofacial angle (Class III group:  $22.68 \pm 4.22$ ; normal group:  $26.24 \pm 3.84$ ), and upper lip to esthetic plane (Class III group:  $-0.65 \pm 2.74$ ; normal group:  $3.07 \pm 1.90$ ).

**Conclusions:** There are significant differences between the craniofacial patterns of normal children and those of children with Class III malocclusion that can be identified with cephalometric analysis as early as the deciduous dentition phase. (*Angle Orthod.* 2010;80:86–90.)

**KEY WORDS:** Class III malocclusion; Mesial step; Anterior crossbite; Deciduous dentition

### INTRODUCTION

Skeletal Class III malocclusion accompanied by anterior crossbite is clearly visible in the early stages of

childhood. It is a major reason that Asian patients seek orthodontic treatment, given its high prevalence in Asian populations (12% in Asian vs 3%–5% in white populations).<sup>1–5</sup>

The recommended time to treat Class III malocclusion with orthodontics is during the deciduous or early mixed dentition years,<sup>6–8</sup> with better results reported during the deciduous dentition years.<sup>9</sup> Methods of treatment include facemask, chin cup, and functional jaw appliances, each with different effects on the maxilla and mandible. The mode of treatment should be selected based on proper diagnosis of the cause of malocclusion, such as a retrusive maxilla, a protrusive mandible, or both.

In this study, facial profile evaluation was combined with cephalometric analysis for accurate diagnosis. Although numerous studies have reported the use of cephalometric analysis in the diagnosis of Class III malocclusion, most were done of children with mixed dentition, with very few studies examining children with deciduous dentition.<sup>10–14</sup>

Therefore, the purpose of this study was to compare the cephalometric characteristics of Korean children with Class III malocclusion to those of Korean children

<sup>a</sup> Associate Professor, Department of Pediatric Dentistry, College of Dentistry and Oral Science Research Center, Yonsei University, Seoul, Korea.

<sup>b</sup> Assistant Professor, Department of Pediatric Dentistry, Samsung Medical Center, Sungkyunkwan University School of Medicine, Seoul, Korea.

<sup>c</sup> Resident, Department of Pediatric Dentistry, Samsung Medical Center, Sungkyunkwan University School of Medicine, Seoul, Korea.

<sup>d</sup> Former resident, Department of Pediatric Dentistry, Samsung Medical Center, Sungkyunkwan University School of Medicine, Seoul, Korea.

<sup>e</sup> Associate Professor and Chairman, Department of Pediatric Dentistry, Samsung Medical Center, Sungkyunkwan University School of Medicine, Seoul, Korea.

Corresponding author: Dr Kitae Park, Associate Professor and Chairman, Department of Pediatric Dentistry, Samsung Medical Center, Sungkyunkwan University School of Medicine, 50, Irwon-dong, Gangnam-gu, Seoul, Korea 135-710 (e-mail: park2426@skku.edu)

Accepted: March 2009. Submitted: December 2008.

© 2010 by The EH Angle Education and Research Foundation, Inc.

with normal occlusion during the deciduous dentition phase.

## MATERIALS AND METHODS

### Class III Group

The Class III group consisted of cephalometric records of 27 patients with Class III malocclusion between the ages of 4.5 and 5.5 years (mean age: 5.03 years) who visited the Department of Pediatric Dentistry at Samsung Medical Center from January 2000 to December 2005. Inclusion criteria were: (1) anterior crossbite, (2) concave facial profile, (3) mesial step molar relationship, and (4) Class III deciduous canine relationship.

### Normal Occlusion Group

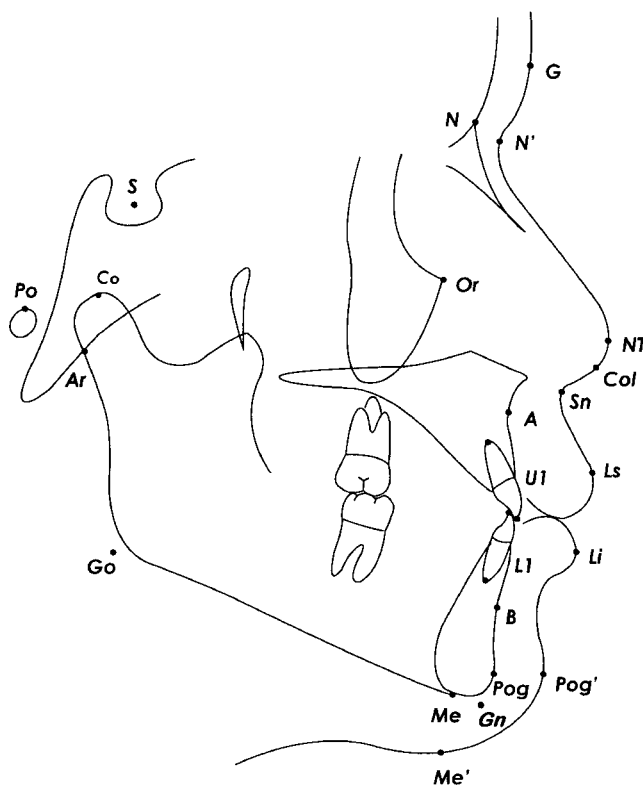
The normal occlusion group consisted of cephalometric records of 32 patients with normal occlusion (mean age: 4.85 years) who visited the Department of Pediatric Dentistry at Samsung Medical Center during the same period as above. Inclusion criteria were: (1) normal overbite and overjet, (2) straight to slightly convex profile, (3) neutro-occlusion or flush terminal plane molar relationship, and (4) Class I deciduous canine relationship.

In order to evaluate the profile of the samples, frontal and lateral facial photographs were judged by two residents as concave or straight. The samples with the same judgment were finally selected for the corresponding group. Exclusion criteria were: (1) proximal dental caries, (2) missing teeth, (3) a history of significant medical illness, and (4) previous orthodontic or prosthodontic treatment.

### Test Methods

Lateral cephalometric radiographs were taken in the natural head position with posterior teeth in maximum intercuspation. Lateral cephalograms were traced onto acetate papers by the same investigator; the papers were then scanned. The landmarks (Figure 1) were digitized using V-Ceph 5.0 (Osstem Implant Co Ltd, Seoul, Korea). For error measurements, 20 randomly selected patients were retraced and digitized in 2 weeks, and intraclass correlation coefficient was calculated. The intraclass correlation coefficient (0.78~0.97) showed that the data measured by the same investigator were highly reliable. Craniofacial structural relationships were divided into four categories for analysis of the angular and linear measurements in each (Table 1).

The means and standard deviations for the Class III and normal occlusion groups were calculated using SAS version 9.13 (SAS Institute Inc, Cary, NC). Stu-



**Figure 1.** Cephalometric landmarks. N indicates nasion; S, sella; Co, condylion; Ar, articulare; Go, gonion; Po, porion; Me, menton; Gn, gnathion; Pog, pogonion; A, A point; B, B point; Or, orbitale; U1, incisal edge of upper central incisor; L1, incisal edge of lower central incisor; G, soft tissue glabella; N', soft tissue nasion; NT, nasal tip; Col, collumella; Sn, subnasale; Ls, labiale superius; Li, labiale inferius; Pog', soft tissue pogonion; Me', soft tissue menton.

dent's *t*-tests or Wilcoxon two-sample tests were performed to assess differences between the test (Class III) group and the control (normal occlusion) group. Results were considered as significant at the significance level of .05. This study was reviewed and approved by the Institutional Review Board of Samsung Medical Center.

## RESULTS

### Sagittal Skeletal Analysis

The relative sagittal position of the maxilla and mandible (ANB difference, facial convexity, Wits appraisal) showed highly significant differences between test and control groups ( $P < .0001$ ). The anteroposterior position of the maxilla relative to the cranial base (SNA, A point to N-perpendicular) was also highly significantly different between groups ( $P < .0001$ ). Mandibular length (condylion-constructed gnathion) was significantly greater in the test group, but there was no difference in maxillary length between groups. See Table 2.

**Table 1.** Categories of Angular and Linear Measurements in the Analysis of Craniofacial Structural Relationships

Skeletal		Dentoalveolar Analysis	Soft Tissue Analysis
Sagittal	Vertical		
SNA	FMA	U1 to SN	Soft tissue convexity (N'-Sn-Pog')
SNB	SN-MP (mandibular plane)	U1 to NA (angular and linear)	Nasofacial angle (angle between G-Pog and N-NT line)
ANB	SN-FH	L1 to NB (angular and linear)	Nasolabial angle (col-sn-ls)
Wits appraisal	Saddle angle (N-S-Ar)	IMPA	Upper lip to E-plane (distance between upper lip and NT-Pog')
A to N-perpendicular	Articular angle (N-Ar-Go)	Interincisal angle	Lower lip to E-plane (distance between lower lip and NT-Pog')
Facial convexity (N-A-Pog)	Gonial angle (Ar-Go-Me)		G-Sn/Sn-Me'
Maxillary length (Gn-Co)	Sum (saddle + gonial + articular)		
Mandibular body (Me-Go)/ anterior cranial base (S-N)	Posterior facial height (S-Go)/ anterior facial height (N-Me) Ramus height (Go-Ar)		

### Vertical Skeletal Analysis

There was no significant difference in the vertical skeletal relationships (SN to MP angle, gonial angle, PFH/AFH ratio) between the two groups. In the test group, however, the saddle angle and ramus height were significantly greater, while the articular angle was significantly smaller than that of the control group. See Table 3.

### Dentoalveolar Analysis

Two measures of the inclination of mandibular incisors (IMPA and L1 to NB) showed significant retroclination in the Class III group. One measure of the inclination of maxillary incisors (U1 to NA) showed significant proclination in the Class III group. The interincisal angle was significantly greater in the Class III group. See Table 4.

### Soft Tissue Analysis

Soft tissue convexity (G-Sn-Pog') was significantly greater in the normal occlusion group. While the lower

lip position (lower lip to E-plane) was similar, there was a significant difference in the upper lip position (upper lip to E-plane) between the two groups. See Table 5.

### DISCUSSION

Patients with anterior crossbites are usually suspected to have skeletal Class III malocclusion, which can be subdivided into true Class III malocclusion of skeletal origin and pseudo-Class III of dental origin. In this study, cephalometric analysis of children with Class III malocclusion and those with normal occlusion in the same age group was performed to identify defining characteristics of Class III malocclusion in the deciduous dentition. To exclude children with pseudo-Class III malocclusion of dental origin, only patients with concave profiles were included. Traditionally, guiding the mandible forward to anterior edge-to-edge bite was the key to judge pseudo-Class III malocclusion. However, in reality, most patients with anterior crossbite in deciduous dentition can guide their mandible forward to anterior edge-to-edge bite. Therefore,

**Table 2.** Sagittal Skeletal Analysis of Normal and Class III Children

Measure Name	Normal Children		Class III Children		P-Value
	Mean	SD	Mean	SD	
SNA	83.00	2.75	78.33	3.34	<.0001
SNB	77.72	2.76	79.24	2.74	.0386
ANB	5.28	1.29	-0.91	1.60	<.0001
Wits	-0.84	1.91	-5.54	2.36	<.0001
A to N-perpendicular	0.78	2.53	-2.94	3.05	<.0001
Facial convexity	13.65	3.44	0.47	4.32	<.0001
Maxillary length	78.04	4.00	76.59	3.22	.1358
Pogonion to N-perpendicular	-9.92	4.80	-6.15	5.43	.0052*
Mandibular body/anterior cranial base	0.93	0.04	0.98	0.06	.0001*
Mandibular length	96.26	4.02	101.16	3.69	<.0001

\* Test method is Wilcoxon two-sample test, otherwise t-test.

**Table 3.** Vertical Skeletal Analysis of Normal and Class III Children

Measure Name	Normal Children		Class III Children		P-Value
	Mean	SD	Mean	SD	
FMA	29.42	3.50	27.22	4.58	.0417
SN-MP	37.28	4.52	35.70	3.89	.1606
SN to FH	7.86	2.29	8.48	2.40	.3166
Saddle angle	120.01	3.75	123.10	4.39	.0050
Articular angle	150.20	5.70	145.42	6.66	.0042*
Gonial angle	127.09	4.21	127.19	5.12	.9320
Sum	397.29	4.51	395.72	3.89	.1614
PFH/AFH	62.47	3.57	63.01	3.07	.5358
Ramus height	38.41	2.87	40.06	2.58	.0257

\* Test method is Wilcoxon two-sample test, otherwise t-test.

the method of mandibular forward guidance was not used for this study.

According to a study by Tollaro et al,<sup>10</sup> patients with Class III malocclusion exhibit unique craniofacial characteristics from the early ages of deciduous dentition.<sup>15</sup> In accordance with this, our study discovered statistically significant differences in many cephalometric measurements between normal and Class III children with deciduous dentition.

Sagittal skeletal analysis showed highly significant differences between groups in all measurements except maxillary length and SNB angle. In most deciduous dentition patients with anterior crossbites, functional deviation of the mandible is common during centric occlusion. This deviation can result in significant error in measurements dictated by mandibular position, such as ANB difference, Wits, facial convexity, and pogonion to N-perpendicular. For this reason, our study instead compared measurements that are independent of mandibular position, such as mandibular length, SNA, A point to N-perpendicular, and mandibular body to anterior cranial base ratio.

Results showed that the difference in maxillary size was insignificant between the two groups. However, A point to N-perpendicular and mandibular body to anterior cranial base ratio showed that the Class III group had retrognathic maxillas and significantly larger mandibles compared to those of the normal group. Similar

**Table 4.** Dentoalveolar Analysis of Normal and Class III Children

Measure Name	Normal Children		Class III Children		P-Value
	Mean	SD	Mean	SD	
U1 to SN	91.08	5.85	90.31	4.29	.5744
U1 to NA (angular)	8.12	5.43	11.98	5.25	.0077
U1 to NA (linear)	1.24	0.94	1.29	1.02	.9515*
L1 to NB (angular)	21.57	4.58	16.29	6.48	.0006
L1 to NB (linear)	3.30	1.28	2.33	1.34	.0064
IMPA	86.57	5.67	81.34	7.40	.0032
Interincisal angle	145.03	7.34	152.65	8.82	.0006

\* Test method is Wilcoxon two-sample test, otherwise t-test.

**Table 5.** Soft Tissue Analysis of Normal and Class III Children

Measure Name	Normal Children		Class III Children		P-Value
	Mean	SD	Mean	SD	
G-Sn-Pog' angle	12.71	3.95	2.47	4.20	<.0001*
Nasofacial angle	26.24	3.84	22.68	4.22	.0013
Nasolabial angle	103.92	10.39	97.32	12.66	.0318
Upper lip to E-plane	3.07	1.90	-0.65	2.74	<.0001
Lower lip to E-plane	1.54	1.81	1.99	2.17	.3929
G-Sn/Sn-Me'	0.88	0.06	0.92	0.06	.0169

\* Test method is Wilcoxon two-sample test, otherwise t-test.

differences were also reported in studies by Tollaro et al<sup>10</sup> and Chang et al.<sup>14</sup> In another study by Mouakeh et al<sup>9</sup> on adults with Class III malocclusion, approximately 45.3% showed protrusive mandibles, 33% showed a retrusive maxilla, and 9.5% showed a combination of these two findings.<sup>3</sup> In addition, Guyer et al<sup>16</sup> reported that 57% of patients with Class III malocclusion showed retrusive maxillas. In a different study on etiology, Sanborn<sup>16</sup> hypothesized that Class III malocclusion during the deciduous dentition years is due to mandibular prognathism in 23% of cases and to a retrusive maxilla in 26%. In this study, according to cephalometric analysis, approximately 50% of patients had prognathic mandibles, 20% had retrognathic maxillas, and 30% had a combination of prognathic mandible and retrognathic maxilla. In contrast to previous studies, our data indicate that an oversized mandible is the cause of Class III malocclusion in almost 80% of the cases. This may be explained by our selection of patients with potential skeletal Class III malocclusion from all patients with anterior crossbites. In addition, the racial difference of oriental origin in our sample could have affected the results.

Vertical skeletal analysis revealed no statistically significant differences between test and control groups except for the saddle and articular angles. Although the saddle angle is classically expected to be smaller in patients with Class III malocclusion, this was not true in our study. For this reason, we do not consider the saddle angle a reliable criterion for the diagnosis of Class III malocclusion in the deciduous dentition. Additionally, although the articular angle was significantly different between groups, this angle may be misleading due to functional forward deviation of the mandible in the Class III group.

Dentoalveolar analysis showed proclined upper incisors and retroclined lower incisors in the Class III group, showing that dental compensation can occur as early as the deciduous dentition years. This finding contradicts findings by Chang et al,<sup>14</sup> who reported patients in which both upper and lower incisors were retroclined. This discrepancy between reports may be

due to the clear skeletal Class III pattern of patients included in our study.

Rak<sup>17</sup> reported decreased soft tissue facial convexity in children with Class III malocclusion, but Kess<sup>18</sup> claimed that this anomaly is not related to the skeletal characteristics of malocclusion, but rather to age. In our study, there was a significant increase in facial concavity in the Class III group, in addition to a significantly smaller nasofacial angle. The nasolabial angle was also smaller in the Class III group, but the difference was not highly significant ( $P = .0318$ ). Lower lip position was not different between groups, but the upper lip was significantly more retruded in the Class III group. Clearly, this trait can be used to distinguish Class III patients in a clinical facial examination.

This study showed that some of the cephalometric values (A point to N-perpendicular, mandibular body to anterior cranial base ratio, mandibular length, U1 to NA angular, L1 to NB angular, interincisal angle) are highly reliable for use to diagnose skeletal Class III malocclusion in the deciduous dentition.

## CONCLUSIONS

- The skeletal characteristics of Class III malocclusion are revealed as early as the deciduous dentition stage in Korean children.
- Cephalometric evaluation can be an effective tool in the early diagnosis of skeletal Class III malocclusion in the deciduous dentition.

## REFERENCES

1. Ngan P, Hu AM, Fields HW Jr. Treatment of Class III problems begins with differential diagnosis of anterior crossbites. *Pediatr Dent*. 1997;19:386–395.
2. Newman GV. Prevalence of malocclusion in children six to fourteen years of age and treatment in preventable cases. *J Am Dent Assoc*. 1956;52:566–575.
3. Mouakeh M. Cephalometric evaluation of craniofacial pattern of Syrian children with Class III malocclusion. *Am J Orthod Dentofacial Orthop*. 2001;119:640–649.
4. Massler M, Frankel JM. Prevalence of malocclusion in children aged 14 to 18 years. *Am J Orthod*. 1951;37:751–768.
5. Horowitz HS, Cohen LK, Doyle J. Occlusal relations in children in an optimally fluoridated community. IV. Clinical and social-psychological findings. *Angle Orthod*. 1971;41:189–201.
6. Jacobson A. Psychology and early orthodontic treatment. *Am J Orthod*. 1979;76:511–529.
7. Campbell PM. The dilemma of Class III treatment. Early or late? *Angle Orthod*. 1983;53:175–191.
8. Moyers RE. *Handbook of Orthodontics*. 4th ed. Chicago, Ill: The Year Book Publishers Inc; 1988.
9. Kajiyama K, Murakami T, Suzuki A. Comparison of orthodontic and orthopedic effects of a modified maxillary protractor between deciduous and early mixed dentitions. *Am J Orthod Dentofacial Orthop*. 2004;126:23–32.
10. Tollaro I, Baccetti T, Bassarelli V, Franchi L. Class III malocclusion in the deciduous dentition: a morphological and correlation study. *Eur J Orthod*. 1994;16:401–408.
11. Singh GD, McNamara JA Jr, Lozanoff S. Morphometry of the midfacial complex in subjects with Class III malocclusions: Procrustes, Euclidean, and cephalometric analyses. *Clin Anat*. 1998;11:162–170.
12. Iwasaki H, Ishikawa H, Chowdhury L, Nakamura S, Iida J. Properties of the ANB angle and the Wits appraisal in the skeletal estimation of Angle's Class III patients. *Eur J Orthod*. 2002;24:477–483.
13. Clifford FO. Cross-bite correction in the deciduous dentition: principles and procedures. *Am J Orthod*. 1971;59:343–349.
14. Chang HP, Kinoshita Z, Kawamoto T. Craniofacial pattern of Class III deciduous dentition. *Angle Orthod*. 1992;62:139–144.
15. Guyer EC, Ellis EE III, McNamara JA Jr, Behrents RG. Components of Class III malocclusion in juveniles and adolescents. *Angle Orthod*. 1986;56:7–30.
16. Sanborn RT. Differences between the facial skeletal patterns of Class III malocclusion and normal occlusion. *Angle Orthod*. 1955;25:208–222.
17. Rak D. Cephalometric analysis in cases with Class III malocclusions. *Stomatol Glas Srb*. 1989;36:277–287.
18. Kess K. Age-dependent soft-tissue changes in the face [in German]. *Fortschr Kieferorthop*. 1990;51:373–377.