

Facial Soft Tissue Profile Following Bimaxillary Orthognathic Surgery

Ayşe Tuba Altug-Atac^a; Halise Bolatoglu^b; Ufuk Toygar Memikoglu^c

ABSTRACT

Objective: To determine the changes in the position and area of nasal and labial soft tissues in adult skeletal Class III patients who underwent bimaxillary orthognathic surgery.

Materials and Methods: Pretreatment (T1), preoperative (T2), and posttreatment (T3) cephalometric variables and upper-lower lip areas were measured on lateral cephalometric radiographs for 20 individuals (9 male, 11 female; mean age 21.3 years at T1, 22.4 years at T2, and 23.4 years at T3) who had maxillary advancement and mandibular setback. Analysis of variance (ANOVA) and Duncan tests were used to compare the cephalometric and area measurements at the beginning of treatment, and at presurgery and postsurgery, respectively. Paired *t*-tests were also performed to analyze changes within the periods.

Results: The tip of the nose was affected less with the movement of the underlying skeletal structure (0.25%), while the soft tissue B point (B') moved equally with the skeletal B point. As the maxilla related variables increased due to the forward movement, the upper labial areas decreased. With the backward movement of the mandible, the middle and inferior lower labial areas increased, while the superior lower labial area decreased.

Conclusions: The results of our study suggest that the dramatic improvement in the facial profiles of the bimaxillary surgery patients is primarily related to the backward movement of the mandible and the significant reduction in the superior lower lip area.

KEY WORDS: Class III malocclusion; Orthognathic surgery; Cephalometrics; Digital planimeter

INTRODUCTION

Successful surgical planning and accurate prediction of orthognathic surgery outcomes include not only occlusal correction and a well-balanced skeletal relationship, but the improvement of esthetics and function as well. For this reason, the prediction of postsurgical soft tissue changes is a crucial part of the presurgical treatment planning process.¹

A combination of mandibular setback plus maxillary advancement is one of the most common bimaxillary orthognathic surgical procedures for correcting severe

skeletal Class III discrepancies. Although several studies have been published on soft tissue changes following maxillary or mandibular surgery alone, few studies have been reported on soft tissue changes with bimaxillary surgery. Moreover, the possibility that lip volume may be one of the most important contributing factors in facial improvement makes including area measurements in the prediction of postoperative soft tissue changes imperative.^{2,3}

Therefore, the aims of this study were (1) to evaluate the skeletal changes and soft tissue responses of skeletal Class III patients treated by bimaxillary orthognathic surgery, and (2) to establish a relationship between cephalometric linear measurements and cephalometric area measurements.

MATERIALS AND METHODS

Twenty consecutive skeletal Class III patients (9 male, 11 female; mean age: 21.3 years; range: 17.08–30.08 years) were selected for this retrospective study. All patients were treated at the Ankara University Departments of Orthodontics and Oral and Maxillofacial Surgery.

^a Assistant Professor, Department of Orthodontics, School of Dentistry, University of Ankara, Ankara, Turkey.

^b Research Assistant, Department of Orthodontics, School of Dentistry, University of Ankara, Ankara, Turkey.

^c Professor, Department of Orthodontics, School of Dentistry, University of Ankara, Ankara, Turkey.

Corresponding author: Dr Ayşe Tuba Altug-Atac, Ankara Universitesi, Dis Hekimligi Fakultesi, Ortodonti Anabilim Dalı, 06500, Besevler, Ankara, Turkey (e-mail: aysealtug@yahoo.com)

Accepted: February 2007. Submitted: December 2006.

© 2007 by The EH Angle Education and Research Foundation, Inc.

Table 1. The Distribution of the Patients According to Gender and Mean Chronological Age for Stages T1 (Pretreatment), T2 (Presurgery), and T3 (Posttreatment)

	N	Mean Chronological Age, Year		
		T1	T2	T3
Female	11	21.1	22.3	23.0
Male	9	21.5	22.5	23.8
Total	20	21.3	22.4	23.4

All patients:

- Were nonsyndromic;
- Received presurgical orthodontics by different residents but with the same protocol;
- Underwent maxillary advancement by Le Fort 1 osteotomy (no maxillary impaction) and mandibular setback by bilateral sagittal split osteotomy, without any additional surgical procedures by the same surgical team.

The lateral cephalometric radiographs were taken by the same operator on the same machine at three time points (Table 1):

- T1: Pretreatment;
- T2: Immediate preoperative (2–4 days before surgery for surgical planning);
- T3: Posttreatment (following the removal of fixed orthodontic appliances, at least 10 months after surgery).

Cephalometric Analysis

Cephalograms were obtained under standardized conditions. Patients were in centric occlusion, and a relaxed lip position was obtained by requesting the patients to gently stroke their lips and relax.⁴ This was repeated several times to ensure a relaxed position without any muscular contraction.

Lateral cephalograms were traced, and cephalometric reference points were determined using acetate tracing paper. The SN plane was taken as the horizontal reference plane (HR), and the perpendicular to the SN plane through the S point was taken as the vertical reference plane (VR). These reference planes were used as guides in measuring the projected distances of the reference landmarks. Twenty-two landmarks were digitized and 32 variables analyzed using the PorDios (Purpose on Request Digitizer Input Output System, trademark of the Institute of Orthodontic Computer Science, Aarhus, Denmark) cephalometric analysis program (Figures 1 and 2).

The upper and lower lip areas were measured in mm² on the lateral cephalograms using a digital planimeter (Ushikata X-Plan380dIII/460dIII, Tokyo, Japan) (Figure 3a, b). The upper lip was divided into two

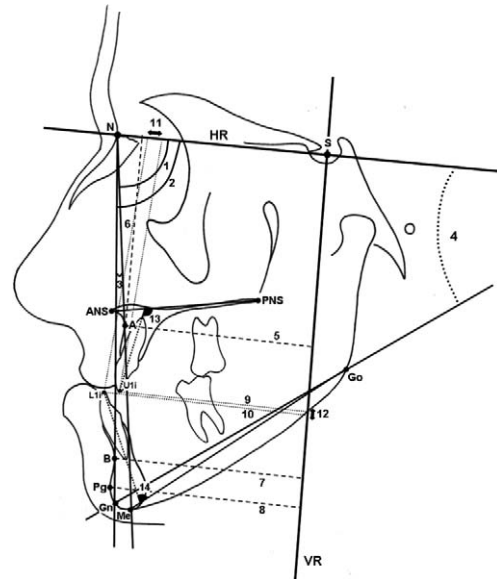


Figure 1. Skeletal measurements: 1: SNA; 2: SNB; 3: ANB; 4: SN/GoGn; 5: A-VR; 6: A-HR; 7: B-VR; 8: Pg-VR. Dental measurements: 9: U1i-VR; 10: L1i-VR; 11: Overjet; 12: Overbite; 13: U1/ANS-PNS; 14: L1/Me-Go.

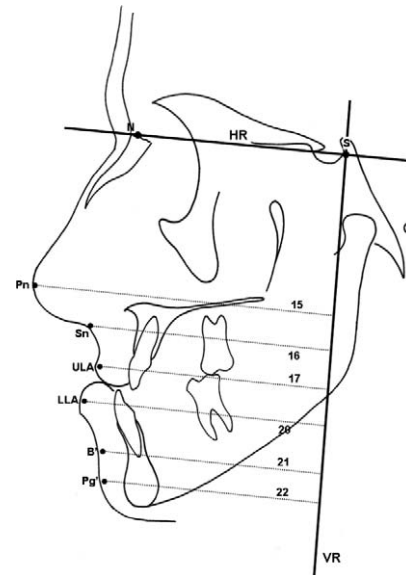


Figure 2. Upper lip-related soft tissue measurements: 15: Pn-VR; 16: Sn-VR; 17: ULA-VR. Lower lip-related soft tissue and skeletal measurements: 20: LLA-VR; 21: B'-VR; 22: Pg'-VR.

parts (Area 1 and 2) and the lower lip was divided into three parts (Area 3, 4, and 5) (Figure 4).

Statistical Analysis

Statistical analysis was performed using the Minitab statistical software package (Minitab Statistical Software Release 13 for Windows). Analysis of variance (ANOVA) and Duncan tests were used to compare the cephalometric and planimetric measurements of bi-

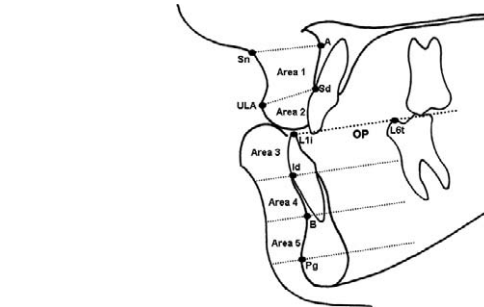
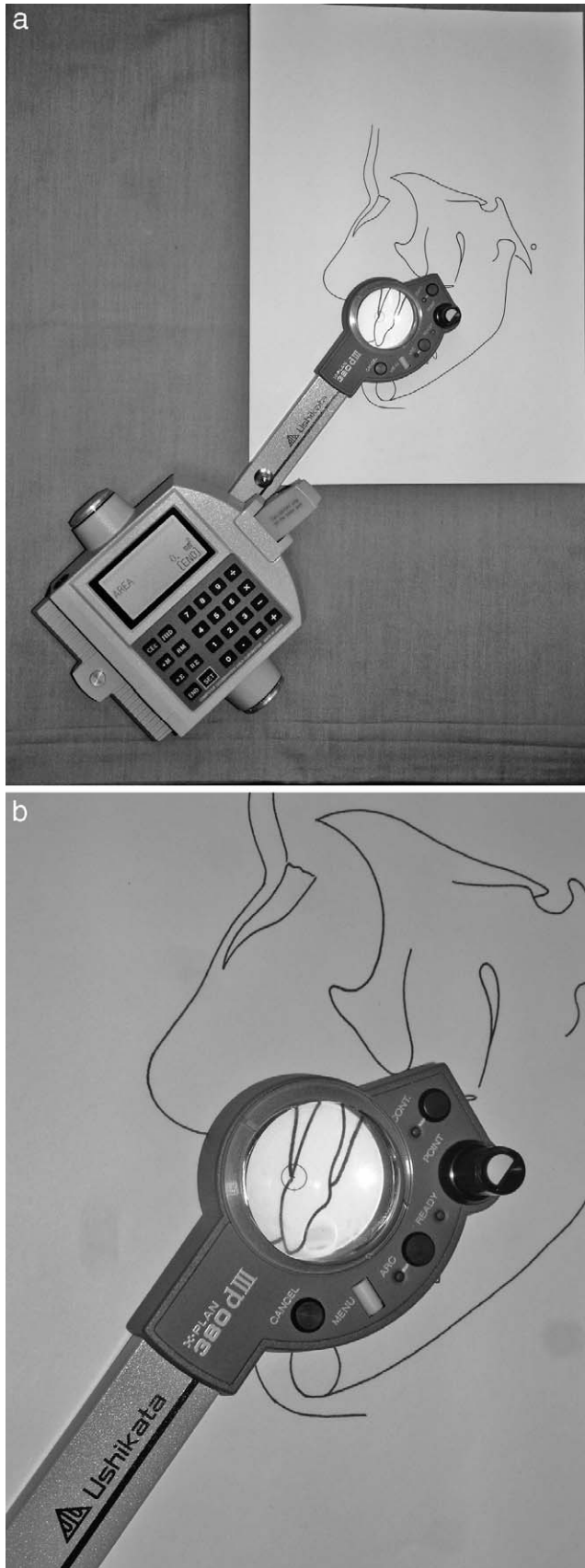


Figure 4. Area measurements: The upper lip was divided into two parts (Area 1 and 2). 18: Area 1: superior upper labial area; the area between point A, subnasal, upper lip anterior and supradental point. 19: Area 2: inferior upper labial area; the area below supradental and upper lip anterior line. The lower lip was divided into three parts (Area 3, 4, and 5) from the incisal edge of the mandibular central incisor (L1), infradentale (Id), B point, and pogonion point. Lines dividing the lower lip area were constructed parallel to the mandibular occlusal plane. 23: Area 3: superior lower labial area; 24: Area 4: middle lower labial area; 25: Area 5: inferior lower labial area.

maxillary orthognathic surgery patients at the beginning of treatment, and before and after surgery (Tables 2 and 3). Paired *t*-tests were also performed to analyze changes within the observation periods (Table 3).

The relationship of linear sagittal changes in soft-tissue variables to the repositioning of skeletal landmarks was expressed using the following formula (Table 4):

$$\frac{T3-T2 \text{ mean of soft tissue changes}}{T3-T2 \text{ mean of skeletal changes}} = \text{Ratio}$$

Error Study

Cephalometric landmarks of a radiograph are digitized twice and the program (PorDios) automatically rejects the digitizing procedure if the two digitized points do not match. Area measurements were repeated three times by the same investigator, and the average values of the three measurements were calculated to eliminate errors in measurement.

RESULTS

The comparison of the mean values and standard error of means of the soft tissue and skeletal variables between three different observation periods of the treatment are presented in Table 2. The most significant differences in skeletal variables were observed in SNA ($P < .001$), subsequently in ANB ($P < .001$), and A-VR ($P < .05$). The differences in dental measurements were seen in U1i-VR ($P < .05$), L1/Me-Go ($P < .01$), and overjet ($P < .001$). The soft tissue variables differed from

←

Figure 3. (a) Digital planimeter. (b) Measurement of the areas using the digital planimeter.

Table 2. Comparison of the Mean Values of the Soft and Skeletal Tissue Variables at the Beginning of Treatment (T1), End of Presurgical Orthodontics (T2), and at the End of Treatment (T3) by Analysis of Variance (ANOVA) and Duncan Test^a

Parameters	T1 Pretreatment		T2 Presurgery		T3 Posttreatment		Test	1-2	2-3	1-3
	X	±Sx	X	±Sx	X	±Sx				
Skeletal Measurements										
1. SNA, degrees	78.16	0.71	78.08	0.72	81.39	0.63	***		***	***
2. SNB, degrees	83.27	0.81	82.98	0.89	81.23	0.74				
3. ANB, degrees	-5.11	0.56	-4.90	0.66	0.15	0.39	***		***	***
4. SN/GoGn, degrees	38.05	1.03	38.42	0.93	37.2	0.93				
5. A-VR	57.03	1.07	57.28	1.19	60.83	1.00	*		*	*
6. A-HR	63.86	0.75	64.59	0.80	65.14	0.97				
7. B-VR	56.91	1.71	57.02	1.86	53.81	1.49				
8. Pg-VR	57.03	1.93	57.03	2.09	54.69	1.78				
Dental Measurements										
9. U1i-VR	58.34	1.32	58.54	1.38	62.91	1.37	*		*	*
10. L1i-VR	62.81	1.51	64.85	1.77	60.18	1.32				
11. Overjet	-5.65	0.63	-7.28	0.63	3.42	0.18	***		***	***
12. Overbite	-0.22	0.68	1.05	0.62	0.19	0.17				
13. U1/ANS-PNS, degrees	27.86	1.29	28.47	1.51	24.92	1.36				
14. L1/Me-Go, degrees	18.51	1.71	25.48	1.83	17.12	1.61	**	**	**	
Upper Lip Measurements										
15. Pn-VR	95.12	1.21	95.54	1.24	96.44	1.14				
16. Sn-VR	76.42	1.20	76.63	1.27	78.05	1.06				
17. ULA-VR	75.50	1.45	76.09	1.64	78.26	1.41				
18. Area 1	231.78	8.91	240.99	9.75	220.04	9.96				
19. Area 2	116.04	6.82	118.01	6.99	95.70	6.10	*		*	*
Lower Lip Measurements										
20. LLA-VR	76.54	1.69	78.22	2.01	74.88	1.56				
21. B'-VR	69.41	1.80	69.31	2.01	65.97	1.55				
22. Pg'-VR	68.75	1.95	68.70	2.10	66.79	1.65				
23. Area 3	190.80	10.6	184.7	13.1	142.85	9.97	**		**	**
24. Area 4	129.38	6.39	129.85	7.45	142.23	5.38				
25. Area 5	166.35	7.94	184.85	9.98	203.7	10.7	*			*

* $P < .05$; ** $P < .01$; *** $P < .001$.

^a X indicates mean; Sx, the error of mean.

each other at Area 2 ($P < .05$), Area 3 ($P < .01$), and Area 5 ($P < .05$) between the three observation periods.

In Table 3, the changes between observation periods as couples (paired t -test; T2-T1, T3-T1 and T3-T2) are presented, but the comparison between those couples are evaluated (ANOVA and Duncan test). There were significant differences between presurgery (T1 and T2) and posttreatment (T3) stages for almost all variables. As the mean values of the variables were more or less similar in T1 and T2, almost no difference in comparison of those time-points with posttreatment was observed (B-C). The only variable which was different in the comparison of B-C was Area 5.

The ratios of the changes between the skeletal and corresponding soft tissue variables are presented in Table 4. This table shows the changes between T2 (presurgery) and T3 (posttreatment). Pronasale was affected less with the movement of the underlying skeletal structure (0.25%), while soft tissue B point (B') moved equally with skeletal B point as a result of the mandibular setback (1.04%). When the ratios in Table

4 are evaluated as a whole, the soft tissues are affected less in the nasal area and the soft tissue improvement increases gradually as we move to the labiomental and chin areas.

Table 5 gives us the comparison between the area measurements and the corresponding linear soft and skeletal tissue variables. As the maxilla and maxillary dentoalveolar structures moved forward, the upper labial areas (Area 1 and 2) decreased. The middle and inferior lower labial areas (Areas 4 and 5) increased with the backward movement of the mandible. Area 3 (superior lower labial area) decreased, however, and the lower incisors (L1i-VR) and lower lip (LLA-VR) moved backward at the end of the treatment.

DISCUSSION

The relatively small sample size of the present study (20 individuals: 9 male and 11 female) is a result of the strict selection criteria applied so as to eliminate some of the drawbacks of the retrospective study design.

Table 3. Comparison of the Cephalometric and Planimetric Changes Occurred During Presurgical Orthodontics (A; T2-T1), Between Pre-treatment and Posttreatment Periods (B; T3-T1), and Presurgery and Posttreatment Periods (C; T3-T2), by Analysis of Variance (ANOVA) and Duncan tests. Paired *t*-Tests Were Also Performed to Analyze Changes Within the Groups^a

Parameters	A		B		C		Test	A-B	B-C	A-C
	T2-T1		T3-T1		T3-T2					
	D	±Sd	D	±Sd	D	±Sd				
Skeletal Measurements										
1. SNA, degrees	-0.08	0.32	3.23***	0.44	3.30***	0.44	***	***		***
2. SNB, degrees	-0.28	0.30	-2.03***	0.39	-1.75***	0.28	***	***		***
3. ANB, degrees	0.20	0.38	5.25***	0.38	5.05***	0.46	***	***		***
4. SN/GoGn, degrees	0.37	0.32	-0.85	0.70	-1.23	0.68				
5. A-VR	0.25	0.36	3.80***	0.49	3.55***	0.46	***	***		***
6. A-HR	0.72	0.36	1.28*	0.57	0.56	0.50				
7. B-VR	0.11	0.62	-3.10***	0.80	-3.21***	0.72	**	**		**
8. Pg-VR	0.01	0.77	-2.34*	0.99	-2.35*	0.86				
Dental Measurements										
9. U1i-VR	0.21	0.51	4.58***	0.63	4.37***	0.40	***	***		***
10. L1i-VR	2.04**	0.68	-2.63**	0.79	-4.67***	0.83	***	***		***
11. Overjet	-1.63**	0.54	9.07***	0.63	10.70***	0.68	***	***		***
12. Overbite	1.27**	0.38	0.41	0.71	-0.86	0.64	*			*
13. U1/ANS-PNS, degrees	0.61	1.28	-2.94*	1.30	-3.55***	0.76	*	*		*
14. L1/Me-Go, degrees	6.97***	1.52	-1.39	1.24	-8.36***	1.25	***	***		***
Upper Lip Measurements										
15. Pn-VR	0.42	0.35	1.32**	0.36	0.90**	0.30				
16. Sn-VR	0.21	0.30	1.63***	0.41	1.42***	0.35	*	*		*
17. ULA-VR	0.59	0.53	2.77***	0.48	2.18***	0.50	*	*		*
18. Area 1	9.21	5.34	-11.74	6.72	-20.95*	8.06	**	**		**
19. Area 2	1.96	4.78	-20.35***	3.50	-22.31***	4.68	***	***		***
Lower Lip Measurements										
20. LLA-VR	1.68*	0.65	-1.66*	0.67	-3.34***	0.62	***	***		
21. B'-VR	-0.10	0.59	-3.43***	0.86	-3.33***	0.79	**	**		**
22. Pg'-VR	-0.05	0.82	-1.96	0.96	-1.91*	0.75				
23. Area 3	-6.10	8.15	-47.90***	10.2	-41.80*	15.7	**	**		**
24. Area 4	0.47	6.86	12.86	6.24	12.39*	5.49				
25. Area 5	18.50***	4.60	37.32	5.10	18.82***	3.99	**		**	**

* $P < .05$; ** $P < .01$; *** $P < .001$.

^a D indicates mean of differences; Sd, standard error of the differences.

Table 4. The Ratios of the Movements of the Skeletal and Soft Tissue Variables Following Bimaxillary Orthognathic Surgery (T2-T3)

	Soft Tissue (S)		Hard Tissue (H)		Ratio (S:H), %
	D		D		
Maxillary variables					
Pn-VR	0.90**	A-VR	3.55***		0.25
Sn-VR	1.42***	A-VR	3.55***		0.40
ULA-VR	2.18***	A-VR	3.55***		0.61
ULA-VR	2.18***	U1i-VR	4.37***		0.50
Mandibular variables					
LLA-VR	-3.34***	L1i-VR	-4.67***		0.72
B'-VR	-3.33***	B-VR	-3.21***		1.04
Pg'-VR	-1.91*	Pg-VR	-2.35*		0.81

* $P < .05$; ** $P < .01$; *** $P < .001$.

^a D indicates mean of differences.

Improvements in skeletal and soft tissue variables following bimaxillary orthognathic surgery were achieved in all patients included in this study. Post-surgical evaluation was assessed using lateral cephalometric radiographs taken at the end of treatment (10–14 months post surgery), and no edema was recorded clinically in any of the patients.^{5,6}

In the present study, the use of any variable related to the anterior nasal spine was avoided as maxillary surgery will often alter that landmark. Alteration of point A was also a possibility⁵; however, no clinical or radiographic damage was observed in that area, thus providing some reassurance for the use of point A as a landmark.

Treatment outcomes were evaluated by comparing immediate presurgery (T2) cephalograms, in which the dentoalveolar structures were decompensated, with posttreatment (T3) cephalograms. Pretreatment (T1) radiographs were also used in order to overcome mis-

Table 5. The Relationship Between Linear Soft Tissue and Skeletal Tissue Movements of Maxillary-Mandibular Components and Upper-Lower Lip Areas Following Bimaxillary Orthognathic Surgery (T3-T2)

		Soft Tissue		Hard Tissue		Soft Tissue		
		D		D		D		
Maxillary variables								
Area 1	↓	-20.95*	A-VR	↑	3.55***	Sn-VR	↑	1.42***
Area 2	↓	-22.31***	U1i-VR	↑	4.37***	ULA-VR	↑	2.18***
Mandibular variables								
Area 3	↓	-41.80*	L1i-VR	↓	-4.67***	LLA-VR	↓	-3.34***
Area 4	↑	12.39*	B-VR	↓	-3.21***	B'-VR	↓	-3.33***
Area 5	↑	18.82***	Pg-VR	↓	-2.35*	Pg'-VR	↓	-1.91*

* $P < .05$; ** $P < .01$; *** $P < .001$.

^a D indicates means of differences; Sd, standard error of the differences.

interpretations resulting from the presence of brackets, which may present a problem in any study evaluating soft tissue changes, especially in the lips.

Recent cephalometric investigations have found that movements of hard and soft tissue after orthognathic operations were strongly correlated horizontally, but not vertically,⁷ and that the position of the lips could not be predicted accurately.⁸ In the present study, in order to provide a better assessment of lip response to hard tissue changes, the areas were examined and linear horizontal changes used to establish a better relationship between area measurements. The vertical position of point A (A-HR) is included in Tables 2 and 3 to indicate that no maxillary superior repositioning was planned or performed in any of the patients.

Several ratios have been presented over the years by a number of workers, but most of these were related to maxillary or mandibular surgery alone.⁹⁻¹² It is commonly believed that changes following bimaxillary surgery are similar to changes following the separate performance of the two procedures.¹ However, more significant differences have been reported in soft tissue changes among bimaxillary patients than single-jaw surgery patients,¹³ and prediction errors have been found to be more common among bimaxillary osteotomy patients than single-jaw osteotomy patients.¹⁴ Posposil¹⁴ explained the disparity as due to the dramatic soft tissue changes following bimaxillary surgeries, especially in skeletal Class III dysgnathia cases. We also felt it necessary to separately evaluate bimaxillary surgeries and support our proportional findings with the results of changes in area.

The results of this study support the findings of previous studies showing the ratio of maxillary soft tissue improvement to be lower than that of mandibular soft tissue improvement following bimaxillary surgery (Table 4).^{8,7,15,16} Previous studies on single-jaw and bimaxillary surgery have explained the weaker soft tissue response following maxillary hard tissue advancement to be related to the resection of the anterior nasal

spine area during the Le Fort I osteotomy and the variability in surgical closure of the soft tissue incision in maxillary surgery.^{6,7,15-18}

In agreement with the present study, the forward movement of the tip of the nose (Pn-VR) and subnasal area (Sn-VR) was previously reported to be less than that of the upper lip (Table 4).^{10,11} Epker et al¹⁹ reported that less advancement will produce less effect on the nasal tip, whereas more advancement will not produce more effect. The authors also reported that nasal tip projection is affected only by the management of the nasal septum at surgery.¹⁹ It has also been reported that the nose tip change following maxillary advancement surgery is usually temporary.²⁰

We recorded significant reductions in the upper lip areas (Table 5; Area 1 and 2), despite significant forward movement in both the maxillary base and the upper lip.^{6,10,21} Bays et al²¹ reported upper lip compression and thinning as a result of anterior repositioning of the maxilla. It has also been suggested that thin lips tend to follow the hard tissue more closely than thick lips.^{22,23}

The variability of soft tissue changes after maxillary surgery is related to the differential response of various parts of the soft tissues, wide individual variation in surgical wound healing, and surgical technique. Since the surgical site is much closer to the upper lip in maxillary surgery than in mandibular surgery, it is not surprising that scarring of the upper incision during wound healing would have a much greater affect on the upper lip area than on the lower lip and chin area. Additionally, firm attachment to the base of the nose prevents the proportional horizontal and vertical movement of the upper lip in correspondence with hard tissue movement.^{11,16}

It should also be remembered that the upper lip may be supported by the lower incisors in presurgical patients exhibiting sagittal maxillary deficiency. In such cases, advancement of the maxilla will not displace the upper lip in proportion to the anterior maxillary move-

ment.²¹ Stella et al²³ mentioned a dead space, which is most noticeable in more severely maxillary retrognathic patients, where an actual air pocket exists between the maxillary dentoalveolar structures and the upper lip mucosa. The authors suggested that a maxilla advanced into this dead space would show no change in soft tissue contours.²³

The ratios of the anteroposterior movements of the soft to hard tissue variables of the mandible are in general agreement with previous studies (for the ratio of lower lip to mandibular incisal tip [0.72%]^{7,11,24}; for soft tissue to hard tissue B points [1.04%]^{7,24,25}; and for soft and hard tissue pogonion [0.81%]⁷) (Table 4). The relationship between the soft to hard tissue B point has been observed to be the most creditable, but the relationship between soft and hard tissues gradually decreases at the level of the lower incisor and pogonion. Although the Area 5 increases significantly at the pogonion level, the ratio is smaller compared to point B.^{25,26} Stella et al²³ and Gjørup and Athanasiou²⁵ suggested that soft tissues at the chin are significantly influenced by preoperative thickness of the area. The adaptation of mental and superhyoid muscles to the new position of the mandible may offer an additional explanation for that finding.

The most significant relationship between soft-to-hard tissues was observed at the lower incisor level. In contrast to the increases in Areas 4 and 5, the area related to the lower incisors (Area 3) decreased significantly at the end of treatment (Table 5). The lower lip is morphologically different from other soft tissue landmarks. It is pliable, directly influenced by the movements of maxillary and mandibular incisors, perioral muscles and underlying muscle attachments, and its thickness-tonicity differs among individuals.²⁷ The significant decrease found in the superior lower lip area is likely attributable to overjet changes in correction of severe malocclusion.²⁸ It is most likely that the retruded position of the maxillary and mandibular incisors prior to surgery created an increase and anterior curve in the pliable part of the lower lip (Area 3) that was relatively decreased by surgery. The initial increase in the lower lip area could also be explained by the effort to assure mouth closure in severe Class III malocclusions.³ The stretching of the upper lip following maxillary advancement might have affected the reduction in Area 3. Regardless of the cause, it is likely that the decrease in lower lip area holds the key to the improvement of facial esthetics in severe Class III patients.

CONCLUSIONS

- The dramatic improvement in facial profiles of bimaxillary surgery patients is primarily related to

backward movement of the mandible and significant reduction in the lower lip area.

- Decreases in the superior lower lip area should be considered during surgical planning for Class III patients so as not to worsen the soft tissue profile.
- Because maxillary advancement does not significantly improve nose/upper lip tissues, it should be avoided in borderline Class III patients, who would benefit from a mandibular setback alone.

REFERENCES

1. Proffit WR. Treatment planning: the search for wisdom. In: Proffit WR, White RP Jr, eds. *Surgical Orthodontic Treatment*. St Louis, Mo: Mosby-Year Book; 1991:142–191.
2. Verdonck A, Jorissen E, Carels C, Van Thillo J. The interaction between soft tissues and the sagittal development of the dentition and the face. *Am J Orthod Dentofacial Orthop*. 1993;104:342–349.
3. Toygar UT, Akcam MO, Arman A. A cephalometric evaluation of lower lip in patients with unilateral cleft and palate. *Cleft Palate Craniofac J*. 2004;41:485–489.
4. Burstone CJ. Lip posture and its significance in treatment planning. *Am J Orthod*. 1967;53:262–284.
5. Bailey LTJ, Collie FM, White RP Jr. Long-term soft tissue changes after orthognathic surgery. *Int J Adult Orthodon Orthognath Surg*. 1996;11:7–18.
6. Enacar A, Ugur Taner T, Toroglu S. Analysis of soft tissue profile changes associated with mandibular setback and double-jaw surgeries. *Int J Adult Orthodon Orthognath Surg*. 1999;14:27–35.
7. Chew MT. Soft and hard tissue changes after bimaxillary surgery in Chinese Class III patients. *Angle Orthod*. 2005;75:959–963.
8. Koh CH, Chew MT. Predictability of soft tissue profile changes following bimaxillary surgery in skeletal Class III Chinese patients. *J Oral Maxillofac Surg*. 2004;62:1505–1509.
9. Hershey HC, Smith LH. Soft tissue profile change associated with surgical correction of the prognathic mandible. *Am J Orthod*. 1974;65:483–502.
10. Dann JJ 3rd, Fonseca RJ, Bell WH. Soft tissue changes associated with total maxillary advancement: a preliminary study. *J Oral Surg*. 1976;34:19–23.
11. Lines PA, Steinhauser WW. Soft tissue changes in relationship to movement of hard structures in orthognathic surgery: preliminary report. *J Oral Surg*. 1974;32:891–896.
12. Turvey TA, White RP Jr. Maxillary surgery. In: Proffit WR, White RP Jr, eds. *Surgical Orthodontic Treatment*. St Louis, Mo: Mosby-Year Book; 1991:248–263.
13. Eckhardt CE, Cunningham SJ. How predictable is orthognathic surgery? *Eur J Orthod*. 2004;26:303–309.
14. Posposil OA. Reliability and feasibility of prediction tracing in orthognathic surgery. *J Craniomaxillofac Surg*. 1987;15:79.
15. Jensen AC, Sinclair PM, Wolford LM. Soft tissue changes associated with double jaw surgery. *Am J Orthod Dentofacial Orthop*. 1992;101:266–275.
16. Lin SS, Kerr WJS. Soft and hard tissue changes in Class III patients treated by bimaxillary surgery. *Eur J Orthod*. 1998;20:25–33.
17. Mansour S, Burstone C, Legan H. An evaluation of soft tissue changes resulting from Le Fort I maxillary surgery. *Am J Orthod*. 1983;84:37–47.
18. Rosen HM. Lip-nasal aesthetics following Le Fort I osteotomy. *Plast Reconstr Surg*. 1988;81:171–179.

19. Epker BN, Stella JP, Fish LC, eds. Maxillary deficiency. Chapter 11, In: *Dentofacial Deformities. Integrated Orthodontic and Surgical Correction*. Vol 1. St Louis, MO: Mosby Year Book; 1986:492–538.
20. Turvey TA, White RP. Maxillary surgery. In: Proffit WR, White RP, eds. *Surgical Orthodontic Treatment*. St Louis, Mo: Mosby-Year Book; 1991:248–263.
21. Bays RA, Hegtvedt AK, Timmis DP. Maxillary Orthognathic surgery. In: Peterson LJ, ed. *Principles of Oral and Maxillofacial Surgery*. Philadelphia, Pa: Lippincott-Raven Publishers; 1997:1373–1376.
22. Oliver BM. The influence of lip thickness and strain on upper lip response to incisor retraction. *Am J Orthod*. 1982;82:141.
23. Stella JP, Streater MR, Epker BN, Sinn DP. Predictability of upper lip soft tissue changes with maxillary advancement. *J Oral Maxillofac Surg*. 1989;47:697–703.
24. Suckiel JM, Kohn MW. Soft tissue changes related to the surgical management of mandibular prognathism. *Am J Orthod*. 1978;73:676–680.
25. Gjørup H, Athanasiou AE. Soft-tissue and dentoskeletal profile changes associated with mandibular setback osteotomy. *Am J Orthod Dentofacial Orthop*. 1991;100:312–323.
26. Gaggl A, Schultes G, Karber H. Changes in soft tissue profile after sagittal split ramus osteotomy and retropositioning of the mandible. *J Oral Maxillofac Surg*. 1999;57:542.
27. Lu CH, Ko EWC, Huang CS. The accuracy of video imaging prediction in soft tissue outcome after bimaxillary orthognathic surgery. *J Oral Maxillofac Surg*. 2003;61:333–342.
28. Sarver DM, Weissman SM. Long-term soft tissue response to Le Fort I maxillary superior repositioning. *Angle Orthod*. 1991;61:267–276.