

Musculoskeletal Complications of Diabetes Mellitus

Rachel Peterson Kim, MD; Steven V. Edelman, MD; and Dennis D. Kim, MD

D iabetes may affect the musculoskeletal system in a variety of ways. The metabolic perturbations in diabetes (including glycosylation of proteins; microvascular abnormalities with damage to blood vessels and nerves; and collagen accumulation in skin and periarticular structures) result in changes in the connective tissue.

Musculoskeletal complications are most commonly seen in patients with a longstanding history of type 1 diabetes, but they are also seen in patients with type 2 diabetes. Some of the complications have a known direct association with diabetes, whereas others have a suggested but unproven association. This article will review the musculoskeletal and rheumatological manifestations commonly seen in patients with diabetes (Table 1).

Hands

Hands are a target for several diabetes-related complications. Diabetic cheiroarthropathy, also known as diabetic stiff hand syndrome or limited joint mobility syndrome, is found in 8–50% of all patients with type 1 diabetes and is also seen in type 2 diabetic patients. The prevalence increases with duration of diabetes. This condition is associated with and predictive of other diabetic complications.

This syndrome is characterized by thick, tight, waxy skin reminiscent of scleroderma. Limited joint range of motion (inability to fully flex or extend the fingers) and sclerosis of tendon sheaths are also seen. The underlying cause is thought to be multifactorial. Increased glycosylation of collagen in the skin and periarticular tissue,

decreased collagen degradation, diabetic microangiopathy, and possibly diabetic neuropathy are thought to be some of the contributing factors. Flexion contractures of the fingers may develop at advanced stages. One indication of the presence of this condition is known as the “prayer sign” (Fig. 1). This is patients’ inability to press their palms together completely without a gap remaining between opposed palms and fingers.

The specific treatment of diabetic cheiroarthropathy (other than optimizing glycemic control) is unknown.

Flexor tenosynovitis (or trigger finger) is another frequent diabetic compli-

cation of the hands (Fig. 2). Patients complain of a catching sensation or locking phenomenon that may be associated with pain in the affected fingers. Examination shows a palpable nodule, usually in the area overlying the metacarpophalangeal joint, and thickening along the affected flexor tendon sheath on the palmar aspect of the finger and hand. Also, the locking phenomenon may be reproduced with either active or passive finger flexion.

This complication is thought to have the same pathogenesis as diabetic cheiroarthropathy, and its prevalence is similarly related to the duration of diabetes.

Initial treatment involves injecting local corticosteroids into the tendon sheath. If this is unsuccessful, patients will most likely need to see a hand surgeon for a minor operation that can provide permanent relief. (A small transverse incision just distal to the flexion crease over the metacarpal head exposes the flexor tendons and sheath. A complete longitudinal incision along the thickened fibrous tendon sheath relieves the constriction and allows the finger to move freely.)

Dupuytren’s contracture results from a thickening, shortening, and fibrosis of the palmar fascia. Nodule formation along the fascia is seen. Flexion contractures of the fingers may result, usually at the fourth finger, but sometimes involving any of the second through fifth digits. Dupuytren’s contracture has been reported in 16–42% of diabetic patients. Its pathogenesis is thought to be the same as that for cheiroarthropathy.

Once again, the prevalence of this condition increases with disease dura-

Table 1. Musculoskeletal and Rheumatological Complications of Diabetes

Conditions Affecting the Hands

- Diabetic cheiroarthropathy (stiff hand syndrome or syndrome of limited joint mobility)
- Flexor tenosynovitis (trigger finger)
- Dupuytren’s contracture
- Carpal tunnel syndrome

Conditions Affecting the Shoulders

- Adhesive capsulitis (frozen shoulder)
- Calcific periarthritis
- Reflex sympathetic dystrophy

Conditions Affecting the Feet

- Diabetic osteoarthropathy (Charcot or neuropathic arthropathy)

Conditions Affecting the Muscles

- Diabetic muscle infarction

Conditions Affecting the Skeleton

- Diffuse idiopathic skeletal hyperostosis (DISH)

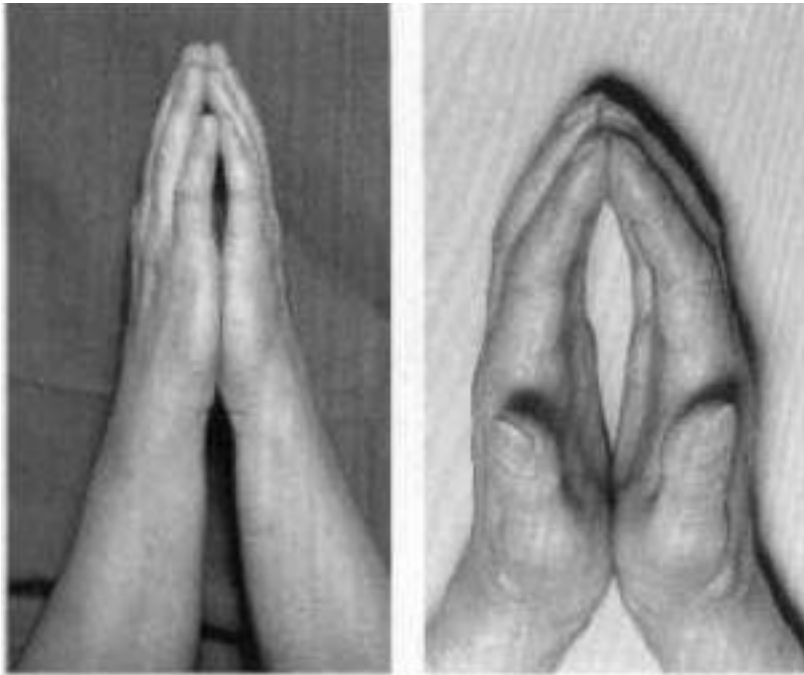


Figure 1. The “prayer sign” indicates the presence of diabetic cheiroarthropathy. It is characterized by patients’ inability to completely close gaps between opposed palms and fingers when pressing their hands together.




Figure 2. This patient with flexor tenosynovitis (trigger finger) is trying to straighten out all of his fingers, but the middle finger is locked.

tion, but Dupuytren’s contracture may also be seen early in the course of disease. Physical therapy may be beneficial for early or mild cases. Varied success has been reported with local corticosteroid injections. Surgical intervention may be needed for severe cases.

Carpal tunnel syndrome (CTS) is seen in up to 20% of diabetic patients. Its specific relationship to diabetes is thought to be median nerve entrapment caused by the diabetes-induced connective tissue changes mentioned above. The prevalence of CTS in diabetic patients generally increases with duration of diabetes.

CTS is usually diagnosed based on patients’ history and clinical findings. Classically, patients complain of burning, paresthesias, or sensory loss in the median nerve distribution (the first three fingers as well as the radial half of the fourth finger). They may also complain of pain in the same area, often with radiation proximally into the forearm and arm. The pain may awaken patients from sleep and is aggravated by activities involving wrist flexion or extension, such as holding a newspaper or book, typing, driving, or using a knife and fork.

Tinel’s sign (tapping over the median nerve on the volar aspect of the wrist) may be helpful in diagnosis but is not universally positive. A positive Tinel’s sign produces paresthesias distally in the hand. Phalen’s test (the wrist flexion test) may also assist in diagnosis, but like Tinel’s sign, it is somewhat variable. Patients are asked to flex both wrists so that the dorsa of both hands are touching and to hold that position for 30–60 sec. A positive Phalen’s test consists of paresthesias being reproduced in the hand with this maneuver.

It is also important to examine patients for possible motor weakness caused by median nerve compression. This is done by assessing thenar muscle strength and examining the hand for the presence of thenar muscle atrophy.

Awareness on the part of the clinicians is necessary in order to intercede in

CTS before the development of thenar muscle atrophy. Diabetic patients may have paresthesias caused by underlying peripheral neuropathy, and these two entities must be differentiated.

Electromyogram/nerve conduction velocity (EMG/NCV) testing can confirm the diagnosis of CTS in uncertain cases and can also help to localize the site of nerve entrapment. If more proximal entrapment is a concern, imaging studies of the cervical region should also be completed.

Management of CTS is the same for diabetic patients as for nondiabetic patients. Conservative treatment is tried initially for early or mild cases, using volar wrist splints (particularly at night) with or without nonsteroidal anti-inflammatory drugs (NSAIDs). Ergonomic adjustment of computer workstations should be made when appropriate. Local corticosteroid injection of the carpal tunnel may be tried as well. Patients with severe or refractory cases, as well as those with thenar atrophy or progressive neurological changes on serial EMG/NCV testing, should be sent for definitive therapy with surgical release of the transverse carpal ligament by a hand surgeon.

Shoulders

Diabetes can affect the shoulder in several ways. First, adhesive capsulitis, or frozen shoulder, has been reported in 19% of diabetic patients. This term refers to a stiffened glenohumeral joint usually caused by a reversible contraction of the joint capsule. Patients report shoulder stiffness, along with decreased range of motion. Therapy is largely conservative and involves minimizing over-immobilization (gentle stretching/range of motion exercises) and the use of analgesics and/or intra-articular injections.

Calcific periarthritis of the shoulder is also seen in diabetes, where it is roughly three times more common than in people without diabetes. Shoulder radiographs show calcium deposits outside of the joint, often in the area of the rotator cuff tendons. However, in up to

two-thirds of the cases, this condition is asymptomatic in patients with diabetes.

Reflex sympathetic dystrophy, also known as "shoulder-hand syndrome," is seen in diabetic patients, although whether it occurs with increased frequency is controversial. It may be associated with adhesive capsulitis (with or without calcific periarthritis).

Patients may complain of pain from shoulder to hand in the affected limb. Classical examination findings include swelling of the affected limb/area, skin changes (changes in hair growth, shiny skin, color and temperature changes), increased sensitivity to temperature and touch (hyperesthesia), and vasomotor instability. Transient, patchy osteoporosis is also often seen. Early intervention is important. NSAIDs, other analgesics, and corticosteroids have been used along with physical therapy, and sympathetic blocks may be helpful.

Feet

Diabetic osteoarthropathy (also known as Charcot or neuropathic arthropathy) is a condition involving destructive, lytic joint changes. It is a severe, destructive form of degenerative arthritis resulting from a loss of sensation (brought on by underlying diabetic neuropathy) in the involved joints. It most commonly affects the pedal bones. Loss of sensation leads to inadvertent (and unnoticed) repeated microtrauma to the joints, which leads to degenerative changes.

The condition is quite rare, affecting only 0.1–0.4% of diabetic patients, and is seen in both type 1 and type 2 diabetes. The average duration of disease in affected patients is 15 years.

Physical examination will invariably demonstrate peripheral neuropathy. There may be skin such as erythema, swelling, hyperpigmentation or purpura, and soft-tissue ulcers over the affected area, as well as joint loosening or instability and joint deformities.

The diagnosis is made based on radiographic findings, with symptoms often milder than would be expected based on the radiographs. There is usually no his-

tory of overt trauma.

Depending on the stage and severity of the arthropathy, radiographs can show degenerative changes with subluxation, bone fragments, osteolysis, periosteal reaction, deformity, and/or ankylosis. Computed tomography (CT) scans are insensitive when evaluating for disease activity, whereas magnetic resonance imaging (MRI) and bone scintigraphy studies are valuable adjuncts to plain films in this regard. The differential diagnosis includes infection, inflammatory processes, degenerative processes, tumor, deep venous thrombosis or thrombophlebitis, and neuropathic arthropathies secondary to other conditions. Diabetic peripheral neuropathy is thought to play the greatest pathogenic role in diabetic osteoarthropathy.

Treatment is generally conservative and unsatisfactory, involving both splinting/bracing to protect the area from weight bearing and good glycemic control. Podiatrists sometimes use a total-contact cast for acute Charcot joints. This must be applied by an experienced cast technician and monitored and changed frequently. Unfortunately, it carries a fairly high risk of causing new injuries and ulcers because of the tight fit and patients' underlying neuropathy. Broad-spectrum empiric antibiotics are also frequently used when skin ulcers accompany the arthropathy.

Muscles

Diabetic muscle infarction is a rare condition. This spontaneous infarction, with no history of trauma, tends to affect patients with a long history of poorly controlled diabetes. It is seen more commonly in patients with insulin-requiring diabetes, and most affected patients have multiple microvascular complications (neuropathy, nephropathy, and retinopathy).

The clinical presentation is an acute onset of pain and swelling over days to weeks in the affected muscle groups (usually the thigh or calf) along with varying degrees of tenderness. Creatinine phosphokinase levels may be nor-

mal or elevated. Otherwise, laboratory investigations are done to exclude other conditions, such as tumor, muscle infection/abscess, thrombophlebitis/thrombosis, localized myositis, or osteomyelitis.

CT scans are nonspecific. MRI may show high signals of the involved muscle on T2-weighted images.

Incisional muscle biopsy may be needed to confirm the diagnosis. The primary findings on biopsy are muscle edema and necrosis. Excisional muscle biopsy may worsen the condition and should only be done to rule out infection or malignancy.

Therapy consists of rest and analgesia. Routine daily activities are not deleterious to the condition, but physical therapy may cause exacerbation. Spontaneous diabetic muscle infarction tends to resolve over a period of weeks to months in most cases.

Skeleton

Diffuse idiopathic skeletal hyperostosis (DISH) is characterized by metaplastic calcification of spinal ligaments (diagnosed on lateral spine radiographs) along with osteophyte formation. However, disc spaces, apophyseal joints, and sacroiliac joints are unaffected. The thoracic spine is most commonly affected. It may be accompanied by a more generalized calcification of other extra-axial

ligaments and tendons, as well.

The underlying pathophysiology is not understood. DISH has a higher prevalence among diabetic patients than among people without diabetes. Specifically, it is commonly seen in association with type 2 diabetes, particularly in obese patients.

Patients complain of stiffness in the neck and back with decreased range of motion. Pain is generally not a prominent symptom. Treatment consists of physical therapy and NSAIDs or other analgesics. There is no evidence yet that good glycemic control delays the onset of or improves this condition.

Osteoarthritis

Diabetes is not clearly a risk factor for osteoarthritis (OA). However, obesity is a risk factor for both conditions. Several studies have reported an association of early OA and diabetes. Both large and small joint OA have been reported to be increased in type 2 diabetes. However, OA of the weight-bearing joints in the affected type 2 diabetic patients may be related to their obesity and not to the diabetes itself. It is not yet known whether diabetes is a risk factor for OA independent of obesity.

Conclusion

Diabetes quite commonly affects the

musculoskeletal system, resulting in significant morbidity. These manifestations may go unrecognized or simply be overlooked in daily clinical practice. However, many of these rheumatological complications are treatable (to varying degrees), with resultant improvements in quality of life and more independence in activities of daily living. Thus, clinicians should be aware of the possible musculoskeletal complications of diabetes in order to intervene and provide the best care for affected patients. Asking patients about their symptoms and monitoring for signs of musculoskeletal complications can be an invaluable part of overall diabetes care.

Rachel P. Kim, MD is a senior postdoctoral fellow of rheumatology at Scripps Clinic in La Jolla, Calif. Steven V. Edelman, MD, is a professor of medicine in the Division of Endocrinology and Metabolism at the University of California–San Diego, and the Division of Endocrinology and Metabolism at the San Diego VA Health Care Systems in San Diego. He is also founder and director of Taking Control of Your Diabetes, a nonprofit organization, and an associate editor of Clinical Diabetes. Dennis D. Kim, MD, is a postdoctoral fellow of endocrinology and metabolism at the University of California–San Diego.