

Husbandry, Diseases, and Veterinary Care of the Bearded Dragon (*Pogona vitticeps*)

Paul Raiti, DVM, DABVP (Reptile and Amphibian)

Beverlie Animal Hospital, Mt. Vernon, New York 10552, USA

ABSTRACT: The bearded dragon (*Pogona vitticeps*) is (perhaps) the most common pet lizard in the United States. The purpose of this review article is to provide a practical overview of the natural history, husbandry, nutrition, reproduction, physical examination method, diagnostic techniques, currently recognized diseases, and therapeutics found useful for the bearded dragon. Nutritional secondary hyperparathyroidism and trauma attributable to cage-mate aggression are common problems encountered in juvenile dragons. Intestinal impaction and renal and cardiac diseases are more commonly seen in adult dragons. Newly described malignancies such as periocular squamous cell carcinoma and gastric carcinoma have also been reported in juvenile and adult bearded dragons.

KEY WORDS: Bearded dragon, diseases, husbandry, lizard, *Pogona vitticeps*, reptile.

INTRODUCTION

The bearded dragon's (*Pogona* spp.) appearance, docility, captive hardiness, diurnal activity, and manageable size (<40 cm) have combined to make this reptile very popular among herpetoculturists and pet owners (Christie, 1993). Several pairs of bearded dragons were imported from Germany in the 1980s, and these animals served as the founding stock for the captive population available in the United States today (Christie, 1993). However, this captive population has probably been repeatedly out-bred to wild-caught dragons illegally imported from Australia since their importation.

Bearded dragons are widespread throughout Australia. There are 6 species currently recognized: *Pogona barbata*, *Pogona henrylawsoni*, *Pogona microlepidota*, *Pogona minor*, *Pogona nullarbor*, and *Pogona vitticeps*. *Pogona minor* is further subdivided into 3 subspecies: *Pogona m. minor*, *Pogona m. minima*, and *Pogona m. mitchelli* (Wilson and Swan, 2010). The central inland species (*Pogona vitticeps*) has proven to be the hardiest and consistently reproduced in captivity in the United States. Assorted color varieties and sizes are available in the pet trade, including the sandfire (increased red pigmentation), yellow, and pastel (dilute pigmentation) color morphs and the so called German giants. More recently, dragons are being bred for reduced scale size (leatherbacks) and scaleless (silkbacks) mutations. Lack of genetic diversity in some lines may be a contributing factor for unthriftiness and susceptibility to disease.

Bearded dragons belong to the family Agamidae. Agamids are the fourth largest family of lizards, with over 300 species spread throughout Africa, Asia, and Australia (Rogner, 1997). Bearded dragons possess round pupils, fleshy tongues, and acrodont dentition and are not capable of caudal autotomy (Raftery, 2004). Acrodont teeth are ankylosed to bone and are not replaced if damaged (Fig. 1). The natural habitat of bearded dragons consists of xeric woodlands. In the wild, bearded dragons consume arthropods, worms, small rodents, lizards, greens, fruits, and flowers.

Husbandry: An appropriate enclosure for a bearded dragon should measure 1.2–1.8 m (4–6 ft) long, 0.6 m (2 ft) wide, and 0.6–0.9 m (2–3 ft) high. Most dragons are maintained in glass tanks with a screen top. Adults can be kept individually or as sexed pairs. Adult males should not share the same cage.

Arm waving (circumduction) by either sex in the presence of dominant conspecifics denotes submissive behavior. Flattening of the body, erect stance, head bobbing, gaping, and an expanded black throat represent defensive behavior. A dominant male will usually stay on the highest perch in the cage.

The author recommends newspaper or paper towels on the bottom of the cage for ease of cleaning and to limit the likelihood for substrate ingestion. Other substrates that may also be used include calciferous sand, beach sand, two-inch pea gravel, or carpet. Sand and fine gravel can cause gastrointestinal impaction and should be avoided. Hide areas (shelters) are strongly recommended.

The photoperiod provided to a bearded dragon should consist of 12 h of light and 12 h of darkness. Full spectrum lighting containing ultraviolet B radiation (UVB; 290–320 nm) and infrared heat (basking area: 35–41°C; 95–105°F) are essential for normal skeletal development and metabolic function (Strimple and Strimple, 1998). Ultraviolet B output should be monitored with a UV radiometer and the source replaced when levels begin to diminish from baseline. If monitoring is not possible, the source should be replaced every 6 months or according to the manufacturer's recommendation. Climbing furniture such as branches or rocks should be provided to allow for environmental enrichment and enhanced thermoregulation. The cooler part of the enclosure should be no less than 27°C (80°F). A drop of 5–10°C (10–15°F) is permissible in the evening for adults. The author discourages the use of hot rocks; heating pads placed on the underside of the enclosure are more appropriate.

A shallow water dish should be present in the enclosure at all times. In general, bearded dragons are reluctant to drink from bowls; hence spraying their head encourages them to drink. Shallow lukewarm water soaks can be done two to

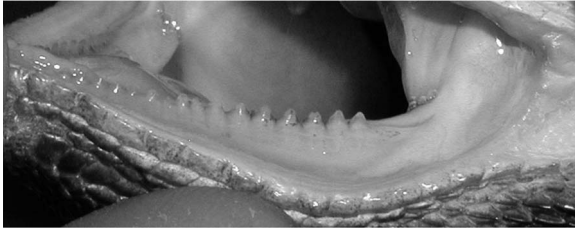


Figure 1. Acrodont dentition is characterized by fusion of the teeth to the crests of the maxillae and mandibles.

three times per week to stimulate defecation. Additionally, spraying the sides of the enclosure with tepid water every 24–48 h is recommended.

Ecdysis in bearded dragons occurs in multiple pieces; shedding frequency depends on growth rate. Bearded dragon owners should be made aware of the potential for dysecdysis, especially around the digits and tail tip. Dysecdysis at these sites can lead to avascular necrosis and the loss of the digit(s) and tail tip.

Life expectancy for bearded dragons in captivity is 7–12 yr. It is best to acquire a juvenile that is 3–6 months of age. By that time the dragon should be established, feeding regularly, and demonstrating robust growth.

Nutrition: Field studies have shown that the diet of adult bearded dragons consists of 90% vegetable matter and 10% animal matter; juveniles consume 50% vegetable and 50% animal matter (MacMillen *et al.*, 1989). In captivity, bearded dragons consume insects (e.g., crickets, mealworms, superworms) and assorted leafy vegetables (e.g., dandelion, Swiss chard, escarole, endive, romaine, “spring mix,” chicory, mustard, beet tops, and bokchoy), carrots, squash, and zucchini (Stahl, 1999). Bearded dragons will also take pinkies; however, these should not be offered more than once every two weeks. Hatchlings and juveniles (<4 months of age) can be offered 30% vegetables and 70% appropriately sized crickets (e.g., less than the width of the dragon’s head) (De Vosjoli and Mailloux, 1996). Proportions of diets can be approximately 50% insects and 50% vegetables for adults (De Vosjoli and Mailloux 1996). Insects should be “gut-loaded” with a balanced commercial food that contains preformed Vitamin A. A phosphorus-free calcium supplement with Vitamin D₃ should also be sprinkled on the feeder insects and vegetables immediately prior to presentation. Hatchlings <2 months of age should be fed two to three times/day. Juveniles at 2–4 months of age can be fed twice daily (De Vosjoli and Mailloux, 1996). Animals from 4 months of age to adulthood can be fed once daily to every two days (De Vosjoli and Mailloux, 1996). It is recommended to offer food in the mornings so that digestion occurs during the warmest part of the day. A multivitamin powder can be sprinkled on the vegetables every two weeks.

Reproduction: Breeding occurs September through March in the wild. Sexual maturity is attained by 18–24 months of age; however, this can be expedited in captivity by maximizing nutrition and husbandry. Brumation can be achieved by cooling the adults in individual enclosures for 4–6 wk at 16–21°C (60–75°F) with a reduced light cycle to 10 h during the late autumn or early winter (Strimple and Strimple, 1998; Stahl, 1999). Water should be provided during

this time. The ambient temperature should be gradually increased to maintenance temperatures over a period of 2–3 wk. The lizards should be fed and then introduced to each other. Courtship consists of the male darkening its throat and circling the female. A receptive female flattens its body and permits copulation. When the female begins displaying signs of being gravid (e.g., increased body weight, enlarged coelom), a nest box should be provided that contains damp sand or potting soil at a depth of 25.4 cm (10 in). After oviposition, the eggs are removed from the enclosure and incubated in vermiculite at a 1:1 ratio by weight with water. The incubator should have an ambient temperature of 28–30°C (82–86°F). Eggs typically hatch in 3–4 wk (Strimple and Strimple, 1998). Neonates possess an egg tooth that is used to facilitate hatching. They should be housed separately and offered food of appropriate size within 24 h. Bearded dragons are cannibalistic, and size disparity among cage mates can lead to cannibalism or attempted cannibalism and resultant head, limb, or tail trauma. Hatchlings should be misted daily.

Physical examination: The physical examination should begin with simple observation of the lizard in its carrier. Most bearded dragons are transported in small glass tanks or transparent plastic containers. Observe the animal’s level of awareness, posture, skin color, injuries, locomotion, respiration, and body conformation. Bearded dragons lift the entire body and proximal tail well off the ground when walking; failure to do so may be an early indicator of a problem (e.g., calcium deficiency). Hypothermia and systemic disease can also affect motor strength. Bearded dragons are more comfortable when they are permitted to rest on a flat surface rather than being manually restrained. Starting at the head, look for abrasions, jaw swelling, ocular lesions, patency of the external nares, and tympanic membrane lesions. Bearded dragons possess an external parietal eye (3rd eye), which is located dorsally on top of the head between the eyes; it should also be examined for any gross lesions (Raftery, 2004). The mouth can be opened by gently depressing the tip of the mandible with an index finger. The color of the oral mucous membranes is normally pale yellow to pale pink but not white. The tip of the tongue should be darker in color than the rest of the tongue; this is because of the increased number of blood vessels at this location. The glottis is situated on the floor of the mouth just caudal to the tongue. It is only visible when the mouth is opened widely. Normal skin color ranges from brown to orange depending on the color morph, health status, and body temperature of the animal. Look for areas of discoloration, swelling, dysecdysis (e.g., toes, tail tip), and scarring on the skin. Palpate the limbs and joints, including the vertebral column. The vertebral column should be relatively straight without lordosis, kyphosis, or scoliosis. Heart rate and rhythm can be evaluated with an ultrasonic Doppler (Fig. 2). Heart rate is temperature dependent, with a range of 40–90 beats per minute. Coelomic palpation should be done to assess the patient for the presence of ingesta, masses, the size of the paired fat bodies, and possible foreign bodies. Care must be taken when palpating reproductively active adult female bearded dragons. Ovarian follicles are fluid-filled structures that can rupture if the dragon is handled roughly. Evaluate the ventral aspect of the body; pay particular attention to



Figure 2. An ultrasonic Doppler monitor crystal is placed caudal to the scapulo-humeral joint to assess the heart.

the vent and femoral glands (Fig. 3A,B). Males generally possess larger femoral glands than females (Raftery, 2004). In mature males, the paired hemipenes form bulges on either side of the tail base. Finally, measure the body weight (g) of the animal; this becomes especially important for monitoring changes in body condition over time and dosing therapeutics. A client handout outlining husbandry and disease symptoms (Stahl, 1999) should be distributed to owners during the first office visit.

Diagnostic techniques: Venipuncture: A tuberculin syringe with a 25 gauge needle may be preheparinized prior to blood sampling, if preferred, but it is not absolutely necessary because of the heparin's effect on staining characteristics of blood cells. The preferred sample site is the ventral coccygeal vein (Heard *et al.*, 2004). This vein can be accessed using either the ventral or lateral approach. Once the vertebral body is encountered, gentle aspiration is done. Sample volume (ml) is calculated as 0.5–0.8% of the body weight (g) (Heard *et al.*, 2004). Other less desirable sites are the ventral abdominal vein, brachial plexus, and heart. The ventral abdominal vein is located on the midline of the caudal coelom. There is the potential risk of uncontrolled hemorrhage and laceration of internal organs if the animal suddenly moves during sampling from this site. The brachial plexus is accessible from the axillary areas. The heart is located within the pectoral girdle. Cardiocentesis should only be attempted with ultrasound guidance. Guidelines for hematology/plasma biochemical values can be found in Tables 1 and 2 (International Species Information System, 2002).

Fecal analysis: Fecal examinations are particularly important in bearded dragons. Normal feces are brown and pelleted. Pigments in processed foods can affect the color of fecal material. Endoparasitic infestations (e.g., coccidiosis, oxyuriasis) are very common. Cestodiasis and amoebiasis are less common. A colonic lavage can be done to collect a fecal sample by inserting a lubricated catheter, feeding tube, or ball-tipped feeding needle into the colon with gentle persistent pressure. This technique often requires multiple redirections until you feel it slip through the colonic sphincter. Saline (10 ml/kg) can then be flushed into the distal colon and aspirated for sample collection (Klingenberg, 2004).

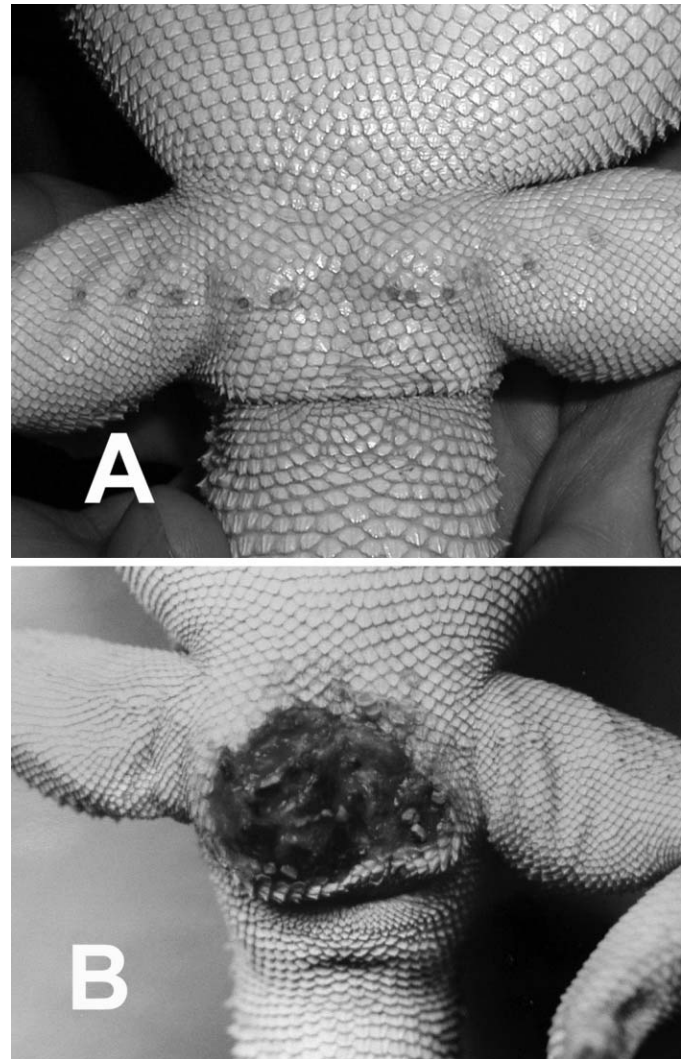


Figure 3. (A) Male bearded dragons possess larger femoral pores than females (B). (B) Note the severe cloacitis attributable to oxyurids in this female bearded dragon.

Urinalysis: Bearded dragons lack a urinary bladder. Urine is stored in the ureters and urodeum. Most of the urinary excreta are composed of semisolid urates and some fluid. Urine-specific gravity (1.003–1.014) of reptiles is normally lower than in mammals (Johnson, 2004). The presence of red blood cells is abnormal.

Noninvasive imaging: Radiography, ultrasonography (US), computed tomography (CT), and magnetic resonance imaging (MRI) are routinely used for reptiles. Radiography is most useful for evaluating the skeletal, respiratory, gastrointestinal, and female reproductive systems. Common radiographic findings are metabolic bone disease, osteomyelitis, articular gout, fractures, lower respiratory tract disease, sand/gravel impaction, follicular development, presence of eggs, and metastatic mineralization (Raiti, 2004) (Fig. 4A,B). US is indicated for visualization of internal organs provided there is a soft tissue window. It is particularly useful for examination of the heart, liver, and ovaries (Fig. 5A,B). CT, unlike radiography, is not limited by overlying structure such as bone. It provides transverse slices

Table 1. Hematology and plasma biochemistry reference ranges for the bearded dragon (ISIS Standard International Units; both sexes combined; ages >1 yr). a = number of samples used to calculate the reference; b = number of different individuals used to determine the reference.

Test	Units	Mean	SD	Minimum value	Maximum value	Sample size ^a	Animals ^b
White blood cell count	×10 ³ /μl	9.069	5.425	2.200	29.70	57	41
Red blood cell count	×10 ⁶ /μl	1.05	0.19	0.73	1.55	29	21
Hemoglobin	g/L	101	15	80	130	21	16
Hematocrit	L/L	0.300	0.058	0.185	0.415	72	53
Mean corpuscular volume	fl	297.2	45.6	228.6	373.7	28	20
Mean corpuscular hemoglobin	pg/cell	104.1	19.5	72.7	142.5	17	12
Mean corpuscular hemoglobin concentration	g/L	354	80	250	591	21	16
Nucleated red blood cells	/100 WBC	0	0	0	0	2	2
Heterophils	×10 ³ /μl	3.070	2.132	0.350	9.220	57	41
Lymphocytes	×10 ³ /μl	4.612	3.601	0.240	17.00	57	41
Monocytes	×10 ³ /μl	0.780	1.114	0.050	5.940	36	29
Eosinophils	×10 ³ /μl	0.356	0.412	0.052	1.440	11	9
Basophils	×10 ³ /μl	0.481	0.457	0.032	2.509	48	37
Azurophils	×10 ³ /μl	0.573	0.598	0.000	2.312	30	22
Calcium	mMol/L	4.13	2.88	1.78	14.00	58	42
Phosphorus	mMol/L	1.78	0.78	0.87	4.88	52	38
Sodium	mMol/L	157	12	137	186	37	29
Potassium	mMol/L	3.7	1.1	1.3	6.3	38	30
Chloride	mMol/L	127	16	104	163	21	17
Bicarbonate	mMol/L	24.0	2.8	22.0	26.0	2	2
Carbon dioxide	mMol/L	16.7	3.6	12.7	20.0	7	7
Osmolarity	Osmol/L	0.2970	0.0000	0.2970	0.2970	1	1
Blood urea nitrogen	mMol/L	0.7140	0.3570	0.0000	1.428	21	18
Creatinine	μMol/L	18	18	0	53	12	10
Uric acid	mMol/L	0.262	0.155	0.000	0.684	61	47
Total bilirubin	μMol/L	9	15	0	63	18	18
Direct bilirubin	μMol/L	0	0	0	0	4	4
Indirect bilirubin	μMol/L	0	0	0	0	4	4
Glucose	mMol/L	11.38	2.942	6.549	23.09	51	38
Cholesterol	mMol/L	11.29	5.154	4.144	23.31	24	20
Triglyceride	mMol/L	3.503	1.944	1.051	5.187	4	4
Creatine phosphokinase	U/L	1,159	1,664	10	7,000	37	26
Lactate dehydrogenase	U/L	300	196	35	628	19	14
Alkaline phosphatase	U/L	158	132	15	447	35	30

Downloaded from http://meridian.allenpress.com/jhm/article-pdf/22/3-4/117/2208660/1529-9651-22_3_117.pdf by guest on 07 December 2024

Table 1. Continued.

Test	Units	Mean	SD	Minimum value	Maximum value	Sample size ^a	Animals ^b
Alanine aminotransferase	U/L	10	5	1	20	17	16
Aspartate aminotransferase	U/L	27	25	0	92	46	37
Gamma glutamyltransferase	U/L	18	29	0	81	8	7
Amylase	U/L	152.3	85.29	91.95	212.6	2	2
Total protein (colorimetry)	g/L	51	14	31	85	40	33
Globulin (colorimetry)	g/L	22	9	10	44	25	22
Albumin (colorimetry)	g/L	26	8	13	46	34	26
Fibrinogen	g/L	1.800	1.100	.0000	3.000	5	5

Table 2. Plasma biochemistry reference ranges from the bearded dragon (ISIS: Conventional U.S. Units; both sexes combined; ages >1 yr). a = number of samples used to calculate the reference; b = number of different individuals used to determine the reference.

Test	Units	Mean	SD	Minimum value	Maximum value	Sample size ^a	Animals ^b
Calcium	mg/dl	16.5	11.5	7.1	56.0	58	42
Phosphorus	mg/dl	5.5	2.4	2.7	15.1	52	38
Sodium	mEq/L	157	12	137	186	37	29
Potassium	mEq/L	3.7	1.1	1.3	6.3	38	30
Chloride	mEq/L	127	16	104	163	21	17
Bicarbonate	mEq/L	24.0	2.8	22.0	26.0	2	2
Carbon dioxide	mEq/L	16.7	3.6	12.7	20.0	7	7
Osmolarity	mOsmol/L	297	0	297	297	1	1
Blood urea nitrogen	mg/dl	2	1	0	4	21	18
Creatinine	mg/dl	0.2	0.2	0.0	0.6	12	10
Uric acid	mg/dl	4.4	2.6	0.0	11.5	61	47
Total bilirubin	mg/dl	0.5	0.9	0.0	3.7	18	18
Direct bilirubin	mg/dl	0.0	0.0	0.0	0.0	4	4
Indirect bilirubin	mg/dl	0.0	0.0	0.0	0.0	4	4
Glucose	mg/dl	205	53	118	416	51	38
Cholesterol	mg/dl	436	199	160	900	24	20
Triglyceride	mg/dl	310	172	93	459	4	4
Creatine phosphokinase	IU/L	1,159	1,664	10	7,000	37	26
Lactate dehydrogenase	IU/L	300	196	35	628	19	14
Alkaline phosphatase	IU/L	158	132	15	447	35	30
Alanine aminotransferase	IU/L	10	5	1	20	17	16
Aspartate aminotransferase	IU/L	27	25	0	92	46	37
Gamma glutamyltransferase	IU/L	18	29	0	81	8	7
Amylase	U/L	823	461	497	1,149	2	2
Total protein (colorimetry)	g/dl	5.1	1.4	3.1	8.5	40	33
Globulin (colorimetry)	g/dl	2.2	0.9	1.0	4.4	25	22
Albumin (colorimetry)	g/dl	2.6	0.8	1.3	4.6	34	26
Fibrinogen	mg/dl	180	110	0	300	5	5

Downloaded from http://meridian.allenpress.com/jhms/article-pdf/22/3-4/117/2208660/1529-9651-22_3_117.pdf by guest on 07 December 2024

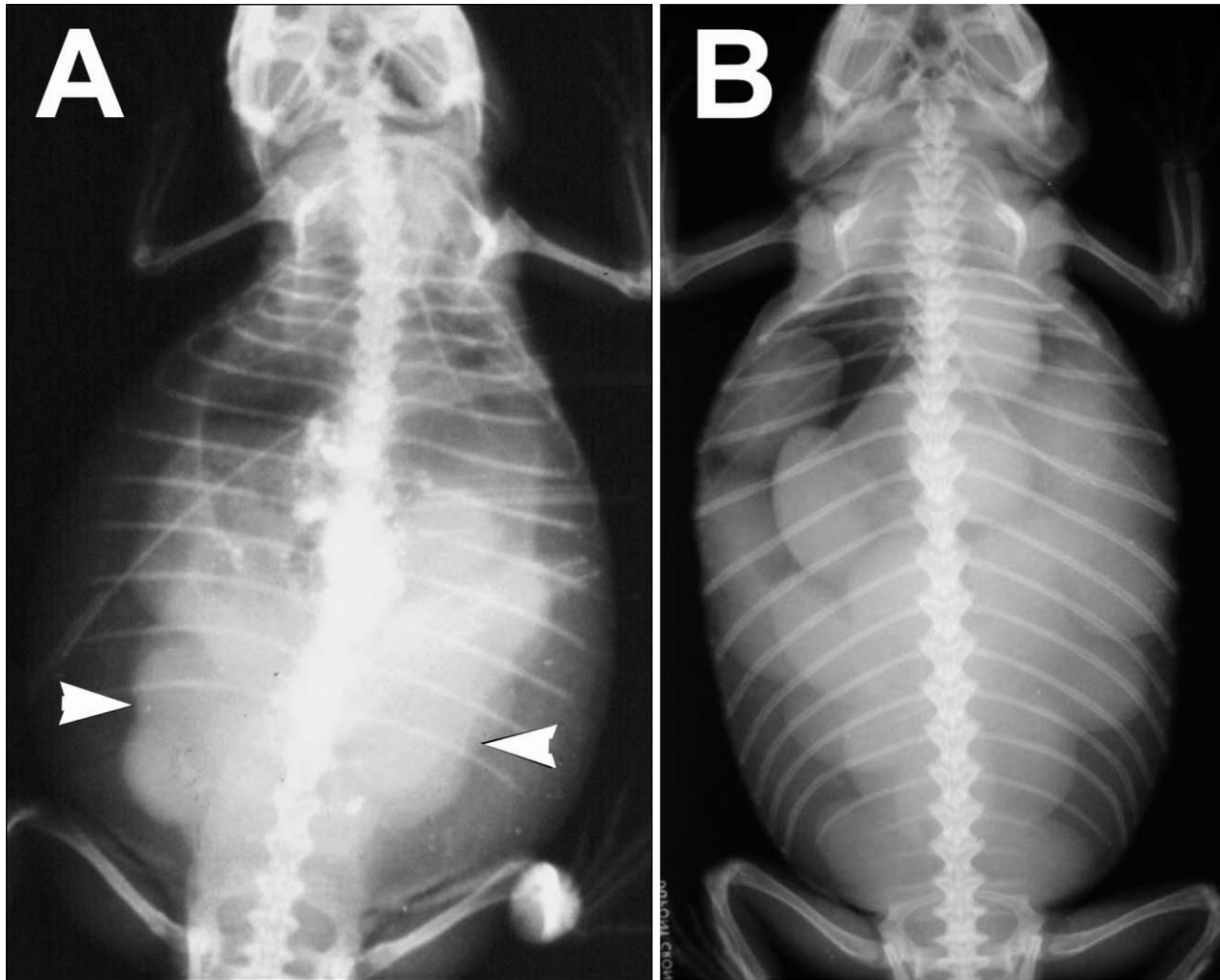


Figure 4. (A) Ovarian follicles (arrowheads) are visible radiographically as a cluster of spherical soft tissue densities occupying the caudal coelomic cavity. (B) Shelled eggs are visible as oblong densities with distinct borders that occupy most of the coelomic cavity.

of all organs and is particularly useful for evaluating the skeleton and lungs. MRI is most useful for evaluating soft tissues and provides slice orientation (coronal, transverse and sagittal) views. CT and MRI may require chemical immobilization.

Endoscopy: This minimally invasive technique provides direct visualization of organs and permits biopsy collection (Hernandez-Divers, 2004). General anesthesia is required. Coeloscopy is useful for evaluating coelomic organs (Fig. 6). Cloacoscopy is useful for evaluating the lower urogenital and intestinal tracts (Hernandez-Divers, 2004).

Necropsy: Necropsy is an invaluable tool that assists the clinician in improving diagnostic skills. Physical examination and surgical abilities are also enhanced. In many cases, necropsy and histopathology are required for a final diagnosis. The bearded dragon possesses heavy melanin deposits on the parietal surface of the caudal coelomic cavity (Fig. 7). It is recommended to archive pictures of normal organs to be used for comparison with diseased tissues.

Diseases: **Atadenovirus (Adenovirus):** Infection causes non-specific clinical signs (e.g., anorexia, lethargy, diarrhea, and encephalopathy) in affected bearded dragons, with highest morbidity/mortality occurring in neonates and juveniles; however, dragons of all ages can be affected (Boyer and Frye, 2000; Reavill and Schmidt, 2009). Subclinical carriers can act as reservoirs. It is suspected that the virus can be passed vertically, because neonates have died from outbreaks despite being housed separately from adults. Atadenovirus infection typically leads to poor growth and mortality in young dragons and poor growth and failure to thrive in older animals. The liver, pancreas, kidneys, and intestines are most commonly affected (Jacobson *et al.*, 1996). The virus infects enterocytes and is shed in the feces. Previously, diagnosis had been limited to histopathology demonstrating the presence of basophilic intranuclear inclusions in hepatocytes, enterocytes, and kidneys (Jacobson *et al.*, 1996). Currently, antemortem diagnosis is possible by either fecal-based polymerase chain reaction (PCR) assay or negative staining electron microscopy (Wellehan *et al.*, 2004; Miller, personal communication). One advantage of

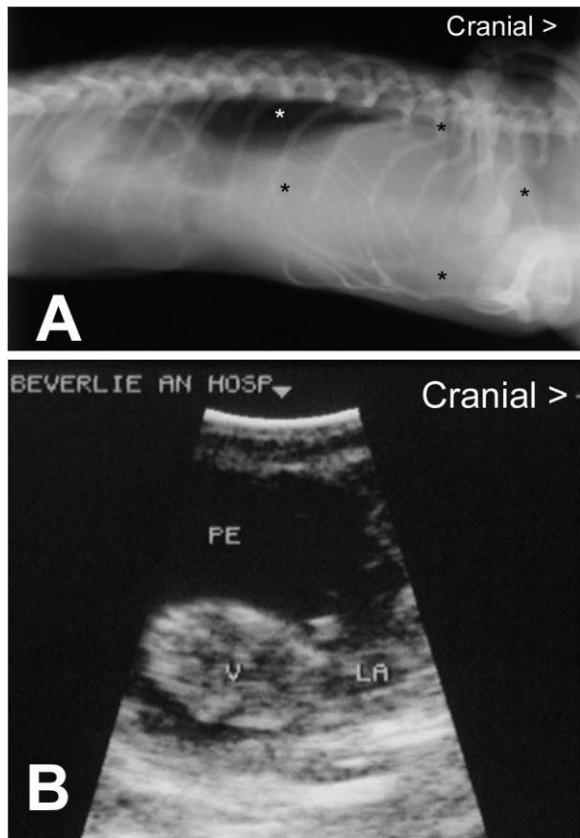


Figure 5. (A) In this radiographic image, a soft tissue mass (black asterisks) in the cranial coelomic cavity is causing dorso-caudal displacement of the lungs (white asterisk). (B) Echocardiographic image of the same case reveals cardiomegaly attributable to pericardial effusion (PE) (V = ventricle; LA = left atrium).

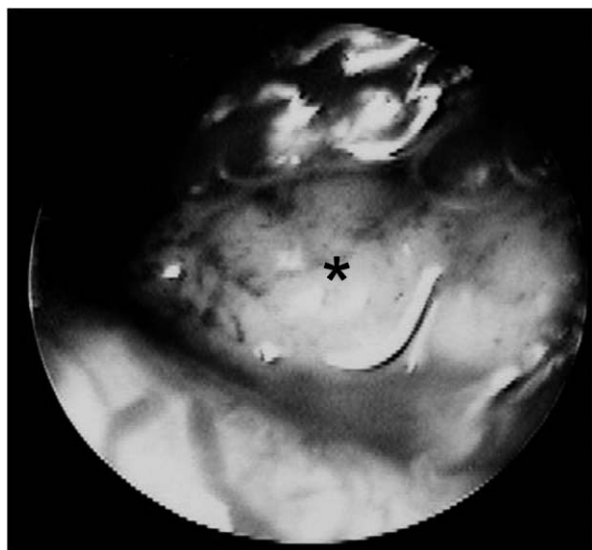


Figure 6. Coelioscopy reveals renomegaly (asterisk) in a bearded dragon with visceral gout.

the latter test is that it can also detect other viruses in the feces (i.e., calicivirus, dependovirus, coronavirus, parvovirus, and rotavirus); however, the sensitivity of electron microscopy for diagnosing atadenovirus in bearded dragons

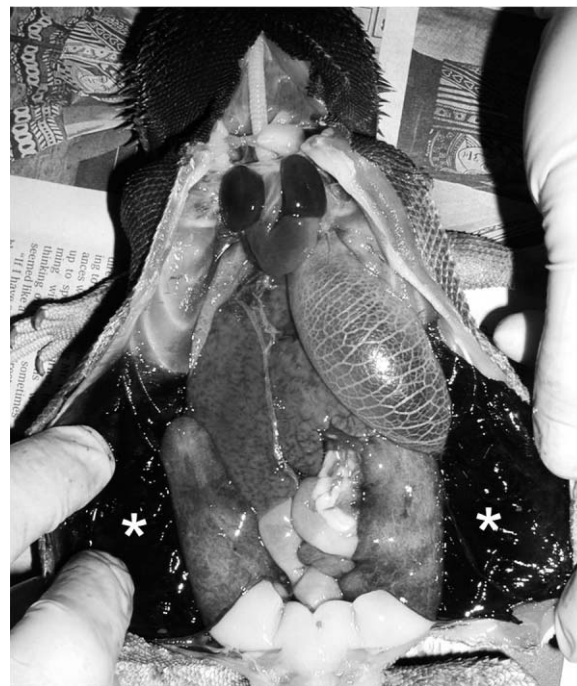

Figure 7. The caudal coelomic membranes (asterisks) of the bearded dragon are normally pigmented with melanin.

compared with PCR is very low (4%) (Walden *et al.*, 2007). Currently, there is no effective treatment against atadenovirus in bearded dragons.

Aneurysm: Several cases of aneurysms have been reported in bearded dragons (Barten *et al.*, 2006; Sweet *et al.*, 2009). The aneurysms usually arise from either an internal carotid artery or from the aorta. Affected lizards may present with a large fluctuant or firm swelling up to 5 cm (2.0 in) in diameter on the dorsolateral neck (Fig. 8A,B). If an ultrasonic Doppler crystal is placed on the aneurysm, it pulses loudly (not like any vein or artery). Surgical correction is often difficult, because the origin of the aneurysm is often proximal to the gross swelling. Performing an MRI prior to attempting surgery to determine the proximal source of the aneurysm is recommended, rather than dissecting the root back to the trunk (i.e., a surgical approach from the head caudal into the chest cavity). One report described successful removal of an aneurysm from the neck area after MRI and CT revealed its origin and boundaries (Barten *et al.*, 2006). Blood loss during surgery required a transfusion from a donor bearded dragon. The lizard survived for 18 months. In another bearded dragon, an aortic aneurysm was located entirely within the coelomic cavity just cranial to the cardiac apex (Sweet *et al.*, 2009). Clinical symptoms consisted of acute onset of listlessness, weakness, and pallor of the entire integument. The lizard suddenly died several days after presentation attributable to rupture of the aneurysm. Histological examination of the aneurysm revealed focal disruption and ulceration of the intimal layer of the aorta with pockets of lymphocytic inflammation within the disrupted intima. Periodic acid-Schiff staining did not reveal any fungal elements. Another bearded dragon did not undergo treatment and survived for 8 months after diagnosis. The etiology of this syndrome is unknown. One possibility is

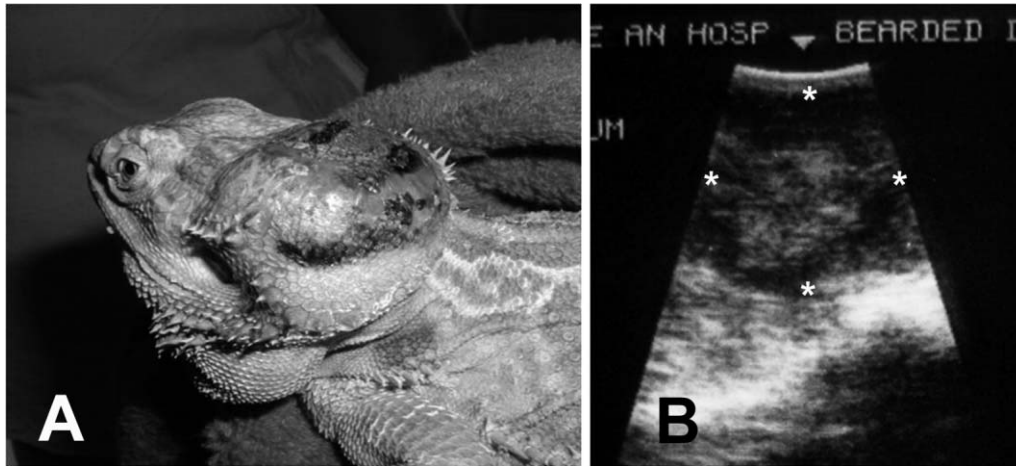


Figure 8. (A) This aneurysm is dorsal to the squamosal bone. (B) Ultrasonographic image of the aneurysm (asterisks); note the hyperechoic core surrounded by areas of mixed echogenicity.

that the carotid arteries, because of their shallow position in the dorsolateral pharynx, may be exposed to trauma during feeding (Barten *et al.*, 2006). Hypertension and/or genetic predisposition are also possible (Barten *et al.*, 2006).

Atherosclerosis and pericardial effusion: Atherosclerosis and pericardial effusion were diagnosed in a 2-yr-old lethargic male bearded dragon based on ultrasound imaging, necropsy, and histopathology (Schilliger *et al.*, 2010). The lizard's diet was totally insectivorous, consisting of crickets, mealworms, superworms, and wax moth larvae. Plasma biochemistries revealed mild hyperglycemia and hypercholesterolemia. Atherosclerosis is characterized by inflammation of arterial smooth muscle cells and formation of atherosclerotic plaques. This buildup leads to abnormalities in blood flow and diminished oxygen supply to target organs. In mammals and birds, development of atherosclerosis may be the result of a high concentration of plasma cholesterol, unbalanced diet, stress, hepatic lipidosis, and/or a lack of exercise (Schilliger *et al.*, 2010).

Ectoparasites: The snake mite (*Ophionyssus* spp.), lizard mite (*Hirstiella trombidiformis*), and chigger mite (Family: Trombiculidae) are occasionally seen on bearded dragons. Skin folds (e.g., lips), external ears, and the vent should be closely inspected for the presence of these ectoparasites. There are several treatment options against these ectoparasites, including: a) 1% injectable ivermectin at 5 mg/0.95 L of water sprayed topically on the lizard q 7 days for 8 treatments; b) fipronil 0.29% sprayed topically on the lizard q 7 days for 2 treatments; and c) 10% permethrin diluted to 1% with tap water and applied topically on the lizard (treat in a well-ventilated room) every 10 days until the ectoparasites are eliminated (Mader, 2006a). Enclosures (without reptiles present) can be sprayed with the same insecticides listed above and then washed with hot water (>49°C, >120°F) to kill any mite life stages living off the host and in the environment.

Intestinal coccidiosis: Coccidiasis has been used to describe the presence of oocysts in the feces of clinically healthy animals, whereas coccidiosis describes active infection and disease in affected animals (Greiner and Mader, 2006).

Coccidiosis (*Isospora amphiboluri*, *Eimeria* spp.) is extremely common in bearded dragons, especially juvenile animals. Clinical signs in affected animals may include anorexia, lethargy, and diarrhea. It is likely that signs are attributable to concurrent infections with adenovirus or microsporidia. Treatment is often unrewarding with traditional potentiated sulfas. Ponazuril is the treatment of choice at 30 mg/kg PO every 48 h (Bogoslavsky, 2007). The author currently administers ponazuril at 30 mg/kg PO q 24 h for 7 days and then repeats it in 2 wk. Environmental decontamination is also important. A recheck fecal examination should be done 2 wk after the second treatment.

Additional endoparasites: Oxyurids (pinworms) are commonly identified in the feces of bearded dragons. These helminths inhabit the lower intestinal tract and, in small numbers, do not cause overt disease. In massive numbers, pinworms have been associated with unthriftiness, impaction, and cloacitis (Klingenberg, 2004; Greiner and Mader, 2006) (Fig. 3B). Fenbendazole at 100 mg/kg PO divided over three days and repeated in 2 wk is usually curative (Klingenberg, 2004). Recheck fecal examination is recommended 3 wk after treatment. Cestodes are occasionally seen in fecal preparations. Treatment consists of praziquantel at 5–8 mg/kg PO or IM (Klingenberg, 2004). Entamoebiasis, although uncommon, is extremely pathogenic in bearded dragons. Hepatic and intestinal granulomas are associated with trophozoite migration (Klingenberg, 2004). Affected dragons presented to the author have been moribund. Detection of motile trophozoites or multinucleated cysts in direct fecal smears is possible but inconsistent. Instead, diagnosis is commonly confirmed by necropsy and histopathology. Based on a pharmacokinetic study in the red rat snake, *Elaphe guttata*, treatment can be done with metronidazole at 50 mg/kg PO q 48 h (Bodri *et al.*, 2006). However, a pharmacokinetic study of metronidazole in the green iguana (*Iguana iguana*) at a dosage of 20 mg/kg PO q 48 h (Kolmstetter *et al.*, 1998) may be more appropriate for bearded dragons. Again, follow-up fecal examinations or colonic washes are needed post-treatment to confirm parasite elimination. Cryptosporidiosis has been reported in bearded dragons and has probably established itself in large breeding operations that supply the pet industry. Some

dragons are asymptomatic carriers, whereas others that presumably are immune compromised succumb to the disease. Diagnosis is by fecal-based acid-fast staining, immunofluorescent antibody testing, or PCR. Successful treatment has been reported using paromomycin at 100 mg/kg q 24 h for 7 days, twice a week treatments for 6 wk, and 360 mg/kg q 48 h for 10 days (Grosset *et al.*, 2011). Flagellates are occasionally encountered in bearded dragons. Treatment consists of metronidazole at 50–100 mg/kg PO with a second treatment 2 wk later (Davies and Klingenberg, 2004).

Cholelithiasis: A 3-yr-old male, captive-bred bearded dragon presented with a history of lethargy, anorexia, and decreased fecal production of several days duration. Physical examination revealed a firm, spherical structure palpable within the coelom. A cholelith was surgically removed from the gall bladder (Ritzman and Garner, 2009). Histologically, there was transmural edema with focal acute ulceration in the gall bladder. Lesions in the liver included hepatic fibrosis and bile duct proliferation.

***Chrysosporium* anamorph of *Nannizziopsis vriesii* (CANV):** Also known as “yellow fungus disease,” CANV is a primary fungal pathogen causing granulomatous dermatitis in snakes, lizards, and crocodylians (Reavill and Schmidt, 2009; Johnson *et al.*, 2011). CANV is not part of the normal dermal microbiota of reptiles and is capable of causing disease in healthy individuals (Johnson *et al.*, 2011). The bearded dragon appears to be particularly susceptible to CANV. Skin lesions appear as yellow to yellow-brown hyperkeratotic areas that can also affect the toenails. CANV is capable of systemic invasion and has been identified in the lung, coelomic fat pads, liver, and spleen (Reavill and Schmidt, 2009; Johnson *et al.*, 2011). Diagnosis is by histopathology and confirmed by fungal culture (Reavill and Schmidt, 2009; Johnson *et al.*, 2011). CANV is considered contagious among bearded dragons and possibly zoonotic in immunosuppressed humans. In seven bearded dragons, itraconazole at 5 mg/kg PO q 24 h eliminated CANV by 27 days; however, there was 70% mortality presumably attributable to hepatic toxicity from the antifungal agent (Van Waeyenberghe *et al.*, 2010). In the same study, seven bearded dragons that were administered voriconazole at 10 mg/kg PO q 24 h were cured of CANV by 47 days with 14% mortality. The authors concluded that voriconazole administered at a regimen of 10 mg/kg PO q 24 h seemed to be a safe and effective antimycotic drug to eliminate CANV infections in bearded dragons.

Constipation: Constipation is the infrequent or difficult evacuation of feces. Clinical signs include anorexia, lethargy, absence of feces, and enlargement of the caudal coelomic cavity. Constipation is most frequently attributable to chronic dehydration (Wright, 2008). Desiccated urates accumulate in the distal colon causing impaction and constipation (Wright, 2008). Medical treatment consists of warm water soaks (8–12 h in duration), mineral oil enemas (2 ml/kg), and gentle digital manipulation of the caudal coelomic cavity. Other predisposing factors are suboptimal basking areas, a lack of adequate dietary roughage, nutritional secondary hyperparathyroidism, intestinal parasitism, intraluminal intestinal lesions (granulomas, neoplasia, intussusceptions), and inappropriate substrate ingestion

(Wright, 2008). Parenchymatous masses and renomegaly should also be included in the list of differentials. Diagnosis is by palpation, radiography, and hematology/plasma biochemical analysis.

Firefly (*Photinus* spp.) toxicosis: Lucibufagins protect fireflies from potential predators. These compounds are similar to bufotoxins and can cause gastrointestinal upset, cardiotoxicity, and acute death (Knight *et al.*, 1999). Ingestion of one firefly can kill an adult bearded dragon. To date there is no effective treatment.

Fungal stomatitis: *Emmonsia* sp. was identified as the causative agent of oral granulomas in a bearded dragon (Boyer and Garner, 2005). The granulomas involved the intermandibular space and portions of the upper jaw. *Emmonsia* are filamentous fungi found in soil and the lungs of burrowing rodents. The source of the infection was thought to be associated with poor husbandry of silkworm prey. The dragon died approximately 1 wk after presentation and 2 days after starting ketoconazole.

Gout: In reptiles, hyperuricemia develops most commonly because of chronic renal disease. The inability of the kidneys to clear the blood of uric acid by tubular excretion leads to precipitation of urate crystals in major organs; hence, the term visceral gout (Johnson, 2004; Mader, 2006b). Deposition of urates in and around joints is called articular gout. Predisposing factors are inappropriate diet (excessive animal protein), hypothermia, and chronic dehydration (Mader, 2006b). Diagnosis of articular gout is by radiography and arthrocentesis (Fig. 9A–C). Needle shaped crystals (urates) are readily visible microscopically. The uric acid crystals turn blue when visualized through a polarizing filter. Hematology and biochemistries demonstrate renal disease (e.g., anemia, hyperproteinemia, hypernatremia, hyperkalemia, hyperphosphatemia, and hyperuricemia). Management consists of correcting husbandry problems, parenteral fluids, and the use of xanthine oxidase inhibitors such as allopurinol at 50 mg/kg PO q 24 h to lower uric acid production (Koelle, 2001).

Hepatic lipidosis: In bearded dragons, as in other reptiles, deposition of lipids in liver tissue can be a normal phenomenon that is associated with folliculogenesis or in preparation for brumation (McArthur *et al.*, 2004; Hernandez-Divers and Cooper, 2006). Examples of pathologic conditions that are associated with hepatic lipidosis are obesity, starvation, hypothyroidism, hyperglycemia, and hepatotoxins. Clinical signs in affected animals are typically nonspecific and often include anorexia and subsequent weight loss. Jaundice can be difficult to evaluate in bearded dragons because of the natural yellowish pigmentation of their oral membranes. Hematology values may reveal nonregenerative anemia and leukocytosis with toxic changes. Plasma biochemistry values reveal albuminemia, and increased aspartate aminotransferase (AST) levels (McArthur *et al.*, 2004; Hernandez-Divers and Cooper, 2006). AST is naturally present in hepatocytes, renal cells, and cardiac muscle (Ramsay and Dotson 1995). Definitive diagnosis is by hepatic biopsy (Fig. 10). Treatment consists of nutritional support, liver tonics, anabolic steroids, and management of concurrent primary disease (Hernandez-Divers and Cooper, 2006).

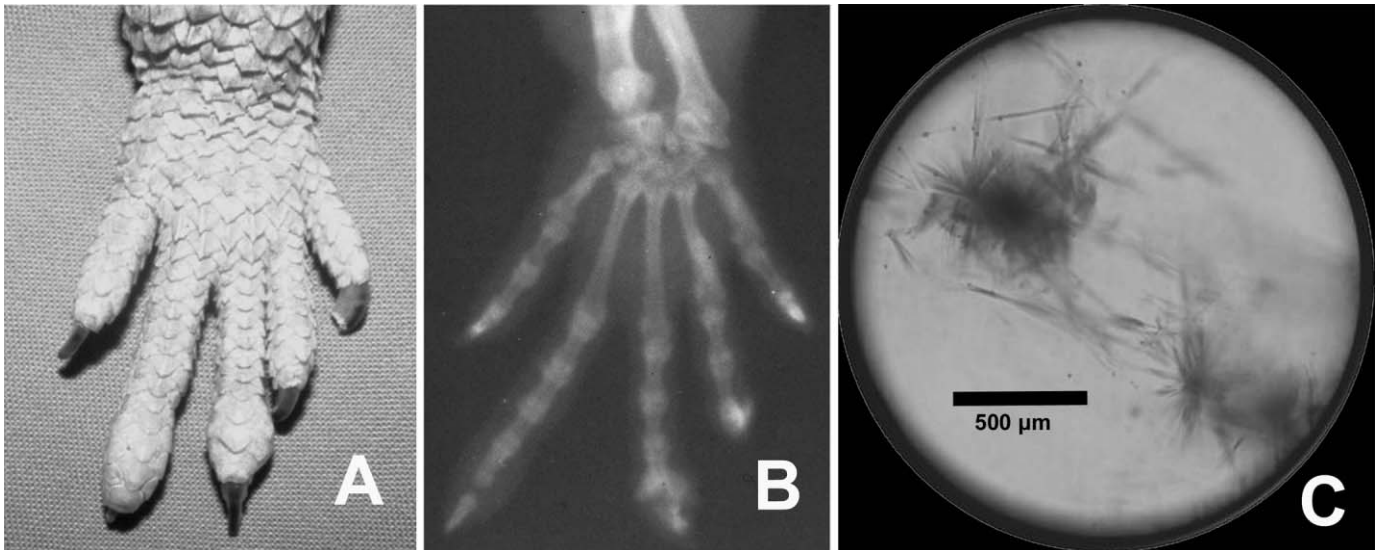

Figure 9. (A) Swollen phalangeal joints in a bearded dragon afflicted with articular gout; all four extremities were affected. (B) Radiographic appearance of the same foot; note the multiple radiopacities surrounding the joints and lysis within the joints. (C) Microscopic view of uric acid crystals obtained by arthrocentesis from the radiocarpal joint. (Unstained, original magnification $\times 10$.)

Listeriosis: A moribund 2.5-yr-old male bearded dragon presented with anorexia and diarrhea of 3 days' duration. Oral petechiation was noted on physical examination. Histology and microbiological culture/sensitivity identified *Listeria monocytogenes* meningitis and septicemia (Girling and Fraser, 2004). Listeriosis is a zoonotic disease that is frequently associated with low environmental temperatures, such as those encountered in the refrigeration of human foodstuffs, or in soil contamination in livestock (Girling and Fraser, 2004). It was suspected that the lizard described in this case contracted the disease after being fed frozen-thawed mouse pups.

Microsporidiosis (*Pleistophora* spp.): Microsporidiosis is considered to be very common in bearded dragons, particularly in individuals originating from commercial breeding facilities. Microsporidia are intracellular pathogens that possess a dark staining polar cap. Recently, they were reclassified as fungi (Gram-positive spores) (Strunk and Reavill, 2011). This organism causes nonspecific clinical signs such as anorexia, cachexia, and encephalopathy (Jacobson *et al.*, 1998). In one case, a 5-month-old female bearded dragon

was presented for anorexia, dyspnea, and presumed bacterial stomatitis. Gram staining of oral exudates revealed bacteria and Gram-positive oval microorganisms (microsporidia). The dragon died 48 h later and necropsy revealed disseminated granulomas containing microsporidial organisms (Cole, 2001). Clinically healthy animals may suffer acute death. The disease has been reported in bearded dragons of all ages. Transmission occurs by the fecal-oral route from spores passed into the environment by infected dragons. Vertical transmission is also thought to occur (Mitchell and Garner, 2011). Feeder insects have been implicated in disseminating the disease; however, this has not been proven. Many affected animals have concurrent infections with atadenovirus, coccidia and *Salmonella*. Diagnosis is by histopathology (Fig. 11). Multifocal granulomas surrounding infected macrophages or epithelial cells are commonly identified in the kidneys, heart, spleen, intestine, and

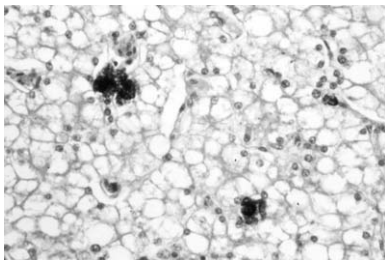


Figure 10. Hepatic lipidosis. Hepatic lipidosis is characterized by distention of hepatocytes with lipid vacuoles. (Hematoxylin and eosin stain, original magnification $\times 20$.)

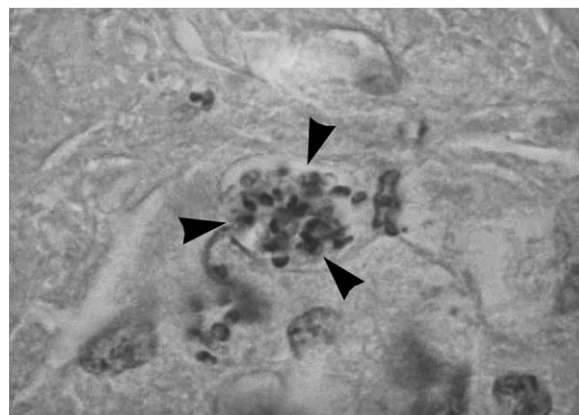


Figure 11. Microsporidial infection. Numerous microsporidial organisms (arrowheads) in a hepatic granuloma. (Hematoxylin and eosin stain, original magnification $\times 200$.)

brain (Jacobson *et al.*, 1998). There is no treatment for microsporidiosis.

Mycobacteriosis: Mycobacteriosis is a potentially zoonotic disease that causes cutaneous and systemic granulomatous lesions in reptiles. Reptiles are most commonly affected by the atypical or nontuberculous types of mycobacteria (Jacobson, 2007). Tissue samples from affected sites should be acid-fast stained, and if positive, submitted for culture or PCR testing. In a retrospective study of 3,880 reptile accessions, 28 (0.7%) mycobacterial positive reptiles were identified (Reavill and Schmidt, 2010). A bearded dragon had oropharyngeal lesions from which *Mycobacterium marinum* was identified (Reavill and Schmidt, 2010). Euthanasia of affected reptiles is recommended.

Nutritional metabolic bone disease (NMBD): This is the most common disorder of juvenile bearded dragons. Clinical signs in affected animals include anorexia, weakness, constipation, motor paralysis, tetany, skeletal deformities, and pathologic fractures. It is characterized by poor skeletal calcification and hypocalcemia (Fig. 12A,B). NMBD is attributable to one or more of the following: deficiencies

of dietary calcium, Vitamin D₃, and/or Vitamin A; lack of exposure to UVB; and suboptimal basking temperatures (Calvert, 2004; Wright, 2008). Identification and correction of inappropriate husbandry practices are essential. Treatment consists of calcium supplementation with calcium gluconate syrup (360 mg/ml) at 1 ml/kg PO q 12 h for critical patients until there is a positive clinical response. Another calcium supplement that can be used is calcium carbonate (TUMS Ultra 1000®, GlaxoSmithKline, Philadelphia, PA). At a concentration of 1,000 mg/tablet, one can administer 1/2 tablet/kg PO daily by pulverizing the tablet and mixing it with food (Wright, 2008). Nutritional support (i.e., Emerald® Omnivore-Avian, Lafeber Co., Cornell, IL) is indicated for anorexic animals until self-feeding. Heat, UVB, cage rest and fluids for rehydration must also be provided. The author does not use calcitonin or Vitamin D₃ because there is usually a dramatic response to the treatments listed above (also see Husbandry and Nutrition sections).

Periodontitis: The base of an acrodont tooth is only covered by a thin layer of epithelium (instead of gingival tissue); hence, bearded dragons are prone to periodontal disease

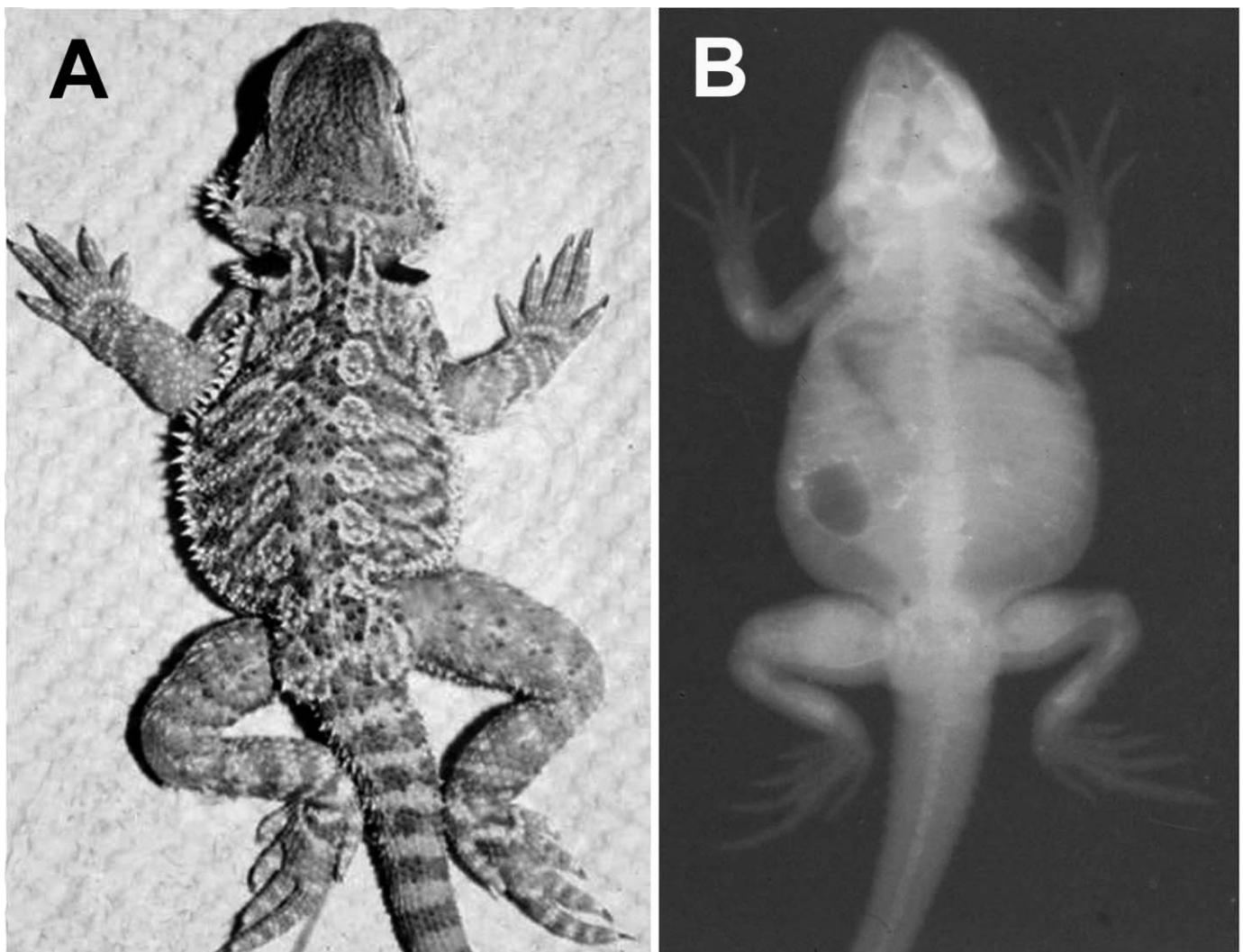


Figure 12. (A) A plantigrade stance and severe fibrous osteodystrophy are seen in advanced cases of NMBD in juvenile bearded dragons. (B) Radiographic appearance of the same dragon demonstrates replacement of skeleton by fibrous tissue.

when fed only soft foods such as moistened processed foods, mealworms, and fruit (McCracken and Birch, 1994). Clinical signs include swelling, erythema, and hyperplasia of the periodontal tissue and accumulation of dental calculus (calcified plaque). Chronicity leads to osteomyelitis, sepsis, systemic granulomatosis, and, in one case, hepatic thrombosis (Redrobe and Frye, 2001). Intraoral radiography is recommended to confirm the extent of the disease. Treatment consists of debridement of periodontal pockets under anesthesia, microbiological culture, antibiotics, and changes in diet (McCracken and Birch, 1994; Raftery, 2004).

Retained eggs: In the author's experience, there is a significantly lower incidence of follicular stasis and prolonged egg retention in bearded dragons than in green iguanas. Reproductively active females should have nest boxes provided. Follicular stasis should be treated by bilateral ovariectomy. The few cases of egg retention that the author has seen have responded well to oxytocin at 20 units/kg IM q 12 h.

Salmonellosis: *Salmonella* spp. are considered a component of the indigenous microflora of the gastrointestinal tract of reptiles and, for the most part, do not cause disease in healthy animals (Mitchell, 2006). These bacteria are capable of causing coelomitis, abscesses, pneumonia, and sepsis in susceptible reptiles (Mitchell, 2006) (Fig. 13). All reptiles should be considered carriers of *Salmonella*. *Salmonella* is potentially zoonotic, and owners should be advised to follow the guidelines on handling reptiles developed by the Association of Reptilian and Amphibian Veterinarians and Centers for Disease Control to minimize the likelihood of being exposed to this pathogen (Bradley *et al.*, 1998).

Trauma: Bearded dragons are cannibalistic, and large size disparities may result in the larger animals trying to eat smaller conspecifics. Trauma is commonly seen in neonates and juveniles. These reptiles are usually maintained in crowded, communal enclosures in pet shops or reptile shows. Additionally, adult males should not be kept together. Injuries can also occur during feeding. Wounds are typically found on the extremities (Fig. 14). Treatment consists of surgical debridement and topical and systemic antimicrobials.

Neoplasia: **Chronic monocytic leukemia:** A 5-yr-old, male bearded dragon presented for lethargy, weight loss, and dehydration. Hematology revealed a nonregenerative anemia (12% hematocrit) and a monocytic leukocytosis (91.6×10^3 leukocytes/ μl ; 43×10^3 monocytes/ μl). Histology revealed infiltration of the liver, small intestine, kidneys, and subconjunctival tissues with neoplastic monocytes (Gregory *et al.*, 2004). Characterization of the monocytes was aided by the use of cytochemical and immunohistochemical stains. In another case, a 4.5-yr-old male bearded dragon with monocytic leukemia died 24 h after attempted treatment with cytosine arabinoside (Jankowski *et al.*, 2011).

Fibrosarcoma: Fibrosarcomas commonly develop in subcutaneous tissue and then metastasize via the circulatory and lymphatic systems to visceral structures. A 9-yr-old, adult male bearded dragon with a 3-wk history of anorexia,

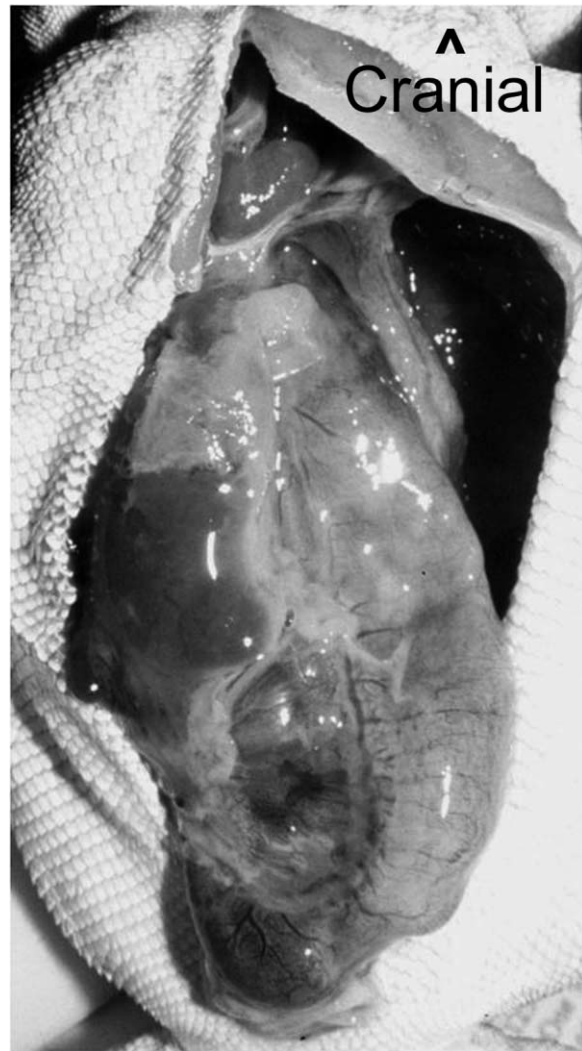

Figure 13. Coelomitis with adhesions encapsulating the coelomic viscera of a juvenile bearded dragon infected with *Salmonella* sp.

malaise, and weight loss had a large, firm, subcutaneous cervical mass on the right side of the neck that had been present for 2 months. The mass was identified as a fibrosarcoma with coelomic metastasis (Diaz-Figueroa *et al.*, 2005).

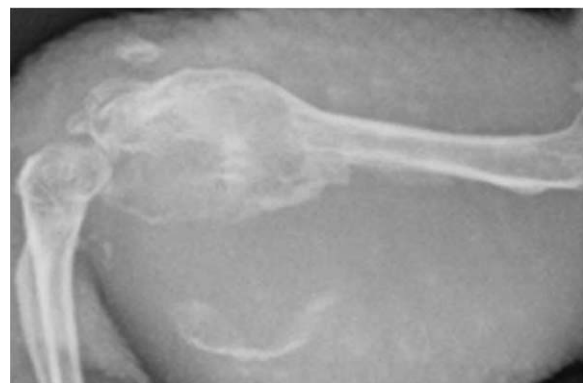

Figure 14. Radiographic appearance of osteomyelitis of the distal femur of a bearded dragon that was attacked by a green iguana. A pure culture of *Acinetobacter baumannii* was isolated.

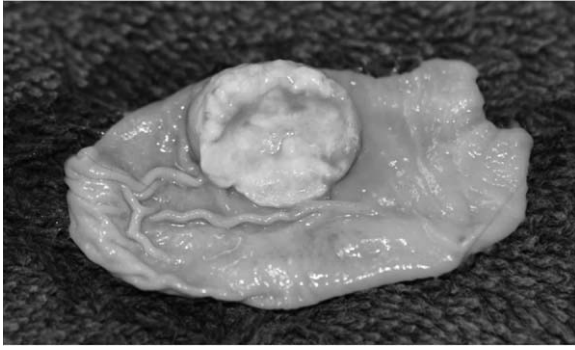


Figure 15. In bearded dragons, gastric endocrine carcinomas originate within the lumen of the stomach prior to systemic metastasis (Courtesy Steven Barten).

Gastric endocrine carcinoma: This is a highly malignant neoplastic entity in young bearded dragons (Ritter *et al.*, 2009; Levine, 2011; Perpignan *et al.*, 2011). Clinical signs include anorexia, vomiting, severe hyperglycemia, and anemia. The tumor originates from the gastric mucosa, penetrates the gastric serosa, and subsequently metastasizes to the liver and kidneys (Fig. 15). Definitive antemortem diagnosis can be attempted with gastroscopy or coeliotomy and biopsy (Levine, 2011; Perpignan *et al.*, 2011). In two published cases, one dragon was euthanized after gastroscopy and another dragon died 24 h after coeliotomy. These tumors are immunohistochemically positive for somatostatin, suggesting they may be somatostatinomas (Ritter *et al.*, 2009).

Hepatocellular carcinoma: A hepatic carcinoma was diagnosed in a 6-yr-old female bearded dragon presented for anorexia and lethargy of several weeks' duration. Hematology and plasma biochemistries revealed leukopenia, hyperglycemia, and elevated alanine aminotransferase (ALT) and AST values. Similar to AST, ALT is not an organ-specific marker and is found in the kidneys and liver (Ramsay and Dotson, 1995). Necropsy revealed numerous hepatic tumors and nodular pancreatic hyperplasia (Griswald, 2001).

Interstitial cell tumor: A juvenile male bearded dragon was presented to the author for anorexia associated with a distended coelomic cavity. Necropsy revealed a large mass occupying the caudal coelom. Histology identified the mass as a testicular interstitial cell tumor (Fig. 16).

Malignant chromatophoroma: A 7-yr-old, male bearded dragon presented for left-sided head swelling with increased yellow cutaneous pigmentation and two cutaneous masses on the right side of the body (Strunk *et al.*, 2009). Biopsies of the masses revealed malignant chromatophoroma. Necropsy revealed metastasis to the spleen, heart, and liver.

Malignant peripheral nerve sheath tumor: An adult bearded dragon with an unresectable axillary mass was euthanized. Numerous metastases were present in the liver, heart, and lungs. Histologically, the mass was identified as a malignant peripheral nerve sheath tumor (Mikaelian *et al.*, 2001).

Nerve sheath tumor (Schwannoma): Five subcutaneous masses were successfully removed from two adult bearded

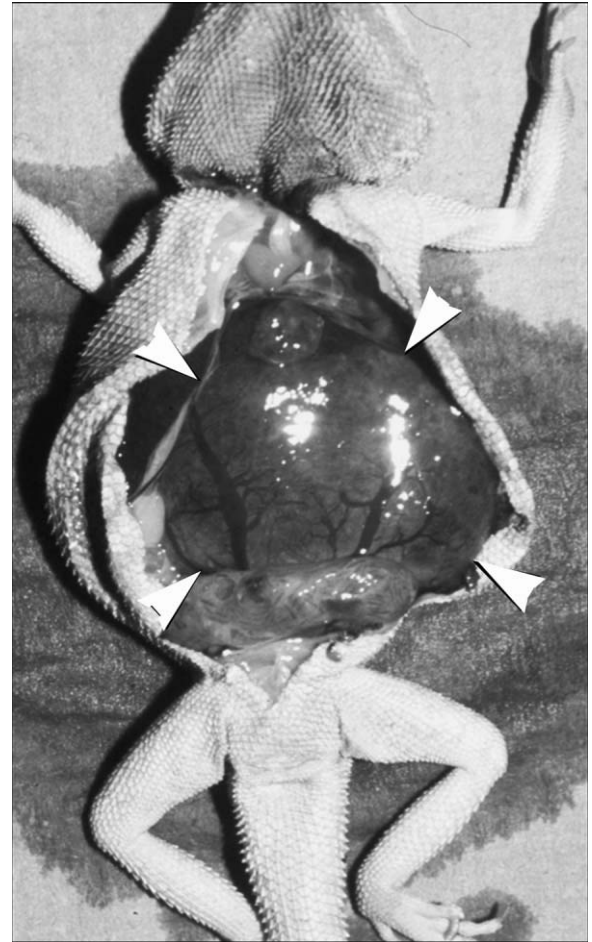


Figure 16. This testicular interstitial cell tumor in a juvenile bearded dragon (arrowheads) caused massive distention of the coelomic cavity.

dragon clutch mates (Lemberger *et al.*, 2005). Histologic, ultrastructural and immunohistochemical features were consistent with a peripheral nerve sheath origin. At one year postexcision, no local recurrence was noted; however, one of the individuals still had three masses ranging from 3–5 mm (0.12–0.20 in) diameter on which no additional growth was observed.

Osteosarcoma: An osteosarcoma of the sacrum with invasion of the spinal cord was diagnosed in a 6-yr-old male bearded dragon that was presented with a mass dorsal to the left coxofemoral joint. Nine days after incisional biopsies, the lizard developed paralysis of the hind quarters and was euthanized (Parr *et al.*, 2005).

Squamous cell carcinoma (SCC): This locally invasive malignant tumor is usually a solitary mass that is located in the eyelids, in periocular tissues, or behind the orbit (Burcham, 2007). Nine of 12 reported cases of SCC in bearded dragons occurred in the periocular tissues (Hannon, 2011) (Fig. 17). Despite its low rate of metastasis, complete excision is difficult to accomplish and may require enucleation. Prognosis appears to improve when SCC solely affects the eyelids. In one case, cryosurgery was used to successfully treat a palpebral SCC in an 8-month-old dragon



Figure 17. A squamous cell carcinoma (asterisk) of the palpebral conjunctiva in a 4-yr-old bearded dragon (Courtesy J.C. Burcham).

(Emerson *et al.*, 2012). The cause of SCC in bearded dragons is unknown; however, overexposure to UVB or a viral etiology is possible.

CONCLUSIONS

Bearded dragons are likely to remain popular pet lizards into the future. Veterinarians working with these animals need to familiarize themselves with “best husbandry practices” so that they can make appropriate recommendations to their clients. One of the benefits associated with their popularity is that they are being presented more commonly to veterinarians, and the literature regarding improved diagnostic methods and emerging diseases has increased as a result of this. It is the professional obligation of all veterinarians to share their experiences to expand our base of the knowledge regarding the species we work with.

Acknowledgment: The author thanks William Cermak for his assistance in the preparation of this manuscript.

LITERATURE CITED

- Barten S, Wyneken J, Mader D, Garner M. 2006. Aneurysm in the dorsolateral neck of two bearded dragons (*Pogona vitticeps*). *Proc ARAV*, 43–44.
- Bodri M, Rambo T, Wagner R. 2006. Pharmacokinetics of metronidazole administered as a single oral bolus to red rat snakes, *Elaphe guttata*. *J Herp Med Surg*, 16(1):15–19.
- Bogoslavsky B. 2007. The use of ponazuril to treat coccidiosis in eight inland bearded dragons (*Pogona vitticeps*). *Proc ARAV*, 8–9.
- Boyer T, Frye F. 2000. Suspected adenoviral hepatitis transmission from juvenile to adult bearded dragons, *Pogona vitticeps*. *Proc ARAV*, 69–71.
- Boyer T, Garner M. 2005. *Emmonsia* fungal stomatitis in a bearded dragon (*Pogona vitticeps*) *Proc ARAV*, 97–99.
- Bradley T, Angulo F, Raiti P. 1998. Association of reptilian and amphibian veterinarian guidelines for reducing the risk of transmission of *Salmonella* spp. from reptiles to humans. *J Am Vet Med Assoc*, 213(1):51–52.
- Burcham J. 2007. Ophthalmic squamous cell carcinoma in a bearded dragon. *Exot DVM*, 9(1):3.
- Calvert I. 2004. Nutritional problems. *In* Girling SJ, Raiti P (eds): *BSAVA Manual of Reptiles*. Wiley-Blackwell, Ames, IA:289–308.
- Christie B. 1993. Captive breeding and reproduction of the inland bearded dragon. *Captive Breeding Mag*, 1(2):20–23.
- Cole A. 2001. Systemic microsporidiosis in an inland bearded dragon, *Pogona vitticeps*. *Proc ARAV*, 155–160.
- Davies RR, Klingenberg R. 2004. Therapeutics and medication. *In* Girling SJ, Raiti P (eds): *BSAVA Manual of Reptiles*. Wiley-Blackwell, Ames, IA:115–130.
- De Vosjoli P, Mailloux R. 1996. A simple system for raising juvenile bearded dragons indoors. *Vivarium*, 7(6):42–55.
- Diaz-Figueroa O, Patterson K, Mitchell M, Lomax L, David A, Zachariah T. 2005. Metastatic fibrosarcoma in a bearded dragon (*Pogona vitticeps*). *Proc ARAV*, 79–81.
- Emerson J, Walling B, Whittington J, Zarfoss M. 2012. Pathology in Practice. *J Am Vet Med Assoc*, 240:1175–1177.
- Girling S, Fraser M. 2004. *Listeria monocytogenes* septicaemia in an inland bearded dragon, *Pogona vitticeps*. *J Herp Med Surg*, 14(1):6–9.
- Gregory C, Latimer K, Fontenot D, Lamberski N, Campagnoli R. 2004. Chronic monocytic leukemia in an inland bearded dragon, *Pogona vitticeps*. *J Herp Med Surg*, 14(1):12–16.
- Greiner E, Mader D. 2006. Parasitology. *In*: Mader D (ed): *Reptile Medicine and Surgery*. Saunders Elsevier Co., St. Louis, MO:343–364.
- Griswold, W. 2001. Hepatocellular carcinoma with associated hyperglycemia in an inland bearded dragon, *Pogona vitticeps*. *Proc ARAV*, 227–231.
- Grosset C, Villeneuve A, Brieger A, Lair S. 2011. Cryptosporidiosis in juvenile bearded dragons (*Pogona vitticeps*): effects of treatment with paromomycin. *J Herp Med Surg*, 21(1):10–15.
- Hannon D. 2011. Squamous cell carcinomas in inland bearded dragons, *Pogona vitticeps*. *Proc ARAV*, 131.
- Heard D, Harr K, Wellehan J. 2004. Diagnostic sampling and laboratory tests. *In* Girling SJ, Raiti P (eds): *BSAVA Manual of Reptiles*. Wiley-Blackwell, Ames, IA:71–86.
- Hernandez-Divers S. 2004. Diagnostic and surgical endoscopy. *In* Girling SJ, Raiti P (eds): *BSAVA Manual of Reptiles*. Wiley-Blackwell, Ames, IA:103–114.
- Hernandez-Divers S, Cooper J. 2006. Hepatic lipidosis. *In* Mader D (ed): *Reptile Medicine and Surgery*. Saunders Elsevier Co., St. Louis, MO:806–813.
- International Species Information Systems. (ISIS). 2002. Physiological Data Reference Values. CD Rom. ISIS. Apple Valley, MN.
- Jacobson E. 2007. Bacterial diseases of reptiles. *In*: Jacobson E (ed): *Infectious Diseases and Pathology of Reptiles*. CRC Press, Boca Raton, FL:468–469.
- Jacobson E, Green E, Undeen A, Cranfield M, Vaughn K. 1998. Systemic microsporidiosis in inland bearded dragons (*Pogona vitticeps*). *J Zoo Wildl Med*, 29(3):315–323.
- Jacobson E, Kopitf W, Kennedy A, Funk R. 1996. Coinfection of a bearded dragon, *Pogona vitticeps*, with adenovirus- and dependovirus-like viruses. *Vet Pathol*, 33(3):343–346.

- Jankowski G, Sirminger J, Borne J, Nevarez J. 2011. Chemotherapeutic treatment for leukemia in a bearded dragon (*Pogona vitticeps*). *J Zoo Wildl Med*, 42(2):326–329.
- Johnson J. 2004. Urogenital system. In Girling SJ, Raiti P (eds): BSAVA Manual of Reptiles. Wiley-Blackwell, Ames, IA:261–272.
- Johnson R, Sangster C, Sigler L, Hambleton S, Parée J. 2011. Deep fungal dermatitis caused by the *Chrysosporium* anamorph of *Nannizziopsis vriesii* in captive coastal bearded dragons (*Pogona barbata*). *Aust Vet J*, 89(12):515–519.
- Klingenberg R. 2004. Parasitology. In Girling SJ, Raiti P (eds): BSAVA Manual of Reptiles. Wiley-Blackwell, Ames, IA: 319–329.
- Knight M, Glor R, Smedley S, González A, Adler K, Eisner T. 1999. Firefly toxicosis in lizards. *J Chem Ecology*, 25(9): 1981–1986.
- Kolle P. 2001. Efficacy of allopurinol in european tortoises with hyperuricemia. *Proc ARAV*, 185–186.
- Kolmstetter C, Frazier D, Cox S, Ramsey E. 1998. Pharmacokinetics of metronidazole in the Green Iguana, *Iguana iguana*. *Bull Assoc Rept Amphib Vet*, 8(3):4–7.
- Lemberger K, Manharth A, Pessier A. 2005. Multicentric benign peripheral nerve sheath tumors in two related bearded dragons, *Pogona vitticeps*. *Vet Pathol*, 42(4):507–510.
- Levine B. 2011. Gastric neuroendocrine carcinoma (somatostatinoma) in a bearded dragon (*Pogona vitticeps*). *Proc ARAV*, 55–56.
- Macmillan R, Augee M, Ellis B. 1989. Thermal ecology and diet of some xerophilous lizards from western New South Wales. *J Arid Envir*, 16(2):193–201.
- Mader D. 2006a. Acariasis. In Mader D (ed): *Reptile Medicine and Surgery*. Saunders Elsevier Co., St. Louis, MO:720–738.
- Mader D. 2006b. Gout. In Mader D (ed): *Reptile Medicine and Surgery*. Saunders Elsevier Co., St. Louis, MO:793–800.
- McArthur S, McLellan L, Brown S. 2004. Gastrointestinal system. In Girling SJ, Raiti P (eds): BSAVA Manual of Reptiles. Wiley-Blackwell, Ames, IA:210–229.
- McCracken H, Birch C. 1994. Periodontal disease in lizards: a review of numerous cases. *Proc ARAV*, 108–114.
- Mikaelian I, Levine B, Smith S, Harshbarger J, Wong J. 2001. Malignant peripheral nerve sheath tumor in a bearded dragon, *Pogona vitticeps*. *J Herp Med Surg*, 11(1):9–12.
- Miller LA. Available from author at Frederick Seitz Materials Research Laboratory, Room 125, 104 South Goodwin Avenue, Urbana, IL 61801; lamiller@illinois.edu, pers comm.
- Mitchell M. 2006. *Salmonella*: diagnostic methods for reptiles. In Mader D (ed): *Reptile Medicine and Surgery*. Saunders Elsevier Co., St. Louis, MO: 900–905.
- Mitchell MA, Garner M. 2011. Microsporidiosis in bearded dragons: a case for vertical transmission. *Proc ARAV*, 123.
- Parr K, Gamble K, Kinsel M. 2005. What is your diagnosis? *J Herp Med Surg*, 15(4):28–30.
- Perpignan D, Addante K, Driskell, E. 2011. Gastrointestinal disturbances in a bearded dragon (*Pogona vitticeps*). What is your diagnosis? *J Herp Med Surg*, 20(2–3):54–57.
- Raftery A. 2004. Clinical examination. In Girling SJ, Raiti P (eds): BSAVA Manual of Reptiles. Wiley-Blackwell, Ames, IA:51–62.
- Raiti P. 2004. Non-invasive imaging. In Girling SJ, Raiti P (eds): BSAVA Manual of Reptiles. Wiley-Blackwell, Ames, IA:87–102.
- Ramsay E, Dotson T. 1995. Tissue and serum enzyme activities in the yellow rat snake (*Elaphe obsoleta quadrivittata*). *Am J Vet Res*, 56(4):423–428.
- Reavill D, Schmidt R. 2009. Review: pathology of the reptile integument. *Proc ARAV*, 93–106.
- Reavill D, Schmidt R. 2010. Mycobacterial infections in reptiles. *Proc ARAV*, 16.
- Redrobe S, Frye F. 2001. Hepatic thrombosis and other pathology associated with severe periodontal disease in the bearded dragon, *Pogona vitticeps*. *Proc ARAV*, 217–219.
- Ritter J, Garner M, Chilton J, Jacobson E, Kiupel M. 2009. Gastric neuroendocrine carcinomas in bearded dragons (*Pogona vitticeps*). *Vet Pathol*, 46(6):1109–1116.
- Ritzman T, Garner M. 2009. Cholelithiasis and surgical cholelith removal in a bearded dragon (*Pogona vitticeps*). *Proc ARAV*, 117.
- Rogner M. 1997. *Lizards Vol. 1*. Krieger Publishing Co., Malabar, FL:119–121.
- Schilliger L, Lemberger K, Chai N, Bourgeois A, Charpentier M. 2010. First case of atherosclerosis associated with pericardial effusion in a bearded dragon (*Pogona vitticeps*). *Proc ARAV*, 70–73.
- Stahl S. 1999. General husbandry and captive propagation of bearded dragons, *Pogona vitticeps*. *Bull Assoc Rept Amphib Vet*, 9(4):12–19.
- Strimple P, Strimple J. 1998. Bearded dragons: a beginner's guide to captive husbandry and reproduction. *Reptiles USA Mag*, Annual: 28–44.
- Strunk A, Haney S, Reavill D. 2009. Malignant chromatophoroma in a bearded dragon (*Pogona vitticeps*). *Proc ARAV*, 73–75.
- Strunk A, Reavill D. 2011. Intracellular parasite in the pelvic limb of a bearded dragon *Pogona vitticeps*. *Proc ARAV*, 152.
- Sweet C, Linnetz E, Golden E, Mayer J. 2009. What is your diagnosis? *J Am Vet Med Assoc*, 234(10):1259–1260.
- Van Waeyenberghe L, Baert K, Pasmans F, van Rooij P, Hellebuyck T, Beernaert L, de Backer P, Haesebrouck F, Martel A. 2010. Voriconazole, a safe alternative for treating infections caused by the *Chrysosporium* anamorph of *Nannizziopsis vriesii* in bearded dragons (*Pogona vitticeps*). *Med Mycol*, 48(6):880–885.
- Walden M, Zimmerman S, Roy A, Bowles K, Klarsfeld J, Mitchell MA. 2007. Estimating the sensitivity and specificity of two different assays for bearded dragon adenovirus using latent exact modelling. *Proc ARAV*, 23.
- Wellehan J, Johnson A, Harrach B, Benko M, Pessier A, Johnson C, Garner M, Childress A, Jacobson E. 2004. Detection and analysis of six lizard adenoviruses by consensus primer PCR provides further evidence of a reptilian origin for the atadenoviruses. *J Virol*, 78(23):13366–13369.
- Wilson S, Swan G. 2010. *A Complete Guide to the Reptiles of Australia*. 3rd Rev. Ed. New Holland Publishers, London, UK.
- Wright K. 2008. Two common disorders of captive bearded dragons *Pogona vitticeps*: Nutritional secondary hyperparathyroidism and constipation. *J Exotic Pet Med*, 17(4): 267–272.