

Pathologic Quiz Case

A 35-Year-Old Man With Hematuria

Anil V. Parwani, MD, PhD; Dengfeng Cao, MD, PhD; Jonathan I. Epstein, MD

A 35-year-old man presented with gross hematuria and flank pain. Prior to this episode, he had been otherwise healthy. A cystoscopic evaluation showed high-grade obstruction of his right ureter at the right ureteral vesicle junction. A right ureteral stent was placed. A subsequent computed tomographic scan showed significant right hydronephrosis in spite of the ureteral stent. The urinary bladder and right ureterovesical segment contained a soft tissue mass, measuring 5 to 6 cm in diameter, which protruded into the bladder lumen. The right ureter stent traversed the center of this soft tissue mass. The radiologic impression was that the mass most likely was an extension

from the prostate, which was also markedly enlarged, measuring approximately 6 cm in diameter. No abnormalities were seen in the left kidney and no renal calculi were identified. A subsequent ultrasound revealed a 97-g prostate, right side larger than the left. A serum prostate-specific antigen level was obtained, which was 0.1 ng/mL (reference range, 0.00–4.00 ng/mL).

A series of 8 prostate biopsies were performed, including one of a hypoechoic area at the right apex. Histologic examination showed a neoplasm composed of anastomosing cell cords or trabecular arrangement of tumor cells (Figure 1, hematoxylin-eosin). The clusters consisted of large, relatively uniform, round eosinophilic cells with abundant finely granular cytoplasm. The nuclei were polymorphic with occasional pseudo-inclusions (Figures 1 and 2, hematoxylin-eosin). The cell clusters were closely associated with a rich vascular sinusoidal network (Figure 3, hematoxylin-eosin). Immunostaining for chromogranin showed diffuse cytoplasmic reactivity (Figure 4).

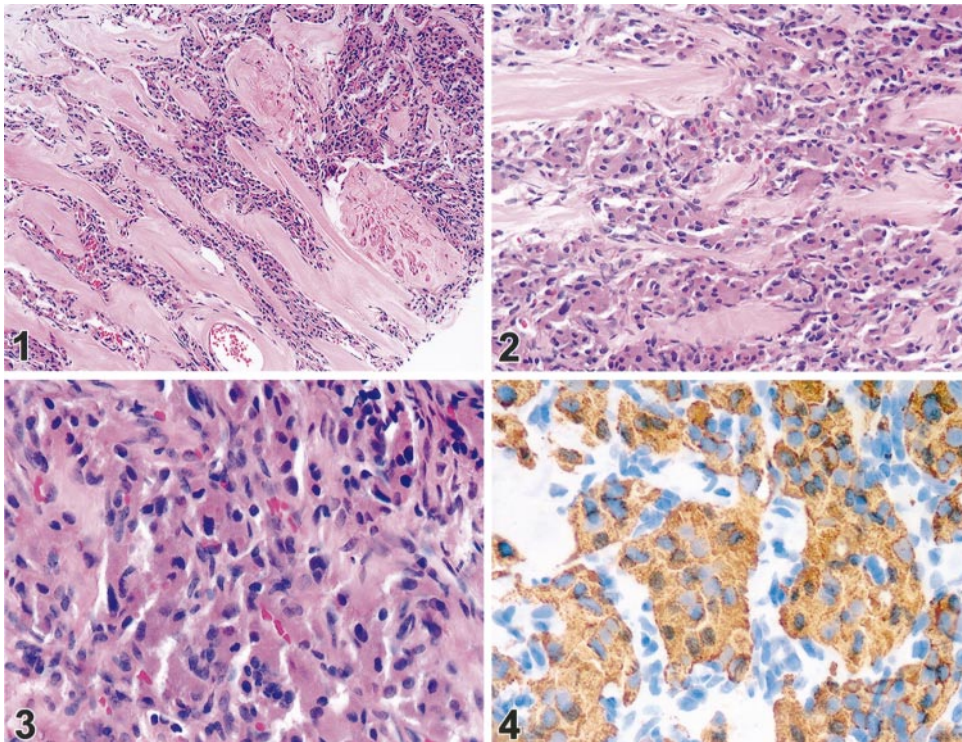
What is your diagnosis?

Accepted for publication March 11, 2004.

From the Departments of Pathology (Drs Parwani, Cao, and Epstein) and Oncology (Dr Epstein), The Johns Hopkins Hospital, Baltimore, Md.

The authors have no relevant financial interest in the products or companies described in this article.

Corresponding author: Jonathan I. Epstein, MD, The Johns Hopkins Hospital, Weinberg Bldg, Room 2242, 401 N Broadway St, Baltimore, MD 21231 (e-mail: jepstein@jhmi.edu).



Pathologic Diagnosis: Paranglioma Involving the Prostate

The histopathologic appearance of the lesion in this patient is typical of a paraganglioma, with small nests (zellballen) or clusters of round cells surrounded by fibrous trabeculae. The tumor cells have abundant, granular, eosinophilic cytoplasm and are uniform and mostly round. The nuclei have a salt-and-pepper appearance, with occasional nuclear pleomorphism and rare mitoses. By electron microscopy, neuroendocrine granules may be seen.¹

A diagnosis of prostate carcinoma in a young patient such as this one, and with an unusual presentation, must be made with caution. Immunostaining can be performed easily. Most cases of paragangliomas are positive for chromogranin and synaptophysin. Immunostains for S100 highlight the sustentacular cells often surrounding nests of tumor cells.¹ In the current case, because of the location and the histologic appearance, a high-grade prostatic adenocarcinoma was considered in the differential diagnosis. Immunostains for prostate-specific antigen, prostate-specific acid phosphatase, cytokeratin 7, cytokeratin 20, cytokeratin 903, and thrombomodulin were negative, while those for chromogranin and synaptophysin were strongly positive.

Parangliomas are slow-growing, usually benign neoplasms that can be found in a variety of locations, including genitourinary sites, such as kidney, spermatic cord, bladder, urethra, and prostate.^{2,3} These are rare tumors thought to arise from the extraadrenal chromaffin cells, which may originate from the sympathetic nervous system or parasympathetic ganglia.⁴ Those arising from parasympathetic ganglia are usually found in the head and neck region, such as the carotid body paraganglioma. Tumors arising from the sympathetic nervous system are generally located in the retroperitoneum and may secrete catecholamine. Up to 60% of retroperitoneal paragangliomas can be functional, with symptoms and signs of norepinephrine overproduction. Parangliomas can metastasize to bones, lymph nodes, and lungs.⁴ Paranglia are present in close proximity to the prostate and urinary bladder, and therefore paragangliomas may arise in these locations. Parangliomas of the prostate are rare, and only a few cases have been reported in the literature to date.⁵⁻⁹ Because of their rarity in the prostate, paragangliomas may be misinterpreted as prostate carcinoma. The first case of paraganglioma involving the prostate was described by Mehta et al in 1979⁸ and was of a malignant paraganglioma of the prostate, which was metastatic to the retroperitoneal area. The neoplasms may be functional or nonfunctional and benign or malignant. Most of the cases have been identified in adults, but there have been rare reports in the pediatric population.¹⁰

Boyle et al⁵ reported 3 cases of paragangliomas arising in the prostatic urethra. The tumors occurred in elderly men, 2 of whom presented with hematuria; the third patient had obstructive symptoms. Patients were treated with local excision, and there were no recurrences or metastases at 5 and 6 years in 2 patients for whom follow-up was available.⁵

Based on the clinical presentation and the location of the tumor in the patient described in this report, it is possible that the paraganglioma originated in the urinary bladder and involved the prostate by extension. Parangan-

gliomas of the urinary bladder are more common than those originating in the prostate. Of the extraadrenal paragangliomas, approximately 10% are found in the bladder wall. Primary paragangliomas of the bladder have a female-male ratio of 3:2, with an average age at diagnosis of 41 years. There is a wide age distribution, from childhood to the elderly. Most tumors are located either on the dome or the trigone. Although the majority of patients have exophytic lesions with an intact mucosa, in a minority of cases there may be ulceration of the overlying mucosa. The majority of patients present with solitary lesions.^{3,11}

Parangliomas arising in the pelvis may present with metastatic disease into the prostate and surrounding region. Taue et al¹² reported a case of pelvic malignant paraganglioma in a 47-year-old man who was treated with surgery, combination chemotherapy, and radiation. The pelvic mass had invaded the prostate, seminal vesicle, and bladder neck.¹²

The clinical presentation of paragangliomas can be highly variable, depending on the functional status of the tumor. If the tumor is functional, the clinical manifestations result from catecholamine secretion and include changes in blood pressure (usually hypertension), tachycardia, anxiety, sweating, flushing, palpitations, and headaches. The attacks may be precipitated by micturition. The laboratory diagnosis is made by detecting an elevation of the 24-hour urinary total metanephrine and metabolic products (vanillylmandelic acid). Imaging studies may be useful, including the use of computed axial tomography, magnetic resonance imaging, and scintigraphy with iodine 131-metiodobenzylguanidine.^{4,13}

Due to asymptomatic presentation or nonspecific symptoms, diagnosis of paraganglioma may not be made until an advanced stage. In some patients, particularly those with familial syndromes, paragangliomas may be multifocal. Multifocality may be misinterpreted as metastasis. In the patient described in this report, the initial presentation was hematuria and obstructive symptoms. There were no functional manifestations of the paraganglioma. The patient was normotensive, and review of symptoms did not reveal any evidence of hypercatecholaminemia.

Treatment options for paragangliomas include surgical resection as well as radiation therapy. The latter is best used for palliative relief of pain associated with bone metastasis. Tumor size and location are important prognostic indicators.² Therefore, early diagnosis is very important and can make a difference in successful outcome.

References

1. Linnoila RI, Keiser HR, Steinberg SM, Lack EE. Histopathology of benign versus malignant sympathoadrenal paragangliomas: clinicopathologic study of 120 cases including unusual histologic features. *Hum Pathol.* 1990;21:1168-1180.
2. Pederson LC, Lee JE. Pheochromocytoma. *Curr Treat Options Oncol.* 2003;4:329-337.
3. Zhou M, Epstein JI, Young RH. Paraganglioma of the urinary bladder: a lesion that may be misdiagnosed as urothelial carcinoma in transurethral resection specimens. *Am J Surg Pathol.* 2004;28:94-100.
4. Bryant J, Farmer J, Kessler LJ, Townsend RR, Nathanson KL. Pheochromocytoma: the expanding genetic differential diagnosis. *J Natl Cancer Inst.* 2003;95:1196-1204.
5. Boyle M, Gaffney EF, Thurston A. Paraganglioma of the prostatic urethra: a report of three cases and a review of the literature. *Br J Urol.* 1996;77:445-448.
6. Dennis PJ, Lewandowski AE, Rohner TJ Jr, Weidner WA, Mamourian AC, Stern DR. Pheochromocytoma of the prostate: an unusual location. *J Urol.* 1989;141:130-132.
7. Hasselager T, Horn T, Rasmussen F. Paraganglioma of the prostate: a case report and review of the literature. *Scand J Urol Nephrol.* 1997;31:501-503.

8. Mehta M, Nadel NS, Lonni Y, Ali I. Malignant paraganglioma of the prostate and retroperitoneum. *J Urol*. 1979;121:376–378.
9. Nielsen VM, Skovgaard N, Kvist N. Pheochromocytoma of the prostate. *Br J Urol*. 1987;59:478–479.
10. Voges GE, Wippermann F, Duber C, Hohenfellner R. Pheochromocytoma in the pediatric age group: the prostate—an unusual location. *J Urol*. 1990;144:1219–1221.
11. Cheng L, Leibovich BC, Cheville JC, et al. Paraganglioma of the urinary bladder: can biologic potential be predicted? *Cancer*. 2000;88:844–852.
12. Taue R, Takigawa H, Sinotou K, et al. A case of pelvic malignant paraganglioma. *Int J Urol*. 2001;8:715–718.
13. Shapiro B, Gonzalez E, Weissman A, McHugh T, Markel SF. Malignant paraganglioma of the prostate: case report, depiction by meta-iodobenzylguanidine scintigraphy and review of the literature. *Q J Nucl Med*. 1997;41:36–41.