

Pigmented “Black” Pheochromocytoma of the Adrenal Gland

A Case Report and Review of the Literature

Guido Bellezza, MD; Michele Giansanti, MD; Antonio Cavaliere, MD; Angelo Sidoni, MD

● A pigmented “black” mass was discovered incidentally in a 72-year-old woman. The tumor, which was detected near the upper pole of the left kidney, was cystic and intensely black throughout with the presence of abundant, coarse, dark brown to black pigment granules. Histologic examination showed a proliferation of monomorphic neoplastic cells arranged in a typical zellballen growth pattern. These features indicated a diagnosis of pheochromocytoma. Immunostains for chromogranin A, synaptophysin, and neuron-specific enolase were positive. The immunostain for HMB-45 was negative. Electron microscopy showed neurosecretory-type granules and larger pleomorphic granules, which were considered most consistent with neuromelanin, a waste product of catecholamine metabolism. The evidence of melanin or melanin-like pigment in the adrenal gland has been described in only 10 cases in the literature and is always a microscopic finding. The case reported here is unique for the characteristic black macroscopic appearance and the abundance of pigment.

(*Arch Pathol Lab Med.* 2004;128:e125–e128)

Several types of tumors, including adrenal cortical adenomas, schwannomas, ganglioneuroblastomas, pulmonary carcinoid tumors, medullary thyroid carcinomas, and dermatofibrosarcoma protuberans, have been reported to be melanotic or pigmented. In contrast, pigmented paragangliomas of the adrenal gland are very unusual neoplasms that are rarely reported in the literature^{1,2} and never have macroscopic evidence of pigmentation. The pigment, which is still of uncertain origin, has been classified variously by histochemical and ultrastructural analyses as lipofuscin, neuromelanin, or true melanin.³ Histochemical distinction among these types of pigments is often difficult and, regarding melanin, a clear ultrastructural documentation of melanosomes or promelanosomes is necessary. The existence of a primary malignant mela-

noma of the adrenal gland has also been described,⁴ but its occurrence has been refuted by other investigators.⁵

We report a case of a pigmented “black” pheochromocytoma and review the pertinent literature regarding pigmented or melanotic adrenal and extra-adrenal paragangliomas.

REPORT OF A CASE

A 72-year-old woman with a history of mild hypertension was being evaluated for the surgical treatment of cholelithiasis when an ultrasound showed a cystic mass in the retroperitoneal space close to the left kidney. A computed tomographic scan of the upper abdomen revealed that the mass was closely related to, but separate from, the upper pole of the left kidney and was compressing the pancreas tail and spleen (Figure 1). The lesion was considered to be arising from the left adrenal gland. Preoperative laboratory screening for catecholamines and their metabolites was not performed because there was no clinical suspicion for an endocrine neoplasm. The patient underwent left adrenalectomy with resection of the mass. The postoperative course was uneventful, and the patient is free of disease 1 year after surgery.

PATHOLOGIC FINDINGS

The tumor weighed 280 g and measured 15 × 11 × 7.5 cm. A rim of the left adrenal gland was still evident (Figure 2). At external inspection, the tumor was dark in color and cystic, containing a reddish brown fluid. In cross section, the tumor was intensely black throughout and had a smooth internal surface (Figure 3). The intraoperative frozen-section diagnosis was probable pigmented paraganglioma.

Histologically, the tumor had an alveolar pattern with a rich and delicate microvasculature and comprised large cells with inconspicuous cell borders and round to oval nuclei with minimal pleomorphism. No necrosis or mitoses was found. Neoplastic cells contained small, round, dark brown to black granules in the cytoplasm that varied from cell to cell. In some areas they were so abundant that the nuclei were partially obscured (Figure 4).

The pigment gave a positive reaction with Masson-Fontana stain (Figure 5), which completely disappeared after pretreatment of the section with potassium permanganate. Periodic acid-Schiff, iron stains, and Ziehl-Neelsen stains were negative. No autofluorescence was detected. Tumor cells were intensely positive for chromogranin A throughout and for other neuroendocrine markers, such as synaptophysin and neuron-specific enolase. S100 was positive only in sustentacular cells. The immunostain for HMB-45

Accepted for publication June 15, 2004.

From the Institute of Pathological Anatomy and Histology, Division of Cancer Research, Perugia Medical School, University of Perugia, Italy.

The authors have no relevant financial interest in the products or companies described in this article.

Corresponding author: Guido Bellezza, MD, Istituto di Anatomia e Istologia Patologica, Policlinico Montelucre, I-06122 Perugia, Italia (e-mail: anapat1@unipg.it).

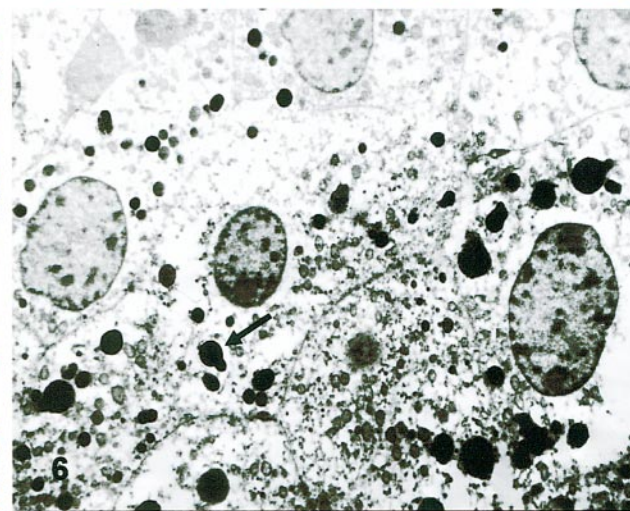
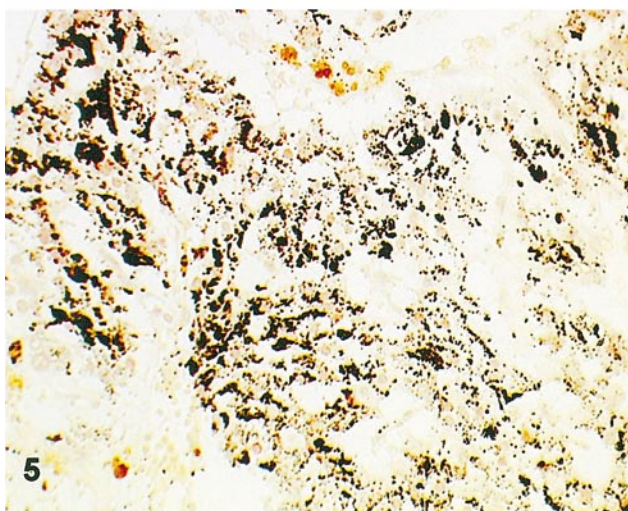
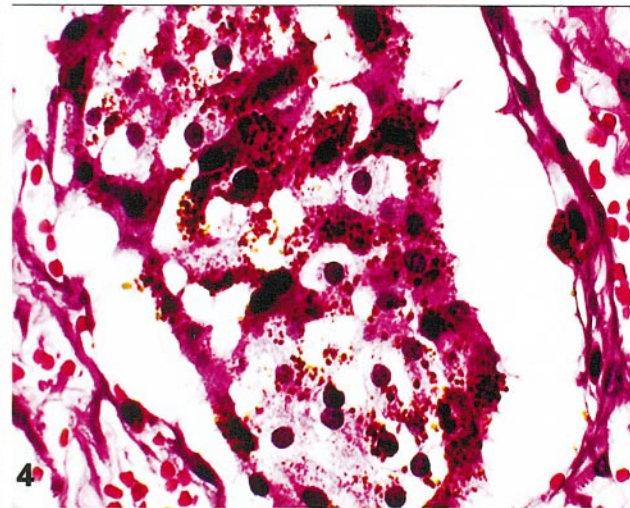
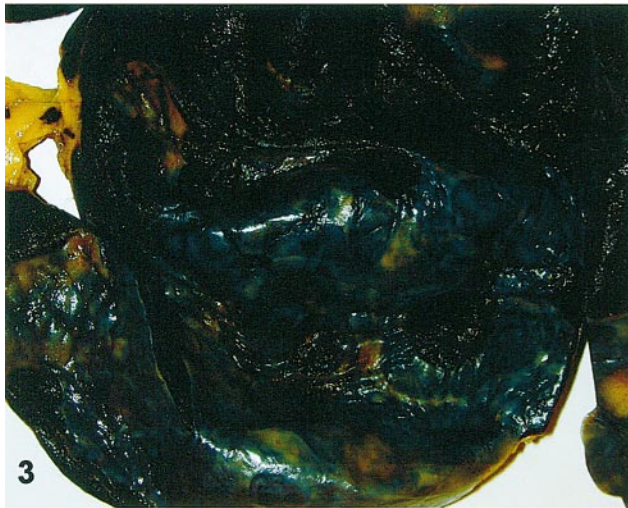
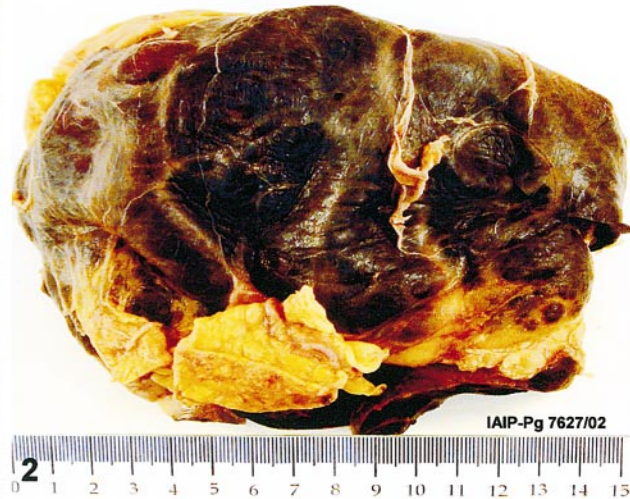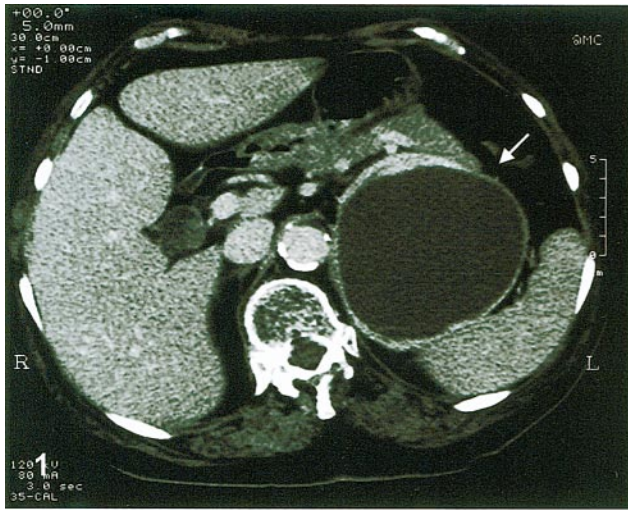


Figure 1. Computed tomographic scan of the upper abdomen shows a well-defined mass (arrow) that compresses the pancreas tail and spleen.
Figure 2. At external inspection, the tumor is black. A rim of the left adrenal gland is still evident.
Figure 3. In cross section, the tumor is intensely black throughout.
Figure 4. Tumor cells show abundant, coarse, black granules. Some nuclei are partially obscured (hematoxylin-eosin, original magnification $\times 400$).
Figure 5. Pigment is intensely positive with Masson-Fontana stain (original magnification $\times 200$).
Figure 6. Pigment granules vary in electron density, size, and shape; the larger granules have an oval or pear-shaped configuration (arrow). No premelanosomes or melanosomes are present (original magnification $\times 7500$).

Source, y	Cases, No.	Pigmentation	
		Macroscopic	Microscopic
Landas et al, ² 1993	6	...	6
Chetty et al, ¹ 1993	3	...	3
Langner et al, ¹⁰ 2001	1	...	1
Present case	1	1	1

Source, y	Cases, No.	Location
Stout, ¹¹ 1935	1	Ganglion nodosum
Tavassoli, ¹² 1986	2	Uterus
Paulus et al, ¹³ 1989	1	Orbit
Hofmann et al, ¹⁴ 1995	1	Posterior mediastinum
Küchemann, ¹⁵ 1995	1	Retroperitoneum
Moran et al, ³ 1997	5	Bladder, spine (2 cases), anterior mediastinum, and retroperitoneum
Lack et al, ⁷ 1998	1	Retroperitoneum
Mikolaenko et al, ⁹ 2001	1	Left atrium

and cytokeratin was negative, while vimentin was positive only in endothelial cells.

Electron microscopy, obtained from formalin-fixed and paraffin-embedded tissue, substantially revealed 2 types of granules in the neoplastic cells. The smaller granules had a dense core, were uniform in shape, and measured approximately 100 to 200 nm. In some fields, a halo around the dense core was evident. These granules were considered neurosecretory-type. The larger granules varied in electron density, size, and shape, with budding and oval configurations that suggested coalescence with other granules (Figure 6). Therefore, it was considered that these granules contained neuromelanin, a conclusion based on the previously reported histochemical results.

COMMENT

Several histologic variants of pheochromocytoma, including spindle cell, oncocytic, angiomatous, and gangli-neuromatous, have been described.⁶ However, melanin or melanin-like pigment production by the cells of classic and sporadic pheochromocytoma is very unusual. In a series of 120 adrenal and extra-adrenal paragangliomas, Linnoila et al⁶ did not find this kind of pigment, while other authors were able to identify melanin or melanin-like pigment in 6 of 19 pheochromocytomas.² Overall, in the few cases of pigmented pheochromocytoma previously reported in literature, macroscopic evidence of pigmentation was never described (Table 1). Also, for paragangliomas of extra-adrenal sites, the presence of pigmentation is an unusual occurrence (Table 2). The case reported here is extraordinary because of the abundance of pigment and the intense black color. In the literature there is only one other case of a paraganglioma with a similar macroscopic appearance, but the tumor was located in an extra-adrenal site (Table 2).⁷

The precise nature of the pigment is not always identifiable without complete histochemical characterization or electron microscopy. Alternative interpretations for this pigment include melanin, lipofuscin, or neuromelanin, a

waste product of catecholamine metabolism. The presence of melanin in pheochromocytoma has been reported,² and the common embryogenesis of chromaffin cells, chief cells, and melanocytes from neural crest may help explain it. HMB-45, a marker considered specific for malignant melanoma, has been reported to be expressed in pheochromocytomas.⁸ On these bases, the term *melanotic pheochromocytoma* has been proposed for primary adrenal malignant melanoma deriving from pheochromocytes in which there is a well documented production of melanin. The presence of melanocytes in the adrenal gland has not yet been clearly demonstrated.

However, apart from these histogenetic hypotheses, pigmented pheochromocytoma must be well distinguished from primary or metastatic malignant melanoma of the adrenal gland. Because of the high frequency of metastatic involvement of the adrenal gland by cutaneous and ocular melanomas, rigid criteria have been proposed to establish a diagnosis of primary adrenal melanomas.⁴ These diagnostic criteria are based on clinical information (no prior or current malignant melanoma and no history of removal of pigmented skin or eye lesions) and pathologic findings, such as presence of a malignant melanoma in only one of the adrenals. In the literature there are 6 cases that are considered primary malignant melanoma by these criteria.⁴ Furthermore, microscopic and histochemical findings and a very aggressive biological course ruled out the alternative diagnosis of pigmented pheochromocytoma. Obviously, immunohistochemical profile and ultrastructural evidence of promelanosomes and melanosomes are extremely important to distinguish pigmented pheochromocytoma from primary or metastatic malignant melanoma, as in the case reported here.

Another interesting point is the distinction between lipofuscin and neuromelanin. Lipofuscin has been found in carotid body chief cells,⁷ as well as in neoplastic chief cells of the carotid body and jugular paragangliomas. Histochemically, lipofuscin may give misleading staining patterns such as argentaffin positivity, but it is usually considered positive with periodic acid-Schiff and Ziehl-Neelsen stains. Both pigments are similar when ultrastructurally viewed.

Neuromelanin function has yet to be determined. This substance is considered a waste product of catecholamine metabolism, derived from the oxidation of dopamine, norepinephrine, and compounds related to quinones. One of its functions is to protect the cell against toxic quinones produced from catecholamines. It is believable that, in particular conditions such as the neoplastic process, an excessive production of catecholamines may cause defects in their cytoplasmatic storage, transport, or degradation and favor accumulation of neuromelanin by an auto-oxidative pathway. Therefore, because of some different histochemical properties with untreated lipofuscin such as absence of autofluorescence under fluorescence microscopy, it has been suggested that neuromelanin may be a melanized lipofuscin. This aspect could be confirmed by findings of neuromelanin-like lipofuscin in pigmented adrenal cortical nodules, primary pigmented nodular adrenocortical disease, and black thyroid syndrome. However, apart from the exact nature of this pigment, it appears clear that pigment production such as neuromelanin-like lipofuscin or neuromelanin, other than imparting a peculiar gross or histologic appearance, does not alter the biologic behavior of adrenal or extra-adrenal paragangliomas.^{3,9}

In conclusion, to the best of our knowledge this is the first case of a grossly pigmented black pheochromocytoma that expands the morphologic spectrum of these neoplasms. The presence of abundant pigment is most probably due to accumulation of neuromelanin or neuromelanin-like lipofuscin.

This work was supported by funds granted to the First Chair of Pathologic Anatomy and Histology, University of Perugia, from the MIUR, Rome, Italy.

References

1. Chetty R, Clark SP, Taylor DA. Pigmented pheochromocytomas of the adrenal gland. *Hum Pathol*. 1993;24:420–423.
2. Landas SK, Leigh C, Bonsib SM, Layne K. Occurrence of melanin in pheochromocytoma. *Mod Pathol*. 1993;6:175–178.
3. Moran CA, Albores-Saavedra J, Wenig BM, Mena H. Pigmented extraadrenal paragangliomas: a clinicopathologic and immunohistochemical study of five cases. *Cancer*. 1997;79:398–402.
4. Dao AH, Page DL, Reynolds VH, Adkins RB Jr. Primary malignant melanoma of the adrenal gland: a report of two cases and review of the literature. *Am Surg*. 1990;56:199–203.
5. Dasgupta T, Brasfield R. Metastatic melanoma: a clinicopathological study. *Cancer*. 1964;17:1323–1339.
6. Linnoila RI, Keiser HR, Steinberg SM, Lack EE. Histopathology of benign versus malignant sympathoadrenal paragangliomas: clinicopathologic study of 120 cases including unusual histologic features. *Hum Pathol*. 1990;21:1168–1180.
7. Lack EE, Kim H, Reed K. Pigmented (“black”) extraadrenal paraganglioma. *Am J Surg Pathol*. 1998;22:265–269.
8. Unger PD, Hoffman K, Thung SN, Pertselides D, Wolfe D, Kaneko M. HMB-45 reactivity in adrenal pheochromocytomas. *Arch Pathol Lab Med*. 1992;116:151–153.
9. Mikolaenko I, Galliani CA, Davis GG. Pigmented cardiac paraganglioma. *Arch Pathol Lab Med*. 2001;125:680–682.
10. Langner C, Hoffmann JG, de Geeter P, Rompel R, Ruschoff J. Pigmented pheochromocytoma: case report with immunohistochemical and electron microscopic characterization. *Pathologie*. 2001;22:276–280.
11. Stout AP. Malignant tumors of peripheral nerves. *Am J Cancer*. 1935;25:1–36.
12. Tavassoli FA. Melanotic paraganglioma of the uterus. *Cancer*. 1986;58:942–948.
13. Paulus W, Jellinger K, Brenner H. Melanotic paraganglioma of the orbit: a case report. *Acta Neuropathol (Berl)*. 1989;79:340–346.
14. Hofmann WJ, Wöckel W, Thetter O, Otto HF. Melanotic paraganglioma of the posterior mediastinum. *Virchows Arch*. 1995;425:641–646.
15. Küchemann K. A rare case of pigmented paraganglioma. *Virchows Arch*. 1995;427:111–112.