

## Pathologic Quiz Case

### An Indurated Plaque on the Ankle of a 74-Year-Old Woman

*Koushan Siami, MD; Michael Wilkerson, MD; Sandra H. Clark, MD; A. Neil Crowson, MD*

**A** 74-year-old woman presented with violaceous to erythematous, nonpruritic plaques that had involved the skin of her right ankle for 18 months (Figure 1). The plaques were irregular and had relatively demarcated

margins, and they coalesced to form larger plaques (Figure 1, arrows). Her past medical history was significant for hypertension, breast cancer, and fatty liver. She had been on multiple medications, including atenolol ( $\beta$ -blocker), moexipril (an angiotensin-converting enzyme [ACE] inhibitor), hydrochlorothiazide (a diuretic), and raloxifene, for several years.

A punch biopsy of the lesion was performed, revealing a diffuse interstitial and perivascular histiocytic infiltration in the superficial and deep dermis and subcutaneous fat, admixed with a few lymphocytes and occasional eosinophils (Figures 2 through 4). The histiocytic infiltrate was bottom heavy and prominent in the deep dermis and subcutaneous tissue. The epidermis revealed subtle changes, including basilar vacuolopathy with lymphocytes tagging along the dermoepidermal junction.

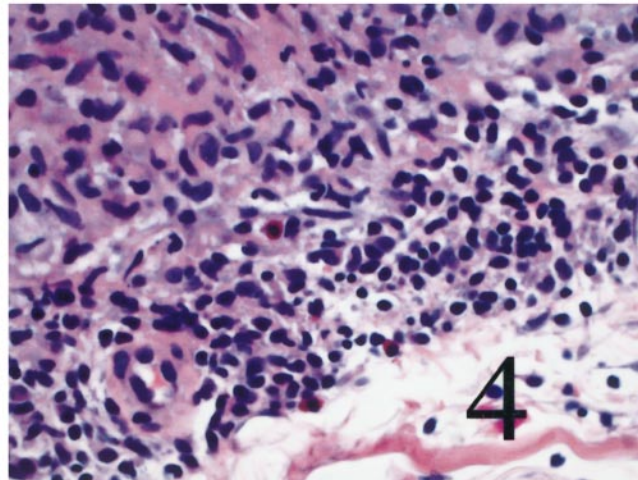
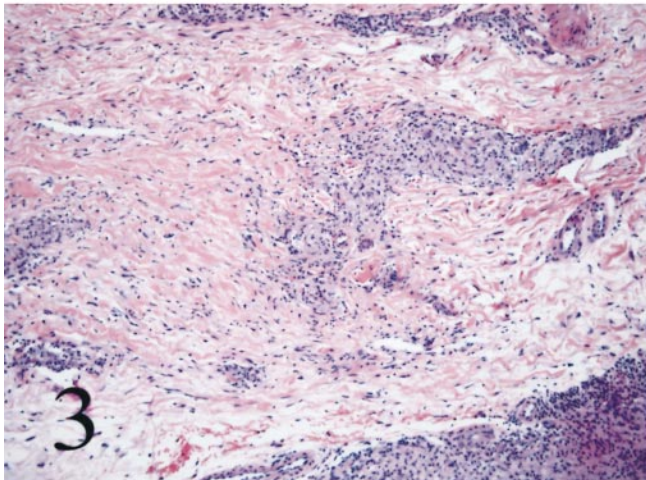
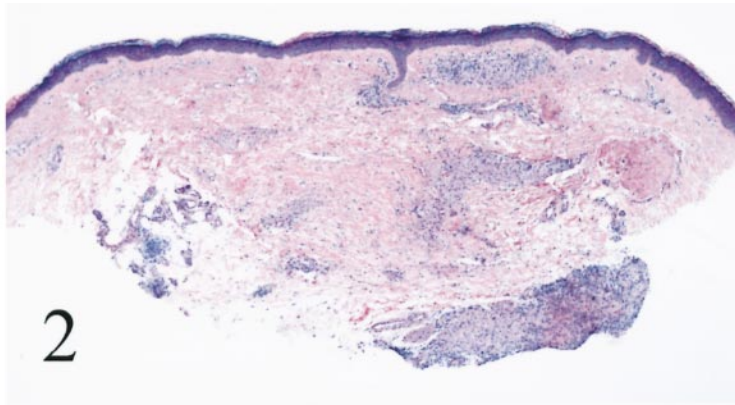
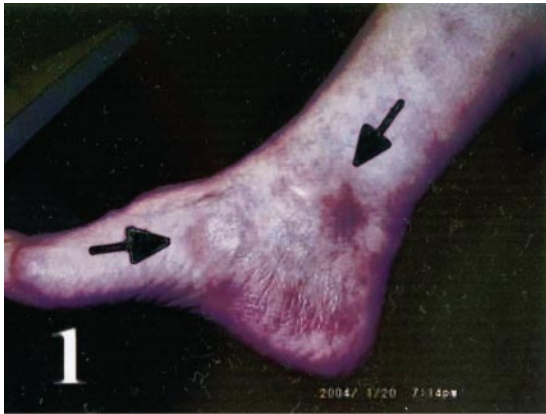**What is your diagnosis?**

Accepted for publication June 1, 2004.

From the Department of Pathology, University of Oklahoma, Health Sciences Center, Oklahoma City (Dr Siami); and the Departments of Dermatology and Pathology, University of Oklahoma, Oklahoma City, and Regional Medical Laboratory, St John Medical Center, Tulsa (Drs Clark and Crowson). Dr Wilkerson is in private practice with the Hillcrest Medical Group/Dermatology, Tulsa, Okla.

The authors have no relevant financial interest in the products or companies described in this article.

Corresponding author: Koushan Siami, MD, Department of Pathology, University of Oklahoma, Health Sciences Center, 940 Stanton L. Young Blvd, Oklahoma City, OK 73104 (e-mail: ksiaminamini@hotmail.com).



## Pathologic Diagnosis: Interstitial Granulomatous Drug Reaction

Granulomatous dermatitis in response to drug therapy is traditionally described in the context of erythema nodosum in the setting of oral contraceptive and sulfonamide intake.<sup>1</sup> The interstitial granulomatous drug reaction is a distinctive clinicopathologic entity that presents as violaceous to erythematous, nonpruritic plaques with bizarre shapes or an annular morphology involving the fold areas of the skin, such as the axillary folds, inner aspects of arms, groin, medial thighs, and popliteal fossae.<sup>1</sup> The clinical differential diagnosis of infiltrated plaques in this distribution includes cutaneous T-cell lymphoma, erythema annulare centrifugum, granuloma annulare, and subacute cutaneous lupus erythematosus, among others.<sup>2</sup> Implicated drugs include calcium channel blockers,  $\beta$ -blockers, lipid-lowering agents, ACE inhibitors, diuretics, nonsteroidal anti-inflammatory drugs, antihistamines, antidepressants, and oral hypoglycemic agents.<sup>2</sup> The patients are frequently on more than 1 of the aforementioned drugs, with a mean duration of 5 years prior to the onset of eruptions. The eruptions resolve within 1 to 40 weeks (mean, 8 weeks) following discontinuation of the implicated drug.<sup>2</sup> All of these agents are known to have immune-dysregulating properties, and all are associated with cutaneous pseudolymphomata.<sup>2</sup> As with pseudolymphomatous drug reactions, a temporal association between the initiation of the drug therapy and lesional onset is often tenuous, and the time course between lesional resolution and drug cessation is several weeks to months, much longer than conventional drug reactions. In some cases, inherent immune dysregulation may have promoted an exaggerated immune response to drugs.

The histologic hallmark of the interstitial granulomatous drug reaction is a diffuse granulomatous dermatitis manifested by interstitial histiocytes, including giant cells, in close apposition to collagen and elastic fibers, often associated with piecemeal fragmentation of collagen, elastic fiber engulfment by giant cells, and variable interstitial mucin deposition. Complete collagen necrobiosis with a palisading histiocytic infiltrate is rarely seen. Although blood vessels are infiltrated by mononuclear cells, fibrin deposition and vasculitis are not present. The epidermis usually reveals an interface dermatitis comprising basilar vacuolopathy and focal dyskeratosis with lymphocytes tagging along the dermoepidermal junction, involving mainly the interfollicular epidermis; in some cases, the hair follicles and acrosyringia are also affected. In some cases, there is a lichenoid pattern of infiltration. Extravasated red blood cells, when present, raise consideration to

the pigmented purpuric dermatoses. Tissue eosinophilia is present in most cases. Lymphoid atypia is commonly seen and is characterized by mononuclear cells whose nuclei are hyperchromatic, small to medium-sized (8–18  $\mu\text{m}$ ), with convoluted nuclear contours, including a cerebriform morphology. The latter usually present as a few singly disposed lymphocytes (mainly in the dermal infiltrate) and are not present within the epidermis, contrary to cutaneous T-cell lymphoma, in which characteristically the most atypical lymphocytes are seen within the epidermis.<sup>2</sup>

The histologic differential diagnosis includes granuloma annulare and granuloma annulare–like tissue reactions in the context of systemic disease,<sup>2</sup> which differ from granulomatous drug reactions by the presence of vasculitis or vasculopathy. In those cases with lymphoid atypia, differentiating granulomatous cutaneous T-cell lymphoma and its variant, granulomatous slack skin,<sup>3</sup> is a particular challenge. Microscopic features favoring a granulomatous drug reaction include an intraepidermal lymphoid population, which while atypical does not exceed the nuclear size of the dermal component, in concert with papillary dermal edema, vesiculation, basilar vacuolopathy, and dyskeratosis.

Our patient was on multiple drugs known to be associated with granulomatous drug reactions, including a diuretic, a  $\beta$ -blocker, and an ACE inhibitor,<sup>2</sup> and had been on these medications for several years before developing the lesion. All of these features are typical for the granulomatous and lymphomatoid drug reactions.<sup>2</sup> Although lesional resolution after cessation of the implicated agents (ACE inhibitor or  $\beta$ -blocker) is required for proof of our diagnosis, and it is too early to determine lesional resolution in our case, the histomorphology of the lesion is characteristic of the interstitial granulomatous drug reaction, and we strongly recommended discontinuation of the ACE inhibitor agent and follow-up of the lesion for complete resolution.

### References

1. Zurcher K, Krebs A. *Cutaneous Drug Reactions*. 2nd ed. Basel, Switzerland: S Karger Publishing; 1992:351–362.
2. Magro CM, Crowson AN, Schapiro BL. The interstitial granulomatous drug reaction: a distinctive clinical and pathologic entity. *J Cutan Pathol*. 1998;25:72–78.
3. Magro CM, Crowson AN. Drug-induced immune dysregulation as a cause of atypical cutaneous lymphoid infiltrates: a hypothesis. *Hum Pathol*. 1996;27:125–132.
4. Magro CM, Crowson AN, Regauer S. Granuloma annulare and necrobiosis lipoidica tissue reactions as a manifestation of systemic disease. *Hum Pathol*. 1996;27:50–56.
5. LeBoit PE, Zakheim HS, White CR Jr. Granulomatous variants of cutaneous T-cell lymphoma: the histopathology of granulomatous mycosis fungoides and granulomatous slack skin. *Am J Surg Pathol*. 1998;12:83–95.