

# Pathologic Quiz Case

## Multiple Cutaneous Lesions in a 27-Year-Old Woman

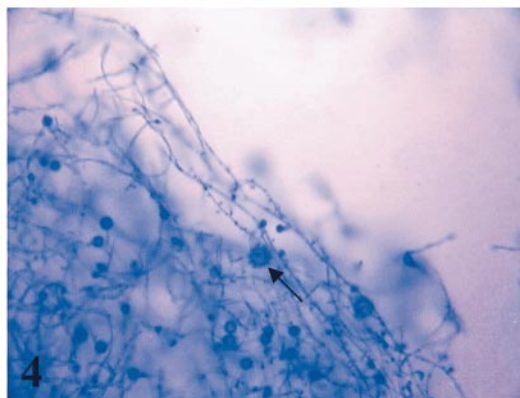
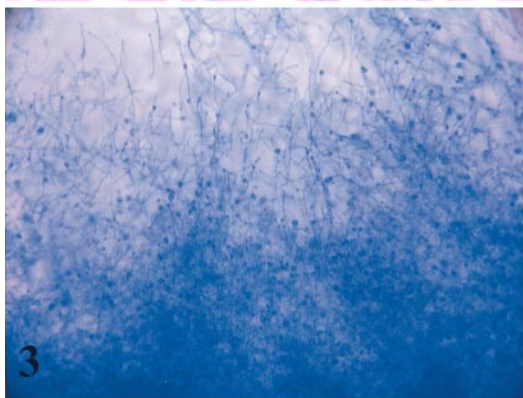
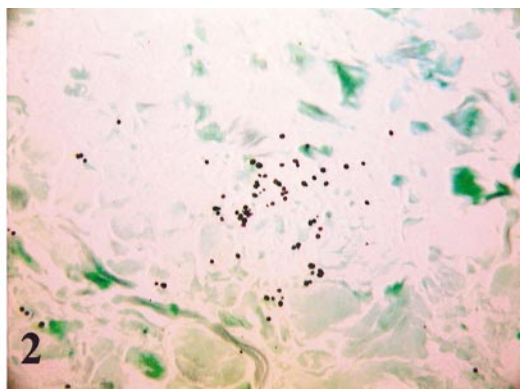
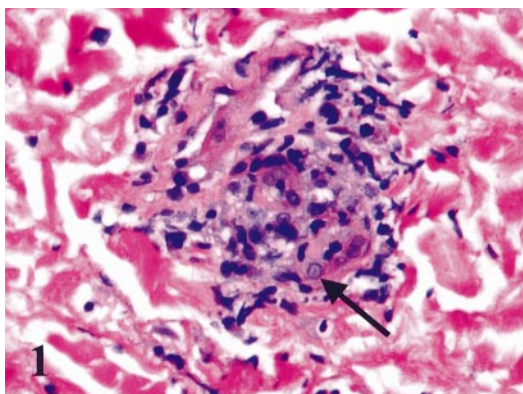
Joshua D. Stephany, MD; Raymond B. Franklin, MD, PhD; Anthony F. Walsh, PhD

**A** 27-year-old black woman presented with multiple cutaneous lesions consisting of nontender bumps over her face, trunk, and upper extremities that had been present for approximately 1 week. She also had fever, chills, night sweats, vomiting, and weight loss. She had no contact with anyone suffering from tuberculosis. Her past medical history was significant for asthma and scoliosis. Her past surgical history was significant for multiple cesarean sections, 7, 8, and 11 years prior to this presentation, with a bilateral tubal ligation following her last pregnancy. Her admission laboratory values were as follows: sodium, 128 mEq/L; potassium, 3.7 mEq/L; chloride, 100 mEq/L; bicarbonate, 25 mEq/L; serum urea nitrogen, 17 mg/dL (6.1 mmol/L); creatinine, 1.8 mg/dL (159  $\mu$ mol/L); glucose, 98 mg/dL (504 mmol/L); hemoglobin, 5.6 g/

dL; hematocrit, 17.2%; and white blood cell count, 5500/ $\mu$ L. Her total T-cell count was 437/ $\mu$ L with a CD4 count of 8/ $\mu$ L (1%). A chest radiograph demonstrated bilateral reticular infiltrates with nodules ranging in size from 1 to 2 mm. A bronchial alveolar lavage was negative for *Pneumocystis* species, viral inclusions, acid-fast bacteria, and fungal organisms. A punch biopsy of a skin lesion was performed.

Grossly, the specimen was a 0.3-cm, round, brown skin biopsy with 0.3-cm-thick attached subcutaneous tissue. Histologically, multiple budding yeasts were identified within the deep dermis (Figure 1; arrow indicates yeast). A Gomori methenamine silver stain better elucidated the organisms from the surrounding tissue (Figure 2). Culture of the skin biopsy incubated at 30°C on Sabouraud dextrose agar for 5 weeks grew a woolly to granular, white-brown mold with a yellowish reverse. Microscopically, the characteristic features of the mold were hyaline septate hyphae with characteristic thick-walled tuberculate macroconidia and microconidia observed when stained with lacto-phenol cotton blue (Figures 3 and 4; arrow indicates macroconidia).

**What is your diagnosis?**



Accepted for publication August 21, 2003.

From the Departments of Pathology (Drs Stephany and Franklin) and Microbiology (Dr Walsh), Orlando Regional Health Care, Orlando, Fla.

Corresponding author: Joshua D. Stephany, MD, Department of Pathology, Orlando Regional Health Care, 1414 Kuhl Ave, Orlando, FL 32806 (e-mail: jdsmd2@yahoo.com)

## Pathologic Diagnosis: Cutaneous *Histoplasmosis capsulatum*

*Histoplasmosis capsulatum* is a dimorphic saprophytic fungus found in soil contaminated with bird or bat excreta. It is endemic to the southeastern United States, Mexico, Africa, and Asia.<sup>1,2</sup> The route of exposure is by inhalation of spores, causing a primary pulmonary pneumonia that is typically self-limiting in immunocompetent patients. In immunocompromised patients, however, such as the very young, very old, or patients with acquired immunodeficiency syndrome (AIDS), the infection disseminates to the liver, spleen, bone marrow, and lymphoreticular system, but rarely to the skin.<sup>2,3</sup> Disseminated histoplasmosis was first described in a study of AIDS patients in 1983, with up to 75% of patients with the human immunodeficiency virus (HIV) initially presenting with the disease.<sup>2</sup> The correlation between disseminated histoplasmosis and AIDS is so prominent that by 1985 the Centers for Disease Control and Prevention revised the definition of AIDS to include patients with confirmed progressive disseminated histoplasmosis and serologic evidence of HIV.<sup>4</sup> The most common symptoms of disseminated disease are fever, weight loss (>4.5 kg), and splenomegaly. Although rare, progression of a primary pulmonary infection to disseminated disease may manifest as a variety of cutaneous lesions, including nodules, papules, and ulcers, and less commonly, macules, pustules, or vesicles.<sup>5</sup> Three histologic presentations are possible: isolated intracellular organisms; larger collections of organisms with a surrounding

tissue reaction characterized by the presence of macrophages, plasma cells, lymphocytes, fibroblasts, and the lack of neutrophils and eosinophils; or most commonly, epithelioid caseating and noncaseating granulomas.<sup>6</sup>

Diagnostic confirmation is attained by laboratory culture. *Histoplasmosis capsulatum* grows as a tan-white-brown woolly mold at 25°C to 30°C on Sabouraud dextrose agar. Microscopically, the hyphae are delicate, septate, and average 1 to 2 μm thick, with large rough-walled macroconidia ranging from 5 to 15 μm at their tip. The macroconidia are smooth early on, but after further incubation become covered with microconidia. Reversion from a mold to a yeast occurs when incubated at 37°C on sheep blood agar. The yeast is a budding, single-nucleate, 2- to 4-μm, round to oval structure with thin rigid walls.<sup>4</sup>

### References

1. Bonifaz A, Cansela R, Novales J, Montes de Oca G, Navarrete G, Romo J. Cutaneous histoplasmosis associated with acquired immunodeficiency syndrome (AIDS). *Int J Dermatol*. 2002;39:35–38.
2. Laochumroonvorapong P, DiCostanza D, Wu H, Srinivasan K, Abusamieh M, Levy H. Disseminated histoplasmosis presenting as *Pyoderma gangrenosum*-like lesions in a patient with acquired immunodeficiency syndrome. *Int J Dermatol*. 2001;40:518–521.
3. Wheat LJ, Conolly-Springfield PA, Baker RL, et al. Disseminated histoplasmosis in the acquired immune deficiency syndrome: clinical findings, diagnosis, and treatment, and review of the literature. *Medicine*. 1990;69:361–373.
4. Johnson PC, Khadori N, Najjar A, Butt F, Manswell PWA, Sarosi GA. Progressive disseminated histoplasmosis in patients with acquired immunodeficiency syndrome. *Am J Med*. 1988;85:152–158.
5. Ramdial PK, Mosam A, Dlova NC, Satar NB, Aboobaker J, Singh SM. Disseminated cutaneous histoplasmosis in patients infected with human immunodeficiency virus. *J Cutan Pathol*. 2002;29:215–225.
6. Reddy P, Gorelick DF, Brasher CA, Larsh H. Progressive disseminated histoplasmosis as seen in adults. *Am J Med*. 1970;48:629–636.