

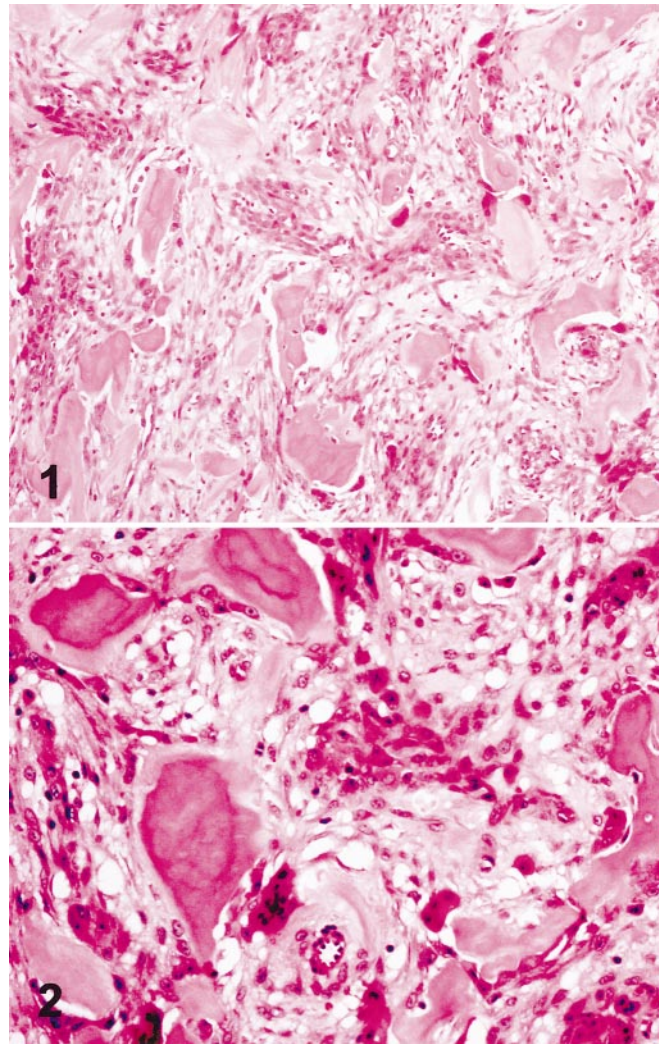
## Pathologic Quiz Case

### A Solitary Breast Nodule in an Elderly Woman

Philip C. W. Lui, MBBS; Lai-Man Pang, FRCR; Winnie C. W. Chu, FRCR; Gary M. K. Tse, FRCPC

**A** 69-year-old woman with no significant medical history presented with a 3-week history of a mass in the left breast. There was no history of trauma, and the lump was painless and static in size. On examination, a stony-hard, 1.5-cm mobile mass was noted at the upper outer quadrant of left breast, and the mass was not fixed to the overlying skin or the underlying chest wall. There was no axillary lymphadenopathy. Mammography showed a well-circumscribed, discrete nodule with bone density, and ultrasonography showed a strong acoustic shadowing with no definite soft tissue component. An image-guided needle-core biopsy and, later, a wide local excision of the bony nodule were performed, and the patient had an uneventful course after the excision. Gross examination showed a 1.5-cm well-circumscribed, spheric nodule, which cut with a gritty sensation and had a gray-white granular surface. No zonation pattern was identified. Histology showed the nodule to be within unremarkable breast parenchyma. The nodule was rounded and was clearly demarcated from the adjacent breast tissue (Figure 1). It was composed of mature lamellar bone trabeculae within a spindle cell stroma. The lamellar bone was rimmed by osteoblasts (Figure 2). The stroma was focally cellular with the bland-looking spindle cells showing rare mitoses. No ductal cells were seen within the nodule. A central area of hemorrhage and reactive spindle cell proliferation was noted, representing a previous biopsy site. These spindle cells expressed vimentin and smooth muscle actin, reflecting myofibroblastic differentiation.

**What is your diagnosis?**



Accepted for publication September 19, 2003.

From the Department of Pathology, United Christian Hospital, Hong Kong (Mr Lui); and the Departments of Diagnostic Radiology and Organ Imaging (Ms Pang and Ms Chu) and Anatomical and Cellular Pathology (Mr Tse), Prince of Wales Hospital, Chinese University of Hong Kong, HKSAR, China.

Corresponding author: Gary M. K. Tse, FRCPC, Department of Anatomical and Cellular Pathology, Prince of Wales Hospital, Ngan Shing St, Shatin, NT, Hong Kong SAR, China (e-mail: garytse@cuhk.edu.hk).

## Pathologic Diagnosis: Fasciitis Ossificans of the Breast

Metaplastic ossification of the breast is uncommon. It is reported in 1.3% of all breast cancers<sup>1</sup> and can also occur in benign breast lesions, including fibroadenoma, phyllodes tumor, pleomorphic adenoma, benign mesenchymoma, and primary localized amyloid tumor of the breast.<sup>1-4</sup> It can be associated with tumor and tumorlike conditions of mesenchymal origin, including fibrosarcoma, malignant mesenchymoma, osteosarcoma, and osteochondrosarcoma.<sup>2,5,6</sup> Rarely, osseous metaplastic foci can be seen in nonneoplastic diseases, such as chronic mastitis, fibromatosis, pseudohypoparathyroidism, and myositis ossificans and ossifying fibromatosis.<sup>1,7-10</sup>

In benign metaplastic ossification of the breast, the underlying etiology can be divided into 2 groups. More commonly, ossification is secondary, being superimposed on long-standing benign breast lesions, notably fibroepithelial lesions including fibroadenomas and phyllodes tumors. This group of lesions is characterized by the presence of a benign epithelial component. In fibroadenoma with ossification, typical pericanalicular or intracanalicular patterns can be discerned, thus facilitating the identification of the original lesion. Less commonly, the ossification process is primary and represents tumor and tumorlike conditions of mesenchymal origin, including fibrosarcoma, malignant mesenchymoma, osteosarcoma, and osteochondrosarcoma.<sup>2,5-7</sup> However, to our knowledge, a fasciitis ossificans-type lesion has not been previously reported in the breast. Fasciitis ossificans is a nonneoplastic heterotopic ossifying lesion that is usually solitary and well circumscribed, situated in the subcutaneous fatty tissue. The lesion passes through various stages of development, including the incipient prebone-forming phase (week 1) and various osseous phases (weeks 1-7). A similar lesion within muscle is known as myositis ossificans. Histologically, the lesions exhibit a range of histologic features with a mixture of immature myofibro-

blastic cells, osteoid, cartilage, and young or mature bone accompanied by fibrous connective tissue. Most cases of fasciitis ossificans lack the zonal pattern characteristic of myositis ossificans.

The mechanism of heterotopic bone formation in the breast remains poorly understood. In some neoplastic lesions, ossification may be due to the direct transformation of the tumor epithelium,<sup>1</sup> the ossification of calcific debris, stromal metaplasia, or metaplasia in areas of tumor mucin secretion.<sup>5</sup> In nonneoplastic lesions, ossifications may be related to the underlying inflammatory process, such as osteoma cutis, which is related to chronic folliculitis.

These rare benign processes should be considered clinically hard nodules that can easily be mistaken for malignancy. At imaging, small foci of heterotopic bone formation may also be labeled suspicious calcifications. The presence of a rounded contour, popcorn calcification on radiographic examination and the relatively static time course provide clues to these benign ossifying lesions.

## References

1. Spagnolo DV, Shilkin KB. Breast neoplasms containing bone and cartilage. *Virchows Arch A Pathol Anat Histopathol.* 1983;400:287-295.
2. Smith BH, Taylor HB. The occurrence of bone and cartilage in mammary tumors. *Am J Clin Pathol.* 1969;51:610-618.
3. Yokoo H, Nakazato Y. Primary localized amyloid tumour of the breast with osseous metaplasia. *Pathol Int.* 1998;48:545-548.
4. Lynch LA, Moriarty AT. Localized primary amyloid tumor associated with osseous metaplasia presenting as bilateral breast masses: cytologic and radiologic features. *Diagn Cytopathol.* 1993;9:570-575.
5. Gonzalez-Licea A, Yardley JH, Hartmann WH. Malignant tumor of the breast with bone formation. *Cancer.* 1967;20:1234-1247.
6. Jernstrom P, Lindberg AL, Meland ON. Osteogenic sarcoma of the mammary gland. *Am J Clin Pathol.* 1963;40:521-526.
7. Zung A, Herzenberg JE, Chalew SA. Radiological case of the month: ectopic ossification and calcification in pseudohypoparathyroidism and pseudopseudohypoparathyroidism. *Arch Pediatr Adolesc Med.* 1996;150:643-644.
8. Salomonowitz E, Youssefzadeh S, Reiner A, et al. Nontraumatic myositis ossificans in the breast. *Eur J Radiol.* 1991;12:130-131.
9. Kim JT, Yoon YH, Baek WK, et al. Myositis ossificans of the chest wall simulating malignant neoplasm. *Ann Thorac Surg.* 2000;70:1718-1720.
10. Mayers MM, Evans P, MacVicar D. Case report: ossifying fibromatosis of the breast. *Clin Radiol.* 1994;49:211-212.