

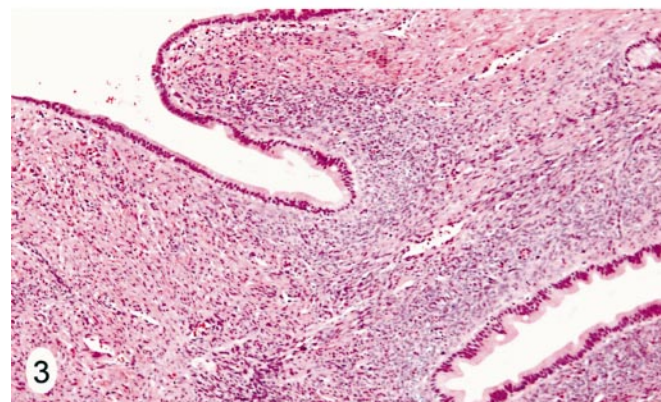
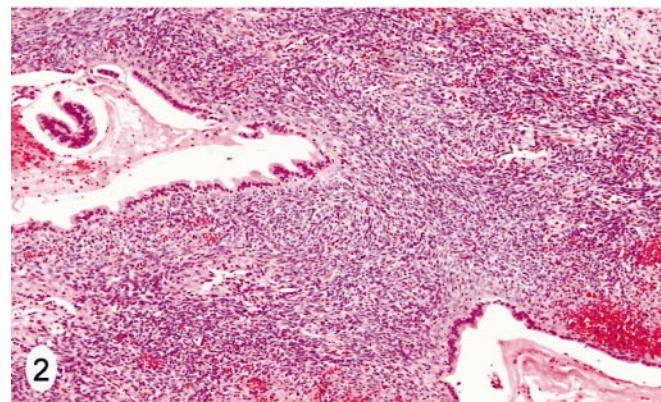
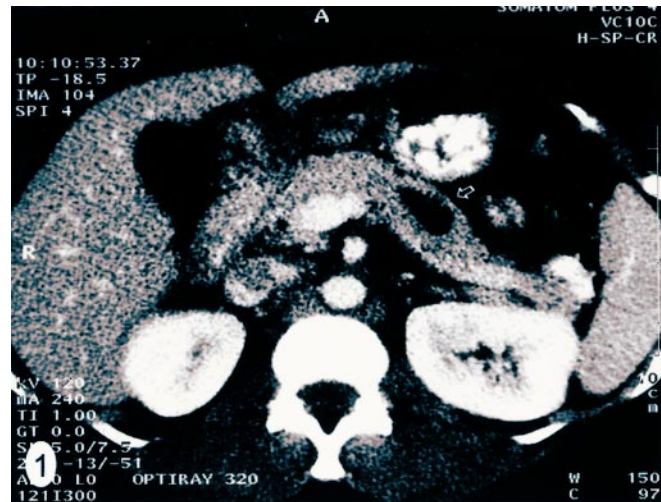# Pathologic Quiz Case

## A 32-Year-Old Western-Indian Woman With a History of Chronic Abdominal Pain and a Cystic Mass of Pancreas

Pamela Papas, MD; Mousa A. Al-Abadi, MD

A 32-year-old Western-Indian woman presented with a history of chronic abdominal pain dating back to her previous pregnancy and had previously been told that she had a pancreatic pseudocyst. She was admitted later to our hospital with abdominal pain, nausea, and vomiting in addition to anorexia for the past week. Her medical history was significant for 2 cesarean sections followed by tubal ligations. She was taking multiple pain medications. She denied tobacco use but admitted occasional alcohol consumption. Her family history was positive for colon cancer and diabetes mellitus. On physical examination, she appeared well nourished, although in mild distress, and her vital signs were stable. The abdomen was soft and slightly distended, with no tenderness. A laboratory work-up was performed, which included a complete blood count, electrolytes, and liver and kidney function tests in addition to amylase and lipase; all were within reference ranges. A previous abdominal ultrasound examination followed by an endoscopic retrograde cholangiopancreatography showed a 5-cm pancreatic cyst. A computed tomographic scan of the abdomen with contrast showed a 3.0-cm nonenhancing cyst in the body of the pancreas (Figure 1). The clinical impression was that of chronic pancreatitis with a pancreatic pseudocyst. Distal pancreatectomy was performed. Gross examination of the tissue specimen revealed a 2.1 × 1.9 × 1.6-cm unilocular cyst with a smooth inner lining containing tan mucoid material. The remainder of the pancreas appeared unremarkable. Extensive sampling of the cyst showed essentially similar microscopic features from one field to another (Figures 2 and 3).

**What is your diagnosis?**



Accepted for publication October 29, 2003.

From the Department of Pathology, Wayne State University/Detroit Medical Center, Sinai-Grace Hospital, Detroit, Mich. Dr Papas is now with the Department of Pathology, Northwest Community Hospital, Arlington Heights, Ill.

The authors have no relevant financial interest in the products or companies described in this article.

Corresponding author: Mousa Al-Abadi, MD, FCAP, Wayne State University/Detroit Medical Center, Department of Pathology, Sinai-Grace Hospital, 6071 W Outer Dr, Detroit, MI 48235 (e-mail: alabadi@dmc.org).

## Pathologic Diagnosis: Mucinous Cystic Neoplasm, Adenoma Type

Mucinous cystic neoplasms of the pancreas are usually multicystic and lined by mucinous epithelium, which is supported by ovarian-like cellular stroma, and they occur predominantly in middle-aged women. The mean age at diagnosis is 49 years, and the female-male ratio is 9:1.<sup>1-5</sup> By definition, they are not connected to the pancreatic duct system.<sup>1</sup> The presence of ovarian-like stroma and the absence of connection to the pancreatic duct system separate them from intraductal papillary mucinous neoplasms. They were first recognized as a distinct clinicopathologic entity in 1978 by Compagno and Oertel.<sup>1</sup> Clinically, mucinous cystic neoplasms are usually asymptomatic and discovered incidentally during radiologic workup for other reasons.<sup>6,7</sup> When symptoms are present, they are usually of the nonspecific upper abdominal type unless the cyst is large with compression to adjacent structures. The predominant location is the tail or the body of the pancreas.<sup>6</sup> Radiologically, mucinous cystic neoplasms exhibit large cysts averaging between 6 and 10 cm with thick capsules and occasionally solid areas.<sup>1,4,5</sup> Grossly, the tumor is characteristically well circumscribed and unicystic (occasionally multicystic) and contains thick viscous mucin, which is surrounded by a thick capsule that may contain calcifications. Microscopic examination usually reveals a single layer of mucinous epithelium, which is occasionally flattened or even denuded. Therefore, extensive sampling is recommended to rule out the possibility of a pancreatic pseudocyst or a more complex, often higher-grade mucinous cystic neoplasm.

Typically, an ovarian-like stroma supports the epithelium, which may express estrogen and progesterone receptors. The mechanism and pathophysiology of this unusual phenomenon remain uncertain. The epithelium may form pseudopapillae; however, further cytologic or architectural atypia is not common in the adenoma type.<sup>8</sup>

Distinction of the adenoma from higher-grade mucinous cystic neoplasms requires the presence of true papillae with pseudostratification and true stratification, mild-to-moderate cytologic atypia, and mitoses. If these features are present, they are best termed mucinous cystic neo-

plasms with low malignant potential or mucinous cystic neoplasms, borderline type. Those exhibiting severe cytologic atypia/carcinoma in situ, loss of mucin-secreting features, more abundant mitoses, tufting, and marked stratification with no evidence of stromal invasion are described as noninvasive mucinous cystic carcinomas. Finally, the presence of true stromal invasion further distinguishes the invasive variant.<sup>9</sup> Mucinous cystic neoplasms are usually treated by excision, and the prognosis depends on the completeness of excision as well as the presence or absence of carcinoma.<sup>6</sup> Mucinous cystic neoplasms with invasive carcinoma harbor a significantly better prognosis than pancreatic ductal adenocarcinomas.<sup>10</sup> The differential diagnosis of mucinous cystic neoplasms includes a pancreatic pseudocyst and all other cystic tumors; however, a thorough gross examination and an extensive sampling with radiologic and clinical correlation in conjunction with the aforementioned microscopic features allow the distinction. A recent review of pancreatic cystic neoplasms by Goldsmith<sup>8</sup> is very helpful and is highly recommended.

### References

1. Compagno J, Oertel JE. Mucinous cystic neoplasms of the pancreas with overt and latent malignancy (cystadenocarcinoma and cystadenoma): a clinicopathologic study of 41 cases. *Am J Clin Pathol.* 1978;69:573-580.
2. Compagno J, Oertel JE. Microcystic adenomas of the pancreas (glycogen-rich cystadenomas): a clinicopathologic study of 34 cases. *Am J Clin Pathol.* 1978;69:289-298.
3. Adsay NV, Klimstra DS, Compton CC. Cystic lesions of the pancreas: introduction. *Semin Diagn Pathol.* 2000;17:1-6.
4. Solcia E, Capella C, Kloppel G. *Tumors of the Pancreas.* Washington, DC: Armed Forces Institute of Pathology; 1997. *Atlas of Tumor Pathology*; 3rd series, fascicle 20.
5. Wilentz RE, Albores-Saavedra J, Hruban RH. Mucinous cystic neoplasms of the pancreas. *Semin Diagn Pathol.* 2000;17:31-42.
6. Zamboni G, Scarpa A, Bogina G, et al. Mucinous cystic tumors of the pancreas: clinicopathologic features, prognosis, and relationship to other mucinous cystic tumors. *Am J Surg Pathol.* 1999;23:410-422.
7. Thompson LD, Becker RC, Przygodzki RM, et al. Mucinous cystic neoplasm (mucinous cystadenoma of low-grade malignant potential) of the pancreas: a clinicopathologic study of 130 cases. *Am J Surg Pathol.* 1999;23:1-16.
8. Goldsmith JD. Cystic neoplasms of the pancreas. *Am J Clin Pathol.* 2003;119(suppl 1):S3-S16.
9. Zamboni G, Hruban RH, Longnecker DS, et al. Mucinous cystic neoplasms of the pancreas. In: Hamilton SR, Aaltonen LA, eds. *Pathology and Genetics of Tumors of the Digestive System.* Lyon, France: IARC Press; 2000:234-236.
10. Wilentz RE, Albores-Saavedra J, Zahurak M, et al. Pathologic examination accurately predicts prognosis in mucinous cystic neoplasms of the pancreas. *Am J Surg Pathol.* 1999;23:1320-1327.