

Prostate Gland–like Epithelium in the Epididymis

A Case Report and Review of the Literature

Lisa Yan-Jie Lee, MD; James Tzeng, MD; Marina Grosman, BS; Pamela D. Unger, MD

● **Aberrant prostatic tissue occurs commonly in the adult male urethra and bladder. Ectopic prostatic tissue occurring outside the urinary system is rare. One case with scattered prostate-type glands in epididymis has been reported in the literature. We report a related case, in which the presence of prostate gland–like epithelium was recognized in epididymal glands in routine histology and was confirmed by subsequent immunohistochemical analysis using prostate-specific antigen. We then examined 23 additional orchiectomy specimens for the presence of prostate-like epithelium. The possibility of this being true ectopia versus an unusual metaplastic change is discussed.**

(*Arch Pathol Lab Med.* 2004;128:e60–e62)

REPORT OF A CASE

The patient was a 64-year-old man who presented with bilateral inguinal hernia and left undescended testicle. His serum prostate-specific antigen (PSA) level was unknown. The patient underwent bilateral inguinal hernia repair and left total orchiectomy. The grossly atrophic testicle and epididymis were processed for routine histology. Light microscopy revealed atrophic testicular parenchyma. The epididymis showed scattered, pale cribriform glandular epithelium admixed with conventional epididymal epithelium. Initial immunohistochemical analysis demonstrated that the cribriform epithelial tissue was positive for PSA with a dilution of 1:50, but negative for prostatic acid phosphatase (PAP). Subsequent evaluations for PSA at different dilutions were then performed, and the cribriform epithelia still demonstrated strong reactivity to the PSA antibody.

MATERIALS AND METHODS

We selected 23 additional cases with epididymal tissue from the surgical pathology files of Mount Sinai Medical Center (New York, NY) for evaluation. Patients ranged in age from 4 to 87 years. These tissues came from orchiectomy specimens for primary testicular malignancy (10 cases) and nonneoplastic tissue (14 cases). The primary malignancy cases included seminoma (n

= 3), diffuse large B-cell lymphoma (n = 2), Leydig cell tumor (n = 2), embryonal carcinoma (n = 1), yolk sac tumor (n = 1), and mixed germ cell tumor (n = 1). Nonneoplastic cases included undescended testis (n = 7), testicular torsion (n = 2), spermatocele (n = 2), orchitis (n = 1), and treatment of prostatic carcinoma (n = 2). Histologic specimens were fixed in 10% neutral buffered formaldehyde solution. Tissue blocks were processed in paraffin, and sections were stained with hematoxylin-eosin. Expression of PSA and PAP in the epididymis was examined by immunohistochemical staining. Immunohistochemical studies were performed with the avidin-biotin peroxidase complex method with appropriately diluted monoclonal antibodies to PSA (Novocastra, Newcastle upon Tyne, United Kingdom; 1:100), PAP (Dako Corporation, Carpinteria, Calif; 1:10000), and high-molecular-weight keratin (K903; Dako; 1:6). Positive and negative controls were also run.

RESULTS

Of the 24 cases, only the index case showed scattered foci of cribriform, pale, glandular epithelium admixed with conventional epididymal epithelium. These cribriform foci represented a minority of the epididymal ductal lining (Figure, A and B). The remaining 23 cases revealed conventional epididymal glands. The cribriform epithelium of the index case was strongly positive for PSA at all 3 different dilutions (1:50 [Figure, C], 1:200, and 1:400) and negative for PAP (Figure, D). The epididymal epithelia of the remaining 23 cases were negative for PSA and PAP. The basal cells of the epididymal duct in all cases were positive for high-molecular-weight keratin (K903).

COMMENT

Ectopic prostatic tissue occurs most commonly in adult male urethra, bladder trigone, and the root of the penis.^{1–3} Its presence in these locations probably represents one of the following: (a) normal embryonic structures that usually regress, rather than truly ectopic prostatic tissue; (b) misplaced tissue representing stranded nests of prostatic mesodermal cells; or (c) metaplasia of the transitional epithelium.⁴

Prostate-type tissue at sites other than the urinary tract, such as the retrovesical space,⁵ submucosa of anus,⁶ pericolic fat,⁷ or retroperitoneum,⁵ also have been reported. The possibility of ectopic prostatic tissue was suggested in these cases. There was only 1 previously reported case with prostate-like epithelium in the epididymis.⁸ A grossly normal epididymis from a 30-year-old man contained scattered prostate-like gland in addition to the normal epididymal ducts. The prostate-like glands were composed of 2 cell layers with intraluminal papillary projections that

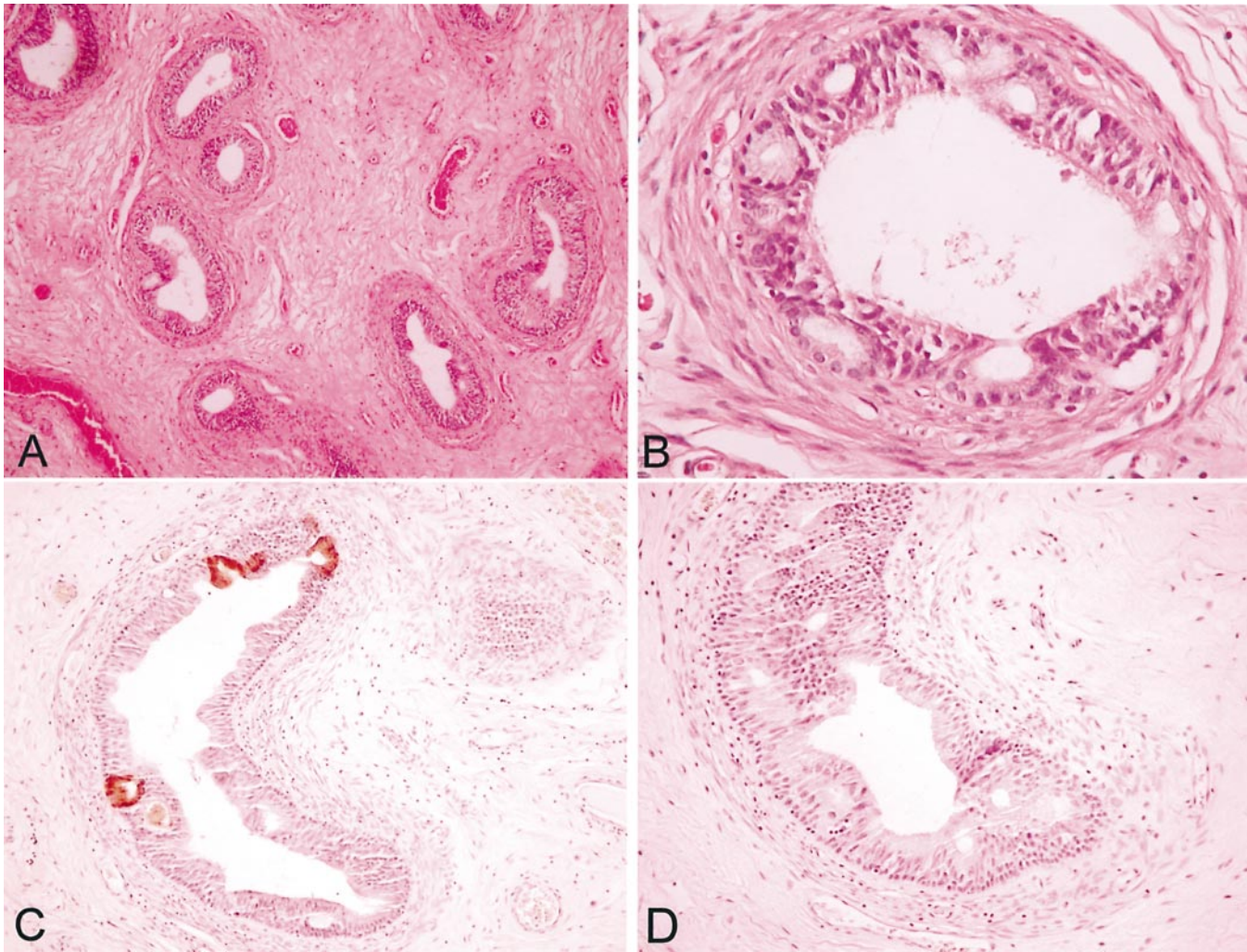
Accepted for publication December 11, 2003.

From the Department of Pathology, Mount Sinai Medical Center, New York, NY (Drs Lee, Tzeng, and Unger, and Ms Grosman); Department of Pathology, Elmhurst Hospital Center, Elmhurst, NY (Dr Lee); and Englewood Hospital, Englewood, NJ (Dr Tzeng).

Presented as an abstract at the International Association of Pathology, Amsterdam, Netherlands, October 2002.

The authors have no relevant financial interest in the products or companies described in this article.

Corresponding author: Lisa Yan-Jie Lee, MD, Department of Pathology, Elmhurst Hospital Center, 79-01 Broadway, Elmhurst, NY 11373 (e-mail: leeli@nychhc.org).



A and B, Low- and high-power views of epididymis with scattered, pale, cribriform glandular epithelia admixed with conventional epididymal epithelium (hematoxylin-eosin, original magnifications $\times 100$ [A] and $\times 200$ [B]). C, Cribriform glandular prostate-like epithelia are positive for prostate-specific antigen by immunohistochemical studies with dilution of 1:50 (original magnification $\times 200$). D, Cribriform glandular prostate-like epithelia are negative for prostatic acid phosphatase by immunohistochemistry (original magnification $\times 200$).

were positive for PSA and PAP by immunohistochemical staining. The investigators suggested segmental prostatic metaplasia rather than ectopic prostatic tissue, owing to the presence of normal periductal stromal elements, typical epididymal epithelium juxtaposed to prostate-like gland, and a transitional zone from one type to the other. It was also suggested that the presence of prostatic tissue in the epididymis might result from fusion of the developing mesonephric ducts with the anterior wall of the caudally migrating urorectal septum. Metaplasia is usually associated with chronic insults to the epithelium, such as chronic inflammation or reflux. This theory does not provide a good explanation for the presence of prostatic-type epithelia in our case. Therefore, the etiology of the prostatic-type gland in our case is difficult to establish with certainty.

The presence of prostatic heterotopia can raise clinically important issues, depending on the location. It is a cause of hematuria and rectal bleeding.^{6,9} In addition, it may be confused endoscopically with malignancy in the urinary tract, gastrointestinal system, retrovesical space, or pericolic fat.^{5,6} One case of malignancy developing within ec-

topic prostatic tissue has been reported.¹⁰ In that case, a 72-year-old man had prostatic adenocarcinoma (Gleason patterns 3+2) that was confined to, but extensively involved, the right side of the prostate gland, extending from the apex to the seminal vesicle. They described an extraprostatic nodule within the vascular pedicle, which was separated from the prostate gland and contained normal prostatic tissue and prostatic adenocarcinoma.

Prostate-specific antigen is positive by immunohistochemistry in the following extraprostatic tissues: periurethral glands (male and female), cystitis cystica and glandularis in the bladder, urachal remnants, neutrophils, and anal glands (male only). The extraprostatic tumors expressing PSA by immunohistochemistry include mature teratoma, periurethral gland adenocarcinoma (female), villous adenoma and adenocarcinoma in the bladder, extramammary Paget disease in the penis, pleomorphic adenoma, and carcinoma in the salivary gland (male only).¹¹

Whether ectopic prostate-type tissue gives rise to elevated PSA serum levels is another issue, which has yet to be investigated. However, to our knowledge nothing has

been reported in the literature regarding elevated PSA levels in ectopic prostate.

We acknowledge and thank Lorraine Miller, MD, for providing information on immunohistochemical studies and Joseph Samet for assistance with photography.

References

1. Dejer SW, Zuckerman ME, Lynch JH. Benign villous polyps with prostatic type epithelium of the penile urethra. *J Urol*. 1988;139:590–591.
2. Ewing R, Harnden-Mayor P, Mason MK, Anderson CK. Extra-urethral ectopic prostate. *Br J Urol*. 1987;60:433–435.
3. Chan JK, Chow TC, Tsui MS. Prostatic-type polyps of the lower urinary tract: three-histogenetic types? *Histopathology*. 1987;11:789–807.
4. Gutierrez J, Nesbit RM. Ectopic prostatic tissue in bladder. *J Urol*. 1967;98:474–478.
5. Yasukawa S, Aoshi H, Takamatsu M. Ectopic prostatic adenoma in retrovesical space. *J Urol*. 1987;137:998–999.
6. Tekin K, Sungurtekin U, Aytekin FO. Ectopic prostatic tissue of the anal canal presenting with rectal bleeding: report of a case. *Dis Colon Rectum*. 2002;45:979–980.
7. Gledhill A. Ectopic prostatic tissue. *J Urol*. 1985;133:110–111.
8. Bromberg WD, Kozłowski JM, Oyasu R. Prostate-type gland in the epididymis. *J Urol*. 1991;145:1273–1274.
9. Butterick JD, Schnitzer B, Abell MR. Ectopic prostatic tissue in urethra: a clinicopathological entity and a significant cause of hematuria. *J Urol*. 1971;105:97–104.
10. Adams JR Jr. Adenocarcinoma in the ectopic prostatic tissue. *J Urol*. 1993;150:1253–1254.
11. Bostwick DG, Eble JN. *Urologic Surgical Pathology*. New York, NY: Mosby; 1997:383.