

# Pathologic Quiz Case

## A 63-Year-Old Renal Transplant Recipient With a Sore Throat

Sajjad P. Syed, MD; Donald R. Chase, MD; Jun Wang, MD

**A** 63-year-old man underwent a kidney transplant in 1996. He had been doing well, with the usual immunosuppressant treatment, until 6 years later, when he developed a persistent sore throat and was noted to have an enlarged right tonsil. The tonsil was excised and submitted for pathologic analysis. Hematoxylin-eosin–stained sections at low magnification demonstrated extensive ef-

acement of the normal lymphoid architecture by sheets of plasmacytic cells containing large eosinophilic structures (Figure 1). At high magnification, the tonsillar tissue showed numerous variably sized eosinophilic structures, which were mostly intracytoplasmic (Russell bodies) and rare intranuclear (Dutcher bodies) inclusions (Figure 2). Histochemical and immunohistochemical studies showed that the inclusions were periodic acid–Schiff positive, and the cells were positive for CD79a (Figure 3) and strongly positive for CD138. Monoclonality was demonstrated by strong  $\lambda$  light chain positivity (Figure 4). Neither the cells nor the inclusions demonstrated any staining with CD20/CD3, Congo red, crystal violet stain, or  $\kappa$  light chain (Figure 4). Studies for the Epstein-Barr virus (EBV) genome (EBER in situ hybridization) were negative.

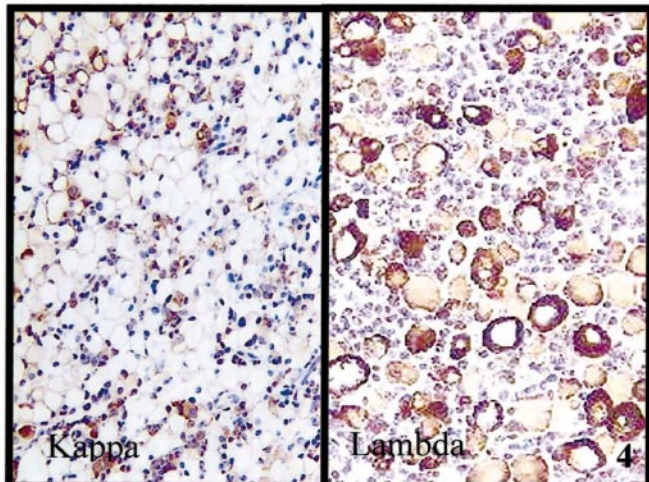
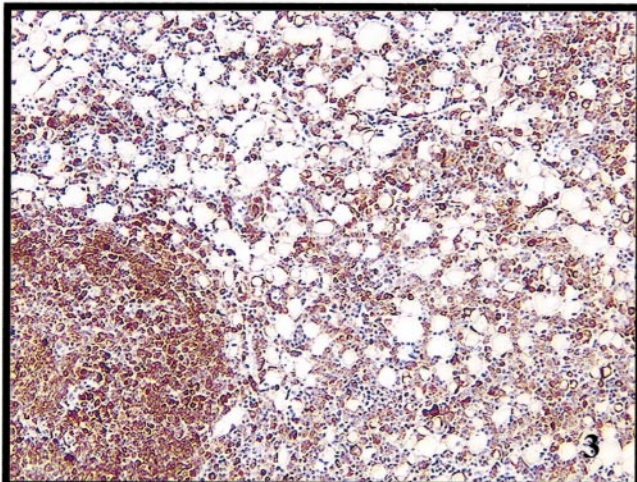
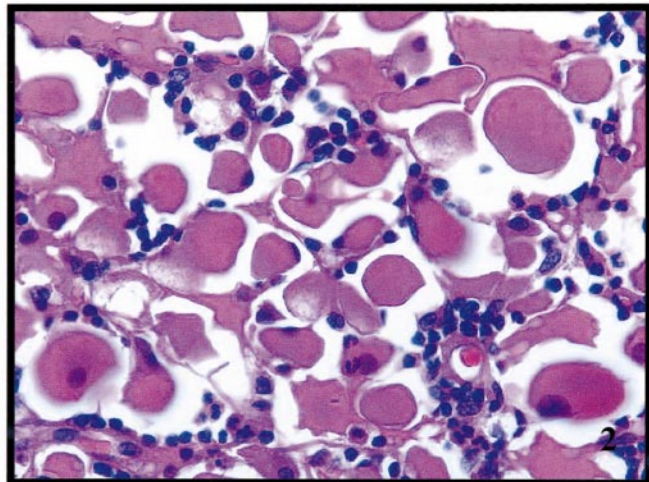
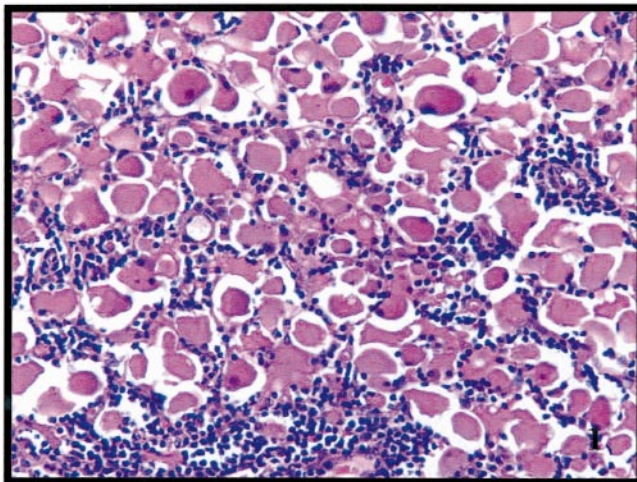
**What is your diagnosis?**

Accepted for publication February 3, 2004.

From the Department of Pathology and Laboratory Medicine, Loma Linda University Medical Center, Loma Linda, Calif.

The authors have no relevant financial interest in the products or companies described in this article.

Corresponding author: Sajjad P. Syed, MD, Department of Pathology and Laboratory Medicine, Loma Linda University Medical Center, 11234 Anderson St, Suite 2151, Loma Linda, CA 92354 (e-mail: ssyed@ahs.llumc.edu).





## Pathologic Diagnosis: Posttransplantation Lymphoproliferative Disorder, Plasmacytoma Type, With Prominent Russell Body Formation

The clinically and histologically heterogeneous group of complex, EBV-driven, B-cell proliferations (majority of cases), which cover a spectrum from reactive lymphoid hyperplasia to lymphoma and arise following solid-organ and bone marrow transplantation, is collectively referred to as posttransplantation lymphoproliferative disorder. However, 20% of posttransplantation lymphoproliferative disorders are EBV negative, and among renal allograft recipients, up to 50% may be EBV negative.<sup>1</sup> EBV-negative cases tend to occur later than EBV-positive cases (usually >5 years after transplant). Posttransplantation lymphoproliferative disorders occur more frequently in children than in adults. Patients who have undergone heart-lung transplantation are described as having the highest incidence and shortest interval of development of posttransplantation lymphoproliferative disorder (9.4%),<sup>2</sup> whereas patients receiving kidney transplants have the lowest incidence and longest interval of development (approximately 1%).<sup>1,3</sup> The interval between transplant and development of posttransplantation lymphoproliferative disorder is relatively short; a mean interval of 48 months has been described in the literature, with some cases reported as early as 0.7 month.<sup>3</sup> Donor-origin posttransplantation lymphoproliferative disorders appear to be most common in liver and lung allografts and frequently involve the allograft.<sup>4</sup> The different incidence of posttransplantation lymphoproliferative disorder has been attributed to the different intensities of immunosuppression needed for the different types of allografts. Patients who have undergone more than one transplant have a higher likelihood of developing posttransplantation lymphoproliferative disorder.<sup>3</sup>

Some of the drugs associated with the development of posttransplantation lymphoproliferative disorder include cyclosporine A, Tacrolimus (these tend to be related to posttransplantation lymphoproliferative disorders in the lymph nodes), OKT3 antibody, azathioprine, and antilymphocyte globulin.<sup>3</sup>

Most posttransplantation lymphoproliferative disorders occur in extranodal locations. One group of patients may present with head and neck disease, either as an infectious mononucleosis-like illness, with fever, sore throat with tonsillar enlargement, and lymphadenopathy, or as a localized mass lesion. In a second group, patients may present with abdominal disease, usually secondary to involvement of the gastrointestinal tract with ulceration or perforation. As a third group, patients may also present with single-organ involvement, with the central nervous system being the most common site.<sup>5</sup>

The plasmacytoma-like lesion is a rare type of monomorphic B-cell posttransplantation lymphoproliferative disorder. The presence of plasmacytic elements is actually considered a hallmark of posttransplantation lymphoproliferative disorder.<sup>6</sup> In fact, in a transplant recipient, the predominance of these cells within an infiltrate should suggest a posttransplantation lymphoproliferative disorder rather than a nonspecific inflammation of another cause.<sup>6</sup> Plasmacytoma is a localized mass lesion composed of plasma cells, which may be divided into 2 groups on the basis of location: extramedullary (extraskelatal site) and solitary plasmacytoma of the bone. Posttransplant

plasmacytoma-like lesions are almost always extramedullary, usually occurring in the gastrointestinal tract, lymph nodes, or other extranodal sites.<sup>1,3</sup> In the setting of an organ transplant, findings of masses in the Waldeyer ring or an excessive number of cervical nodes should increase the index of suspicion of posttransplantation lymphoproliferative disorder.<sup>7</sup> Histologically, there is a dense, homogeneous infiltrate of plasma cells, regardless of the site. The plasma cells are clonal and may demonstrate varying degrees of atypia, including prominent nucleoli, dispersed chromatin, irregular nuclei, and multinucleation. Immunoglobulin inclusions in the cytoplasm (Russell bodies) or nuclear pseudoinclusions (Dutcher bodies) can be present in all of the more differentiated types of plasmacytomas. In this study, the most striking feature of this particular plasmacytoma is the remarkably overwhelming number of immunoglobulin inclusions (Russell bodies), which have nearly completely replaced the tonsillar parenchyma (Figures 1 and 2). Rarely, amyloid or amorphous deposits of immunoglobulin, sometimes accompanied by a foreign body reaction, can occur.

The plasma cells are usually surface immunoglobulin negative and contain monoclonal cytoplasmic immunoglobulin. Most B-cell antigens (CD19, CD20, and CD22) are negative, but CD79a may be positive (Figure 3), and CD138 is frequently positive. Other markers, including CD45, HLA-DR, CD38, epithelial membrane antigen, CD43, and CD56, can be variably expressed.<sup>1</sup> The differential diagnosis includes benign processes, such as plasma cell granuloma of the upper aerodigestive tract, and lymphomas with plasmacytic differentiation (follicular center cell, monocytoid B cell, mucosa-associated B cell, immunoblastic lymphoma of B cell, and lymphoplasmacytic lymphoma), granulocytic sarcoma, melanoma, poorly differentiated carcinoma, and olfactory neuroblastoma.<sup>8</sup>

If untreated, posttransplantation lymphoproliferative disorders of both the polyclonal and monoclonal type often have a rapidly progressive, fatal clinical course.<sup>9</sup> However, upon the withdrawal or substantial reduction of immunosuppressive therapy, posttransplantation lymphoproliferative disorders may completely regress. Acyclovir may also be given to inhibit EBV replication, but the utility of acyclovir in this extramedullary plasmacytoma is unclear. If the lesions continue to progress, then the more standard lymphoma treatments, such as irradiation and chemotherapy, may be used.

Although the overall mortality of posttransplantation lymphoproliferative disorder in solid-organ allograft recipients is approximately 60% while that of marrow allograft recipients with posttransplantation lymphoproliferative disorder is 80%,<sup>10</sup> the actual mortality, in our institutional experience, appears to be lower than that reported. The administration of antibodies to CD20 antigen has been useful in abrogating posttransplantation lymphoproliferative disorder development in some cases, particularly in the marrow allograft setting.<sup>10</sup>

We thank William P. Illig, MD, Staff Pathologist, Saint Francis Hospital, Tulsa, Okla, for contributing this case to the California Tumor Tissue Registry (CTTR), Loma Linda University Medical Center.

### References

1. Ferry JA, Jacobson JO, Conti D, et al. Lymphoproliferative disorders and hematologic malignancies following organ transplantation. *Mod Pathol*. 1989;2: 583-592.

2. Randhawa PS, Yousem SA, Paradis IL, Dauber JA, Griffith BP, Locker J. The clinical spectrum, pathology, and clonal analysis of Epstein-Barr virus-associated lymphoproliferative disorders in heart-lung transplant recipients. *Am J Clin Pathol.* 1989;92:177–185.
3. Nalesnik MA, Jaffe R, Starzl TE, et al. The pathology of posttransplant lymphoproliferative disorders occurring in the setting of cyclosporine A–prednisone immunosuppression. *Am J Pathol.* 1988;133:173–192.
4. Spiro IJ, Yandell DW, Li C, et al. Brief report: lymphoma of donor origin occurring in the porta hepatis of a transplanted liver. *N Engl J Med.* 1993;329:27–29.
5. Penn I. Cancers complicating organ transplantation. *N Engl J Med.* 1990;323:1767–1769.
6. Hanto DW, Frizzera G, Purtilo DT, et al. Clinical spectrum of lymphoproliferative disorders in renal transplant recipients and evidence for the role of Epstein-Barr virus. *Cancer Res.* 1981;41:4253–4261.
7. Loevner LA, Karpati RL, Kumar P, Yousem DM, Hsu W, Montone KT. Post-transplantation lymphoproliferative disorder of the head and neck: imaging features in seven adults. *Radiology.* 2000;216:363–369.
8. Frizzera G, Hanto DW, Gajl-Peczalska KJ, et al. Polymorphic diffuse B-cell hyperplasia and lymphomas in renal transplant recipients. *Cancer Res.* 1981;41:4262–4279.
9. Mihalov ML, Gattuso P, Abraham K, et al. Incidence of post-transplant malignancy among 674 solid-organ transplant recipients at a single center. *Clin Transplant.* 1996;10:248–255.
10. Curtis RE, Travis LB, Rowlings PA, et al. Risk of lymphoproliferative disorders after bone marrow transplantation: a multi-institutional study. *Blood.* 1999;94:2208–2216.