

# Pathologic Quiz Case

## A 70-Year-Old Man With Bladder Outflow Obstruction

Purnima Malhotra, MD; Arati Bhatia, MD; Vinod K. Arora, MD; Navjeevan Singh, MD

In March 2001, a 70-year-old man underwent an evaluation when he presented with a complete bladder outflow obstruction. He had experienced 2 similar episodes of urinary retention and hematuria in the past 4 years.

During the first episode in 1998, he underwent a suprapubic prostatectomy, after which his symptoms subsided. No histopathology report was available.

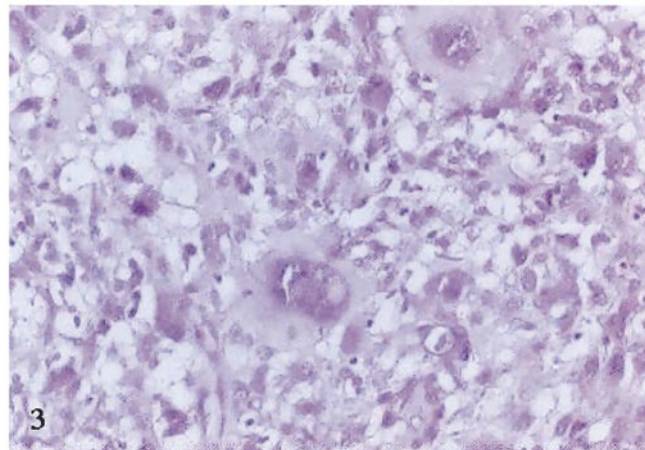
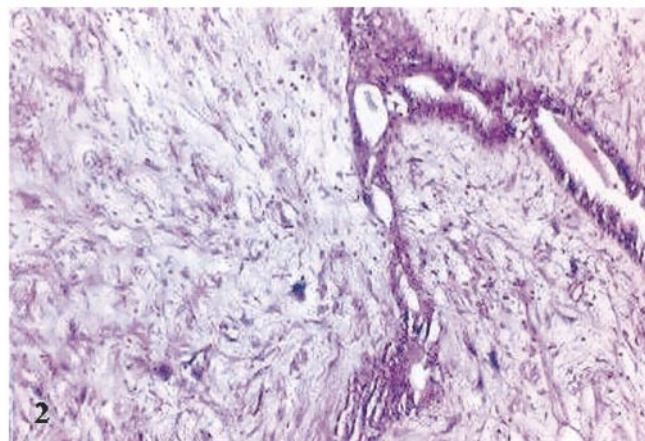
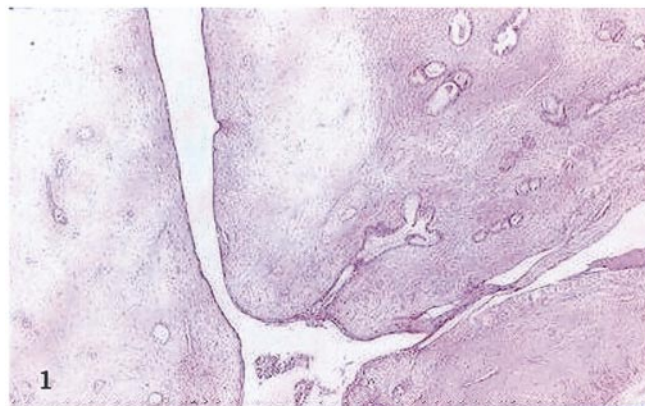
He had been well for 2 years when his symptoms recurred. At this time, his prostate-specific antigen level was 28.6 ng/mL. A transurethral resection of the prostate was performed. A histopathologic examination showed rare, single atypical cells in the stroma. A malignancy was suspected; however, a definitive diagnosis could not be made. Subsequently, a bilateral orchiectomy was performed. The patient was discharged on a regimen of flutamide.

The prostate-specific antigen level during the present episode was 0.59 ng/mL. A cystoscopy could not be performed. A suprapubic cystostomy and a radical prostatectomy were performed. A nodule on the anterior abdominal wall was also excised.

The resected prostate was lobulated; it weighed approximately 250 g and measured 21 × 15 × 9 cm. The cut surface was gray-white, with occasional foci of hemorrhage and necrosis. A microscopic examination showed a cellular stromal proliferation with cleftlike spaces lined by epithelial cells that produced a leaflike pattern (Figure 1). The stroma showed foci of hypercellularity, periglandular condensation, and bizarre cells (Figure 2). The glandular epithelium throughout was nonneoplastic and was composed of 2 layers: myoepithelial and secretory epithelial cells. Some glands showed squamous metaplasia. No mitoses were seen in the stromal or epithelial elements.

The metastatic nodule showed greater cellularity than the prostatic nodule and was composed exclusively of bizarre cells (Figure 3). No atypical mitoses or necrosis was identified in the primary or metastatic lesions.

**What is your diagnosis?**



Accepted for publication February 9, 2004.

From the Department of Pathology, University College of Medical Sciences and GTB Hospital, Delhi-95, India.

The authors have no relevant financial interest in the products or companies described in this article.

Corresponding author: Arati Bhatia, MD, Department of Pathology, University College of Medical Sciences, Delhi-95, India (e-mail: aratibhatia@hotmail.com).

## Pathologic Diagnosis: Prostatic Stromal Sarcoma

Sarcomas and related proliferative lesions of prostatic stroma are rare, distinctive lesions characterized by an expansion of specialized prostatic stroma and are associated with a nonneoplastic glandular component. Various terminology, including cystadenoma-leiomyofibroma,<sup>1</sup> phyllodes tumor, and cystic-epithelial stromal tumor,<sup>2</sup> has been used to describe these lesions. To better define the histologic spectrum, Gaudin et al<sup>3</sup> classified them into 2 main categories: prostatic stromal proliferations of uncertain malignant potential and prostatic stromal sarcomas. To our knowledge, only 5 well-documented cases of prostatic stromal sarcomas have been described in the literature.

The reported ages of affected individuals range from 25 to 86 years, with a peak incidence in the sixth and seventh decades of life. The most common clinical presentation is urinary retention; next most common are an abnormal digital rectal examination, hematuria, and hematospermia or a palpable rectal mass. Most lesions arise from the posterior prostate, protrude basally toward the vasa deferentia and seminal vesicle, and compress the adjacent bladder and rectum.

Based on the degree of stromal cytologic atypia and the presence or appearance of a nonneoplastic glandular component, 4 histologic patterns of prostatic stromal proliferations of uncertain malignant potential are recognized. The first and most common pattern shows proliferating stromal cells with focal cytologic atypia associated with benign glands. The second pattern differs in that cytologically atypical cells are not present. The third pattern is reminiscent of phyllodes tumor of the mammary gland. The fourth pattern consists exclusively of stroma. Prostatic stromal sarcoma differs in showing greater cellularity, atypical mitotic figures, necrosis, and stromal overgrowth. The present case morphologically resembled pattern 3 prostatic stromal proliferations of uncertain malignant potential; however, because of the unequivocal presence of

metastasis, a diagnosis of prostatic stromal sarcoma is necessary. Squamous metaplasia seen in the present case can be attributed to hormonal therapy. Because a progression of prostatic stromal proliferations of uncertain malignant potential to prostatic stromal sarcoma has been reported,<sup>4</sup> a thorough sampling was performed to look for a focus with histologic features of prostatic stromal sarcoma.

Both prostatic stromal sarcomas and prostatic stromal proliferations of uncertain malignant potential are invariably reported to be positive for CD34 and progesterone receptors.<sup>3</sup> CD34 may help distinguish these tumors from other prostatic mesenchymal neoplasms, such as rhabdomyosarcoma and leiomyosarcoma.<sup>5</sup> In contrast to prostatic stromal proliferations of uncertain malignant potential, immunoreactivity in prostatic stromal sarcomas is usually absent for desmin, HHF-35, and smooth muscle actin, which suggests that the expression of muscle markers is a function of differentiation. In the present case, immunoreactivity was also lacking for desmin and smooth muscle actin, the 2 markers studied.

Local recurrence is common, and distant metastases have been reported in the lungs and bones. Because of the limited number of reported cases, clear guidelines for treatment are not available. A prompt radical prostatectomy and a cystoprostatectomy should probably be performed. To our knowledge, the roles of chemotherapy and radiotherapy have not yet been evaluated.

### References

1. Cox R, Dawson IMP. A curious prostatic tumor: probably a true mixed tumor (cystadenoma-leiomyofibroma). *Br J Urol*. 1960;32:306-311.
2. Mazur MT, Myers JL, Maddox WA. Cystic epithelial-stromal tumor of the seminal vesicle. *Am J Surg Pathol*. 1987;11:210-217.
3. Gaudin PB, Rosai J, Epstein JI. Sarcomas and related proliferative lesions of specialized prostatic stroma: a clinicopathologic study of 22 cases. *Am J Surg Pathol*. 1998;22:148-162.
4. Young JF, Jensen PE, Wiley CA. Malignant phyllodes tumor of the prostate: a case report with immunohistochemical and ultrastructural studies. *Arch Pathol Lab Med*. 1992;116:296-299.
5. Westra WH, Gerald WL, Rosai J. Solitary fibrous tumor: consistent CD34 immuno-reactivity and occurrence in the orbit. *Am J Surg Pathol*. 1994;18:992-998.