

# Pathologic Quiz Case

## Bladder Tumor in a 41-Year-Old Man

Sanjay Mukhopadhyay, MD; William Taylor, MD

**A** 41-year-old man with a history of chronic prostatitis presented with difficulty voiding. He was found on cystoscopic examination to have a bladder tumor. A computed tomogram of the pelvis revealed an irregularly thickened and lobulated bladder wall. Transurethral resection of the bladder tumor was performed. At surgery, the bladder neck and prostatic urethra revealed marked edema of the mucosa (Figure 1), extending from the ver-

umontanum well into the bladder, including the trigone. It was difficult to determine whether this represented carcinoma or inflammation. On histologic examination, the lesions consisted of a proliferation of glands in the lamina propria (Figure 2; hematoxylin-eosin, original magnification  $\times 20$ ). The glands were lined by columnar epithelium, including goblet cells and Paneth cells (Figure 3; hematoxylin-eosin, original magnification  $\times 200$ ). Mucin production was prominent. Focal mucin extravasation into the stroma was identified (Figure 4; hematoxylin-eosin, original magnification  $\times 200$ ). There was no significant nuclear hyperchromasia, pleomorphism, or pseudostratification (Figure 3). Mitoses, necrosis, or signet ring cells were not seen. Moderate acute and chronic inflammation was present around the glands, but no significant inflammation was seen around the foci of extravasated mucin (Figure 4). Detrusor muscle was identified. No invasion of the detrusor was seen.

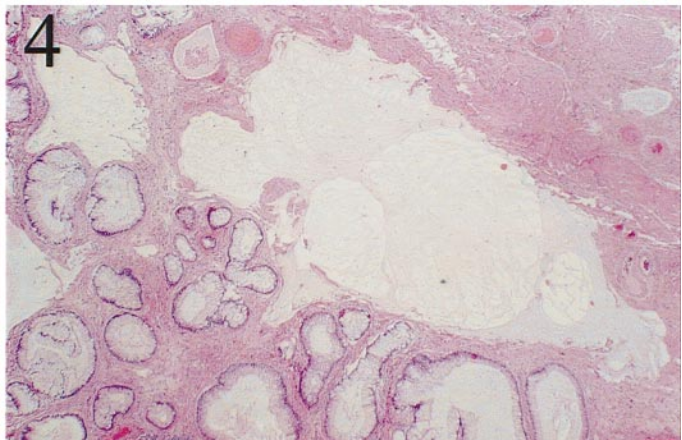
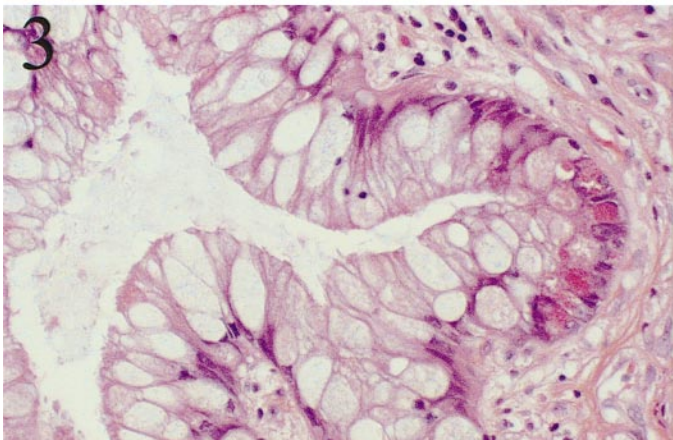
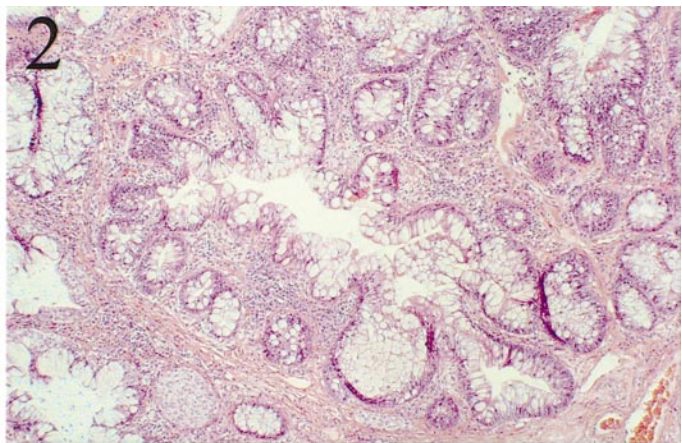
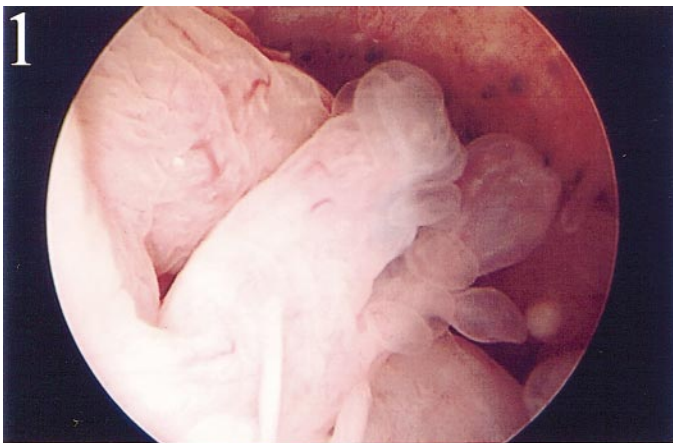
**What is your diagnosis?**

Accepted for publication February 26, 2004.

From the Department of Pathology, State University of New York Upstate Medical University, Syracuse (Dr Mukhopadhyay); and Department of Pathology, Wilson Memorial Regional Medical Center, Johnson City, NY (Dr Taylor).

The authors have no relevant financial interest in the products or companies described in this article.

Corresponding author: Sanjay Mukhopadhyay, MD, Department of Pathology, State University of New York Upstate Medical University, 750 E Adams St, Syracuse, NY 13210 (e-mail: mukhopas@upstate.edu).



## Pathologic Diagnosis: Cystitis Glandularis of Intestinal Type With Mucin Extravasation

Cystitis glandularis is a common benign epithelial abnormality of the urinary bladder. Two forms are recognized: typical and intestinal.<sup>1,2</sup> The 2 types differ in terms of histologic appearance, frequency of occurrence, degree of difficulty in diagnosis, and association with adenocarcinoma.<sup>1</sup>

Cystitis glandularis of intestinal type (CGIT), also referred to as colonic metaplasia,<sup>3</sup> is less common than the typical form of cystitis glandularis. Although typical cystitis glandularis rarely presents diagnostic problems, CGIT is frequently misdiagnosed as adenocarcinoma, and florid CGIT is well known as a pseudoneoplastic lesion of the urinary bladder.<sup>1</sup>

CGIT has a predilection for the bladder neck and trigone. It occurs in both sexes.<sup>3</sup> There appears to be a male preponderance.<sup>2,4</sup> The most common presenting complaints are irritative symptoms or hematuria.<sup>4</sup> Hydro-nephrosis is uncommon. Radiologic and cystoscopic appearances may suggest a malignant tumor. Although CGIT is usually a microscopic finding, it is occasionally visible grossly as a polypoid or papillary mass. Histologically, CGIT is variable in morphologic features, depending on the prominence of the process and the coexistence of areas with typical cystitis glandularis. The lesion is seen in the lamina propria beneath a flat overlying epithelium. It consists of glands lined by mucinous columnar epithelium (goblet cells) with basally situated nuclei. The "intestinal" appearance is usually striking. There may be extravasation of mucin into the stroma, with dissecting mucin pools, creating diagnostic difficulties.<sup>1-3,5</sup> Prominent edema and inflammation may be seen. Intestinal-type cells may also line the surface epithelium. Histochemically, the mucin seen in CGIT is similar to "colonic" mucin.<sup>6</sup>

The differential diagnoses of CGIT include adenocarcinoma<sup>1,3</sup> and endocervicosis.<sup>1</sup> Well-differentiated adenocarcinoma may be difficult to differentiate from extensive CGIT. Features that favor CGIT over adenocarcinoma include lack of atypical epithelial cells in or adjacent to the mucin and lack of more than mild atypia of the cells lining the glands. An orderly arrangement of the glands, lack of associated desmoplasia, and absence of invasion of the detrusor muscle<sup>1,3</sup> also favor a diagnosis of CGIT. Focal atypia may be present, and in these cases, a diagnosis of CGIT with atypia or CGIT with foci of adenocarcinoma in situ may be appropriate.<sup>1</sup> Mitoses, focal detrusor invasion, and dissecting mucin may rarely be seen in CGIT, but the degree and extent of these findings are less than those seen in adenocarcinoma.<sup>3,5</sup> Signet ring cells and necrosis are not

seen in CGIT.<sup>3</sup> Endocervicosis is a glandular lesion of the urinary bladder characterized by a prominent component of endocervical-type epithelium, which is seen in women of reproductive age. In contrast to endocervicosis, which typically involves the detrusor muscle, CGIT is almost always confined to the lamina propria. There is minimal stromal and inflammatory cell response to the extravasated mucin in CGIT, in contrast to what is often seen in endocervicosis.<sup>1</sup>

The relationship between CGIT and risk of subsequent carcinoma of the bladder is unresolved. The natural history has been difficult to evaluate because of insufficient follow-up or complete excision.<sup>3</sup> It appears that the presence of extensive CGIT is more ominous than focal colonic metaplasia. Progression from CGIT to adenocarcinoma has been well documented.<sup>2,7,8</sup> A few cases of CGIT coexisting with adenocarcinoma have also been described.<sup>9</sup> A recent study found nuclear localization of  $\beta$ -catenin in CGIT as opposed to membranous expression of  $\beta$ -catenin in typical cystitis glandularis. Nuclear localization of  $\beta$ -catenin is also seen in the Barrett esophagus, which is a preneoplastic condition, suggesting that CGIT may have the potential to progress to malignancy.<sup>10</sup>

In summary, CGIT is a distinct pseudoneoplastic entity of uncertain malignant potential that differs from typical cystitis glandularis at many levels. Correct identification of this lesion requires recognition of the histologic overlap with well-differentiated adenocarcinoma and correct identification of the differentiating morphologic features.

### References

1. Young RH. Pseudoneoplastic lesions of the urinary bladder and urethra: a selective review with emphasis on recent information. *Semin Diagn Pathol.* 1997; 14:133-146.
2. Young RH, Bostwick DG. Florid cystitis glandularis of intestinal type with mucin extravasation: a mimic of adenocarcinoma. *Am J Surg Pathol.* 1996;20: 1462-1468.
3. Jacobs LB, Brooks JD, Epstein JI. Differentiation of colonic metaplasia from adenocarcinoma of urinary bladder. *Hum Pathol.* 1997;28:1152-1157.
4. Davies G, Castro JE. Cystitis glandularis. *Urology.* 1977;10:128-129.
5. Guarch Troyas R, Jimenez Calvo J, Reparaz Romero B, Gomez Dorransoro ML. Florid glandular cystitis of the intestinal type with mucin extravasation: a lesion simulating a tumor. *Acta Urol Esp.* 2003;27:297-300.
6. Newbould M, McWilliam LJ. A study of vesical adenocarcinoma, intestinal metaplasia and related lesions using mucin histochemistry. *Histopathology.* 1990; 17:225-230.
7. Bullock PS, Thoni DE, Murphy WM. The significance of colonic mucosa (intestinal metaplasia) involving the urinary tract. *Cancer.* 1987;59:2086-2090.
8. Edwards PD, Hurm RA, Jaeschke WH. Conversion of cystitis glandularis to adenocarcinoma. *J Urol.* 1972;108:568-570.
9. Lin JI, Yong HS, Tseng CH, Marsidi PS, Choy C, Pilloff B. Diffuse cystitis glandularis associated with adenocarcinomatous change. *Urology.* 1980;15:411-415.
10. Bryan RT, Nicholls JH, Harrison RF, Jankowski JA, Wallace DM. The role of beta-catenin signaling in the malignant potential of cystitis glandularis. *J Urol.* 2003;170:1892-1896.