

RECYCLED DENTIN ROOT MATRIX FOR A CARRIER OF RECOMBINANT HUMAN BONE MORPHOGENETIC PROTEIN

Masao Ike, DDS
Marshall R. Urist, MD

KEY WORDS

Recycled root matrix
Bone morphogenetic protein (BMP)
Recombinant human bone
morphogenetic protein (rhBMP-2)

Masao Ike, DDS, is a UCLA postdoctoral research fellow. His present address is Aichi-Gakuin University School of Dentistry, Department of Second Oral and Maxillofacial Surgery, 1-100 Kusumoto-cho, Chikusa-ku, Nagoya, Aichi 464, Japan.

Marshall Urist, MD, is a Professor of Orthopaedic Surgery. His present address is University of California, Los Angeles, School of Medicine, Department of Orthopaedic Surgery, Bone Research Laboratory, 1000 Veteran Avenue, Room A3-34, Los Angeles, Calif 90024. Dr Urist is the author to whom correspondence should be addressed.

Dysfunctional teeth, donated by community dental clinics, were recycled for research on bone morphogenetic protein (BMP) in health and disease. The crown remnants were trimmed away, and the roots were washed in 70% alcohol, demineralized, lyophilized, and prepared in one of two forms: (1) human partially demineralized root dentin matrix (PDM) or (2) autolysed, antigen-extracted root matrix (AAAD), including attached cementum. Composites of either PDM or antigen-extracted, autolysed, delipidized allogenic dentin matrix (AAAM) and recombinant human bone morphogenetic protein (rhBMP-2) were implanted in either normal or athymic mice. The percentage of muscle replaced by heterotopic bone was estimated by computer-assisted random point analysis. Implants of PDM and AAAD made from dysfunctional teeth exhibited little or no endogenous BMP activity and failed to induce new bone formation. Composites of 1 μ g of rhBMP-2 per 70 mg of PDM carrier induced 61% replacement of muscle by bone formation; 1 μ g of rhBMP-2 in 70 mg of AAAM matrix induced 78% replacement of muscle mass by bone; 2 or 5 μ g of rhBMP-2 and 70 mg of AAAM carrier induced 100% replacement of thigh muscle mass by bone. In athymic mice, the areas of new bone were only slightly greater than those in normal mice. These observations suggest that root dentin prepared from extracted teeth may be recycled for use as a carrier of rhBMP-2 because it induces new bone formation in the periodontium.

INTRODUCTION

Dentin matrix is osteoinductive and rich in bone morphogenetic protein (BMP).¹⁻³ BMP is a low molecular weight hydrophobic glycoprotein found in the organic matrix of both bone and dentin. BMP has the same physicochem-

ical characteristics in dentin as in bone.⁴⁻⁷ Classified as a local hormone, or morphogen, BMP forms a concentration gradient pattern leading cell development along a pathway of bone in orthotopic and heterotopic sites.⁸⁻¹⁵

Bone BMP¹⁶ and dentin BMP⁷ are assayed by implantation in heterotopic

sites as partially purified, partially insoluble native (hBMP/NCP) and as highly purified soluble recombinant (recombinant human bone morphogenetic protein [rhBMP-2]) buffered to about pH 6. To retain the morphogen at the site of implantation long enough for the host-bed cells (of perivascular mesenchymal type) to gather, soluble rhBMP-2 is adsorbed to a carrier or to a delivery system.¹² The delivery system may also provide an adhesive substratum. In our experiments, the partially demineralized matrix (PDM) provided the mineral and matrix for adsorption of rhBMP-2. The antigen-extracted, autolysed, delipidized allogeneic dentin matrix (AAAM) provided a substratum with minimal antigenic substances. The host mice were either normal (Swiss Webster strain) or athymic mice that were deficient in the *da* antigens, T-cells, and immunogenic reactions to BMP.¹⁰ However, autogeneic fresh bone has the disadvantage of transplanting osteoclast progenitor cells, which, in some cases, causes resorption of the root structure of adjacent teeth.

Kawai and Urist⁷ separated the pulp and the periodontal soft tissue from the hard tissues (enamel, dentin, and cementum) of 1-year-old steers and found high levels of osteoinductive activity. Becker *et al*¹⁷ found very low or no endogenous osteoinductive activity in adult human DBM issued from clinical bone banks and pointed out the need for supplementary exogenous BMP for treatment of periodontal defects. Neiderwanger and Urist¹⁸ implanted composites of human DBM and rhBMP-2 and demonstrated higher yields of induced bone formation than previously noted. Here, we report on two experimental rhBMP-2 carrier systems prepared from human tooth remnants. One system is surface-demineralized PDM designed to determine the effects of slow mineral resorption and release of rhBMP-2. The other system, AAAM, is designed to emit a low level of soluble antigenic proteins. The matrix mineral interface is assumed to

Implants	1 μ g	<i>n</i>	2 μ g	<i>n</i>	5 μ g	<i>n</i>
rhBMP-2 solution in gelatin capsules	0.0%	5	42 \pm 6.4%	10	59 \pm 7.4%	25
PDM in gelatin capsules		3		3		3
PDM + rhBMP-2 in capsules	61 \pm 1.8%	15	83 \pm 11%	10	104 \pm 16%	5
AAAD in gelatin capsule		3		3	100 \pm 10%	3
AAAD + rhBMP-2 in capsules	78 \pm 6.9%	10	100 \pm 10%	10		10

*rhBMP-2, recombinant human bone morphogenic protein. PDM, partially demineralized root dentin matrix. AAAD, autolysed, antigen-extracted root matrix.

contain substances and/or receptors that promote the BMP-induced bone development.

MATERIALS AND METHODS

rhBMP-2 (batch 2D11J024) was provided by Dr Vicki Rosen, and Dr John Wozney (Genetics Institute, Boston, Mass). Biological activity was verified in adult rats using intramuscular implants composed of rhBMP-2 and 6 M guanidine hydrochloric acid (GuHCl)-deactivated rat bone matrix.

Implants of rhBMP-2 in a glycine buffer solution in gelatin capsules

Three sets of 4-week-old male Swiss Webster mice were recipients of 1, 2, and 5 μ g of rhBMP-2 in glycine-buffered solutions. The solutions were instilled in the open half of disassembled no. 5 gelatin capsules, were reassembled without any other carrier, and were then implanted in the hindquarter muscles of the mice. The same number of implants were placed in athymic mice. The number of animals in each treatment group and the quantity of induced bone development is shown in Table 1.

Carriers for rhBMP-2

Root dentin matrix was prepared from human teeth donated by outpatients at the University of California School of Dentistry. Immediately after extraction, the roots were trimmed and cleaned of all extraneous material and sterilized in 70% alcohol. The roots were partially demineralized with 0.6 N hydrochloric acid for 24 hours at 2°C

and were then cut into 0.5-g blocks. PDM, including cementum, was washed in cold water and lyophilized. PDM was also converted into antigen-extracted autolysed matrix (AAAD) by methods employed for human use in previous reports.¹⁹ The PDM and AAAD root matrices were cut into 1.0- to 2.0-mm³ blocks. Briefly stated, antigen was also extracted with chloroform methanol, the soluble noncollagenous proteins were autolysed and digested in 0.1 M phosphate-buffered saline, and bone collagen was converted to insoluble bone gelatin in 8 M lithium chloride.

Three sets of each composite dose of 70 mg of PDM or of AAAD plus 0, 1, 2, and 5 μ g of rhBMP-2, respectively, were implanted in normal and athymic mice (C Rivers Lab, North Wilmington, Mass).

Root AAAD powders

Two hundred milligrams of root AAAD were pulverized in a milling machine (Spex Ind, Metuchen, NJ) to a particle size of 100–200 μ m³. Samples weighing 70 mg, with and without 1, 2, or 5 μ g of rhBMP-2, were implanted in gelatin capsules in the 20 normal mice.

Histologic methods

The mice were sacrificed at 21 days. The hindquarters were x-rayed, and tissues were fixed in 10% neutral formalin, decalcified in ethylenediaminetetra-acetic acid (EDTA), sectioned in paraffin, and stained by hematoxylin,

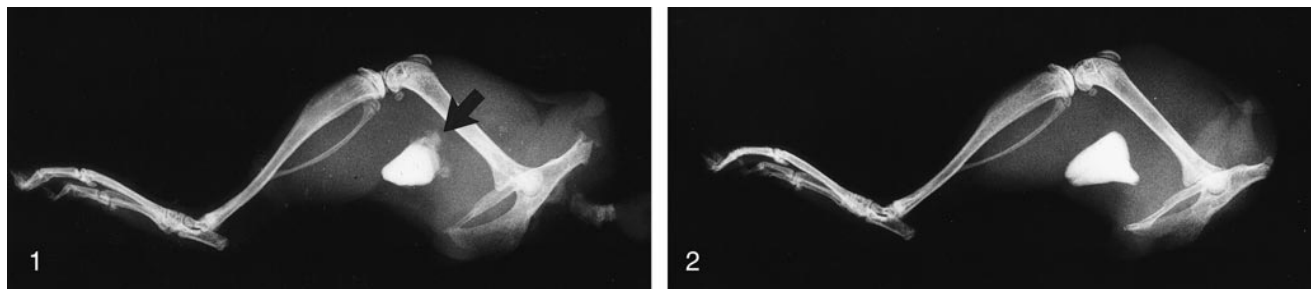


FIGURE 1. Radiograph of intramuscular implant of root PDM in athymic nude mouse, 3 weeks after the operation. Two small areas of new bone appear on the surface (arrow).

FIGURE 2. Radiograph of intramuscular implant of root AAAD in athymic nude mouse, 3 weeks after the operation. Note absence of new bone on surfaces of AAAM.

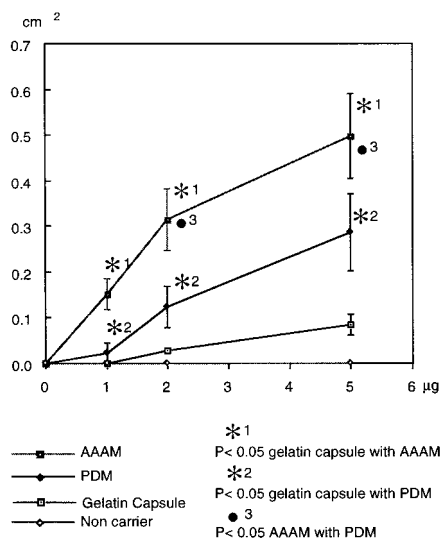


FIGURE 3. Graphic representation of implants of root-PDM and -AAAM. New bone deposits appeared on surfaces of AAAD, 0, 1, 2, 5 µg of rhBMP-2 per 30 g mouse weight. Note radiographic area of new bone in square centimeters is proportional to the dose.

eosin, and azure II for histologic evaluation.

The areas of new bone, which displaced muscle, and the old unabsorbed matrix particles (Tables 1, 2) were measured with a grid micrometer on radiographs and on histological sections. The data were obtained by random point analysis computed as described in detail by Kawai and Urist⁷ and calculated as follows:

$$\% \text{ new bone} = \frac{\text{area of new bone}}{\text{area of hindquarter muscle}} \times 100$$

The Student's *t*-test was applied to each carrier. The data were reported as the mean value and standard deviation. Sample sizes of groups 2, 3, and 4 were too small for statistical evaluation. The paired Student's *t*-test for unusual sample sizes was used to compare group 1 (rhBMP-2 solution in gelatin capsules) with group 2 (AAAD and rhBMP-2 in gelatin capsules).

RESULTS

The PDM and AAAM were implanted either *en bloc* or as powders in gelatin capsules in hindquarter muscles in both normal and athymic mice.

Normal mice

In the control group of normal mice, blocks of human PDM and AAAD dentin implanted in muscle caused no muscle to be replaced by new bone development. Implantation of 1 µg of rhBMP-2 alone was absorbed without inducing bone development, while the response to implantation of 2 µg of rhBMP-2 was bone replacement of muscle at a rate of 42%. The response to implantation of 5 µg of rhBMP-2 was 59.7% replacement by new bone.

rhBMP-2-PDM composites

As a result of implantation of 1 µg of rhBMP-2 plus PDM, the rate of muscle replacement by new bone was 61%. Bone replaced muscle at a rate of 83% with 2 µg of rhBMP-2 plus PDM, and 100% replacement occurred with 5 µg of rhBMP-2 plus PDM. Without rhBMP-

2, PDM induced no new bone development.

rhBMP-2-AAAD composite

Implantation of 1 µg of rhBMP-2 using AAAD as a carrier produced bone replacement of the mouse hindquarter muscles at rates of 78 to 100%. Implantation of 2 and 5 µg of rhBMP-2 with AAAD as a carrier both produced the same rates of replacement as the 1-µg trial (78–100%; Table 1). Without rhBMP-2, 70 mg of AAAD tooth matrix produced histologically detectable replacement at a rate of about 3%; that is, only slight endogenous native BMP activity that was hardly detectable in radiographs (Figs 1–4). Implants of root matrix dentin were rapidly resorbed and replaced by new bone at rates proportional to the quantity of exogenous rhBMP-2 in the implant. Bone development increased with increases of rhBMP from 1 to 2 to 5 µg and was associated with progressive replacement of old matrix. With implantation of fine powders, the rates of the hindquarter replacement of muscle by bone were 40% with 1 and 2 µg of rhBMP-2 and 63% with 5 µg of rhBMP-2 (Table 2). The percentage of unabsorbed matrix decreased in proportion to the area of new bone. Implantation of 2 µg of rhBMP-2 with both PDM and AAAM carriers showed statistically significant equivalent responses (Figs 3–5).

HISTOLOGICAL OBSERVATIONS

Implants of 2 µg of rhBMP-2 without a carrier other than the gelatin capsules

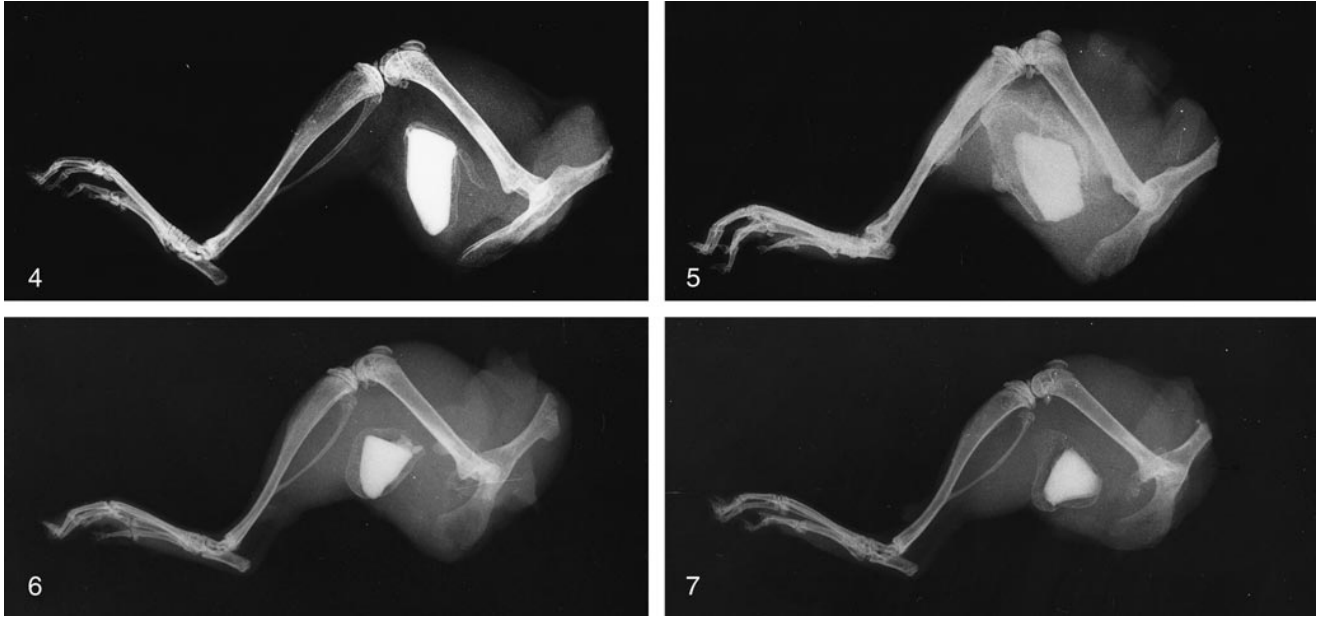


FIGURE 4. Radiograph of implant of a rhBMP-2-PDM composite (5 μg of rhBMP-2 per 30 g of body weight) in a normal mouse, 3 weeks after the implantation. Note new bone enveloping the implant.

FIGURE 5. Radiograph of implant of AAAD with 5 μg of rhBMP-2, showing massive deposit of new bone surrounding the implant on all sides, 3 weeks after the operation.

FIGURE 6. Radiograph of an implant of 2 μg of rhBMP-2 with PDM for a carrier showing a lower yield of new bone with 2 μg of rhBMP compared with the 5 μg dose noted in Fig 5.

FIGURE 7. Radiograph of an implant with a composite of 2 μg of rhBMP-2 and AAAM. Note the equivalence of the osteoinductive response to the dose of rhBMP-2 shown in Fig 6.

produced no bone, but implants of 2 to 5 μg of rhBMP-2 induced considerable bone development. The rhBMP-2-PDM and -AAAD composites induced similar quantities of bone in both athymic and normal mice (Figs 6–9). While there were significant differences in quantities of bone induced, normal mice showed slight macrophage, lymphocyte, plasma cell, and reticulocyte reactions suggestive of a cell-mediated immune response. Without exogenous BMP, AAAD and PDM root matrix alone implanted in normal mice produced little or no histological evidence of cartilage development or bone development. A thin membrane of fibrous tissue covered the AAA and PDM root surfaces (Figs 10–12).

rhBMP-2-PDM and rhBMP-2-AAAD composites implanted in normal mice

Within 3 weeks, new bone deposits were remodeled and filled with he-

matopoietic marrow. In some places, histological sections showed direct bone-to-carrier attachments with no intervening fibrous or inflammatory connective tissue. The volume of bone formation was directly proportional to the dose levels of rhBMP-2 in the ranges of 1, 2, and 5 μg per 0.07 g of (PDM or AAAD) carrier (Figs 13, 14).

AAAD and PDM alone implants in the athymic mice

Figures 15 and 16 show results of AAAD and PDM implantation (without rhBMP-2) in athymic mice after 3 weeks. Trace amounts of new bone attached to the exposed surfaces of the dentin were suggestive of sites of endogenous BMP activity (Fig 16). Comparable deposits were not found in mice that had been implanted with PDM; instead, the PDM implants were enveloped in dense fibrous connective tissue (Figs 15–17).

AAA tooth and PDM-rhBMP-2 composite implants in the athymic nude mice

Figures 18 and 19 show the histologic reactions to composites of 2 μg of rhBMP in athymic mice. Both implants caused large deposits of new bone, including active bone marrow, as well as direct appositional bone deposition on the tooth surfaces of the implants in both the AAAD and the PDM composite subjects.

Table 2 summarizes observations of the carrier function of AAAD pulverized to increase the surface area of absorption of rhBMP-2. Without rhBMP-2, AAAD powder was rapidly absorbed and was without any osteoinductive effects. With 1, 2, or 5 μg of rhBMP-2 per 50 mg of AAAD powders, however, 40, 44, and 63% of the muscle matrix particles were displaced by bone, respectively. The reduction of

TABLE 2
Percent of thigh occupied by heterotopic bone*

Implant	% New Bone	% Unabsorbed Matrix
AAAM powder alone	0.0	66.7 ± 14.2
AAAM (10 mg) with 1 µg of rhBMP-2	40.5 ± 6.4	32.7 ± 13.6
AAAM (10 mg) with 2 µg of rhBMP-2	43.9 ± 4.1	23.7 ± 2.8
AAAM (10 mg) with 5 µg of rhBMP-2	63.3 ± 4.2	13.3 ± 4.0

*AAAM, Antigen-extracted, autolysed, delipidized allogenic dentin matrix. rhBMP-2, recombinant human bone morphogenic protein.

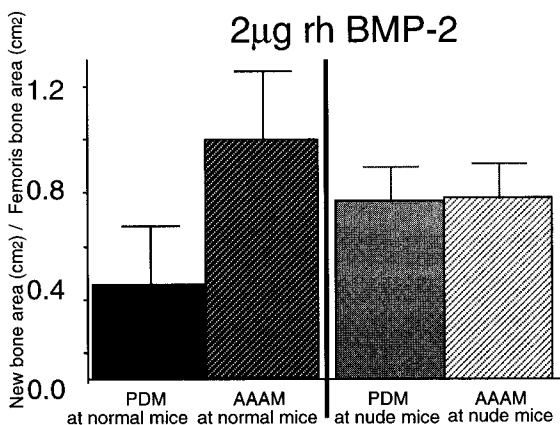


FIGURE 8. Bar graph representation of the volumes of new bone formed in response to PDM and AAAM in normal and athymic mice. The rate of new bone development from PDM is 20% higher in athymic mice with greater immunodeficiency.

the rate of replacement by bone associated with the implanted powder in the absence of rhBMP-2 was 66.7%. In the composite with 1 µg of rhBMP-2 plus AAAM, the reduction rate was 32%, but dropped to 23% with 2 µg of rhBMP-2 with AAAM, and to only 3% with 5 µg of rhBMP-2 with AAAM.

This striking reciprocal relationship of the volume of new bone to the absorption of the AAAD carrier is shown in Figs 20 and 21.

DISCUSSION

The experiments on human adult extracted teeth presented here were de-

signed to determine whether root matrix, including small patches of cementum may (1) induce heterotopic bone development and/or (2) serve as a carrier for rhBMP-2 induced bone development. A literature review showed that the following substances have also been investigated for carrier properties: human collagen, atelocollagen, albumin, osteonectin, osteocalcin, bone matrix, blood clot, polylactic polyglycolic acid polymers, calcium sulfate, hydroxyapatite, β-tricalcium phosphate, and titanium oxide.²⁰ Although endogenous BMP has been found in large quantities in dentin in normal young adult mammals, dentin matrix seems not to have been evaluated as a carrier of exogenous BMP. BMP activity declines in bone with aging, but whether or not BMP also declines in dentin with time and/or with periodontal disease requires investigation by quantitative methods. The surprising findings in our study were the large quantity of induced bone development and the complete resorption and replacement of root dentin matrix as compared with bone matrix development induced by the carriers, listed above.

The quantity of unresorbed matrix after 21 days was less than previously observed with implantation of either crown dentin or cortical bone matrix.^{1,2,18,21} Microscopic remnants of unresorbed root dentin matrix powders were osteointegrated, that is, embedded in bone trabecular like old bone in

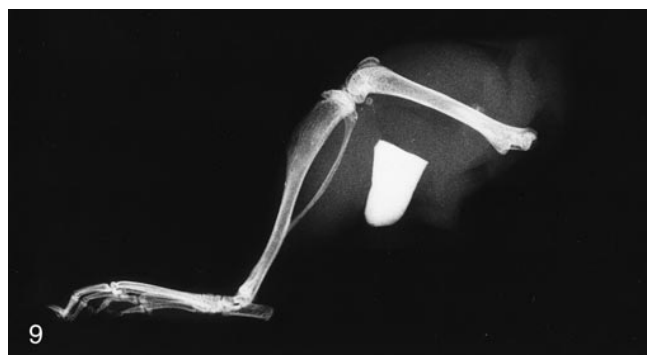

FIGURE 9. Radiograph of PDM implant 3 weeks after the operation, showing no osteoinductive response in a normal mouse.

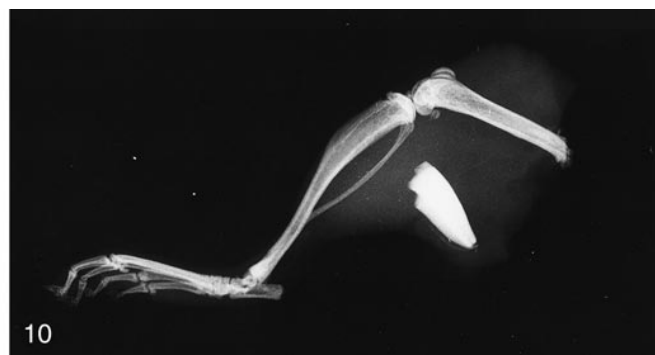

FIGURE 10. Radiograph of AAAM implant showing little or no osteoinductive response in a normal mouse.

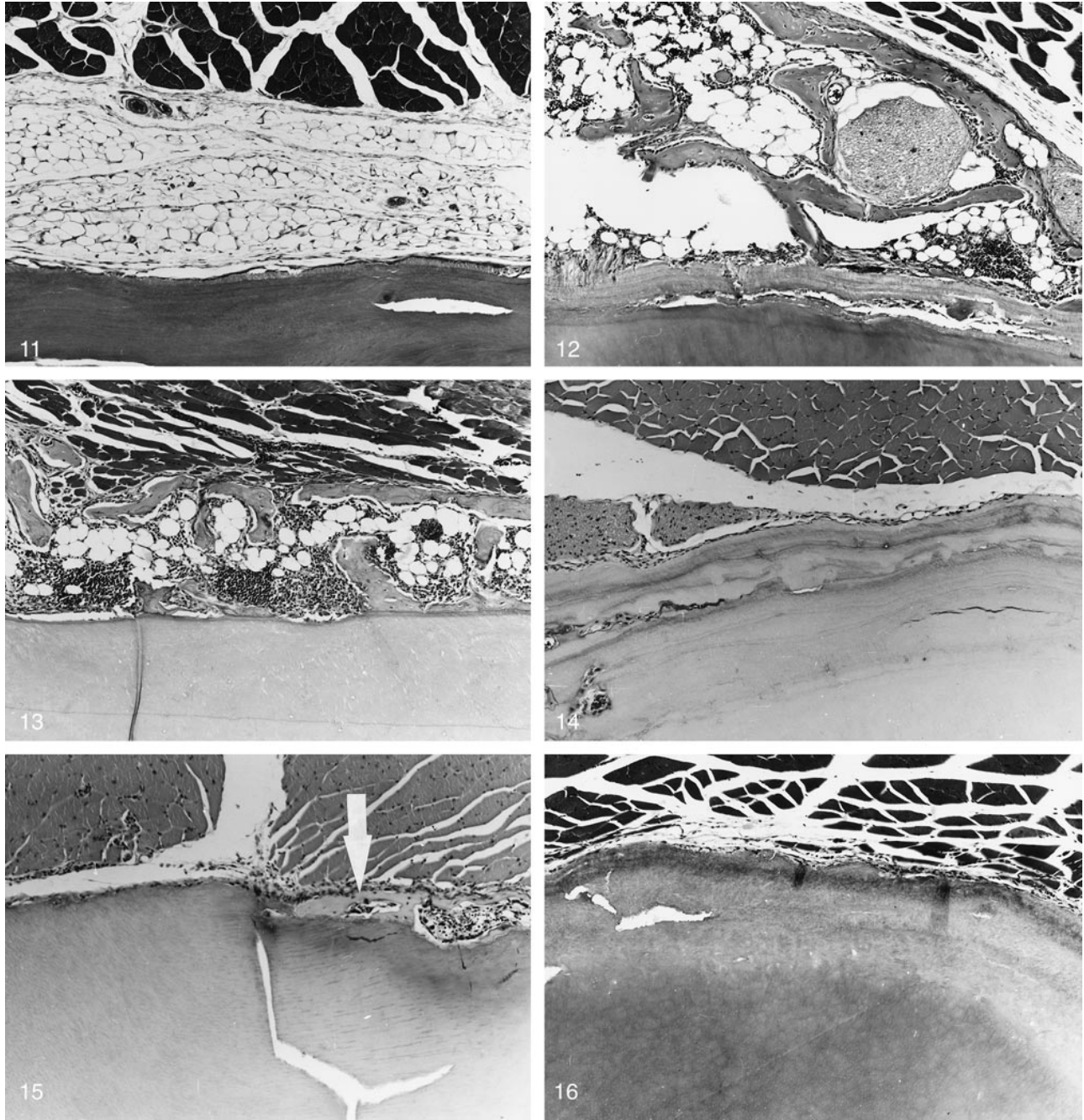


FIGURE 11. Photomicrograph of the implant shown in Fig 10. Note muscle (top), adipose tissue (middle), and root dentin (bottom), with surface coat of cementum. Hematoxylin, eosin, and azure II (magnification $\times 100$).

FIGURE 12. Photomicrograph of an implant of a composite of 5 μg of rhBMP-2 and PDM 3 weeks after the operation. Note muscle (top right), bone and bone marrow (middle), cementum, human dental root PDM (bottom) (magnification $\times 100$).

FIGURE 13. Photomicrograph of a composite of root dentin (AAAM and 5 μg of rhBMP-2 per 30 g body weight) 3 weeks after implantation in a normal mouse. Note muscle (top), new bone and bone marrow (middle), cementum and dentin (bottom) (magnification $\times 100$).

FIGURE 14. Photomicrograph of implant of the PDM control in athymic mouse. Note muscle (top), granulation tissue (middle), and root dentin (bottom) (magnification $\times 100$).

FIGURE 15. Photomicrograph of PDM coated with cementum implanted in an athymic mouse. Note muscle (top), root dentin (bottom) with deposit of new bone developed at the interface (arrow).

FIGURE 16. Photomicrograph of an AAAM control showing the fibrous tissue envelope between muscle and root dentin in an athymic mouse.

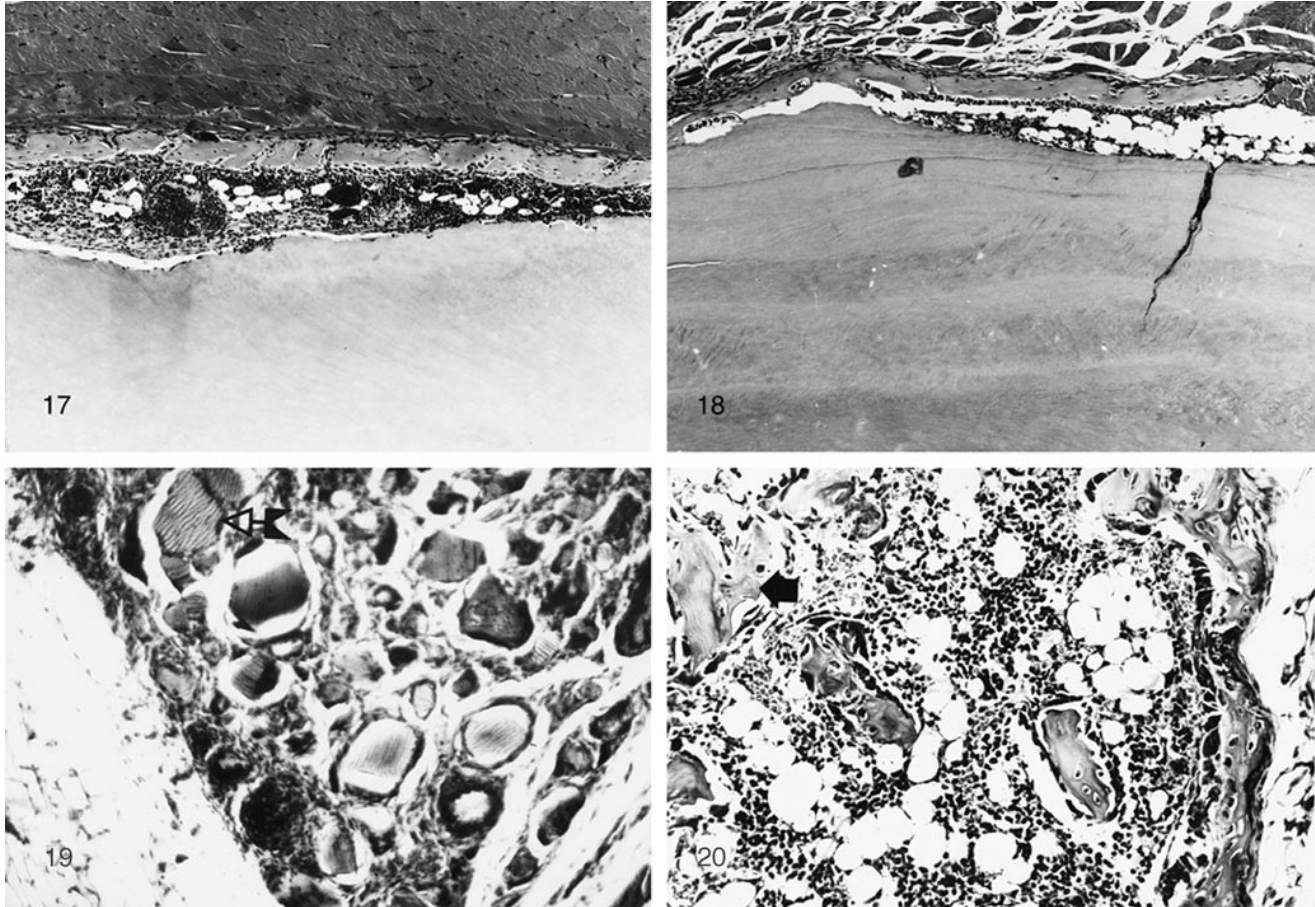


FIGURE 17. Photomicrograph of composite of 2 μ g of rhBMP-2 and PDM 3 weeks postimplantation in an athymic mouse. Note muscle (top), new bone and bone marrow (middle), and root dentin (bottom).

FIGURE 18. Photomicrograph of a composite of 2 μ g of rhBMP-2 and AAAM in an athymic mouse. Note: muscle (top), root dentin (bottom), and new bone and bone marrow in the space between.

FIGURE 19. Photomicrograph of an implant of pulverized AAAM root dentin 3 weeks after implantation in a normal mouse. Note dentinal tubules (arrow) and network of granulation tissue, but no bone development (magnification $\times 200$).

FIGURE 20. Photomicrograph of new bone development with an implant of a composite of pulverized AAAM root dentin and rhBMP-2, 3 weeks after the operation in a normal mouse. Note remnants of root dentin in trabecular bone (arrow).

new bone in an autogenic homostructural graft.²²

Extensive investigations of growth factors and BMP on shavings of cementum and dentin have been reported; rhBMP-2 induced connective tissue proliferation with attachments to cementum and bone.^{23,24} Sigurdsson *et al*²⁵ demonstrated that rhBMP-2 induced bone formation and periodontal bone regeneration in dogs. Arzate *et al*²⁶ isolated a partially purified cementum protein (with a molecular weight of 55 kDa) that stimulated chondrogen-

esis and mineralization in cultures of mouse embryo forelimb buds. In that study, progenitor cells (presumably derived from periodontal ligaments and alveolar bone) differentiated into cartilage and bone. BMP expression was transient in both embryonic development and organogenesis of bones and teeth, as observed by *in situ* hybridization or immunohistochemical methods.^{26,27}

The quantity of endogenous BMP in dysfunctional teeth was very small or nil compared with the large deposits

of bone induced by 2 μ g of exogenous BMP. The antigenicity of recombinant BMP compared with native dentin BMP remains to be determined by quantitative immunohistochemical methods.^{28,29} Previous experiments with demineralized cortical bone matrix as a carrier^{17,18} showed no qualitative difference in response to partially purified native hBMP and rhBMP-2.

Microscopically, implants of pulverized root with cementum on one surface of some particles or on no surfaces or implants of cementum shavings in-

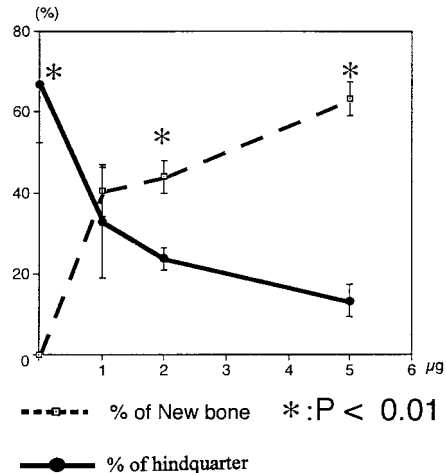


FIGURE 21. Graphic representation of volume of new bone and percent of the remnants of root dentin powder in the implants of AAAAM shown in proportion to the quantity of rhBMP-2 (1, 2, and 5 µg). New bone deposits replaced from 40 to 60% of the hindquarter muscle mass.

duced bone formation occurring in apposition to both cementum and non-cementum surfaces. Wozney *et al.*,³⁰ Sommerman *et al.*,³¹ Sommerman *et al.*,³² and Kagayama *et al.*³³ (1997) made GuHCl and EDTA extracts of bovine cementum and other tissues known to contain BMP and observed stimulation of human gingival fibroblasts *in vitro*. Miki *et al.*,²³ King *et al.*,³⁴ Nishimura *et al.*,³⁵ Kinoshita *et al.*,²⁴ Vanio *et al.*,³⁶ and Wang *et al.*³⁷ observed an increase in DNA synthesis in culture media with and without supplements of BMP and other growth factors.

Conover and Urist¹⁰ separated BMP from collagenase digests of gelatinized, demineralized dentin matrix of adult rabbits; the undigested residual matrix was rapidly resorbed and demonstrated very high levels of BMP activity. Fractionation of the collagenase resistant proteins produced a native BMP (with molecular weight of 30 and 23 kDa). Previously, Butler *et al.*³ isolated an insoluble noncollagenous BMP from a soluble phosphoprotein of dentin in rats, guinea pigs, and rabbits. Kawai and Urist⁷ described water-insoluble BMPs with molecular weights of 15 to 28 kDa isolated from a pulverized mixture of enamel, dentin, and cementum of unerupted bovine teeth. The isoinductive activity of these BMPs

was slightly higher than that of the BMPs isolated from cortical bone.

Present observations on root-matrix-induced bone development were derived from discarded dysfunctional teeth deficient in endogenous BMP. Some of the teeth were so decayed that only the root structure with a thin coat of cementum remained available for use as a carrier. Exogenous rhBMP-2 adsorbed to a pulverized root PDM or AAAAM proved to be as osteoinductive as autogeneic bone. Whether or not a large periodontal alveolar bone defect may be repaired using composites of rhBMP and PDM or AAAAM warrants special investigation.

ACKNOWLEDGMENTS

The authors are indebted to Drs Vicki Rosen and John Wozney for generous supplies of rhBMP-2, the Harry and Yvonne Lenart Charitable Foundation, the Joseph R. Biafora Fund, the Rachford Harris Fund, the AOASIF Research Commission, the Marjorie Gustars Dann Fund, and the American Academic Implant Dentistry Research Foundation. The authors wish to thank Edward King and Markus Niederwanger for preparation of the partially purified BMP and for surgical assistance, and Adelaida A. Zellipour, MT, for the histological preparation. Dr Urist is

aided by a grant from the American Academy of Implant Dentistry Research Foundation.

REFERENCES

1. Yeomans DJ, Urist MR. Bone induction by decalcified dentin implanted into oral osseous and muscle tissues. *Arch Oral Biol.* 1967;12:999-1008.
2. Bang G, Urist MR. Bone induction in excavation chambers in matrix of decalcified dentin. *Arch Surg.* 1967;94:781-789.
3. Butler WT, Mikulski A, Urist MR. Noncollagenous proteins of a rat dentin matrix possessing bone morphogenetic activity. *J Dent Res.* 1977;56:228-232.
4. Urist MR, Strates BS. Bone morphogenetic protein. *J Dent Res.* 1971;50(suppl 6):1392-1406.
5. Urist MR, DeLange RJ, Finerman GAM. Bone cell differentiation and growth factors: induced activity of chondro-osteogenic DNA. *Science.* 1983;220:680-686.
6. Urist MR, Chang JJ, Lietze A, Huo YK, Brownwell AG, DeLang RH. Methods of preparation and bioassay of bone morphogenetic protein and polypeptide fragments. In: Barnes D, Sirbaska DA, eds. *Methods in Enzymology*, vol. 146. New York, NY: New York Academy Press; 1987:294-312.
7. Kawai T, Urist MR. Bovine tooth-derived bone morphogenetic protein. *J Dent Res.* 1989;68:1069-1074.
8. Urist MR. The substratum for bone morphogenesis. *Dev Biol.* 1971;4:125-163.
9. Urist MR, Nakata N, Felsner JM, *et al.* An osteosarcoma cell and matrix retained morphogen for normal bone formation. *Clin Orthop.* 1977;124:251-266.
10. Conover MA, Urist MR. Dentin matrix morphogenetic protein. In: *The Chemistry and Biology of Mineralized Connective Tissues*. Northwestern University; May 3-7, 1981. New York: Elsevier-North Holland Inc; 1981:597-606.
11. Urist MR, Lietze A, Mizutani H, *et al.* A bovine low molecular weight

bone morphogenetic protein (BMP) fraction. *Clin Orthop*. 1982;162:219–232.

12. Urist MR, Mizutani H, Conover MA, Lietze A, Finerman GAM. Dentin bone and osteosarcoma tissue bone morphogenetic proteins. In: *Factors and Mechanisms Influencing Bone Growth*. New York, NY: Alan R. Liss; 1983:61–81.

13. Urist MR. Chemosterilized antigen-extracted surface demineralized allogeneic bone for arthrodesis. In: Friedlander F, Mankin H, Sell KW, eds. *Osteochondral Grafts*. Boston, Mass: Little Brown and Co, 1983:193–201.

14. Smith HV, Urist MR. Recombinant human bone morphogenetic protein (rhBMP) induced heterotopic bone development *in vivo* and *in vitro*. *PSEBM*. 1996;211:265–272.

15. Urist MR. Bone transplants and implants. In: Urist MR, ed. *Fundamental and Clinical Bone Physiology*. Philadelphia, Pa: JB Lippincott; 1980:331–368.

16. Urist MR. A substratum for bone morphogenesis. *Develop Biol*. 1971 (Suppl.); 4:125–163.

17. Becker W, Urist MR, Tuckler LM, Becker B, Oschsebein C. Human demineralized freeze-dried bone: inadequate induced bone formation in athymic mice. A preliminary report. *J Periodontol*. 1995;66(9):822–828.

18. Niederwanger M, Urist MR. Demineralized bone matrix supplied by bone banks for a carrier of recombinant bone morphogenetic protein (rhBMP-2): a substitute for autogeneic bone grafts. *J Oral Implant*. 1997; 22:210–215.

19. Urist MR, Mikulski A, Boyd SD. A chemosterilized antigen-extracted bone morphogenetic alloimplant for bone banks. *Arch Surg*. 1975;110:416–428.

20. Urist MR. Experimental delivery systems for bone morphogenetic protein. In: Wise DL, Altobelli DE, Schwartz ER, Gresser JD, Trantolo DJ, Yaszemski M, eds. *Handbook of Biomaterials and Applications, Section 3: Orthopaedic Biomaterials Applications*. Boston, Mass: Marcel Dekker; 1995:1093–1133.

21. Johnson EE, Urist MR. Preliminary explorations of reconstructive surgery with implants of autolyzed antigen-extracted allogeneic (AAA) bone surcharged with bone morphogenetic protein (BMP). In: Urist MR, Burwell RG, O'Connor BT, eds. *Bone Grafts, Derivations and Substitutes*. London, England: Butterworth Heinemann; 1994: 363–376.

22. Melonig JT. Decalcified freeze-dried bone allografts as implant material in human periodontal defects. *Int J Periodontics Restorative Dent*. 1984;4:41–55.

23. Miki Y, Narayanan AS, Page RC. Mitogenic activity of cementum components to gingival fibroblasts. *J Dent Res*. 1987;66:1399–1403.

24. Kinoshita A, Oda S, Takahashi K, Yokota S, Ishikawa I. Periodontal regeneration by application of recombinant human bone morphogenetic protein-2 to horizontal circumferential defects created by experimental periodontitis in beagle dogs. *J Periodontol*. 1997;68:103–109.

25. Sigurdsson TJ, Lee M, Kukota R, Turek TJ, Wozney TH, Wikesjo UM. Periodontal repair in dogs: recombinant human bone morphogenetic protein significantly enhances periodontal regeneration. *J Periodontol*. 1995;66:131–138.

26. Arzate H, Olson S, Page RC, Gown AM, Narayanan AS. Production of a monoclonal antibody to an attachment protein derived from human cementum. *RASEB J*. 1992;6:2990–2995.

27. Marusic A, Grcevic N, Katavic V. New bone induction by bone matrix and recombinant human bone morphogenetic protein-2 in the mouse. *Croatian Med J*. 1997;37:237–244.

28. Pinholt EM, Bang G, Haanaes H. Alveolar ridge augmentation in rats by

combined hydroxyapatite and osteoinductive material. *Scand J Dent Res*. 1991; 99:64–74.

29. Pinholt EM, Haanaes H, Roervik M, Donath K, Bang G. Alveolar ridge augmentation by osteoinductive materials in goats. *Scand J Dent Res*. 1992; 100:361–365.

30. Wozney JM, Rosen V, Celeste AJ, et al. Novel regulators of bone formation: molecular clones and activities. *Science*. 1988;242:1528–1534.

31. Somerman MJ, Archer SY, Shteyer A, Foster RA. Protein production by human gingival fibroblasts is enhanced by guanidine extracts of cementum. *J Periodontol Res*. 1987;22:75–77.

32. Somerman MJ, Argraves WS, Foster RA, Dickerson K, Norris K, Sauk JJ. Cell attachment activity of cementum: bone sialoprotein II identified in cementum. *J Periodontol Res*. 1991;26: 10–16.

33. Kagayama M, Li HC, Zhu J, Sasano Y, Hatakeyama Y, Mizoguchi I. Expression of osteocalcin in cementoblasts forming acellular cementum. *J Periodontol Res*. 1997;32:273–278.

34. King GN, King N, Gruchley AT, Wozney JM, Hughes FJ. Recombinant human bone morphogenetic protein-2 promotes wound healing in rat periodontal fenestration defects. *J Dent Res*. 1997;76:1460–1470.

35. Nishimura K, Hayashi M, Matsuda K, Shigeyama Y, Yamasaki A, Yamaoka AJ. The chemoattractive potency of periodontal ligament, cementum and dentin for human gingival fibroblast. *J Periodontol Res*. 1989;24:146–148.

36. Vanio S, Karavanova I, Jowett A, Thesleff I. Identification of BMP-4 as a signal mediating secondary induction during early tooth development. *Cell*. 1993;75:45–58.

37. Wang EA, Rosen V, D'Alessandro JS, et al. Recombinant human bone morphogenetic protein induces bone formation. *Proc Natl Acad Sci USA* 1990; 87:2220–2224. ■