

# PERIAPICAL IMPLANT PATHOLOGY

Harold I. Sussman, DDS, MSD

## KEY WORDS

Dental implants  
Osseointegration  
Periapical pathology  
Etiology  
Classification

Periapical implant pathology, a distinct dental lesion, is the coalescence of adjacent periapical pathology with the apical segment of a dental implant that results in a common lesion. I present four cases to document two proposed case types: type 1, implant to tooth, which occurs during osteotomy preparation either by direct trauma or through indirect damage and causes adjacent pulp to undergo devitalization; and type 2, tooth to implant, which occurs shortly after placement of the implant when an adjacent tooth develops periapical pathology, either by operative damage to the pulp or through reactivation of a prior apical lesion. In both types, the resulting periapical pathology contaminates the fixture and inhibits osseointegration of the implant during stage 1 healing. These two case types are presented to help clarify the use of etiology as the basis of a classification system.

## INTRODUCTION

Periapical implant pathology as a distinct entity was first reported as endodontic-implant pathology in the dental literature in 1993.<sup>1</sup> The lesion occurs infrequently when implants are placed adjacent to natural teeth.<sup>2-5</sup> When a periapical lesion from a tooth and an implant coalesce, the bone-titanium interface may become contaminated. Should this occur during stage 1 healing, the implant will not osseointegrate.<sup>6,7</sup> It is recommended that the fixture be removed as soon as possible so that osteomyelitis does not develop. If left in place, the implant pathology may cause extensive bone destruction and delay wound healing. If root pathology occurs after implant osseointegration, performing an apicoectomy on the implant is a possibility.<sup>8</sup>

## CASE PRESENTATIONS

There appear to be two basic pathways of periapical implant pathology, implant to tooth and tooth to implant.

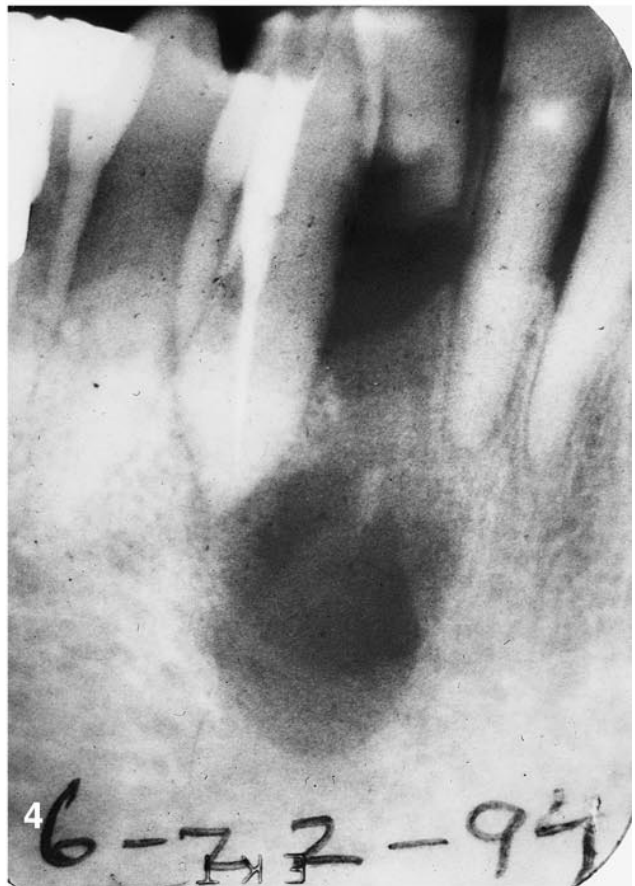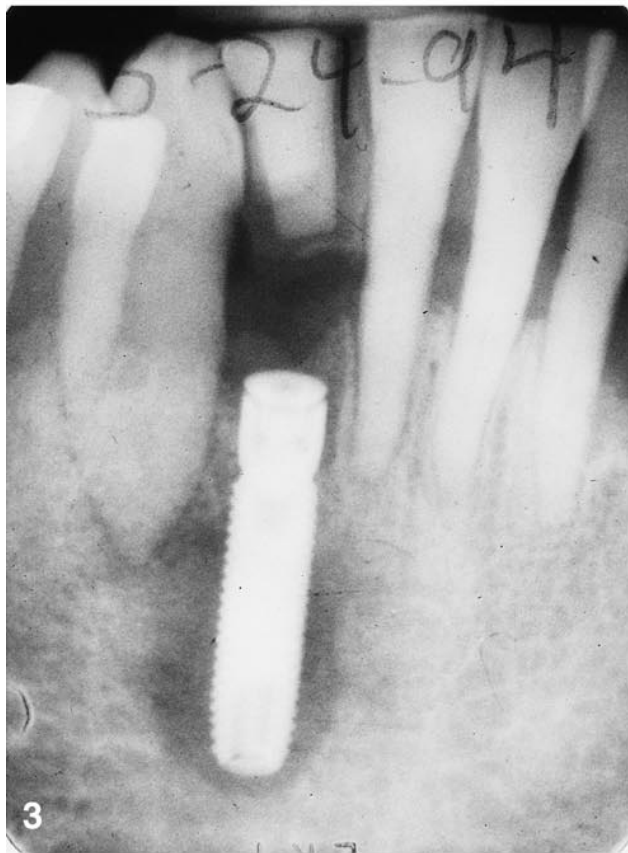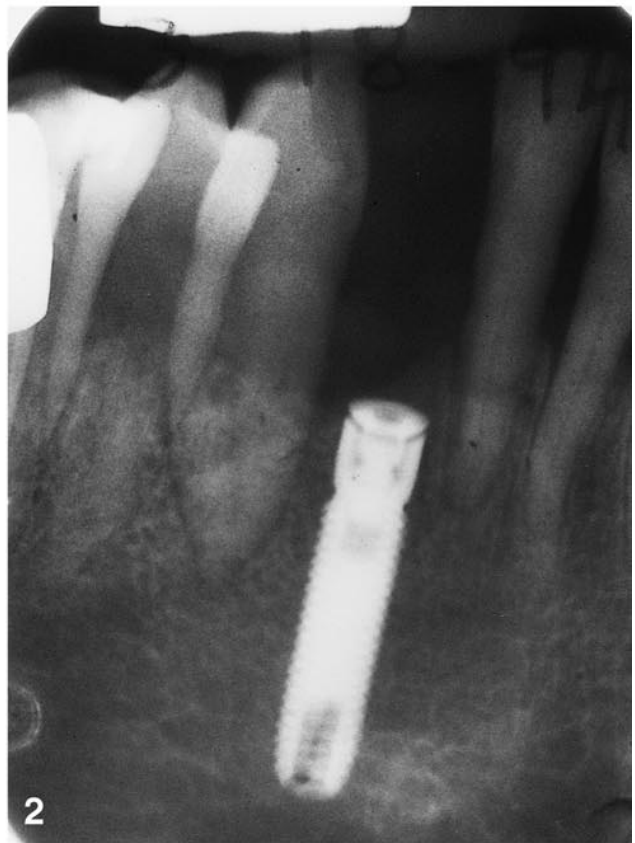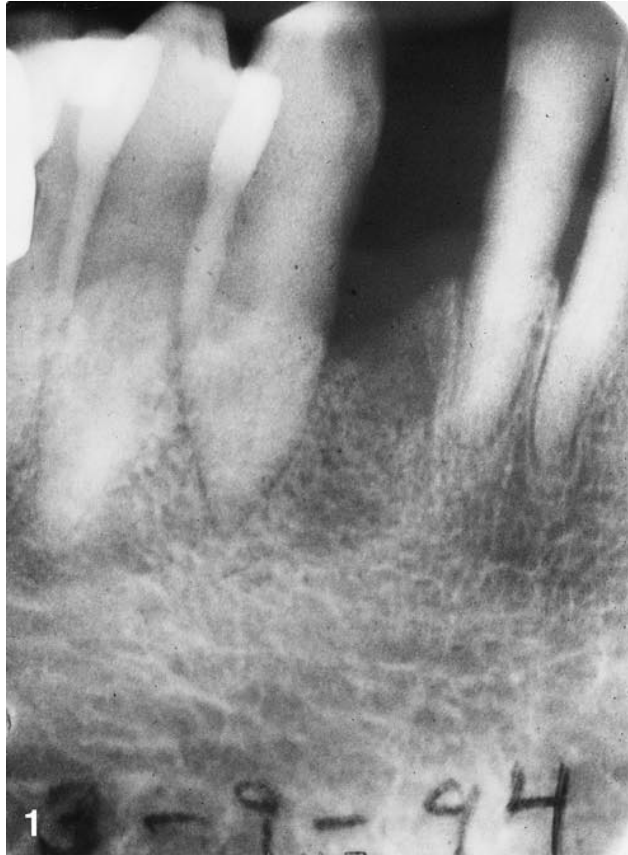### *Type 1: Implant to Tooth*

An implant-to-tooth lesion occurs when the insertion of the implant results in tooth devitalization. Possible causes include placement of the implant at an insufficient distance from the tooth during the osteotomy, overheating of bone during the osteotomy, or direct trauma to a tooth root via osteotomy preparation, cutting off the blood supply to the pulp.<sup>1,4,5,9</sup>

### *Type 2: Tooth to Implant*

A tooth-to-implant lesion occurs when a periapical lesion from a nearby devitalized tooth encroaches upon the implant and contaminates it. Possible causes could be injury of the pulp from operative tooth preparation, carious involvement, or external root resorption.<sup>3,10</sup> In addition, another possible cause could be the reactivation of a dormant periapical lesion and the removal of the periapical endodontic seal.<sup>2</sup>

Harold I. Sussman, DDS, MSD, is Associate Clinical Professor, Department of Periodontics, New York University College of Dentistry, New York, NY. He also has a private periodontic practice in New York, NY. Send reprint requests to Dr Sussman at 67 Park Avenue, Suite 1A, New York, NY 10016.



### Case Type Documentation

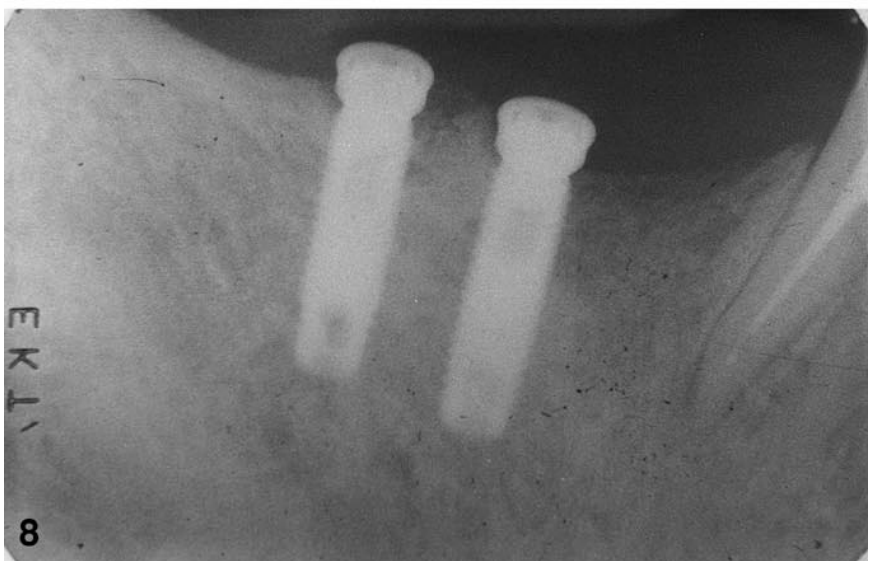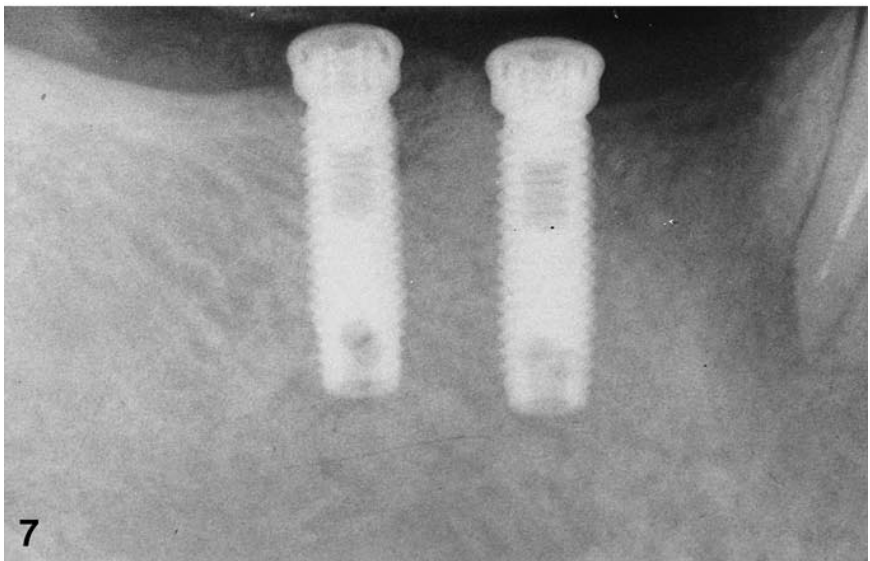
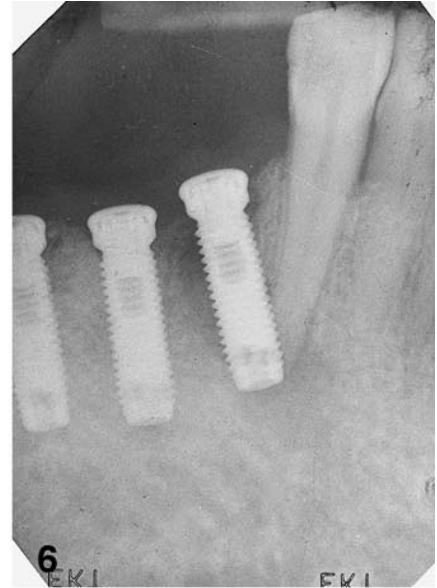
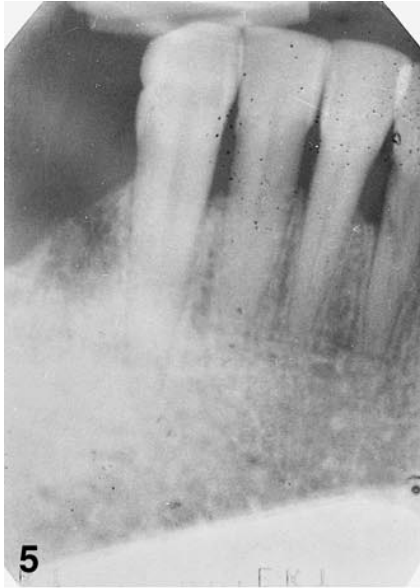Cases 1 and 2 were both examples of type 1 periapical implant pathology. Case 1 had an inadequate distance between the fixture and the tooth, an overheating of bone during the implant placement, or both (Figs 1–4). Case 2 had direct trauma to the tooth root as a result of implant placement (Figs 5–8).

Cases 3 and 4 were both examples of type 2 periapical implant pathology. Case 3 had exposure of the pulp, which caused periapical pathology leading to contamination of the implant (Figs 9–12). Case 4 had the periapical seal removed, which reactivated a periapical pathology (Figs 13–16).

Note that in all of the cases presented, the common denominator was that the endodontically treated teeth survived, whereas the associated implant fixtures failed to integrate and were lost, either by removal or exfoliation. This was partly the result of the pathologic lesion occurring during stage 1 healing.

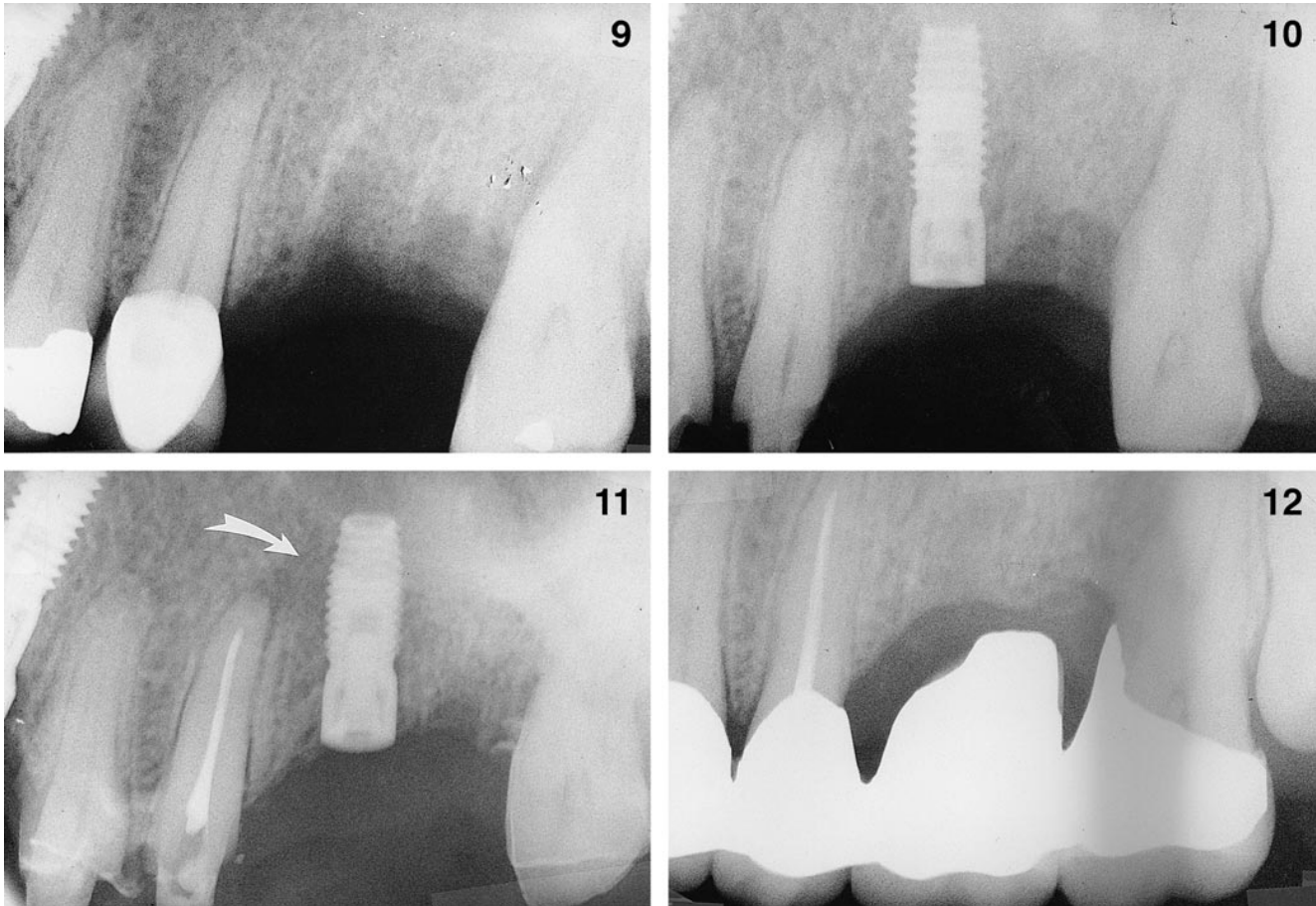
### DISCUSSION

Although originally termed endodontic implant pathology, there was con-



FIGURES 1–4. Type 1 lesion: implant to tooth, case 1. FIGURE 1. Radiograph of mandibular implant site. FIGURE 2. Radiograph of implant placed between canine and central incisor. FIGURE 3. Radiograph of apico-implant radiolucency, indicating devitalization of canine coalescing with apical half of fixture. FIGURE 4. Radiograph of site 3 months after implant exfoliation with endodontic filling in the canine. The cortical plate of bone exhibits resorption.

FIGURES 5–8. Type 1 lesion: implant to tooth, case 2. FIGURE 5. Radiograph of mandibular implant site. FIGURE 6. Radiograph showing implant base inserted through canine apex, demonstrating devitalization radiolucency. FIGURE 7. Radiograph of fixture removed and endodontic filling in canine. FIGURE 8. Radiolucency of implant site demonstrating osseous repair 4 months postoperatively.



FIGURES 9–12. Type 2 lesion: tooth to implant, case 3. FIGURE 9. Radiograph of maxillary implant site. FIGURE 10. Radiograph of implant placed in first molar site. Note pulp exposure in the crown of the second premolar. FIGURE 11. Radiograph of fixture with radiolucency extending from second premolar apex, which now has an endodontic filling. FIGURE 12. Surgical area demonstrating osseous repair 3 months postoperatively, with a four-unit fixed bridge in place.

fusion between this condition and the failure of endodontic stabilizing pins inserted through a root canal into the jaw.<sup>1</sup> The origin of this lesion may be a lesion either at the apex of the implant or at the apex of the tooth root. If the two lesions coalesce, contamination of the implant results. Should this occur during stage 1 healing, osseointegration will be prevented, leading to loss of the fixture.

There are two main types of periapical implant pathology proposed here: implant to tooth and tooth to implant.

*Type 1: Implant to Tooth*

Type 1 periapical implant pathology or implant-to-tooth pathology, occurs when osteotomy preparation, either by direct trauma or through indirect damage, causes adjacent tooth pulp to undergo devitalization. The resulting periapical pathology contaminates the fixture and inhibits osseointegration of the implant during stage 1 healing.

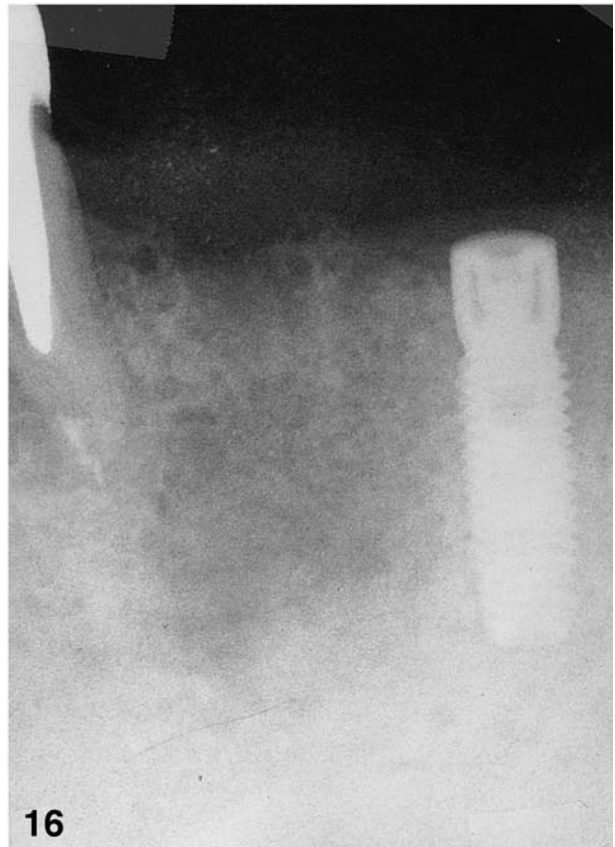
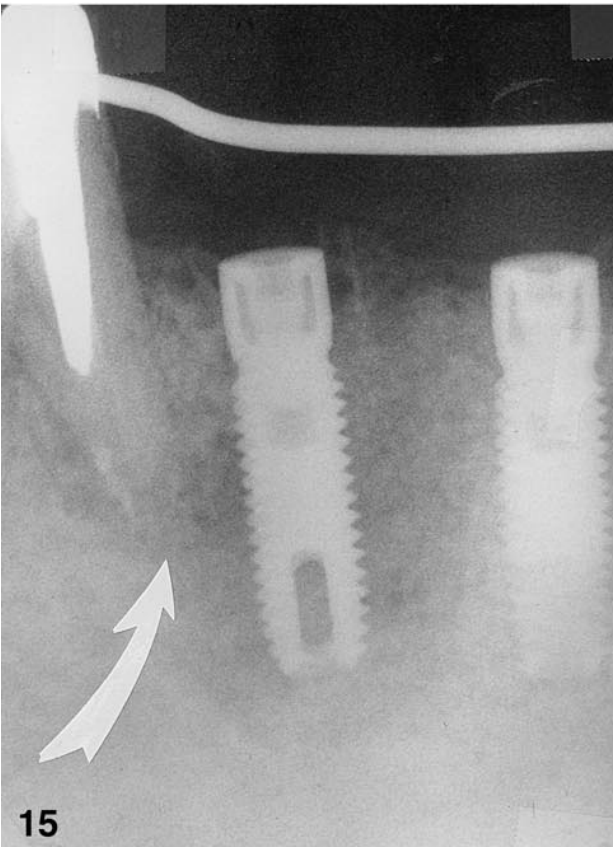
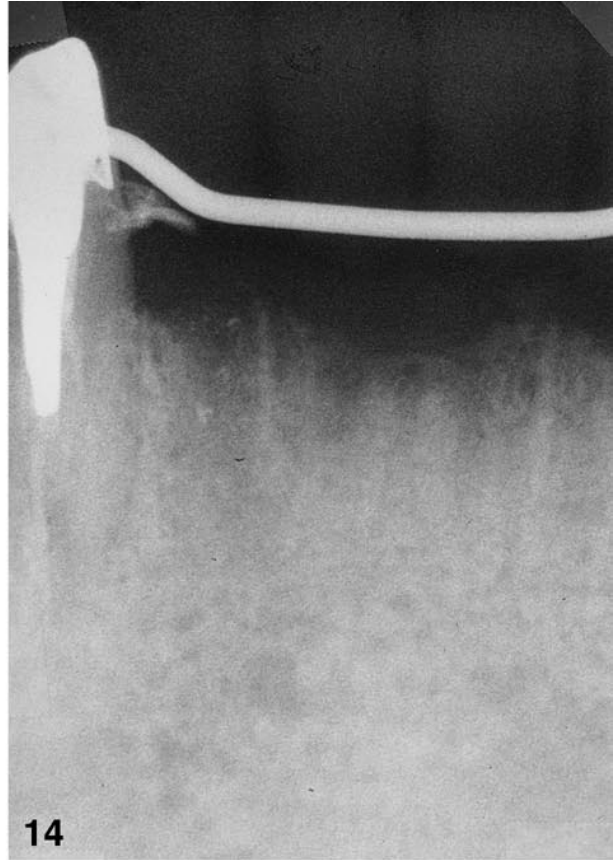
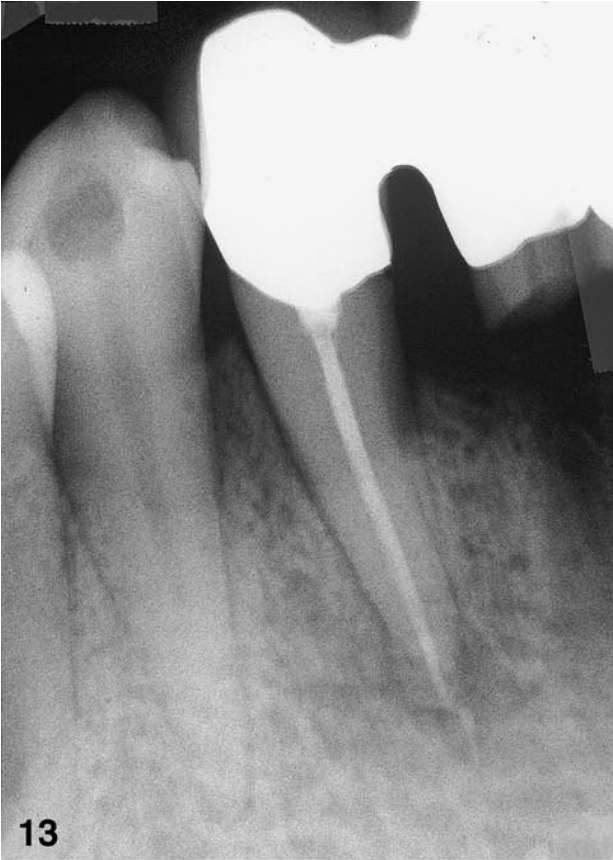*Type 2: Tooth to Implant*

Type 2 periapical implant pathology or tooth-to-implant pathology, occurs

shortly after placement of the implant when an adjacent tooth develops periapical pathology, either by operative damage to the pulp or through reactivation of a previously existing apical lesion. The resulting periapical pathology contaminates the fixture and inhibits osseointegration of the implant during stage 1 healing.

Note that if there is postextraction residual infection in the medullary bone, the base of the implant may become contaminated through tracking. When this involves an adjacent tooth, the coalescing lesion would fit into the

FIGURES 13–16. Type 2 lesion: tooth to implant, case 4. FIGURE 13. Radiograph of mandibular canine with recent endodontic filling. FIGURE 14. Radiograph of implant site before placement. FIGURE 15. Radiograph of radiolucent lesion extending from canine apex to lateral surface of adjacent implant fixture. Note loss of gutta percha from root canal. FIGURE 16. Radiograph of surgical site demonstrating osseous repair 3 months postoperatively.



type 1 category. There may well be other causes found that fit into both categories.

There are times when the health of an adjacent tooth's pulp is suspect; pulp testing in these cases is warranted (see Fig 1 and Fig 9). Prophylactic endodontic therapy of a nearby tooth may be prudent therapy before implant placement.

#### CONCLUSION

Case examples have been presented to document two types of periapical implant pathology. I hope that this will help to clarify this distinct dental lesion by using the etiologic origin of the pathology as a basis for this classification.

#### ACKNOWLEDGEMENTS

I thank Dr Gregory Kazandjian (Manhattan Department of Veterans Affairs

Medical Center) and Dr Dennis Tarnow (New York University College of Dentistry) for their invaluable assistance in preparing this manuscript.

#### REFERENCES

1. Sussman HI, Moss SS. Localized osteomyelitis secondary to endodontic-implant pathosis: a case report. *J Periodontol* 1993;64:306-310.
2. Sussman HI. Implant pathology associated with loss of periapical seal of adjacent tooth: clinical report. *Implant Dent* 1997;6:33-37.
3. Sussman HI. Endodontic pathology leading to implant failure: a case report. *J Oral Implantol* 1997;23:112-115.
4. Sussman HI. Tooth devitalization via implant placement: a case report. *Periodont Clin Invest.* 1998;20:22-24.
5. Sussman HI. Cortical bone resorption secondary to endodontic-im-

plant pathology: a case report. *NY State Dent J* 1997;63:38-40.

6. Branemark PI, Zarb G, Albrektsson T. *Tissue-Integrated Prosthesis: Osseointegration in Clinical Dentistry*. Chicago, Ill: Quintessence; 1985;11-70.

7. Lindhe J, Berglundh T, Ericsson I, Lilljenberg B, Marinello C. Experimental breakdown of peri-implant and periodontal tissues: a study in the beagle dog. *Clin Oral Implant Res* 1992;3:9-16.

8. Reiser GM, Nevins M. The periapical lesion: etiology, prevention and treatment. *Compendium* 1995;16:768-777.

9. Brisman DL. The effect of speed, pressure, and time on bone temperature during the drilling of implant sites. *Int J Oral Maxillofac Implant* 1996; 11:35-37.

10. Christensen GJ. Tooth preparation and pulp degeneration. *J Am Dent Assoc* 1997;128:353-354.

## DISCUSSION

In "Periapical Implant Pathology," Dr Sussman describes the periapical implant lesion as "a distinct dental lesion" and explains how etiology influences that classification. If we exclude any other factors that might be responsible or that might contribute to the lack of integration (traumatic surgery, lack of initial stabilization, sufficient bone in bucco-lingual dimension, etc.), all presented cases have a common denominator: loss of vitality of adjacent teeth. This is followed by bacterial invasion of root canal systems that become a constant source of infection unless they are thoroughly and properly eliminated and obturated.

If endodontic lesions were properly and successfully treated (which was not done in the presented cases according to the radiographic evidence), there is no reason to lose an implant or have it removed even if it happened during

stage 1 of healing after implant placement.

Besides efforts to introduce a new classification based on etiology, the author should emphasize the need for endodontic evaluation and, if necessary, treatment-retreatment of the teeth adjacent to potential implant sites. To avoid it and prevent it, this needs to be done before surgical implant placement. It is especially necessary when we are dealing with periodontally involved teeth, teeth with existing multiple restorations, and especially teeth with root canal therapy already done in the past regardless of them being asymptomatic.

This reminds me once again of the importance of proper diagnosis and treatment planning in addition to implant placement itself.

Milos M. Boskovic, D.D.S.

#### AUTHOR'S RESPONSE

The review of my manuscript by Dr. Boskovic, while astute, has one point in the second paragraph with which I disagree.

If an endodontic lesion communicates with an adjacent implant surface during stage 1 healing, even if endodontic therapy were done completely and properly at that point, the implant may still fail to osseointegrate. This may well be the result of irreversible contamination of the implant surface, precluding its ongoing integration process.

However, if endodontic lesions are properly and successfully treated prior to implant placement, then there should be no reason to lose an implant because of the development of adjacent periapical pathology during stage 1 healing.

Harold I. Sussman, D.D.S.