

EVALUATION OF THE PERIOTEST AS A DIAGNOSTIC TOOL FOR DENTAL IMPLANTS

A. Norman Cranin, DDS, D.Eng
Jack DeGrado, DDS
Marc Kaufman, DDS
Mylene Baraoidan, DDS
Robert DiGregorio, PharmD
George Batgitis, DDS
ZuBin Lee, DMD

KEY WORDS

Periotest
Implant stability
Subclinical mobility

The Periotest is examined as a possible replacement for outdated, inconsistent dental implant stability diagnosis tools. The Periotest has the advantage of offering reproducible findings by measuring the levels of subclinical mobility using an ultrasonically vibrating probe. The Periotest is successful in assessing the stability status of an implant, but it can detect the quantity of bony osseointegration only in terminal cases. Radiography proved to be a more sensitive method of determining pericervical bone loss; therefore, periapical radiographs in addition to the Periotest device were found to offer the most reliable assessment of an implant's status.

INTRODUCTION

The earliest methods used for diagnosing dental implant stability were subjective. Stability, one of the most significant factors in assessing the status of an implant, was determined by using two opposing instruments placed against the sides of the implant's abutment to create lateral forces. Another technique used was to tap the implant with the shank of an instrument and evaluate the sound created. These types of evaluation varied from examiner to examiner and because of their subjectivity, lacked the requisite accuracy.

The Periotest (Siemens) offers a more reliable method of diagnosing implant status by measuring levels of subclinical mobility in a reproducible manner.² It is an electronic instrument that uses an ultrasonically vibrating probe to assess micromobility (Fig 1). The device has been used in a number of applications for determining the periodontal

status of natural teeth since its introduction in 1983.² It has been an effective tool for evaluating implant stability from the time of second-stage surgery through all subsequent stages of management.³ It has also been used to determine tooth ankylosis as compared with physiologic tooth mobility.² Some have even claimed to use the instrument for balancing and fine-tuning the forces of occlusion.⁴ *In vitro* evaluations revealed that no statistically significant difference existed in measuring Periotest values (PTVs) from operator to operator.⁵ A high level of repeatability between different Periotest units had been shown as well.⁶

Successfully integrated dental implants have yielded a wide range of stability readings with the Periotest.⁷ This range in values is believed to reflect bone density at the implant interface. Bone density at the interface is related to implant location.⁸ For example, differences in PTV ranges have been

The authors are with the Brookdale Hospital Medical Center, Department of Dental and Oral Surgery, One Brookdale Plaza, Brooklyn, NY 11212-3198. Correspondence should be addressed to Dr. Cranin.



FIGURE 1. The Periotest apparatus consists of a control box and probe. The box contains a reporting window that indicates values. In addition, there is a corroborating verbal report that permits the operator to maintain eye contact with the site being tested.

reported for implants placed in the mandible as compared with the maxilla.^{9,10} However, controversies exist as to whether implant diameter, length, coating configuration, and location influence PTVs. Some investigators state that there is a correlation between larger implant diameters and lengths and the presence of coating as shown by lower PTV scores.¹¹ Others have published reports stating that implant coatings or variations in length do not influence PTV significantly.^{10,12,13} The length of the implant abutment and the location of the Periotest instrument on it were also shown to have influence on the PTV.^{5,13}

Radiographs are also used to assess the status of an implant under standardized conditions; they demonstrate the level and density of bone at the host site with reliability. Radiography presents only a two-dimensional image, however, and may be misleading because of the superimposition of anatomic structures (*ie*, tori, external oblique ridges). In addition, considerable bone loss may not influence the

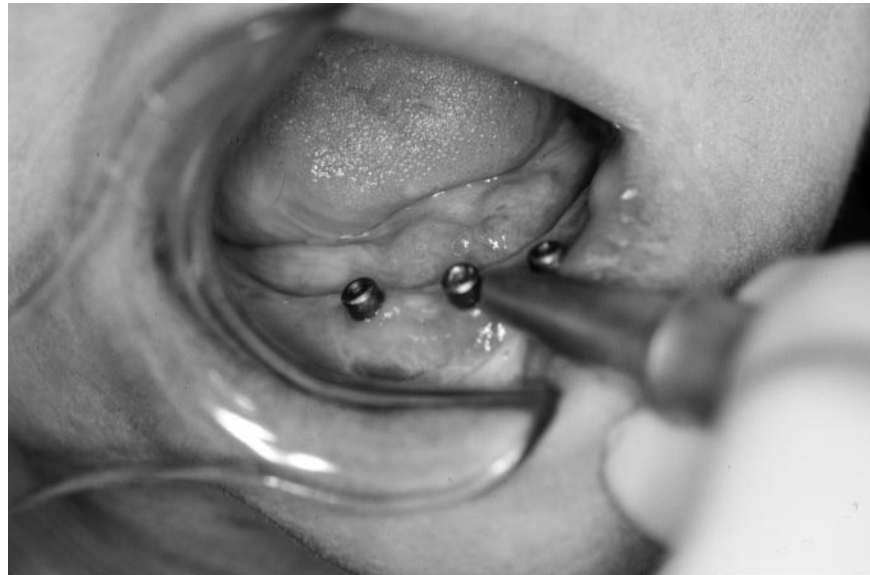

FIGURE 2. The probe must be applied horizontally in order to obtain a valid recording.

stability of an implant; establishing the correlation, if any, between the radiographic appearance of an implant and its Periotest reading would be of significant diagnostic value. In a study on periodontally involved teeth, a relationship was shown between PTV and bone loss.⁴ It has never been shown whether the same type of relationship exists for endosseous implants. One report concluded that the Periotest reflected implant stability but did not reflect the level of peri-implant bone and therefore could not be substituted for radiography.¹⁰ However, the principal aim of that study was to determine standard values only for 4.0-mm-diameter IMZ implants.

This study was designed to prospectively compare the Periotest values of implants of various designs, diameters, lengths, and locations to one another, as well as to relate radiographic findings to them in a blinded study.

MATERIALS AND METHODS

The Periotest device was used to measure the stability of implants at stage 2 surgery as well as at subsequent recall visits. At the second stage, healing posts were attached to the implants, and the patient was seated so that the jaw that was tested occupied a hori-

zontal posture. The probe was leveled at a right angle to the post, and its contact was made as close to the bony crest as possible (Fig 2). All of the implants were tested in lateral directions. Readings were taken until the device registered the same value three consecutive times. Patients who were seen for regular recall as well as those who presented for other reasons had their implants tested. Their prostheses, overdentures, and mesostructures were removed. A standardized periapical radiograph was taken of each implant. The location of each implant, its dimensions, its design, and other salient characteristics were charted. The radiographs were rated by two skilled and blinded reviewers using a grid to calculate the total length of the implant and the percentage of bone loss. A radiographic value (RV) from 0 to 10 was assigned to each implant. A value of 0 was given to implants with no radiographic crestal bone loss, and a value of 10 was assigned to those with total radiographic bone loss. The implants were categorized in relation to their locations: anterior mandible (AMn), posterior mandible (PMn), anterior maxilla (AMx), and posterior maxilla (PMx). The implants tested in this study varied in design. They included hydroxy-

apatite (HA) coated cylinders, titanium plasma-sprayed (TPS) cylinders, and commercially pure (CP) titanium as well as titanium alloy screws. Statistical analysis of variance was performed.

RESULTS

Table 1 shows an analysis of the implant data pool. The data were subdivided according to PTV, implant length, diameter, and RV. Some of the RV data could not be used because of poor image quality resulting from an inability to obtain an accurate radiograph using the paralleling technique. Therefore, the PTV data, as they related to implant length and width, were more numerous than the RV data.

In the AMn, a total of 103 implants were tested with the Periotest device. PTVs ranged from -8 to 15 , with an average of -4 . RVs ranged from 0 to 8 , with mean of 1 . Implant lengths varied from 8 to 20 mm, and implant diameters ranged from 3.25 to 4.0 mm. A correlation was found between PTV and RV for this group which was reflected in an R^2 of 0.354 . As radiographic bone loss increased, the Periotest readings in general became higher (Graph 1a). A few implants however, did not follow this trend. Several implants that demonstrated PTVs above the stable range appeared to have little radiographic bone loss. Conversely, one implant that had over 50% bone loss demonstrated a PTV of -1 (Fig 3, Graph 1a). No correlation was found between PTV and implant lengths or diameters (Fig 4, Graph 1b, c).

In the PMn, a total of 37 implants were tested. PTVs ranged from -7 to 7 , with a mean of -3 . RVs ranged from 0 to 10 , with a mean of 1.5 . Implant lengths varied from 8 to 16 mm, and implant diameters ranged from 3.25 to 4.0 mm. A positive correlation was noted when PTV and RV were compared (Graph 2a). As radiographic bone loss increased, PTVs increased. Most implants conformed to this trend. However, a few implants with $40\text{--}50\%$ radiographic bone loss had PTVs well

	Mean Implant PTV*	Mean Implant RV	Mean Implant Length	Mean Implant Diameter
AMn ($n = 103$)	-4	1	15	3.3
PMn ($n = 37$)	-3	1.5	10	3.3
AMx ($n = 106$)	-3	1	13	3.3
PMx ($n = 44$)	-2	1	10	3.3

* AMn, anterior mandible; PMn, posterior mandible; AMx, anterior maxilla; PMx, posterior maxilla; PTV, periotest values (-8 to $+20$); RV, radiographic value (0 to 10). Mean Periotest values indicate that the most stable implants were in AMn, followed by the PMn and AMx. The lowest stability was seen for the PMx group.

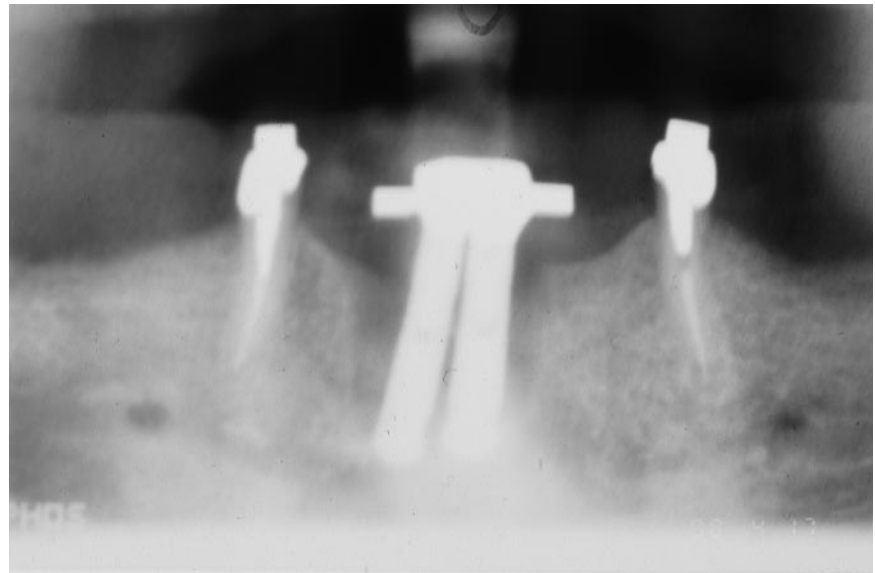


FIGURE 3. Implants in the anterior mandible demonstrating 50% bone loss. Such loss may not be recognized by the Periotest.

into the negative range (Fig 5, Graph 2a). Correlation was also found between PTV and implant length (Graph 2b). As implant lengths increased, PTVs became higher. In addition, a correlation was found between PTV and implant diameter (Graph 2c). As implant diameters increased, PTVs became higher.

In the AMx, a total of 106 implants were tested. PTVs ranged from -8 to 15 , with a mean of -3 . RVs ranged from 0 to 10 , with a mean of 1 . Implant lengths varied from 10 to 16 mm and implant diameters ranged from 3.25 to 4 mm. A statistically significant correlation was found between PTV and RV (Graph 3a). However, as may be noted from the graph, some implants that

demonstrated RVs of 2 to 6 ($20\text{--}60\%$ radiographic bone loss) showed PTVs well into the negative range (Fig 6). There was no statistically significant correlation between PTVs and implant lengths or diameters (Graphs 3b, c).

In the PMx, a total of 44 implants were evaluated. PTVs ranged from -7 to 15 , with a mean of -2 . RVs ranged from 0 to 10 , with a mean of 1 . Implant lengths varied from 7 to 16 mm and implant diameters ranged from 3.25 to 4.0 mm. A statistically significant correlation was noted when PTVs and RVs were compared (Graph 4a). As radiographic bone loss increased, PTVs became more elevated (Fig 7). Although no correlations were seen for PTVs and implant lengths (Graph 4b),

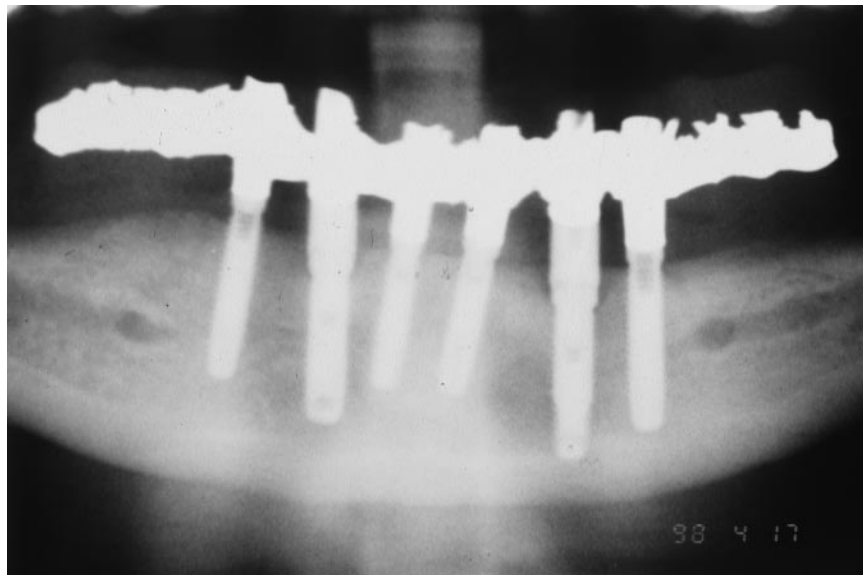


FIGURE 4. In the anterior mandible, varying implant dimensions played no role in determining Periotest ratings.

a trend was noted when implant diameters and PTVs were compared. As implant diameters increased, PTVs became lower (Graph 4c). This correlation, however, also was not statistically significant.

DISCUSSION

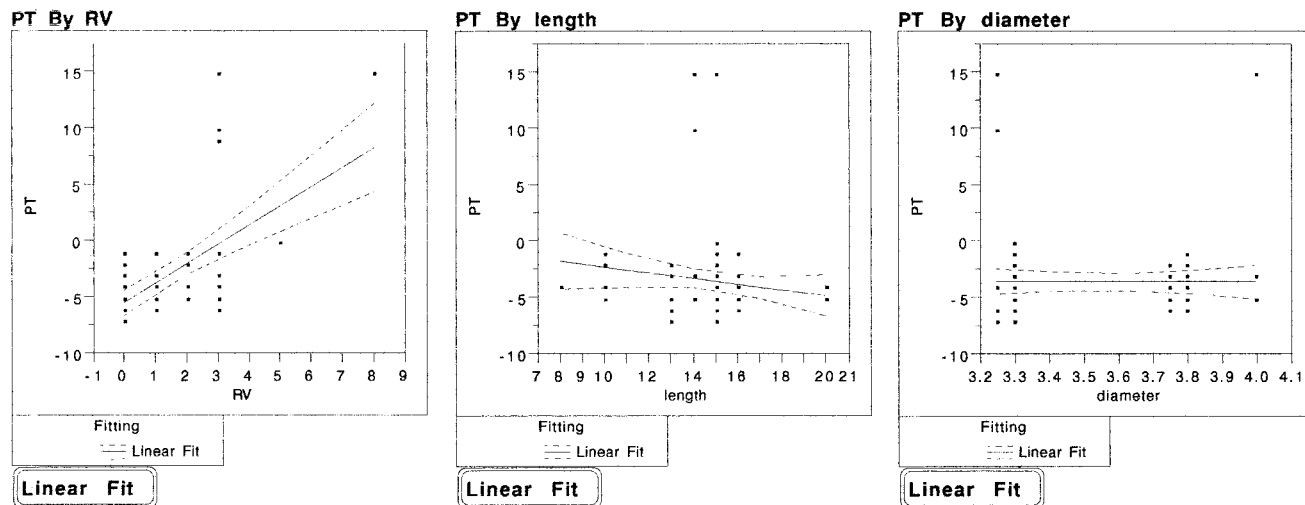
A statistically significant correlation was found between PTV and RV in all

four groups. An R^2 value of 1 implies a negative relationship between the two groups. As one value decreases, the other increases by the same amount. The R^2 values for the four groups ranged from 0.354 to 0.133 (Table 2).

The only region that showed a correlation between PTV and length was PMn. In this region, it appeared that

longer implants were less stable than shorter implants. Studies of the other three regions, however, showed evidence that as length increased, implant stability increased (Table 3). Only the data collected for the PMn group were statistically significant. In a previous long-term investigation, it was clinically established that longer implants function over longer periods.¹⁴

Correlation was found between PTV and implant diameter for the PMn group. Wider implants had higher PTVs. The same study for the PMx group showed a reverse relationship. As implant diameter increased, stability increased commensurately. However, this finding was not statistically significant. The correlation for the PMn group may have resulted from collection of data for implants placed in highly trabecular bone. Implant stability in this region may be a reflection of the modulus of elasticity of bone itself, irrespective of implant length. Another factor that influenced the results of the PMn group was that it, alone, did not include implants tested at uncoverty. The implants tested in this region had been in function for extended periods. All the other groups had implants that



GRAPH 1. (a) AMn Periotest value versus radiographic value. Note the ascending slope of the fit line (as radiographic bone loss increases, periotest values become more positive) and that some implants have radiographic bone loss of 3–5 and a negative Periotest value (points below the fit line). Some implants showed low radiographic values and had positive Periotest readings (points above the fit line). (b) AMn Periotest value versus implant length. The descending slope of the fit line indicates that as implant length increase, periotest values decrease. (c) AMn Periotest value versus implant diameter. The nearly horizontal fit line reflects the negligible effect of implant diameter on Periotest values for this group.

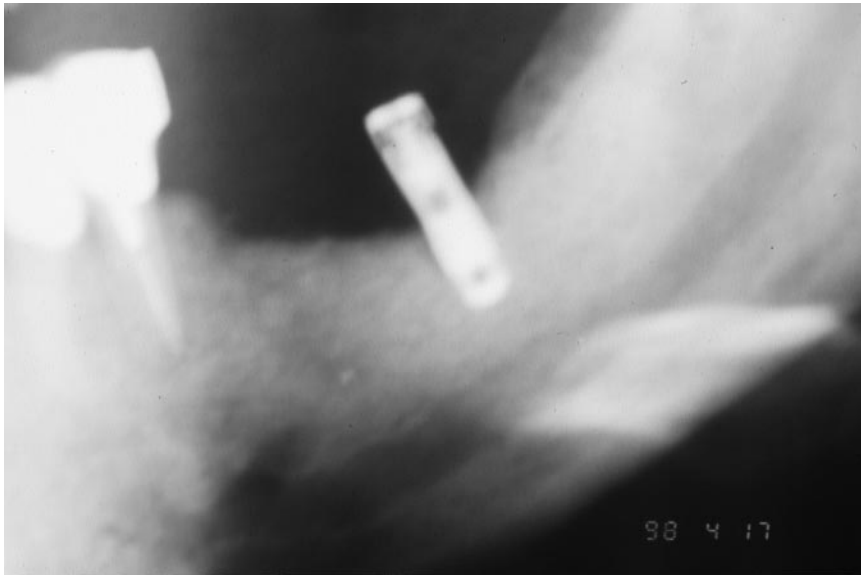


FIGURE 5. Marked bone loss surrounded posterior mandibular implants. Periotest ratings in such instances failed to detect such findings.

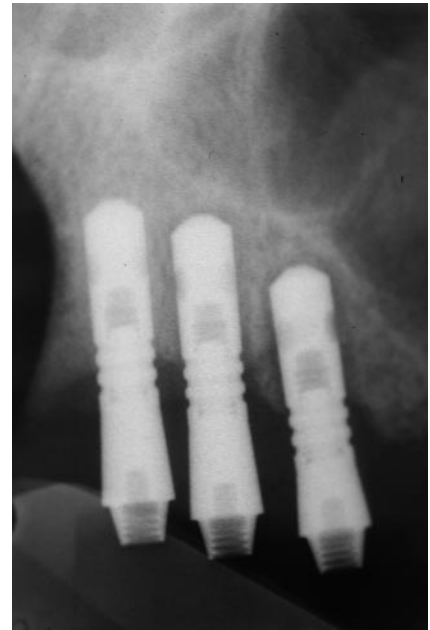


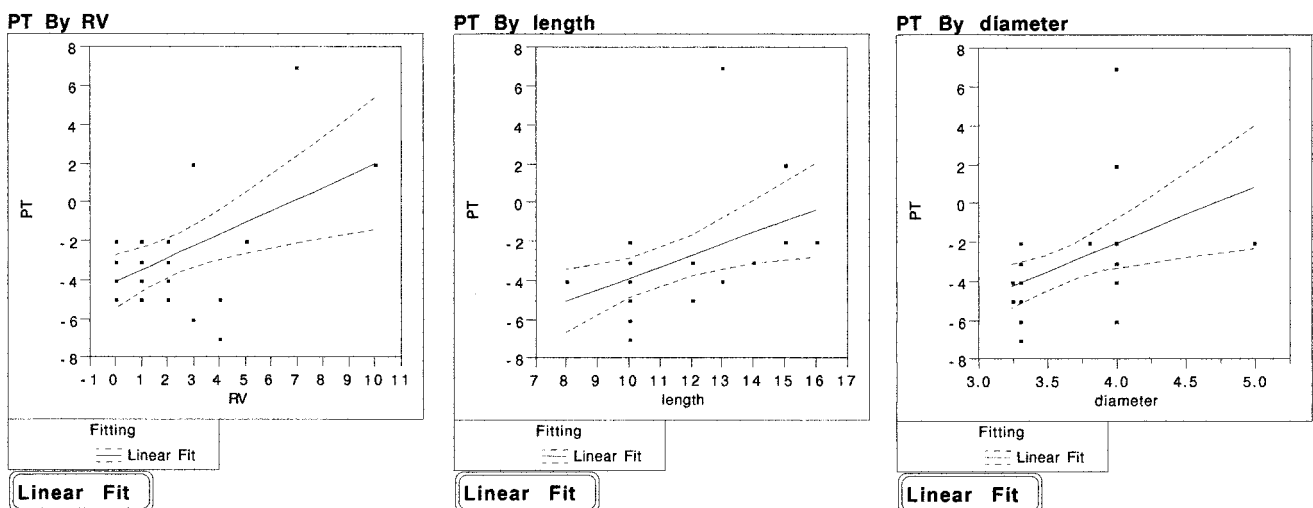
FIGURE 6. The anterior implant had a negative Periotest rating (-2), and the two posterior implants showed +7 and +10 ratings, respectively. In this case, Periotest and radiographic corroboration were clear.

were tested at stage 2 surgery as well as implants that had been in function. Another consideration was the small sample size of the PMn group.

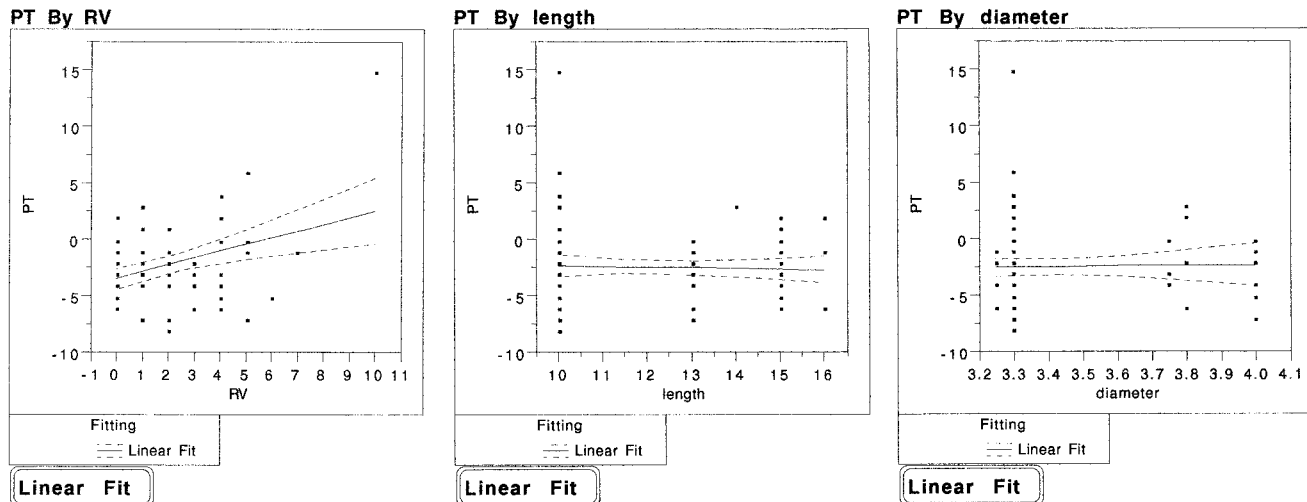
The Periotest apparatus has been shown to be successful in assessing the stability of an implant.⁶ However, it often fails to detect saucerization of bone. Radiographs will show bone levels of an implant. The relationship between radiographic bone loss and implant stability was found to be minimal in

this study. It was found that even though an implant was stable, it may have suffered significant horizontal bone loss. The Periotest did not detect the degree of bone loss until it was very advanced. Based on these findings, the Periotest is a reliable tool for the diagnosis of stable implants, and it may be used to evaluate the salvagability of an implant with advanced bone loss. The device, however, will fail to diagnose an implant with progres-

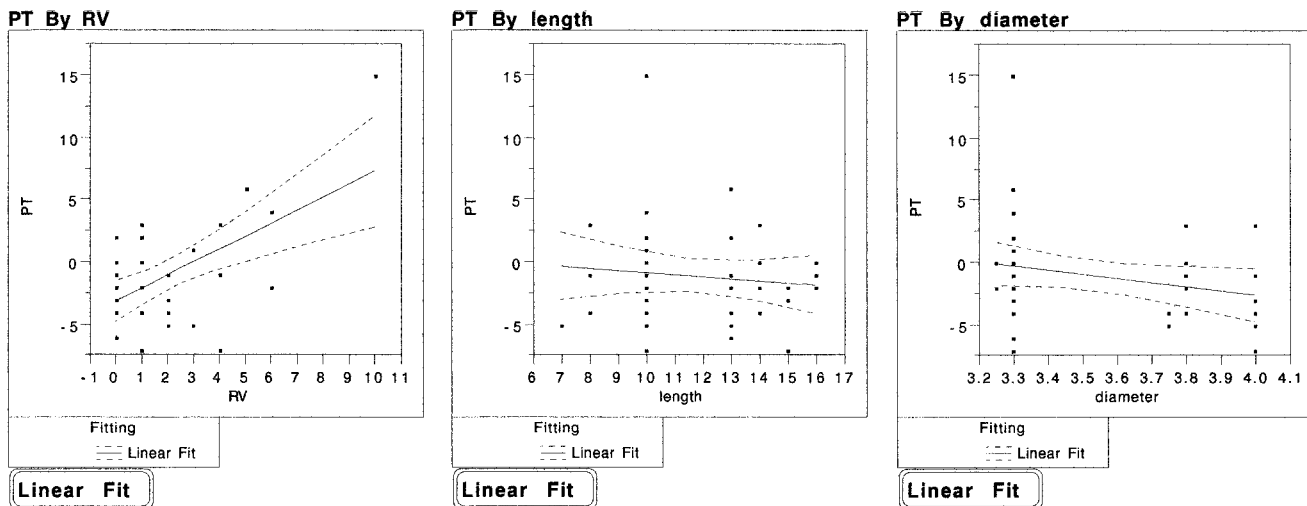
sive bone loss, because its values remain the same until the bone loss is virtually terminal. Therefore, the information gained from application of the Periotest will have to be combined with other clinically harvested information in order to determine the true status of an implant.



GRAPH 2. (a) PMn Periotest value versus radiographic value. Note the ascending slope of the mean fit line. (b) PMn Periotest value versus implant length. The ascending slope indicates that as implant length increases, Periotest values become more positive. (c) PMn Periotest value versus implant diameter. The ascending slope indicates that as implant diameter increases, Periotest values become more positive.



GRAPH 3. (a) AMx Periotest value versus radiographic value. Note the ascending slope of the fit line and that several implants that had radiographic bone loss ranging from 10–60% had Periotest values well into the negative range (points below the fit line). (b) AMx Periotest value versus implant length. Note the descending slope of the fit line. As implant length increases, Periotest values become somewhat more negative. (c) AMx Periotest value versus implant diameter. The somewhat ascending slope of the fit line reflects little effect of implant diameter on Periotest values.



GRAPH 4. (a) PMx Periotest value versus radiographic value. Note the sharply ascending fit line and that, again, some implants that have radiographic values of 4–6 are in the negative Periotest value range. (b) PMx Periotest value versus implant length. Note the descending slope. (c) PMx Periotest value versus implant diameter. The descending slope of the fit line indicates that as implant diameter increases, periotest values become more negative.

Radiography, on the other hand, showed itself to be a more sensitive method of determining pericervical bone loss; it enabled us to see bone loss around implants before the Periotest indicated changes in implant stability. It appeared that a number of implants in all four regions studied presented with 50% or more crestal bone loss radiographically and still maintained ex-

cellent stability. Radiography in addition to mobilometry, however, presents the most accurate evaluation of implant status.

CONCLUSIONS

1. Positive correlation was seen between radiographic bone loss and loss of implant stability for all four groups.

2. The lowest (best) Periotest ratings were found among AMn implants. The regions that followed were PMn and AMx. The highest readings were for the PMx. This is consistent with previous reports that compared implant stability with bone quality and location.
3. The Periotest device was reliable in the assessment of stability but not in

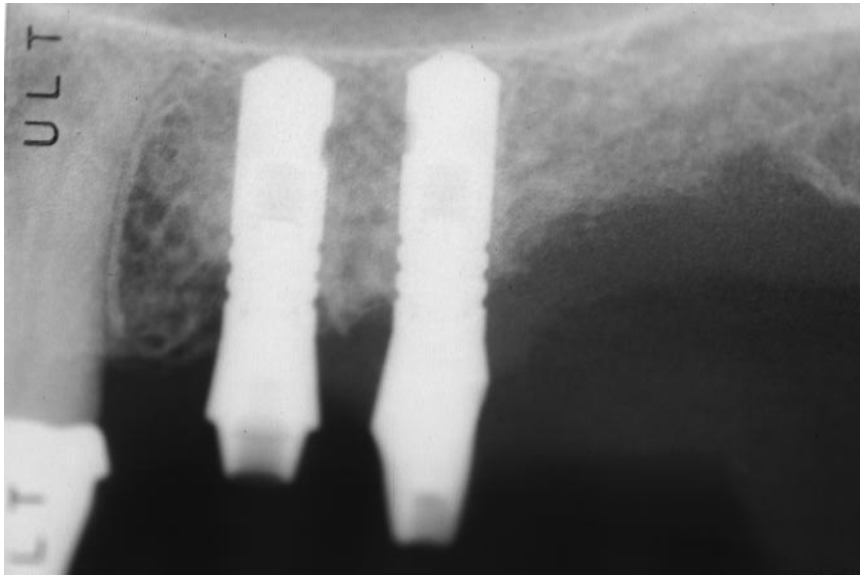


FIGURE 7. Despite modest bone loss surrounding the anterior implant of these two, Periostest ratings were both in the minus range.

more reliable assessment of implant status.

REFERENCES

1. Van Steenberghe D, Qirynen M. Reproducibility and detection threshold of peri-implant diagnosis. *Adv Dent Res.* 1993;7:191-195.
2. Van Scotter DE, Wilson CJ. The Periostest method for determining implant success. *J Oral Implantol.* 1991;17:410-413.
3. Truhlar RS, Morris HF, Ochi S, Winkler S. Assessment of implant mobility at second-stage surgery with the Periostest: DICRG interim report no. 3. *Implant Dent.* 1994;3:153-156.
4. Schulte W, Lukas D. Periostest to monitor osseointegration and to check the occlusion of oral implantology. *J Oral Implantol.* 1993;19:23-32.
5. Chai JY, Yamada J, Pang IC. In vitro consistency of the Periostest instrument. *J Prosthodont.* 1993;2:9-12.
6. Manz MC, Morris HF, Ochi S. An evaluation of the Periostest system (part II). *Implant Dent.* 1992;1:221-226.
7. Chavez H, Ortman LF, DeFranco RL, Medige J. Assessment of oral implant mobility. *J Prosthet Dent.* 1993;7:421-426.
8. Tricia J, Laohapand P, Van Steenberghe D, Quirynen M, Naert I. Mechanical state assessment of the im-

TABLE 2
Analysis of Periostest value correlation with radiographic value, implant length, and diameter*

	RV†	Length	Diameter
AMn	0.354 [0.000]	0.024 [0.144]	0.000 [0.946]
PMn	0.276 [0.006]	0.212 [0.012]	0.227 [0.009]
AMx	0.133 [0.001]	0.002 [0.661]	0.000 [0.827]
PMx	0.331 [0.000]	0.011 [0.488]	0.067 [0.093]

* The top numbers indicate the R² values reflected in the slope of the fit line in Graphs 1-4. The bottom numbers, in brackets, indicate the F values (probability). Statistical significance was assigned to F values lower than 0.05.

† AMn, anterior mandible; PMn, posterior mandible; AMx, anterior maxilla; PMx, posterior maxilla; RV, radiographic value.

ed with lower stability for the PMn group. Although there was no statistically significant correlation, a trend was noted between increased implant diameter and increased stability in the PMx group.

6. The Periostest diagnosed failed implants very well but was unable to reliably detect quantities of bony osseointegration.

7. Periapical radiographs combined with the Periostest device offered a

degree of crestal bone loss. All four groups had some implants that had advanced bone loss and a favorable Periostest reading. PTVs reflected only very advanced crestal bone loss.

4. Increased implant length correlated with decreased stability in the PMn group. However, the opposite trend was seen in the other three regions.
5. Increased implant diameter correlat-

TABLE 3
Results of PTV* correlation; summary of data interpretation for each group (Graphs (1-4)†

	RV	Implant Length	Implant Diameter
AMn	Bone loss correlates with loss of stability	No correlation	No correlation
PMn	Bone loss correlates with loss of stability	Longer implant correlates with decreased stability	Wider diameter correlates with decreased stability
AMx	Bone loss correlates with loss of stability	No correlation	No correlation
PMx	Bone loss correlates with loss of stability	No correlation	Trend: increased stability was seen with larger implant diameter

* AMn, anterior mandible; PMn, posterior mandible; AMx, anterior maxilla; PMx, posterior maxilla; PTV, Periostest value; RV, radiographic value.

† Analysis of variance between PTV and RV, PTV and implant length, and PTV and implant diameter in the four subgroups.

plant–bone continuum: a better understanding of the Periotest method. *Int J Oral Maxillofac Implants*. 1995;10:43–49.

9. Salonen MA, Oikarinen K, Virtanen K, Pernu H. Failures in the osseointegration of endosseous implants. *Int J Oral Maxillofac Implants*. 1993;8:92–97.

10. Hass R, Saba M, Mensdorff-Pouly N, Mallath G. Examination of damping behavior of IMZ implants. *Int J*

Oral Maxillofac Implants. 1995;10:410–441.

11. Ochi S, Moris HF, Winkler S. The influence of implant type, material, coating, diameter and length on Periotest values at second-stage surgery: DICRG interim report no. 4. *Implant Dent*. 1994;3:159–162.

12. Carr AB, Papazoglou E, Lersen PE. The relationship of Periotest values, biomaterial, and torque to failure in

adult baboons. *Int J Prosthodont*. 1995;8:15–20.

13. Teerlinck J, Quirynen M, Darius P, Van Steenberghe D. Periotest: an objective clinical diagnosis of bone apposition toward implants. *Int J Oral Maxillofac Implants*. 1991;6:55–61.

14. Niedermeier W, Kublbeck K. Factors involved in endosseous implant function. *Dtsch Zahnärztl Z*. 1991;46:589–594. ■