

USE OF NEW MAGNETIC ATTACHMENTS FOR IMPLANT-SUPPORTED OVERDENTURES

Takehiro Fujimoto, DDS, PhD
Atsushi Niimi, DDS, DMSc
Itsuki Murakami, DDS, MS, PhD
Minoru Ueda, DDS, PhD

KEY WORDS

Brånemark implant
Magnetic implant attachment
Overdenture

Takehiro Fujimoto, DDS, PhD, is an Instructor in the Department of Oral Surgery, Nagoya University School of Medicine, Nagoya, Japan. He is also currently located at the Department of Oral and Maxillofacial Surgery, Loma Linda University School of Dentistry, Loma Linda, Calif 92350.

Atsushi Niimi, DDS, DMSc, is an Assistant Professor, Department of Oral Surgery, Nagoya University School of Medicine, Nagoya, Japan.

Itsuki Murakami, DDS, MS, PhD, is Director, Sophia Implant Center, Nagoya, Japan, and Clinical Assistant Professor, Department of Oral Surgery, Nagoya University School of Medicine, Nagoya, Japan.

Minoru Ueda, DDS, PhD, is Professor and Chairman of the Department of Oral Surgery, Nagoya University School of Medicine, Nagoya, Japan.

A newly designed magnetic attachment system for external hexed implants with a standard abutment platform has been developed. This system has certain definite advantages over bar attachments and ball attachments, which are frequently utilized for implant-supported overdentures. Especially, it can be applied to cases with reduced vertical dimension of occlusion because the total height of the magnet and the keeper is only 2.3 mm when assembled. In addition, detrimental lateral stresses to the fixture are greatly alleviated due to very low attractive forces horizontally. Favorable clinical results using this new magnetic attachment system have been obtained, and it may be considered a useful addition to overdenture therapy using any external hexel implant with a standard abutment platform, such as the Brånemark implant system.

INTRODUCTION

At present, there are several kinds of attachments that may be applied to overdentures that are supported by osseointegrated implants. The oldest method employs clips embedded in the denture with implant connecting bars.^{1,2} Next came a system with O-rings embedded in the denture that snapped onto ball attachments that were connected to implants.^{1,3} Recently, a third type of attachment, a magnetic attachment, was put into clinical use in implant dentistry.⁴⁻⁸ Additionally, it has been demonstrated that the magnetic field does not affect the surrounding bone tissues.^{9,10} Previous magnetic attachment systems had certain disadvantages such as complex laboratory procedures for castings, the tendency of dentures to

be bulky, and the necessity of excessive interarch space.¹¹

Although the samarium-cobalt alloy magnet is most frequently used for dental placement, neodymium-iron-boron alloy has great advantages, including its small size and large attractive force. The neodymium-iron-boron alloy has approximately 20% stronger attractive forces per unit volume than the samarium-cobalt unit.¹² Recently, a neodymium-iron-boron alloy magnet was developed into a very compact and thin magnetic attachment system for Brånemark implants. Therefore, the outline of this system and a case are reported.

MATERIALS AND METHODS

Magnet and keeper

The magnet used in this paper is called Hicorex Super 4515® (Hitachi




FIGURE 1. (a) Exploded view of a magnetic attachment and an implant. The keeper (K) is screwed onto the abutment cylinder (A), and the magnet (M) is assembled in the denture. (b) Components assembled together.

Metals, Ltd, Tokyo, Japan), and it has a columnar shape (Fig 1). An undercut is provided to the superior part of the magnet to enhance its retention to the denture. The diameter of this magnet is 4.5 mm, and its height is 1.5 mm. The attractive force is known to be 910 g.

The keeper is manufactured by grinding out magnetic stainless steel, and it possesses threads with a shape identical to that of an abutment screw. The diameter of the keeper is 4.5 mm, which is the same as the diameter of a standard abutment. The height of the head of the keeper is 0.8 mm, which is very thin.

Clinical techniques

Prior to incorporation of the magnet into the completed denture, the keeper is connected to the abutment cylinder

by screwing it in. Following the second-stage surgery and soft tissue healing, standard abutments, which protrude 0.5–1.0 mm supragingivally (Fig 2), replace the healing abutments. A hexagon screw is utilized for keeper connection.

After keeper connection, impression-taking procedures are carried out in a conventional manner. After impression taking, occlusal registration and try-in of wax dentures are performed in a conventional manner as well. During this period of overdenture fabrication, the old denture may be kept in function either by incorporating magnets into it or by applying a tissue-conditioning material.

When the overdenture is completed, it is tried intraorally, and parts of the unpolished surface corresponding to the keepers are adjusted prior to the

incorporation of the magnets. After placing the magnets on the keepers, fit examining material is used to verify whether or not the magnets interfere with the unpolished surface (Fig 3). If any magnets contact the unpolished surface, interferences are ground repeatedly until they are completely eliminated.

After eliminating any interferences, the magnets are sandblasted and metal primer is applied to them. The magnets are then placed on the keepers, and an appropriate amount of self-curing acrylic resin is applied to the ground parts of the denture. The denture is placed back in the mouth, and the magnets are incorporated into the denture under occlusal pressure. After the resin sets completely, excessive resin is removed and the implant-supported overdenture is

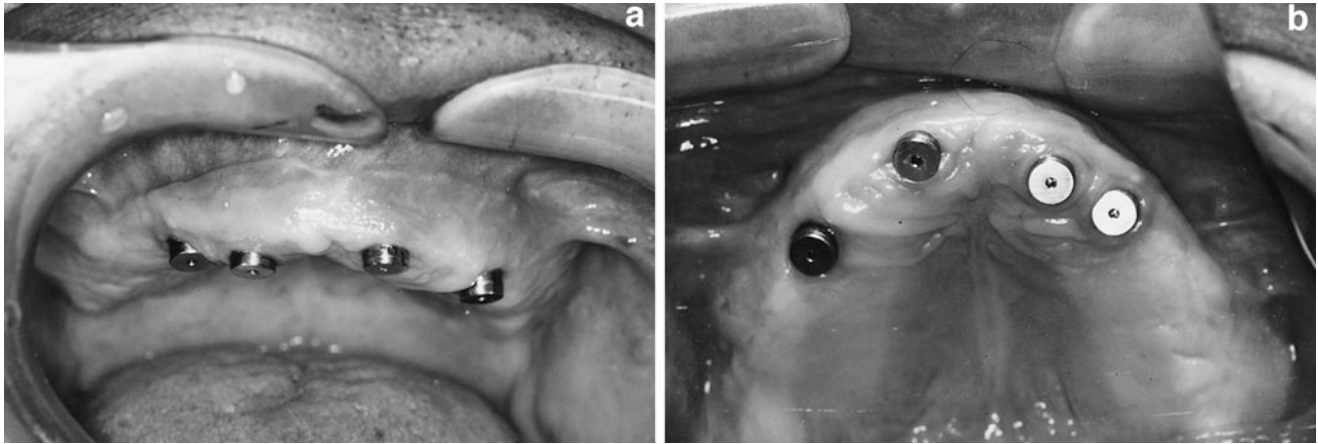


FIGURE 2. (a) Frontal view of the keeper in place. Abutment cylinders protruded 0.5–1.0 mm supragingivally. (b) Occlusal view.

completed (Fig 4). When incorporating more than one magnet at a time, however, care should be taken not to make it difficult to remove the overdenture if parallelism is lacking among the abutments.

Case presentation

A 71-year-old female had been wearing an implant-supported bridge extending from the maxillary right canine to the left canine for 8 years (Fig 5). However, the remaining maxillary teeth had been developing abscesses due to periodontitis, and an immediate complete denture was fabricated after extracting the remaining teeth (Fig 6). After extraction of the teeth, tissue conditioning was performed repeatedly until the morphology of the residual ridge became stable.

Although abutments were selected so that they would protrude 0.5–1.0 mm supragingivally, the most distal abutment on the right side protruded about 2 mm supragingivally because the implant had not been placed deep enough (Fig 7). Therefore, the part of the denture corresponding to this side of the abutment was relieved in order to alleviate excessive lateral stresses. After completion of the denture, magnets were placed on the keepers, and they were incorporated into the denture under occlusal pressure.



FIGURE 3. Interferences (arrows) have to be ground repeatedly until they are completely eliminated.

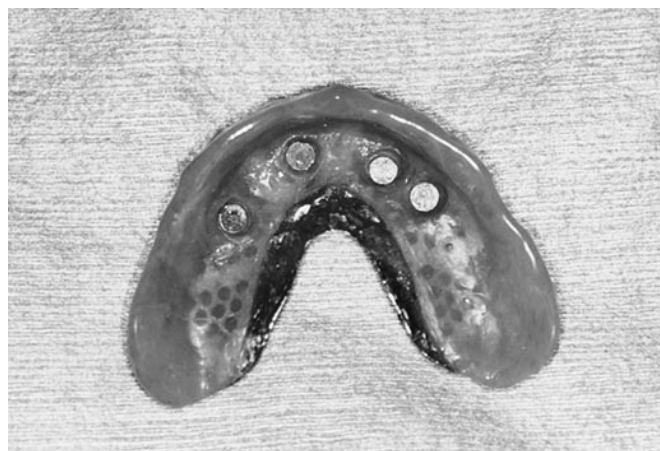

FIGURE 4. Unpolished surface of a maxillary overdenture showing four magnets embedded in the acrylic resin base.

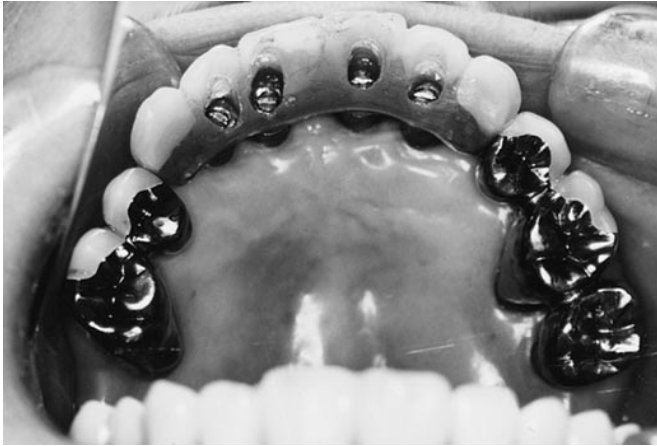

FIGURE 5. Occlusal view of previous prostheses before extraction of teeth.

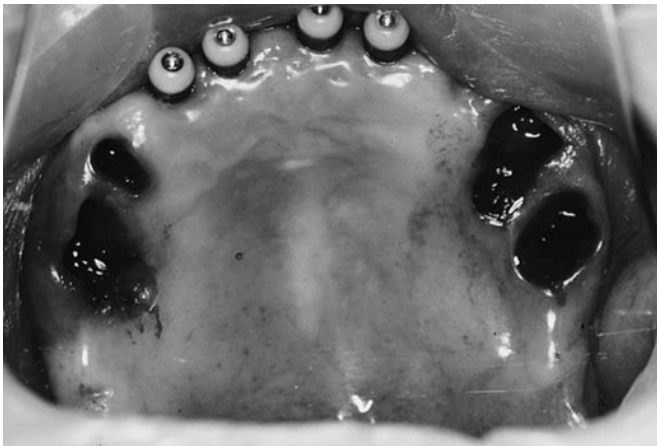


FIGURE 6. Occlusal view after extraction of teeth.

DISCUSSION

Implant-supported overdentures have the following advantages over fixed bridges: (1) they are more esthetic,¹ (2) they make it easier to maintain hygiene,^{1,13} (3) they are easier to handle in the laboratory and at chairside, (4) they reduced in cost,^{1,14} (5) they may be utilized together with attachments applied to remaining natural teeth, and (6) implants can be placed in anatomically optimal locations.¹⁵

Disadvantages include fracture of the denture around the attachment, fracture of the attachment itself,¹⁵ and inferiority in masticatory function.¹³

In addition to the advantages of implant-supported overdentures, there are other advantages with this mag-

netic attachment system as compared to bar attachments or ball attachments, which are as follows: (1) the frequency of problems such as bar fracture or clip fracture is low,¹⁶ (2) laboratory procedures associated with castings are not necessary, (3) replacement of O-rings when ball attachments are used is not necessary,¹⁷ (4) they may be applied to cases with reduced interarch distance, (5) lateral stresses to the implants are very low because attractive force is much lower horizontally,^{8,11,12,18} and (6) they allow for a rotational path of insertion, leading to the elimination of food traps.

Of the advantages pertinent to this magnetic attachment system, there are two that merit special mention. First, it

can be applied to cases with reduced occlusal vertical dimension, because the thickness of the magnet is 1.5 mm and the thickness of the keeper is 0.8 mm, making the total height of the assembled attachment 2.3 mm. The other advantage, which is common to all magnetic attachments, is that attractive forces are greatest vertically and very small horizontally.^{8,11,12,18} Therefore, detrimental lateral stresses to the implants are greatly diminished and a better prognosis may be expected in the long term.

Magnetic attachment systems have certain disadvantages. The attachment needs to be removed before taking magnetic resonance imaging because it causes streaking. It has been reported that when numbers of implants are relatively few, retention is not as good as when ball attachments are used.¹⁹ However, attractive force of magnets used in this particular study was very small because the average vertical retention force of the overdenture was about 479 g using two magnets. If our magnetic attachment system had been used in the same study, results would have been different.

Disadvantages of the magnetic attachment system using Hicoclex Super 4515® include possible loosening of the keeper and crevice corrosion at the keeper-abutment interface. For loosening of the keeper, careful observation and periodic inspection are necessary after installation of the attachment. Regarding crevice corrosion, it was greatly improved after nitrating the keeper. Further, as we continue to observe the cases treated with these magnetic attachments, we will be able to determine the proper timing for replacement of keepers. At present, however, neither corrosion of the magnetic attachment system nor tarnishing of the abutment cylinder has been observed 2 years after magnet placement.

In our cases, there were no implant failures 2 years after placement of magnetic attachments (30/30). As regards survival rate of implants in

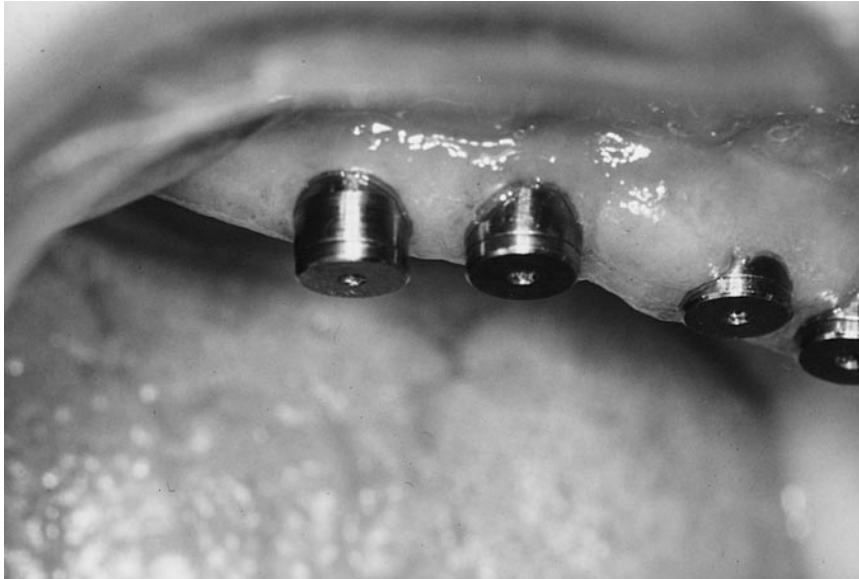

FIGURE 7. Lateral view of the keeper.

combination with magnetic attachments, good results were reported in the literature. Walmsley *et al*⁸ reported a 100% success rate (63/63) after placement of magnets with an average follow-up period of approximately 3 years. Additionally, as indicated in that article, use of longer implants, at least 10 mm, is recommended to expect predictability in the long term.

ACKNOWLEDGMENTS

The authors thank Mr Hirohide Yamada of Hitachi Metals, Ltd, and Mr Haruyuki Watanabe of Nagoya Rashi, Ltd, for their advice and help in making magnetic attachments. The authors also thank the following companies for their donations of magnets and custom-made keepers: Hitachi Metals, Ltd, Tokyo, Japan, and Nagoya Rashi, Ltd, Seki, Japan.

REFERENCES

1. Engquist B. Advanced osseointegration surgery: applications in the maxillofacial region. In: Worthington P, Brånemark P-I, eds. Chicago: Quintessence; 1992:233–247.
2. Naert I, Quirynen M, Theuniers G, van Steenberghe D. Prosthetic aspects of osseointegrated fixtures supporting overdentures. *J Prosthet Dent*. 1991;65:671–680.
3. Donatsky O. Osseointegrated dental implants with ball attachments supporting overdentures in patients with mandibular alveolar ridge atrophy. *Int J Oral Maxillofac Implants*. 1993; 8:162–166.
4. Jackson TR. New rare earth magnetic technology: the Jackson solid state attachment system. *Trends Tech Contemp Dent Lab*. 1986;3:31–39.
5. Carlyle LW, Duncan JM, Richardson JT, Garcia L. Magnetically retained implant denture. *J Prosthet Dent*. 1986; 56:583–586.
6. Mensor MC. Compliant keeper system for magnet- and screw-retained implant prosthodontics. *Int J Prosthodont*. 1988;1:201–207.
7. Davis DM, Watson RM. The use of two implant systems for providing implant supported overdentures in the mandible—a clinical appraisal. *Eur J Prosthodont Rest Dent*. 1993;2:67–71.
8. Walmsley AD, Brady CL, Smith PL, Frame JW. Magnet retained overdentures using the Astra dental implant system. *Br Dent J*. 1993;174:399–404.
9. Altay OT, Kutman T, Koseoglu O, Tanyeri. The biological effects of implanted magnetic fields on the bone tissue of dogs. *Int J Oral Maxillofac Implants*. 1991;6:345–349.
10. Camilleri S, McDonald F. Static magnetic field effects on the sagittal suture in *Rattus Norvegicus*. *Am J Orthod Dentofac Orthop*. 1993;103:240–246.
11. Jackson TR, Healey KW. Rare earth magnetic attachments: the state of the art in removable prosthodontics. *Quintessence Int*. 1987;18:41–51.
12. Jackson TR. The application of rare earth magnetic retention to osseointegrated implants. *Int J Oral Maxillofac Implants*. 1986;1:81–92.
13. Feine JS, de Granmont P, Boudrias P, *et al*. Within-subject comparisons of implant-supported mandibular prostheses: choice of prosthesis. *J Dent Res*. 1994;73:1105–1111.
14. Zarb GA, Janson T, Jemt T. Other prosthodontic applications. In: Brånemark P-I, Zarb GA, Albraktsson, eds. *Tissue-Integrated Prostheses: Osseointegration in Clinical Dentistry*. Chicago: Quintessence; 1985:283–293.
15. Naert I, De Clercq M, Theuniers G, Schepers E. Overdentures supported by osseointegrated fixtures for the edentulous mandible: a 2.5-year report. *Int J Oral Maxillofac Implants*. 1988;3: 191–196.
16. Jemt T, Linden B, Lekholm U. Failures and complications in 127 consecutively placed fixed partial prostheses supported by Brånemark implants: from prosthetic treatment to first annual checkup. *Int J Oral Maxillofac Implants*. 1992;7:40–44.
17. White GE. Overdentures. In: White GE, ed. *Osseointegrated Dental Technology*. London: Quintessence; 1993:153–168.
18. Gillings BRD. Magnetic retention for complete and partial overdentures. Part I. *J Prosthet Dent*. 1981;45: 484–491.
19. Burns DR, Unger JW, Elswick RK, Beck DA. Prospective clinical evaluation of mandibular implant overdentures: part I—retention, stability, and tissue response. *J Prosthet Dent*. 1995; 73:354–363. ■