

IMMEDIATE LOADING OF A SINGLE HYDROXYAPATITE-COATED THREADED ROOT FORM IMPLANT: A CLINICAL REPORT

André Gomes, DDS
Jaime L. Lozada, DDS
Nicholas Caplanis, DMD, MS
Alejandro Kleinman, DDS

KEY WORDS

Immediate loading
Single tooth implant
Hydroxyapatite-coated implant
Laboratory technique

The successful results of endosseous root form implants in the treatment of partially and completely edentulous patients has been made possible by the application of standardized surgical and prosthetic protocols. Different techniques have been published in the literature with the purpose of reducing implant prosthetic rehabilitation times. This clinical case report describes a new surgical concept and a technique to fabricate screw-retained provisional crowns for immediate loading of free-standing single tooth implants. Further clinical and histologic studies are necessary in order to promote routine clinical application of this technique.

INTRODUCTION

Endosseous root form implants have been shown to be highly successful for the reconstruction of partially as well as completely edentulous patients.¹⁻³ These results have been made possible through the application of standardized surgical and prosthetic protocols. However, one major disadvantage of these surgical protocols is the necessary healing period between implant placement and restoration. This healing period is often psychologically and socially unacceptable for many patients.⁴

Recently, various attempts have been made to reduce healing times through immediate implant loading by utilizing provisional implant techniques and designing implants with mechanical characteristics that theoretically hasten the healing process.⁵ These experiences have exclusively utilized several splinted implants through bar structures^{6,7}

and fixed provisional prostheses.^{8,9} The success of these techniques seems to be dependent on the ability to control implant micromotion through splinting during the healing period.

Recently, human histologic evidence of two clinically successful, immediately loaded, free-standing titanium plasma-sprayed implants was reported. These implants were immediately loaded for 8 and 9 months and were retrieved because of abutment fracture and psychological concerns, respectively. The microscopic evaluation revealed physiologically mature bone around both implants, with an approximate bone-to-implant contact of 60 to 70%.¹⁰

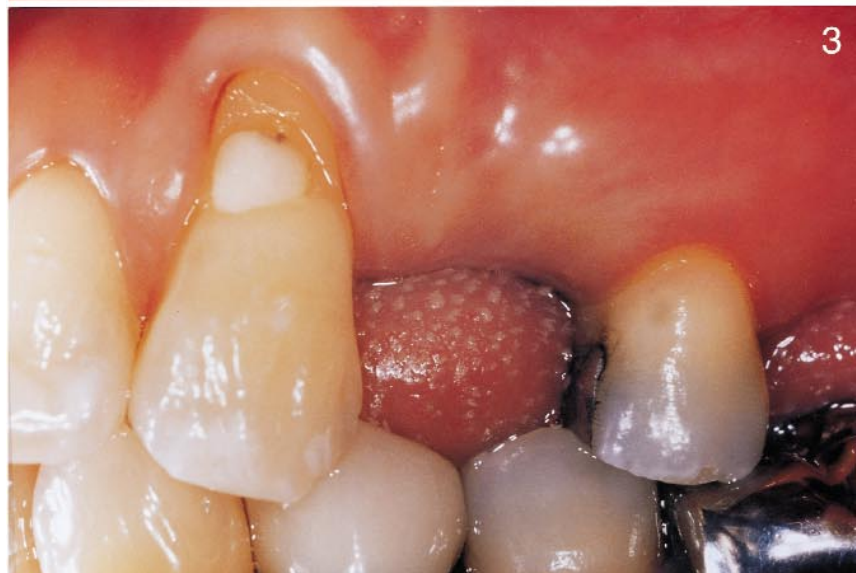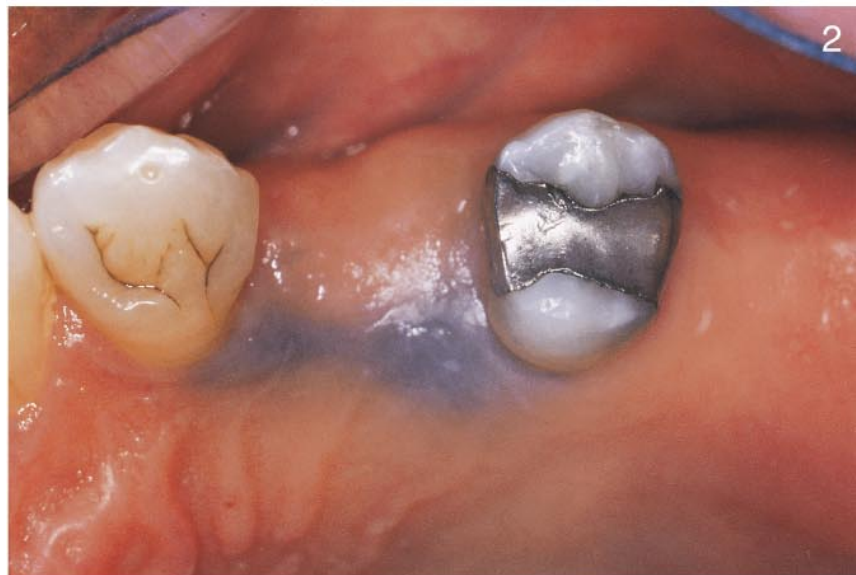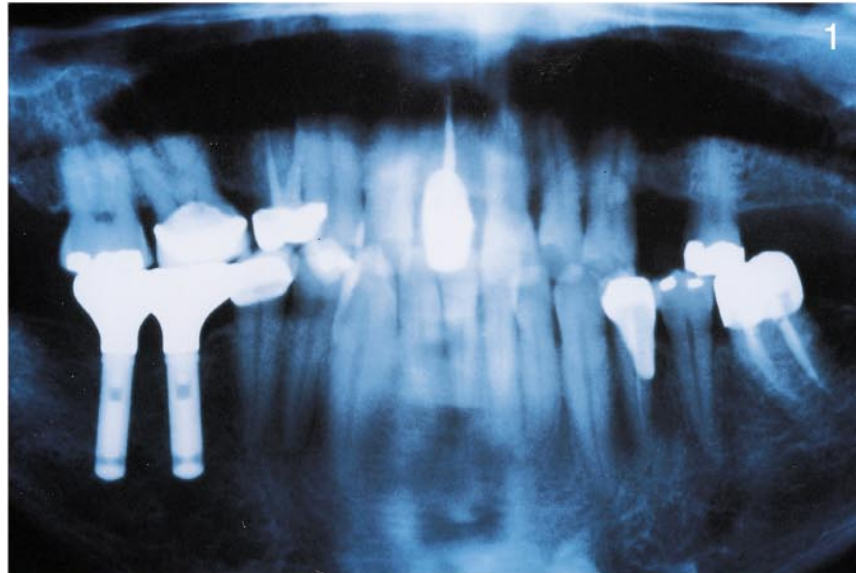
These findings are exciting, given that these implants were single-tooth replacements and nonsplinted during the healing phase. This suggests prudent deviation from established surgical protocol is possible without compromising osseointegration. The pur-

All the authors are affiliated with the Advanced Education Program in Implant Dentistry, Loma Linda University School of Dentistry, Loma Linda, Calif. André Gomes, DDS, is a resident; Jaime L. Lozada, DDS, is the Program's director; Nicholas Caplanis, DMD, MS, is an assistant professor; and Alejandro Kleinman, DDS, is an assistant professor.

pose of this single clinical case report is to present a new surgical concept and a technique to fabricate screw-retained provisional crowns for immediate loading of free-standing single tooth implants.

CASE REPORT

On January 27, 1998, a 46-year-old African American male reported to the Loma Linda University Center for Prosthodontics and Implant Dentistry, Loma Linda, Calif, for the replacement of a missing maxillary left first bicuspid tooth. In 1992, the patient had been successfully rehabilitated with two endosseous root form implants placed in the mandibular first and second right molar region. His desire was to replace the missing maxillary left first bicuspid with an implant. The tooth had been previously treated endodontically, including a retrograde amalgam filling and reconstructed with a post, core, and metal-ceramic crown. In January 1995, the tooth was extracted because of deep recurrent decay. The patient wished to expedite treatment because of aesthetic concerns and was not receptive to removable provisionalization. The patient's medical history was unremarkable. The patient had no known drug allergies. Dental examination revealed a partially edentulous maxilla and mandible (missing teeth 1, 4, 12, 14-18, 32) (Fig 1). Generalized tooth malpositions, gingival recessions, and previous restorative treatment were noted as well. The most posterior dental contact on the patient's left side exclusively involved teeth 13 and 19. However, the patient had no functional or physiologic complaints. Bilateral canine guidance without lateral interferences was noted during the occlusal examination. The periodontal examination revealed stable



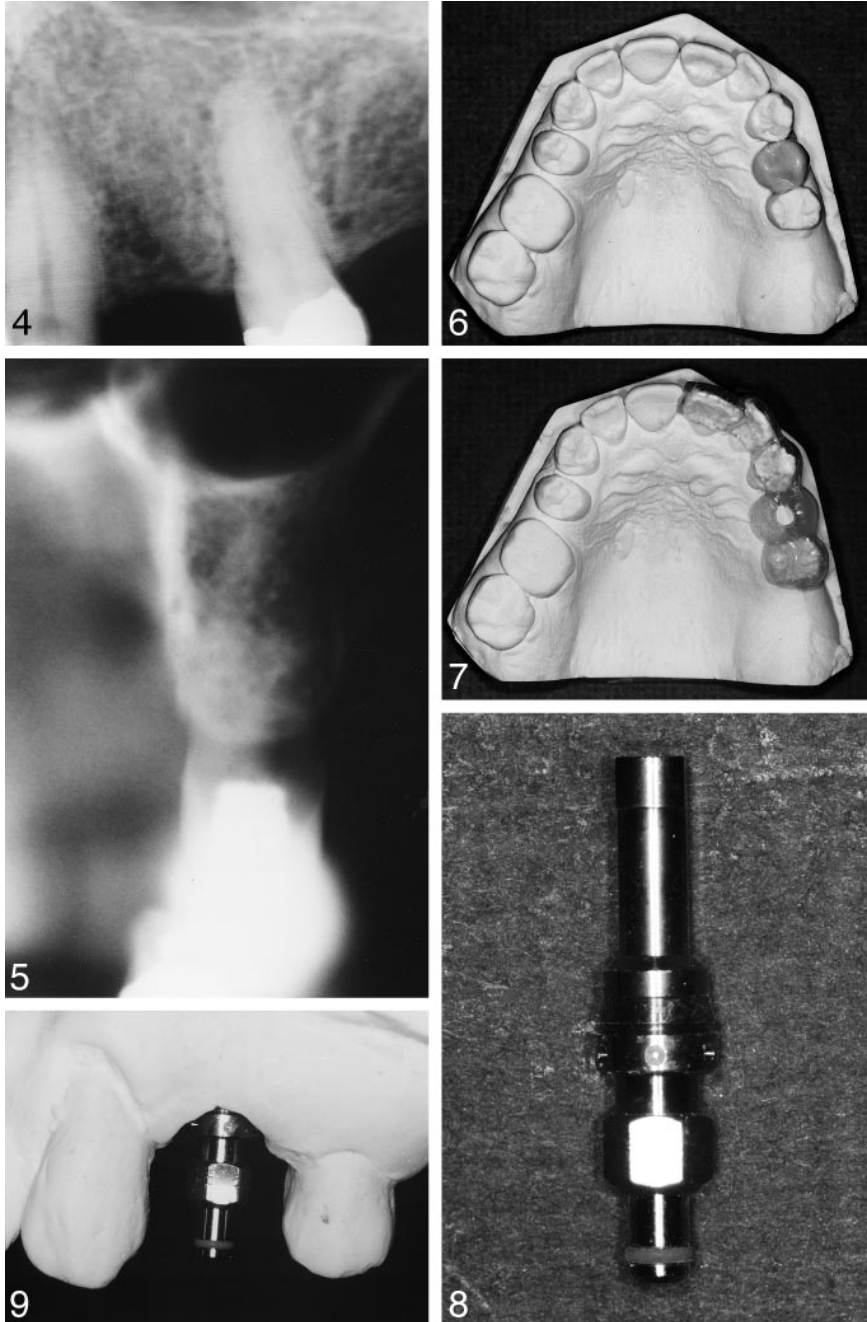
FIGURES 1-3. FIGURE 1. Radiograph reveals a partially edentulous maxilla and mandible (missing teeth 1, 4, 12, 14-18, and 32). FIGURES 2, 3. Area of missing tooth 12. The gingival tissues are well keratinized and the dimensions satisfactory for implantation.

periodontal condition, with isolated areas of gingivitis. The patient appeared to have acceptable oral hygiene. Radiographic examination using periapical, panoramic, and linear tomographic radiographs confirmed adequate bone quantity at the proposed implant site for the placement of an endosseous root form implant. Approximately 16 mm of apico-coronal and 10 mm of bucco-lingual bone was available for implantation (Figs 2–5). After discussing several treatment options and associated risks and benefits, the patient elected to have a single root form implant with an immediate provisional crown placed at the time of the surgery. He also accepted treatment for correction of a gingival recession on the facial aspect of the maxillary left canine tooth and a metal ceramic crown to restore the maxillary left second bicuspid.

The provisional implant-supported crown was prefabricated in the laboratory before surgery in order to minimize implant trauma following implant placement. The implant used in this case was a Replace hydroxyapatite (HA)-coated 4.3 × 16-mm tapered root analog implant (Steri-Oss, Yorba Linda, Calif).

Presurgical procedures

Maxillary and mandibular alginate impressions were obtained and models fabricated using type V dental stone. Casts were mounted on a semiaadjustable articulator. A diagnostic wax-up replacing tooth 12 was created (Fig 6). The wax-up was duplicated and a vacuum-form radiographic template was fabricated. Guttapercha was used through the template over the proposed implant site as a radiographic marker (Fig 7). The template was placed in the patient's mouth and periapical and linear tomographic radiographs were obtained to assess the future implant trajectory (Fig 5). The patient was anesthetized and bone sounding was performed over the proposed implant site to determine soft-tissue thickness; this thickness measured 3 mm.

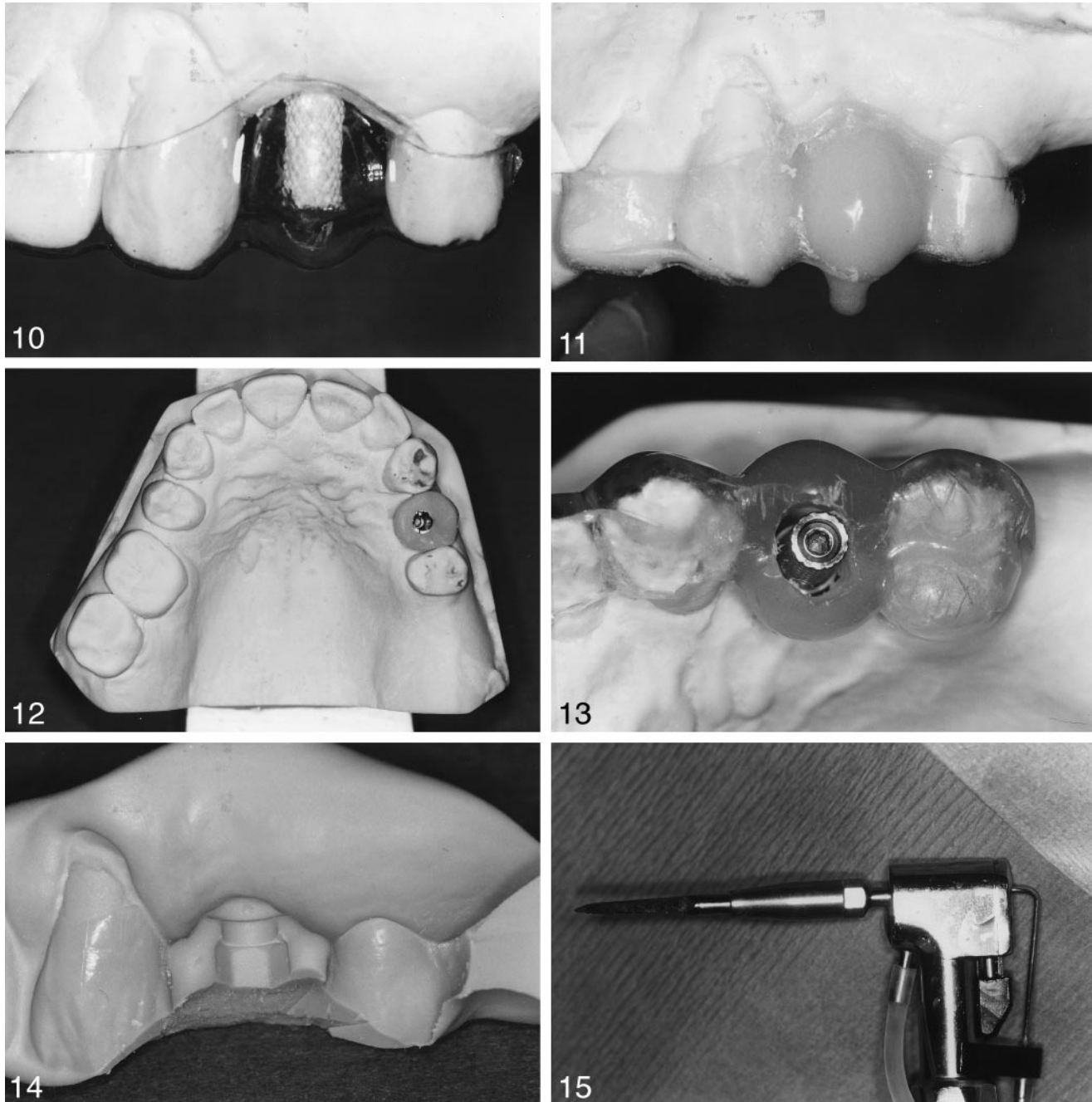


FIGURES 4–9. FIGURES 4, 5. Periapical and linear tomographic radiographs confirm the existence of an adequate amount of bone at the proposed implant site. FIGURE 6. A diagnostic wax-up of tooth 12. FIGURE 7. Guttapercha was used through the template over the proposed implant site as a radiographic marker. FIGURE 8. Implant mount and implant analog. FIGURE 9. The implant analog fixed in position using type IV dental stone.

A 4.3-mm-diameter implant mount and an implant analog (Replace, Steri-Oss) were assembled and used to simulate the surgery on the working cast in the laboratory using the radiographic template devoid of guttapercha for guidance (Fig 8). The decision to place the

implant platform exactly 1 mm below the bony crest was arbitrarily made in order to keep the aesthetic emergence profile in mind. This translated to a 4-mm distance from the tissue surface.

The distance between the apex and the platform of the implant analog was



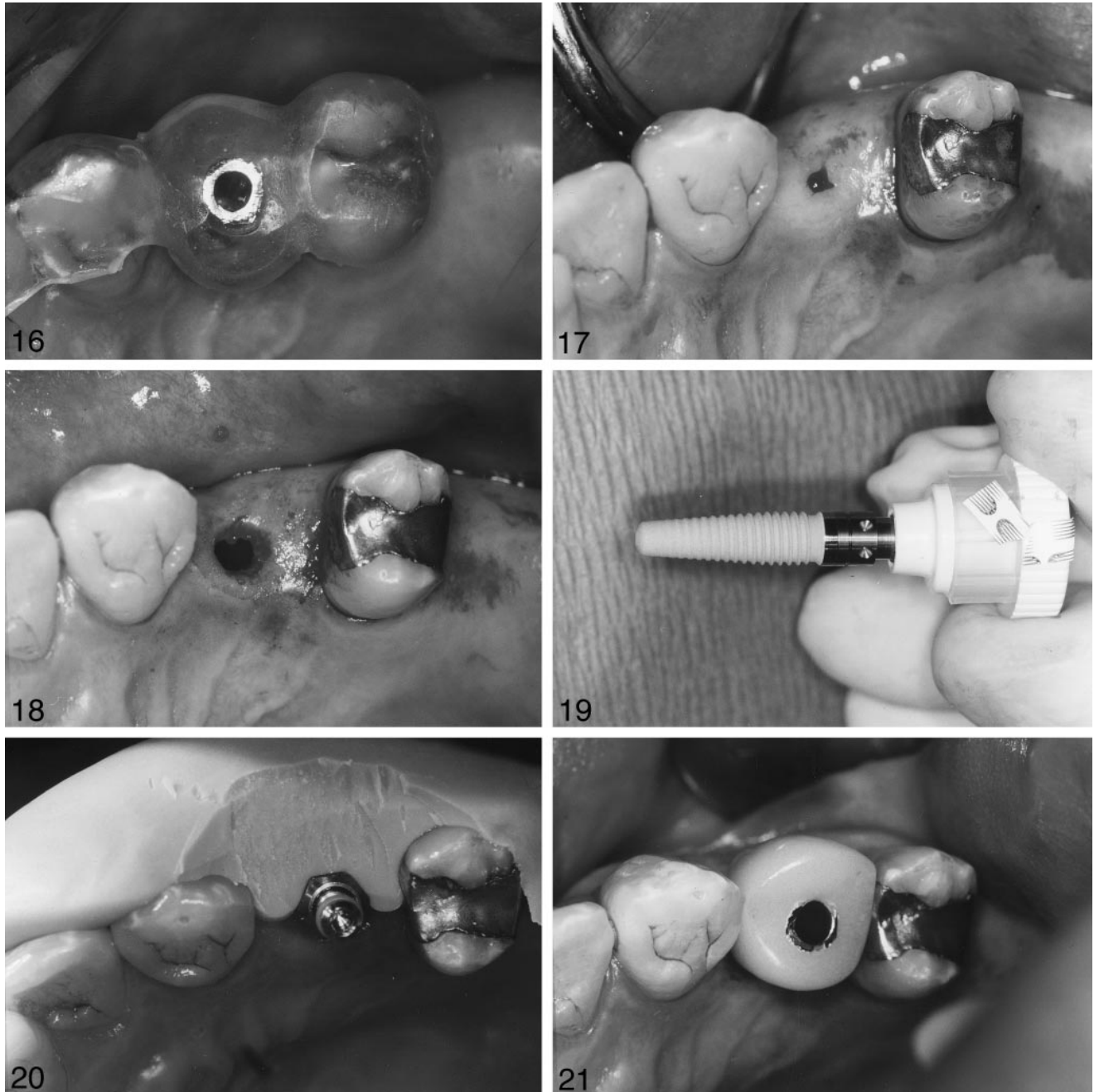
FIGURES 10–15. FIGURES 10, 11. Creation of a direct acrylic provisional on the 4.3-mm-diameter hexed metallic provisional abutment. FIGURE 12. The adjusted and finalized occlusion. FIGURE 13. The radiographic template was transformed into a surgical template. FIGURE 14. Silicone laboratory putty was used to index the position of the implant mount to the neighboring teeth. FIGURE 15. Plate cutter drill (H219-21-023, Brasseler, Savannah, Ga).

measured to be 9 mm. As previously measured, 4 mm accommodated the hard- and soft-tissue measurements (3 mm soft-tissue thickness, 1 mm countersinking). Thus, 13 mm was the working length necessary to place the implant analog within the stone cast.

Drilling followed in order to position the implant analog into the stone cast with the platform located exactly 4 mm from the tissue surface. This distance was confirmed using a North Carolina periodontal probe. The implant analog was then fixed in position using type

IV dental stone, taking great care to position the implant mount dimple that corresponded to the flat surface of the implant hex toward the buccal (Fig 9).

A 4.3-mm-diameter hexed metallic provisional abutment was opaqued and screwed onto the implant analog. A



FIGURES 16–21. FIGURES 16, 17. The drill initiated the drilling sequence, passing through both soft and hard tissues. The surgical template was used as a guide. FIGURE 18. The final osteotomy, with a depth of 20 mm. FIGURE 19. A 4.3 × 16-mm hydroxyapatite-coated Replace implant (Steri-Oss). FIGURE 20. The silicone putty index was used to match the angles of the mount marks for final implant positioning. FIGURE 21. The screw-retained provisional implant crown.

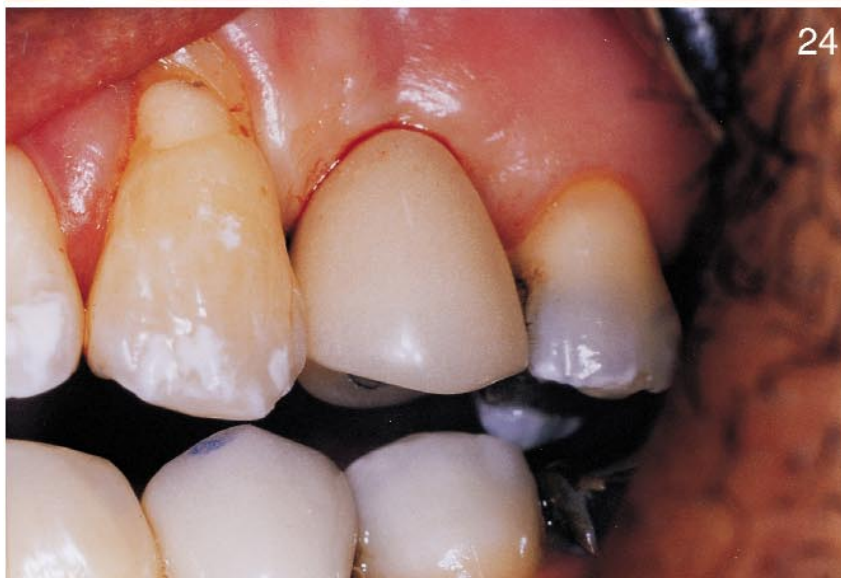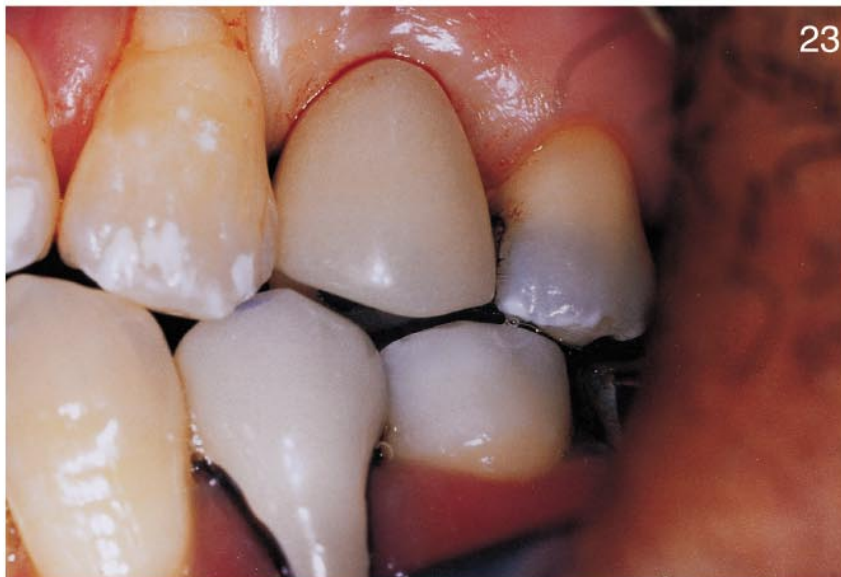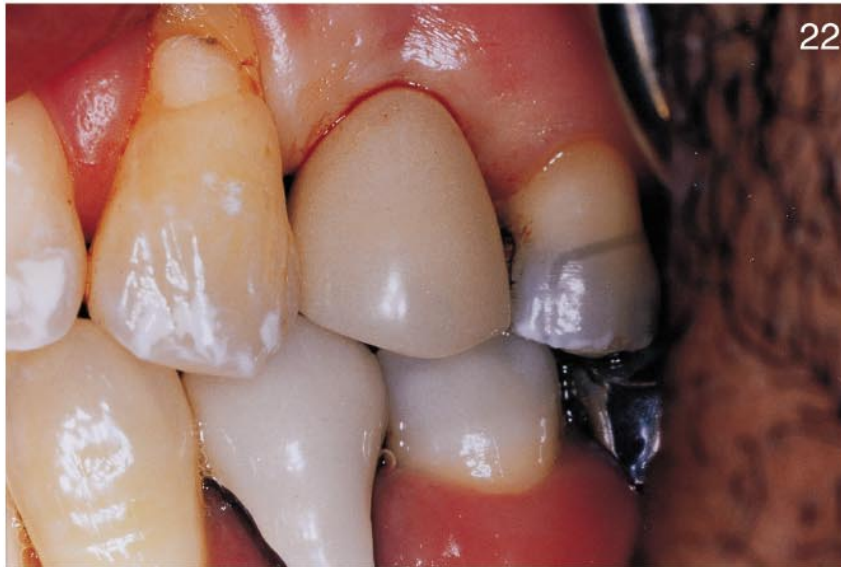0.020-inch clear-vacuum-formed stent fabricated from the previously constructed diagnostic wax-up cast was positioned on the cast, and a direct acrylic provisional was created (Figs 10, 11).

The occlusion was adjusted and finalized on the semiadjustable articulator, establishing no contacts in centric

relation, intercuspal position, and clearance in lateral and protrusive excursions (Fig 12). The radiographic template was transformed into a surgical template by screwing another hexed metallic temporary abutment onto the implant analog, relieving the radiographic template through the ac-

cess hole, and luting the temporary metallic abutment to the template with cold-cure acrylic (Fig 13).

The implant mount was screwed onto the implant analog on the cast and silicone laboratory putty was used to index the position of the implant mount to the neighboring teeth (Fig 14).



Surgical procedures

The patient was given 500 mg amoxicillin qid 1 day before the surgery. The surgical procedure was performed in the operating room under sterile conditions using routine local infiltrative anesthesia (Polocaine 2%, Astra, Westborough, Mass).

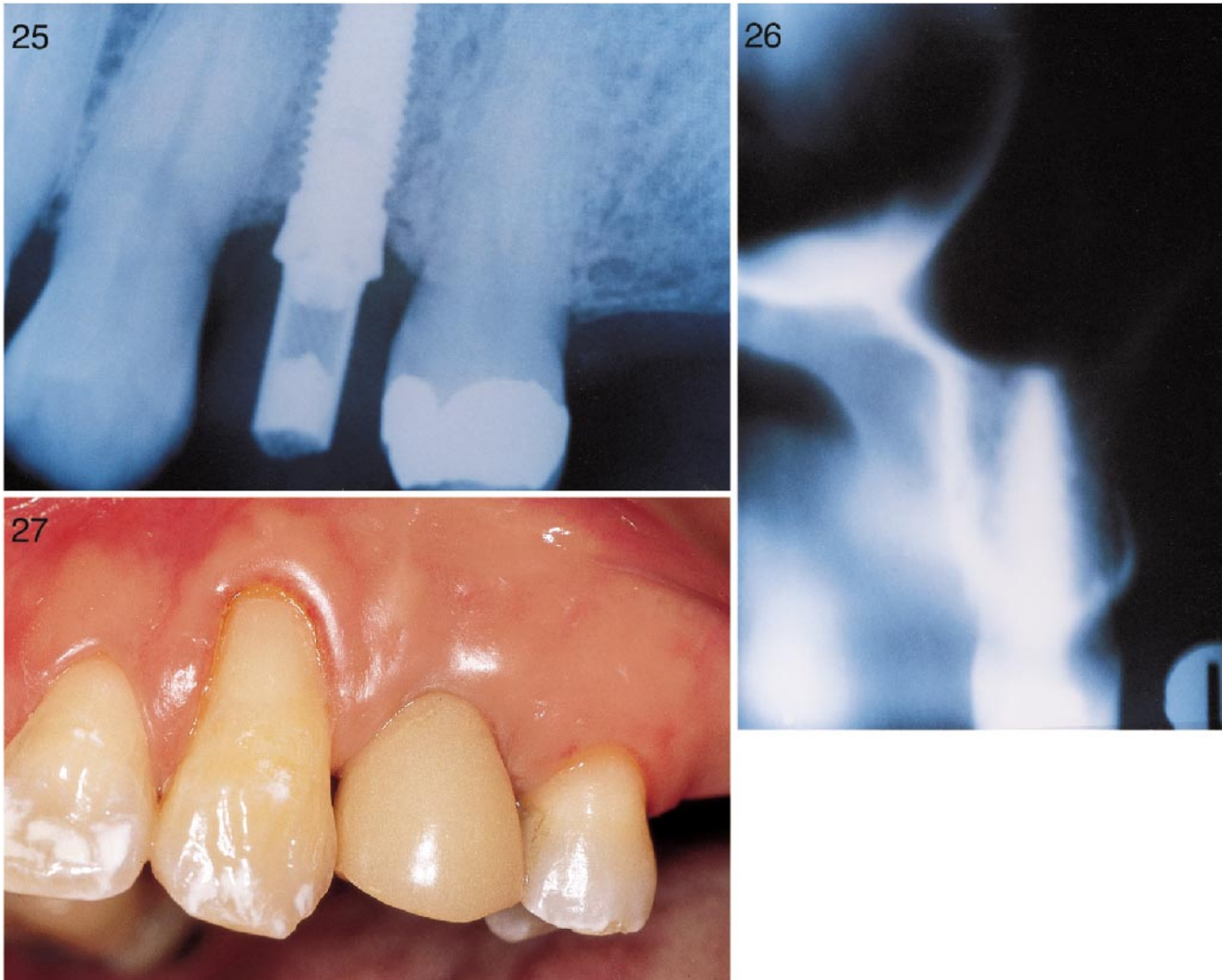
No incision or mucoperiosteal flap elevation was performed because of the excellent bone volume. A plate cutter drill (H219-21-023, Brasseler, Savannah, Ga) initiated the drilling sequence, passing through both soft and hard tissues. The surgical template was used as a guide (Figs 15–17).

Following the manufacturer's guidelines, the final osteotomy was created using internal and external sterile saline irrigation. Again, the surgical template was used as a guide. The final depth achieved was 20 mm (16-mm implant length, 3-mm soft tissue thickness, 1 mm countersink) (Fig 18).

The apical 2 mm of the osteotomy was self-tapped by the implant, achieving a maximum depth of 20 mm from the tissue crest. A 4.3 × 16-mm HA-coated Replace implant (Steri-Oss) was self-tapped manually into the osteotomy site until initial resistance was met; then a contra-angle slow speed hand-piece was used (Fig 19).

The silicone putty index was positioned intraorally, and a hand ratchet was used to match the angles of the implant mount to the marks in the silicone index to achieve the final position of the implant (Fig 20). The implant mount was removed, and the screw-retained provisional implant crown was fixed onto the implant (Fig 21). Proximal contact points were evaluated and occlusion was verified. Because of excellent presurgical diagnostics, adjustments were unnecessary (Figs 22–24). Digital periapical radiographs were obtained to verify proper implant po-

←
FIGURES 22–24. Evaluation of contact points and occlusion verified that adjustments were unnecessary.



FIGURES 25–27. FIGURE 25. Digital periapical radiograph verified proper alignment and seating of the restoration. FIGURE 26. Linear tomography showing approximation to the floor of the maxillary sinus adjacent to the implant's apex. FIGURE 27. After 6 months of treatment, the patient has had no complications and final restorative procedures have been rendered.

sition and seating of the provisional restoration (Fig 25).

Periotest (Siemens) value (+1) was obtained to confirm the lack of implant mobility. Final panoramic, periapical, and linear tomographic radiographs were obtained postoperatively for the purposes of documentation (Fig 26). Two weeks after surgery, the hard- and soft-tissue evaluation adjacent to the provisional implant restoration was completely normal. After 4 months of treatment, the screw-retained provisional crown was removed, an implant mount was placed, and a Periotest value of -2 was obtained. The patient had no complications after 6 months of

treatment. Final restorative procedures have been rendered (Fig 27).

DISCUSSION

One of the original prerequisites for osseointegration mandated a submerged, stress-free environment during the healing period.¹¹ This prerequisite has been challenged through the excellent success rates of one-stage nonsubmerged implant systems.³ It is believed that micromotion can disturb the early remodeling phase during implant healing.¹² Cameron¹³ concluded that the growth of bone onto a porous surface will occur in the presence of micromovement but not of macromovement.

Dental implant manufacturing has been recently characterized by the development of a variety of implant surfaces so that specific implants can be used according to the specifics of each clinical situation. It has been reported that HA-coated implants achieve faster and proportionally greater bone-implant contact than uncoated implants.¹⁴ In a nonhuman primate study, immediately loaded HA-coated blade implants splinted to natural teeth achieved osseointegration in comparison with a fibrous union achieved by titanium blades.¹⁵ An animal study of dogs reported that continuous loading of initially unstable titanium implants

resulted in the development of a permanent fibrous encapsulation after 16 weeks, whereas HA-coated implants had the capacity to replace the motion-induced fibrous tissue with bone. These implants were placed into the canine medial femoral condyles and subjected to micromovement of 150 μm .¹⁶

Criteria for using immediately loaded implants have been proposed by Salama *et al*⁴ to be as follows: bone quality (mandible versus maxilla); macrointerlock properties of the implant (threaded designs); microinterlock properties of the implant (surface coatings); bicortical initial stabilization; optimal distribution of implants; and careful use of cantilevers.

In this limited case report, our patient presented ideal conditions in terms of quantity of bone available for a root form implant. The implant selected had optimum macrointerlock properties (screw) and microinterlock properties (HA coating) that may be beneficial in these situations. In addition, the implant was self-tapped into position, the countersink drilling was eliminated, and fixation was achieved by approximating to the floor of the maxillary sinus with the implant apex. In this clinical situation, splinting of the implant restoration to adjacent teeth was not attempted. Therefore, the provisional implant restoration was completely free of centric and lateral occlusal contacts.

In addition to expediting treatment and eliminating a second surgical procedure, another advantage of this immediate implant single-tooth technique might be the preservation of both soft and hard tissues. Surgical violation of the interproximal papillae and the reflection of mucoperiosteal flaps was avoided, thereby maintaining crestal blood supply and eliminating interproximal tissue shrinkage and retraction. A prefabricated screw-retained restoration was used to maintain restoration retrievability and to minimize trauma to the implant. A provisional cement-retained restoration may be substituted in this technique. However,

great care must be exercised during the clinical relining process to minimize implant trauma.

In conclusion, this limited clinical case study reports for the first time the successful applicability of an immediately loaded implant-supported single-tooth replacement and an innovative laboratory technique for fabricating an immediate provisional implant restoration. However, we must stress the limited information gained from uncontrolled case studies such as this one. The conventional osseointegration protocol has demonstrated excellent predictability and success for over 15 years. The delayed healing protocol must still be considered the treatment of choice when using endosseous root form dental implants. However, as reported, we must recognize that many patients can benefit from modifications of the currently accepted protocols. Further clinical as well as histologic studies are necessary in order to promote routine clinical application of this technique.

REFERENCES

1. Branemark P, Hansson BO, Adell R, *et al*. Osseointegrated implants in the treatment of the edentulous jaw: experience from a 10-year period. *Scand J Plast Surg* 1977;2 (suppl 16):1-132.
2. Adell R, Ericksson B, Lekholm U. A long-term follow-up study of osseointegrated implants in the treatment of totally edentulous jaws. *Int J Oral Maxillofac Implants* 1990;5:347-359.
3. Buser D, Mericske Stern R, Bernard JP, *et al*. Long-term evaluation of non-submerged ITI implants, part 1: Eight-year life table analysis of a prospective multi-center study with 2359 implants. *Clin Oral Implant Res* 1997;8:161-172.
4. Salama H, Rose L, Salama M, Betts N. Immediate loading of bilaterally splinted titanium root-form implants in fixed prosthodontics. A technique reexamined: two case reports. *Int J Periodont Restor Dent* 1995;15:345-361.
5. Lozada J, Rungcharassaeng K, Kan J. Immediately loaded Steri-Oss implants: can evidence support change in protocol? *Int J Dent Symp* 1997;4:36-41.
6. Babbush CA, Kent JN, Misiak DJ. Titanium plasma-sprayed screw implant system for the reconstruction of the edentulous mandible. *J Oral Maxillofac Surg* 1986;44:274-282.
7. Lefkove MD, Beals RP. Immediate loading of cylinder implants with overdentures in the mandibular symphysis: the titanium plasma-sprayed technique. *J Oral Implantol* 1990;16:265-271.
8. Schnitman PA, Wöhrle PS, Rubenstein JE. Immediate fixed interim prostheses supported by two-stage threaded implants: methodology and results. *J Oral Implantol* 1990;16:96-105.
9. Tarnow DP, Entiaz S, Classi A. Immediate loading of threaded implants at stage 1 surgery in edentulous arches: ten consecutive case reports with 1- to 5-year data. *Int J Oral Maxillofac Implants* 1997;12:319-324.
10. Piatelli A, Paolantonio M, Corigliano M, Scarano A. Immediate loading of titanium plasma-sprayed, screw-shaped implants in man: a clinical and histological report of two cases. *J Periodontol* 1997;68:591-597.
11. Adell R, Lekholm U, Rockler B, Branemark P. A 15-year study of osseointegrated implants in the treatment of edentulous patients. *Int J Oral Surg* 1981;10:387-415.
12. Brunski JB. Biomechanical factors affecting the bone-dental implant interface: review paper. *Clin Mater* 1992;10:153-201.
13. Cameron HU. The effect of movement on the bonding of porous metal on bone. *J Biomed Mater Res* 1973;7:301-311.
14. Lozada J. Eight-year clinical evaluation of HA-coated implants. *J Dent Symp* 1993;1:67-69.
15. Lum LB, Beirne OR, Curtis DA. Histologic evaluation of Hydroxylapatite-coated versus uncoated titanium blade implants in delayed and immediately loaded applications. *Int J Oral Maxillofac Implants* 1991;6:456-462.
16. Soballe K, Hansen E, Brackstedt-Rasmussen H, Bunger C. Hydroxyapatite coating converts fibrous tissue to bone around loaded implants. *J Bone Joint Surg BR* 1993;75B:270-278.