

# CRITICAL DESIGN ERRORS IN MAXILLARY SUBPERIOSTEAL IMPLANTS

Leonard I. Linkow, DDS, DMSc  
Robert Ghalili, DMD

## KEY WORDS

Palatal fenestrated straps  
Mesobar  
O-ring projections  
Internal clips  
Equilibrium triad  
Maxillary subperiosteal implant

A maxillary full arch subperiosteal implant consists of a metallic framework that rests closely on the atrophied residual ridge beneath the mucoperiosteum and offers support for a dental prosthesis by means of posts or bars with O-ring protrusions or internal clip attachments. The maxillary subperiosteal implant is indicated for those patients presenting with advanced atrophy of the maxilla leaving the patient with three existing stable dense bony areas (the anterior nasal spine, the canine eminences, and the palatal surface of the existing crest) for its support. Over 300 cases with up to 12 years in function are presented. The importance of the basic anatomic and physiologic background required to optimize results are emphasized. The first 600+ subperiosteal implant cases that were placed prior to 1985 showed considerably lower success rates.

## INTRODUCTION

With the great strides made in endosteal root-form implants over the past 15 years, the value of subperiosteal implants have been minimized. Dahl,<sup>1</sup> Gershkoff and Goldberg,<sup>2,3</sup> Marziani,<sup>4-6</sup> Lew and colleagues,<sup>7-9</sup> Berman,<sup>10</sup> Bodine and colleagues,<sup>11,12</sup> Linkow and Chercheve,<sup>13,14</sup> Linkow,<sup>15,16</sup> Cranin,<sup>17-19</sup> James,<sup>20</sup> Judy and Weiss,<sup>21,22</sup> Linkow and Mangini,<sup>23</sup> Boyne,<sup>24</sup> and Benoit and colleagues<sup>25</sup> have made valuable past contributions to the technique, however.

A problem that has confronted many clinicians who have been using the maxillary subperiosteal implant is concerned with considerations of design. Subperiosteal implants, when designed properly, can be inserted and successfully remain in function for significant periods of time.<sup>23,26</sup> Immacu-

late, atraumatic surgery must be performed, followed by an impeccable impression of the osseous structures. The accuracy of the master stone cast and the articulation of both jaws greatly influences long-term results. Expert occlusal equilibration of the implant-borne overdenture further leads to a satisfactory prognosis.

Anatomic landmarks of the maxilla of concern to clinicians are the palatal surface of the maxillary crest, anterior nasal spine, canine eminence, zygomatic arch, malar prominence, hamular notch, maxillary sinus, nasal vestibulum, and the labial and buccal concavities.

## THE SUBPERIOSTEAL IMPLANT

Designing a subperiosteal implant—one that rests on dense cortical bone rather than on cancellous alveolar

Leonard I. Linkow, DDS, is a clinical professor in the Department of Implant Dentistry at NYU College of Dentistry, New York, N.Y. He is also a clinical professor in the Department of Fixed Prosthodontics at the University of Pittsburgh, School of Dental Medicine, Pittsburgh, Penn. Dr. Linkow may be contacted at 18 East 50th Street, New York, N.Y. 10022. Robert Ghalili, DMD, is an assistant professor in the Department of Periodontics at the University of Medicine and Dentistry of New Jersey, Newark, N.J.

bone—is more difficult to achieve in the maxillary arch than in the mandibular arch. The primary reason for this is morphology. The maxillary subperiosteal implant must meet the same basic criteria as the mandibular implant if it is to be successful. These criteria are as follows:

- (1) A subperiosteal implant must always be seated on the densest cortical bone available. After tooth loss, the occlusal surface of the posterior maxillary quadrant is almost always characterized by exposed cancellous bone. Although the bone flanking the sinus is compact, it is typically eggshell-thin when the sinus is large. Posteriorly, the hamular notch area and the palatal side of the alveolar crest are composed of dense compact bone that survives satisfactorily under surface pressure. Bone is suitable for supporting a subperiosteal implant between the canine pillars both palatally and labially up to the anterior nasal spine.
- (2) The subperiosteal implant must be designed on a stone model made from a direct bone impression or from a cast derived from a CT scan (Fig 1). All areas that will support the implant must be exposed for the impression by incising their overlying soft tissues and aggressively retracting them (Fig 2).
- (3) The struts of a subperiosteal implant must wrap around or rest against distinct anatomic features for adequate bracing against lateral forces. These structures are (a) the palatal surface of the ridge crest, (b) the anterior nasal spine, (c) the canine pillars or eminences, and (d) the posterior buccal surface of the maxilla (mostly for more added immediate retention of the implant) (Figs 3–10).
- (4) A subperiosteal implant must be placed only in those areas in which the overlying tissues are firmly attached to bone. Tight resealing of the tissues to bone is essential to

bind the implant to the site (Figs 11–13).

- (5) The implant must be lightweight. Economy in design is essential. The larger and heavier the implant, the more it is affected by gravity—a particularly important consideration in maxillae (Fig 14).
- (6) The struts should either be narrow (2 mm width but not narrower) or fenestrated (3–10 mm in width and 0.5 mm thick) to minimally interrupt living tissues and permit short connective tissue strands to extend directly from the mucoperiosteum to the bone. Narrowness and fenestration also lighten the implant (Fig 15).

Endosteal and subperiosteal implants may be combined in many ways. A successful fixed prosthesis must be anchored firmly anteriorly and posteriorly on both sides of the arch. The anchoring device matters less than its ability to withstand vertical and lateral forces. The ability derives from the implant's appropriateness to the site. Thus, it is not unusual, particularly in the maxillae, to see endosteal bladevent or root-form implants combined to be used with prepared natural teeth.<sup>23,27–29</sup>

#### PHYSIOLOGY OF THE MAXILLAE AFTER TOOTH EXTRACTIONS

After maxillary teeth are extracted, certain phenomena occur, including the following:

- (1) Posteriorly, the maxillary sinus drops inferiorly and pneumatizes laterally, while concomitantly the alveolar bone directly below and lateral to the antrum resorbs, thereby creating thicknesses of 1 mm or less and often a large buccal undercut.
- (2) The sinus is also seen to migrate distally to obliterate a substantial portion of the maxillary tuberosity.
- (3) Anteriorly, the labial surface of the bone resorbs inward, leaving the anterior nasal spine and the canine eminences intact.
- (4) A totally edentulous maxilla, after

a period of time, resorbs inward toward the center of the hard palate, but in cross-section, it often leaves buccal and labial undercuts.

- (5) The maxillary sinus rarely invades the palatal side of the ridge crest.

#### AVOIDANCE OF PROBLEMS

Posterior buccal surfaces of the maxillae should not be burdened by excessive numbers of struts. The greatest degree of resorption beneath maxillary subperiosteal implants is at the sites of both posterior buccal plates of bone. By overloading these labile areas, a large percentage of cases will be caused to fail. If problems arise in posterior maxillae, a plethora of struts create significant problems in their removal or revision.

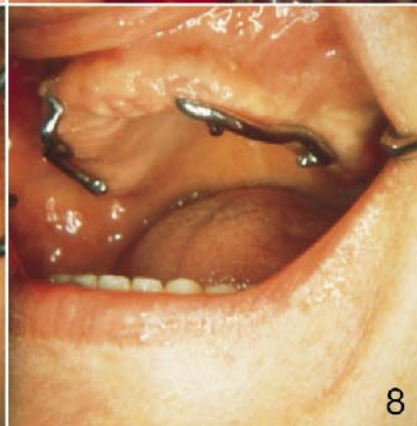
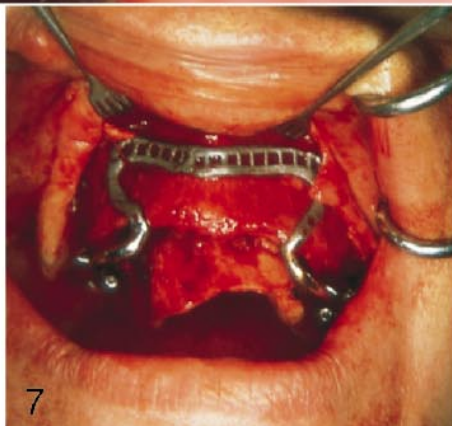
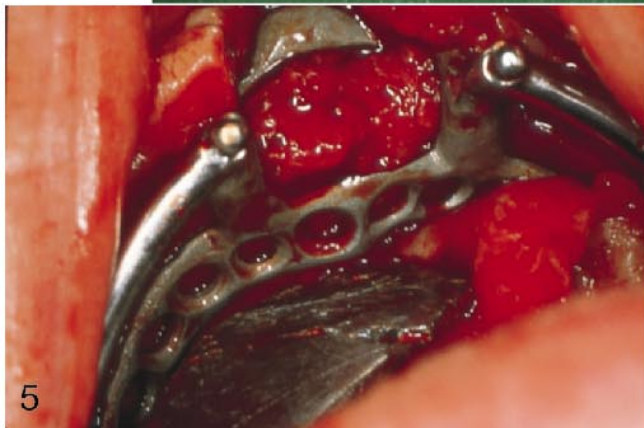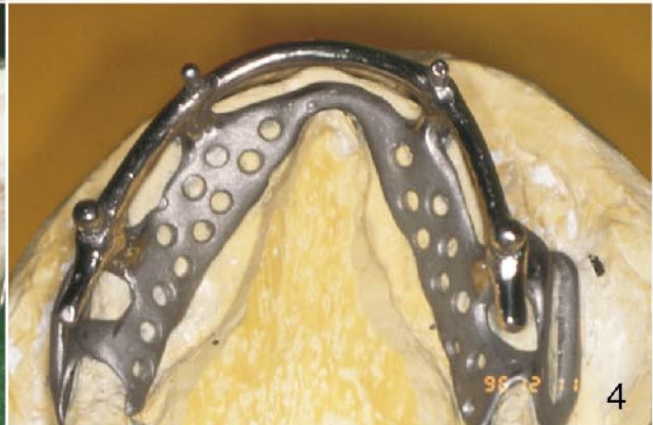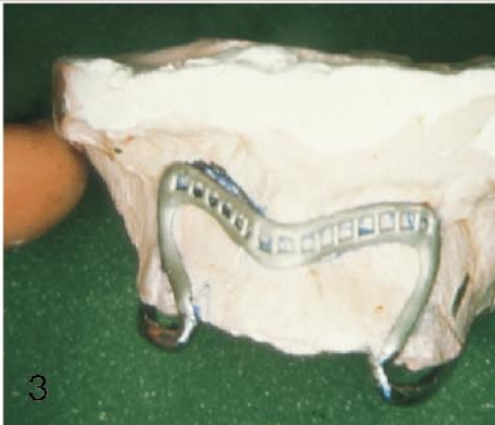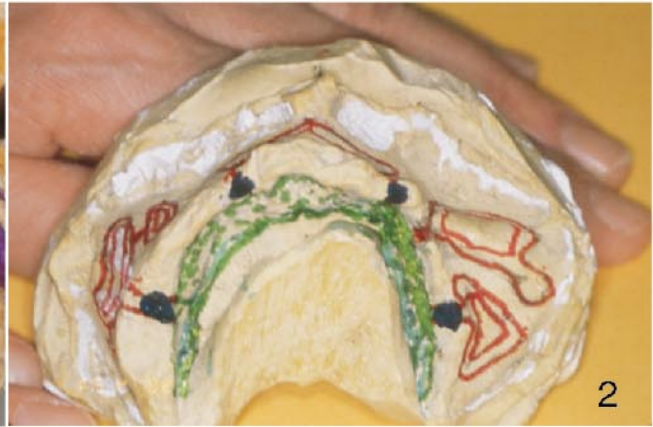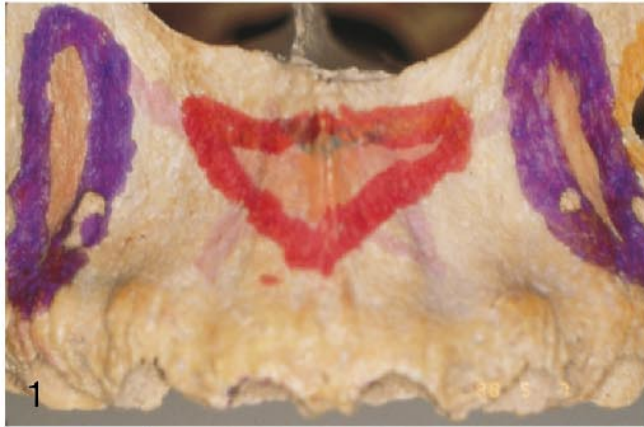
Narrow, solid, single struts should not be placed along the palatal surface of the crest. This is the area that must offer resistance to anterior and lateral thrusts of the tongue. The struts located in this position should be broad and fenestrated, covering at least 80% of the palatal side of the crest. The large fenestrations allow for the reattachment of the mucoperiosteal tissues to the bone without vascular challenge, discourage settling, and reduce weight.

A strut should not be placed over a sharp or right angle of bone geometry. If allowed, eventual exposures of such a strut's corners cause irritation of overlying soft tissues, which will recede and cause bone resorption beneath it.

Secondary struts (those that are not abutment-bearing between the peripheral struts) cannot be made thicker than 0.5 mm or less than 2 mm in width. A narrow strut can cause bone resorption, while a thick strut can inhibit soft-tissue closure.

The peripheral struts on the labial and buccal surfaces should extend into the undercut areas that lie above the maxillary atrophied crest area to a point that will not interfere with implant placement. However, the struts should not be fenestrated, as the mobile areolar tissue that lies in the mu-





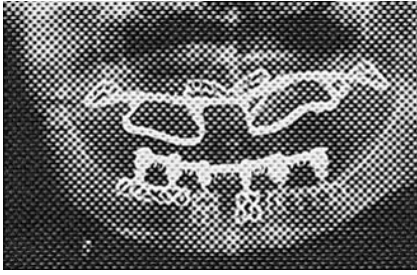


FIGURE 9. A postoperative panoramic roentgenogram indicates locations of vital struts and extensions.

cobuccal fold would be easily irritated by such fenestrations.

Omnivac or other trays should not be designed with flange undercuts because they will distort the final rubber or polyvinyl siloxane impressions. The final impression material itself should be induced to extend into the undercuts.

The necks of an implant should be designed only to protrude through attached gingivae or keratinized tissue. Attached gingivae in severely atrophied jaws lie along the palatal and lingual borders and not at the soft tissue crest.

Minimal numbers of struts should be used in areas of known dense bone. Of importance are struts that engage the anterior nasal spine and canine eminences as well as the palatal side of the crest. For additional immediate support whenever deemed necessary, a 2-mm wide posterior buccal loop connecting it to the palatal strap with a single 2-mm strut can be employed. If it has to be removed because of buccal resorption, it can be done by cutting through it.

Extension of the peripheral frame beyond the maxillary tuberosities in order to expose the pterygoid plates causes resorption of the distal proximal surfaces of the tuberosities in an anterior direction, leaving the hamular notch and pterygoid struts totally isolated with large spaces anterior to them. This sometimes causes trismus.

Whenever possible, a continuous buccal and labial peripheral strut design should be eliminated and replaced with independent, intermittently placed labial and buccal extensions. In this manner, each portion will not have significant influence on others and can be eliminated selectively from the substructure if necessary.

If less than 1 cm of palatal bone does not exist bilaterally, it is inadvisable to consider implant fabrication. This is because support from the broad, fenestrated palatal strut is required as a primary element of design. Substitution of struts placed in alternative positions (*ie*, labio-buccal, zygomatic buttress, or pterygohamular) will not contribute to lateral and anterior stress resistance but may contribute to an early demise caused by significant resorption processes in the bearing areas.

Implants can be seated even if secondary struts do not fit closely to undermining bone. The key points of support (the continuous palatal strut, the canine struts, and the anterior nasal spine accommodation), however, must fit with precision. In such instances, minor deficiencies can be repaired with the use of particulated HA or HTR.

A patient should never be permitted to leave the office until the tissues are

completely sutured, covering every aspect of the substructure. If it is necessary to make split thickness horizontal incisions to allow for complete, passive suturing of the tissues, this must be done. Mattress sutures, both interrupted and continuous, should be used with silk or Vicryl.

Implant overdentures should never be tissue-borne in any area. If they compress the soft tissues, severe pain and swelling may result. Areas of impingement can be eliminated easily, however, by relieving the peripheral borders and the tissue-borne surfaces of the overdenture.

Porcelain teeth should not be used with subperiosteal implants. Acrylic teeth are preferable so they can wear in time, thereby diverting more stresses from the underlying bone. If they wear excessively, acrylic can be added to them; new acrylic teeth can be processed directly over the original framework or a new overdenture can be fashioned. In order to accommodate demanding patients, the six anterior teeth may be made of porcelain.

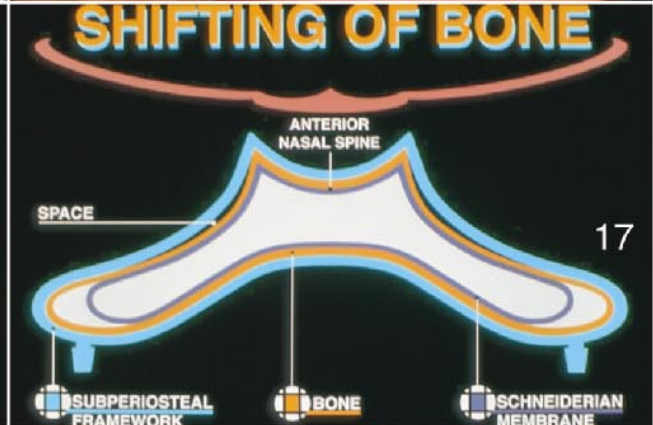
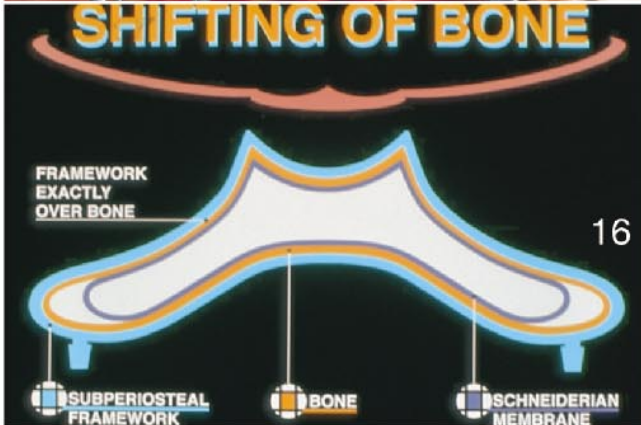
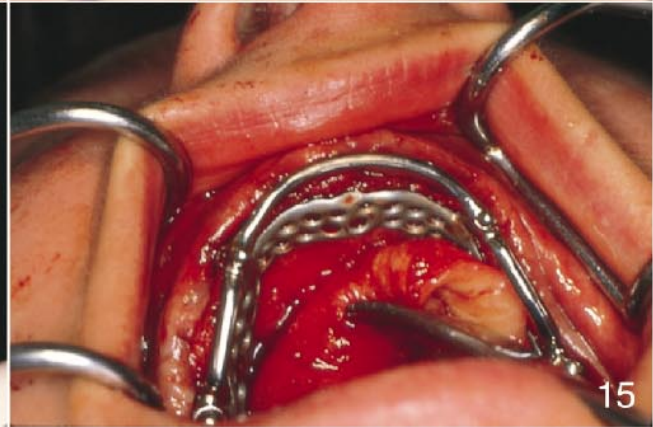
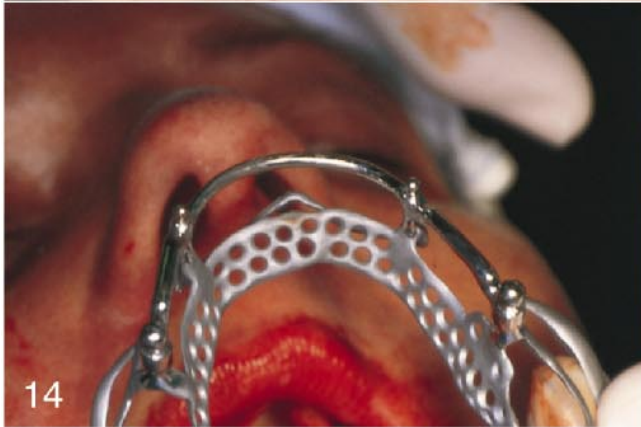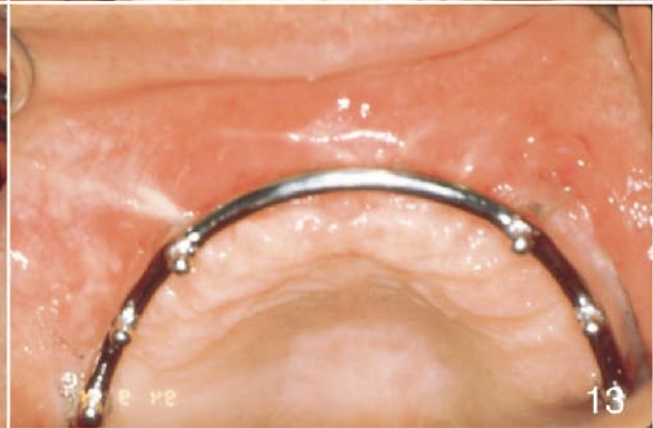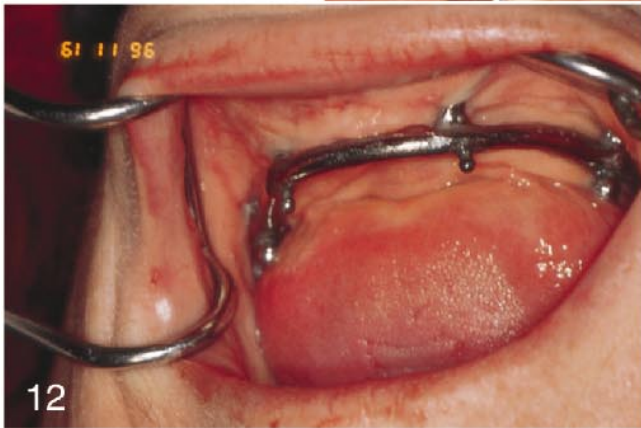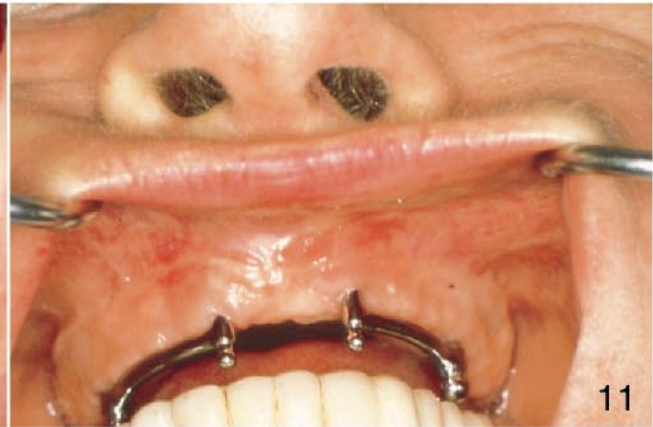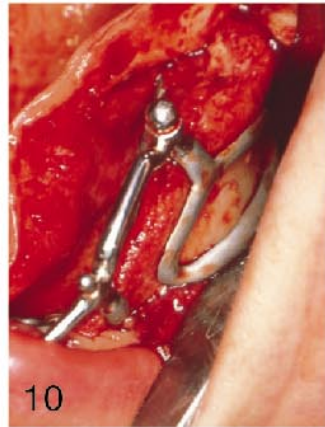Fixed prostheses are contraindicated for complete subperiosteal implants because they prevent ridge lap adjustments, which might occur after infrastructural settling. In addition, oral hygiene measures are facilitated if a superstructure is removable.

The ideal plane of occlusion and occlusal patterns to be used with subperiosteal implants is contingent on the following factors:

- (a) When the opposing arch is edentulous with a full subperiosteal implant supporting an overdenture,

- ←
- FIGURE 1. A close view of a maxilla shows the anterior nasal spine, canine eminences, and the lower portion of the nasal cavity.  
 FIGURE 2. The subperiosteal implant is designed on a master stone cast made from a direct bone impression. This particular design takes advantage of the very dense zygomatic process.  
 FIGURE 3. The mucoperiosteal tissues must be well retracted in order to expose the necessary anatomic features required for an accurate bone impression. This encourages an accurate casting.  
 FIGURE 4. At least 5–10 mm of bone should exist on the palatal surface of the maxillary crest to resist the anterior and lateral thrusts of the tongue. This fenestrated palatal strap should rest on 70–80% of the remaining crestal bone.  
 FIGURE 5. The palatal fenestrated strut and anterior nasal spine struts are demonstrated.  
 FIGURE 6. A more distal view of the fenestrated palatal strut and its close adaptation to the underlying bone is presented.  
 FIGURE 7. The fit of the subperiosteal implant resting over the anterior nasal spine and canine eminences is illustrated.  
 FIGURE 8. A clinical view of the same case after soft-tissue healing is shown.





the ideal occlusal anatomy should show zero degree cuspal inclines on the acrylic teeth with group function during lateral excursions.

- (b) When natural teeth or fixed bridge prostheses are present in the opposing arch, the maxillary teeth are guided by the inclined planes of the posterior quadrants if they do not exceed 15°. It is imperative in these situations, however, to eliminate the inclined planes of the buccal cusps of the posterior maxillary teeth and to narrow their occlusal tables.
- (c) Anterior incisal guidance should be minimized for long-term success.

Severe labial and buccal undercuts often exist in the edentulous maxillary arch. In these situations, the author's two-piece bisectional interlocking implant design has proved to be successful.

When the posterior buccal surface of the bone has resorbed to less than 0.5 mm as a result of a subperiosteal implant placed over it, or merely from disuse atrophy, the maxillary sinus, the membrane, and the posterior buccal surface of the maxillae form a triad that is in equilibrium and can remain so for years if not disturbed. When placing subperiosteal struts over this extremely fragile bone, a physiologic phenomenon often occurs. The bone no longer continues to resorb in spite of a space that sometimes appears between the buccal struts and the extremely thin bone. As this thin bone recedes, it is influenced by the sinus membrane, which is attempting to maintain the equilibrium that existed prior to the

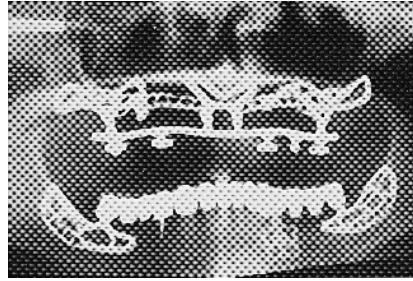


FIGURE 18. A panoramic X-ray showing the earlier rigid posterior buccal loops.

implant contact. When the patient inhales, the membrane will draw bone inward, which causes it to recede. The space beneath the metallic framework fills in with granulomatous tissue, which causes swelling and discomfort (Figs 16 and 17). This is eliminated by removing the classically placed rigid buccal strut with no loss of the overall retention of the implant. Due to these observations, the author has replaced the rigid buccal loop with a delicate leaf design in which each leaf is totally independent of the others (Figs 18–20). An alternative is to eliminate any posterior buccal struts in instances when the palatal crest exhibits at least 10 mm of height.

The additions of the posterolateral portions of the maxillary subperiosteal implant, that is, leafy, petal-like extensions, contribute to keeping the triad in equilibrium.

#### DISCUSSION

For the first 20 years of practice (1965–1985), the author encountered a lower degree of success than in the past 12 years due to factors such as learning

curves, poor impression materials, inadequate designs due to not fully understanding the physiology of bone resorption, and poor surgical and impression techniques as compared with current techniques. Graph 1 represents the author's experience with maxillary subperiosteal implants.

The following are advantages of the presently employed design:

- (1) When done correctly, it is a predictable technique.
- (2) Noninvasive surgeries are preferred compared to the use of iliac crest bone grafts.<sup>17</sup>
- (3) Severely atrophic maxillae may be rehabilitated with confidence.
- (4) Patients who undergo successful treatment note positive psychological advantages.
- (5) Segmental (unilateral) subperiosteal implants have been used successfully as posterior fixed bridge abutments when endosseous implants are contraindicated.<sup>25</sup>

Implants of these designs and their prostheses may be delivered in 3 to 4 weeks time.

The following are disadvantages of the technique:

- (1) Two-stage surgery is required.
- (2) Experienced technicians must be available to cast these implants.
- (3) Removing failing implants may present technical difficulties.
- (4) Complexities of design and operation require experience.

#### INDICATIONS FOR MAXILLARY SUBPERIOSTEAL IMPLANTS

Maxillary subperiosteal implants are called for under the following conditions:

FIGURE 10. A posterior buccal loop is seen to be attached to the fenestrated palatal strap by only one strut, which enables it to be easily removed if necessary.

FIGURES 11–13. The firmness of the mucoperiosteal tissues covering the implants is clearly demonstrated.

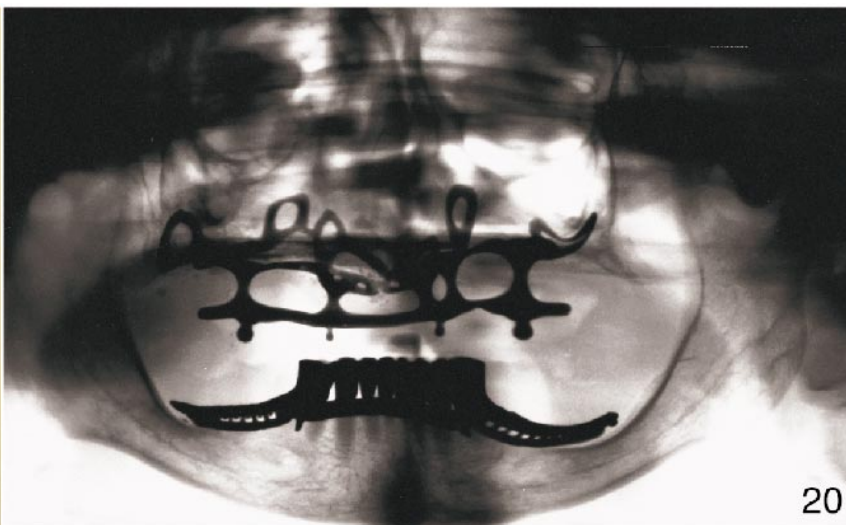
FIGURES 14 AND 15. The large fenestrated palatal strap lightens the weight of the implant besides allowing for the reattachment of the mucoperiosteal tissues to the bone that lies beneath the fenestrations.

FIGURES 16 AND 17. A shifting of the posterior buccal surface of the fragile bone seems to take place when rigid metallic struts from a subperiosteal implant are placed over it. This is orchestrated by the Schneiderian mucosal lining, which forms an equilibrium triad between itself, the maxillary sinus, and the remaining 0.5 mm of bone in the posterior buccal area. In order to prevent the bone from resorbing directly to the Schneiderian mucosal lining, it allows the bone to recede away from the metallic framework and thus maintain the state of equilibrium. When at least 10 mm of height exists along the palatal surface of the crest, the buccal struts or leaf-like designs can often be totally eliminated from the original design.



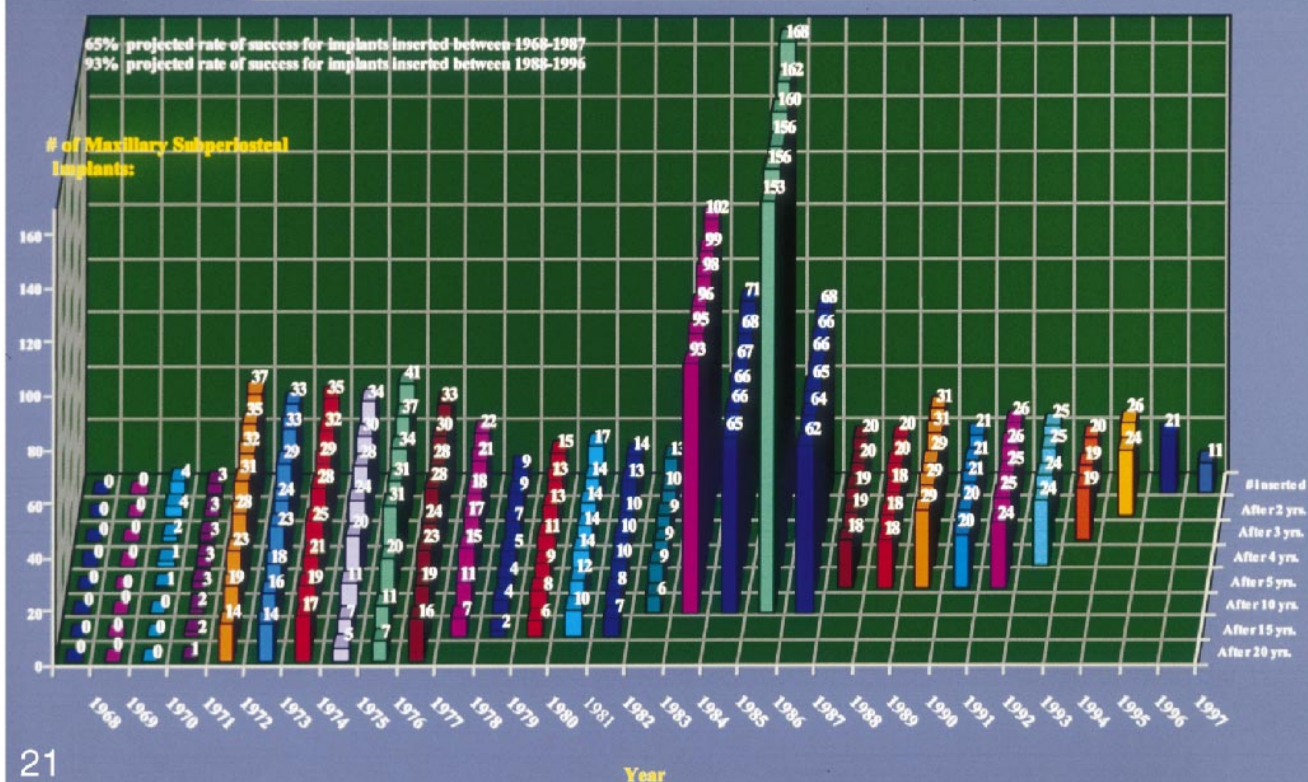


19



20

A study of 940 Maxillary Subperiosteal implants inserted between 1968 and 1997



21

FIGURE 19. The latest casting eliminates the classically rigid buccal loop and is replaced with delicate leaf designs in which each leaf is totally independent of the others.

FIGURE 20. A postoperative panoramic X-ray showing the tiny delicate leaf-like extensions along the fragile posterior buccal plates of bone. GRAPH 1. The graph shows a span of 29 years from 1968 to 1997 during which 940 maxillary subperiosteal implants were inserted. Only during the past 12 years of placement in over 300 cases did the results rise to 93% projected rate of success as compared to an average of 65% projected rate of success during the much earlier years.

- (1) When there are atrophic maxillae where the palatal surfaces of the ridges are at least 5–10 mm in height.
- (2) When no other type of implant can be placed.
- (3) When previous endosseous implants have failed.

**CONCLUSION**

By following the design suggestions and technical information presented

here, possibilities for higher levels of satisfaction with maxillary subperiosteal implants may be realized.

#### REFERENCES

1. Dahl GSA. Subperiosteal implants and superplants. *Dent Abstracts*. 1957;2:685.
2. Goldberg NI, Gershkoff A. Six year progress report on full denture implants. *Implant Dent*. 1954;1:13-16.
3. Gershkoff A, Goldberg NI. *Implant Dentures*. Philadelphia: JB Lippincott Company; 1957.
4. Marziani I. Use of tantalum in reconstructive surgery with special regard to oral subperiosteal implants. *Int Dent J*. 1952;3:13. Correction 1953;4:627.
5. Marziani I. Dental implants and implant dentures, their theory, history and practice. *Int Dent J*. 1954;4:459.
6. Marziani I. Co-report: tantalum implant dentures. *Int Dent J*. 1958;8:255-257. Discussion 1958;8:257-260.
7. Lew I. Implant denture—a simplified upper technique using immediate prosthesis. *Dent Digest*. 1952;1:10.
8. Lew I. Implant denture case study of twelve years duration. *J Implant Dent*. 1962;8:41-43.
9. Lew I, Greene BD, Maresco MJ. The Lew passive retainer for overlay and partial prosthesis. *J Oral Implantol*. 1977;7:124-137.
10. Berman N. Methods for improving implant dentures. *Oral Surg*. 1953;8:227-236.
11. Bodine RL Jr. Research with implant dentistry. *Int Dent J*. 1957;7:425-426.
12. Bodine RL Jr et al. Long term implant denture histology and comparison with previous reports. *J Prosthet Dent*. 1976;35:665-673.
13. Linkow LI, Chercheve R. *Theories and Techniques of Oral Implantology*. Vol. I. St. Louis: CV Mosby; 1970:171-183.
14. Linkow LI, Chercheve R. *Theories and Techniques of Oral Implantology*. Vol. II. St. Louis: CV Mosby; 1970:559-566.
15. Linkow LI. *Implant Dentistry Today—A Multidisciplinary Approach*. Vol. I. Padua, Italy: Piccin Nuova Libaria Publishing; 1990:821-909.
16. Linkow LI. Maxillary pterygoid extension implant, the state of the art. *Dent Clin North Am*. 1980;24.
17. Cranin AN. Simplifying the subperiosteal implant denture technique. *Oral Surg*. 1966;22:7-20.
18. Cranin AN. Implant dentures. *J Am Dent Assoc*. 1963;67:441-442.
19. Cranin AN. *Oral Implantology*. Springfield, MO: Charles C Thomas; 1970:111.
20. James RA. The support system and the perigingival defense mechanism of oral implants. *Oral Implantol*. 1976;6:270-285.
21. Judy KW, Weiss LM. Modern surgical and design considerations and clinical indications for subperiosteal implants. Part III, Partial subperiosteal implants. *Quintessence Int*. 1977;8:37-48.
22. Judy KW, Weiss LM. Modern surgical and design considerations, clinical indications for subperiosteal implants. Part II, Total mandibular implants. *Quintessence Int*. 1977;8:25-36.
23. Linkow LI, Mangini F. *Color Atlas of Implant Techniques and Implant Prostheses*. Padua, Italy: Piccin Nuova Libreria Publishing Company; 1998:131-138.
24. Boyne PJ. Restoration of deficient edentulous ridges by bone grafting and the use of subperiosteal metal implants. *Int J Oral Surg*. 1974;3:278-281.
25. Benoit P et al. Subperiosteal implants (principles and practice). *Bordeaux Med*. 1970;3:1079-1080.
26. Linkow LI. *Maxillary Implants—A Dynamic Approach to Oral Implantology*. Vol. I. North Haven, Conn. Glarus Publishing; 1977:113-133, 159-185.
27. Linkow LI. My thoughts, philosophies and contributions regarding implantological restorations for severely atrophied maxillae that are partially or totally edentulous. *Oral Implantol*. 1973;4:7-45.
28. Linkow LI. *Implant Dentistry Today—A Multidisciplinary Approach*. Vol. II. Padua, Italy: Piccin Nuova Libaria Publishing; 1990:876-878, 900, 902-905.
29. Linkow LI. *Implant Dentistry Today—A Multidisciplinary Approach*. Vol. II. Padua, Italy: Piccin Nuova Libaria Publishing; 1990:1051-1080.