

THE USE OF TITANIUM PLATES FOR BONE REGENERATION WITH ROOT FORM IMPLANTS: A CASE REPORT

Mohamed A. Maksoud, DMD

KEY WORDS

Implants
Bone regeneration
Titanium mesh
Ridge augmentation
Atrophic ridge

In reconstruction of the partially and totally edentulous ridges that have bony defects due to old trauma or longstanding atrophy, it is necessary to reconstruct both the width and height of the alveolar ridge. This clinical case report covers bone regeneration prior to implant placement to achieve an aesthetic and functional base for prosthetic restoration. The focus of this report will be on bone regeneration, which does not depend on the utilization of a barrier membrane.

INTRODUCTION

Bone regeneration evolved from improving the support of a removable prosthesis to satisfy today's demand for a natural, predictable prosthesis with a natural bone contour that enables the placement of the maximum number of implants of the greatest possible diameter and length in a direction that is acceptable occlusally.¹⁻³ Intraoral grafting from the mandibular symphysis, maxillary tuberosity, and the ascending ramus have been common sites for bone harvesting, which allow fixation of bone blocks or granules on the different atrophic ridges using titanium screws or membranes.⁴⁻⁷ These techniques allow the placement of dental implants in patients not previously considered to be implant candidates because of insufficient bone at the implant site.

Misch *et al*⁵ and Misch and Misch⁶ introduced the technique of bone blocks, which are immobilized using

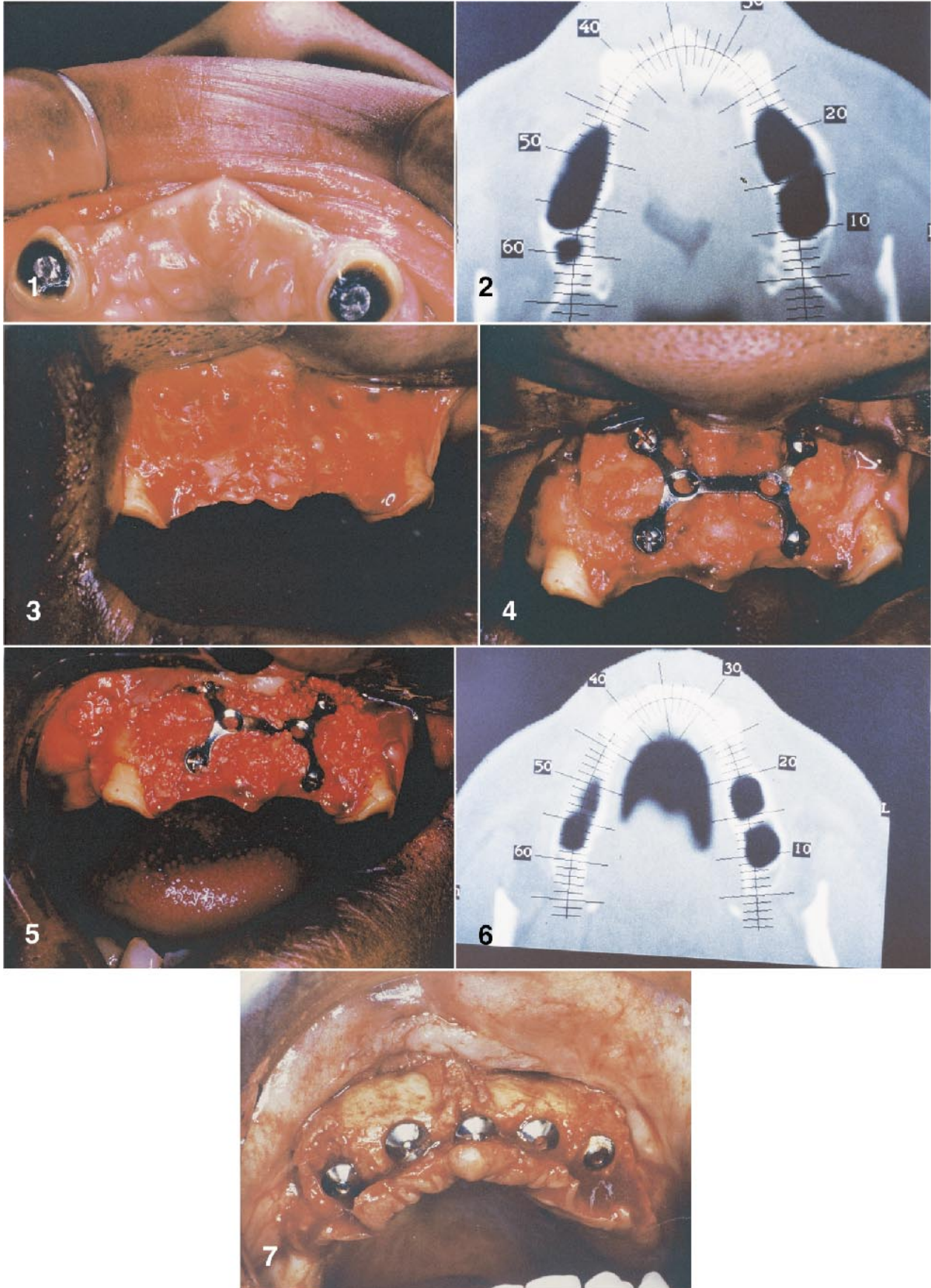
titanium screws drilled through the bone block and removed at the time of implant placement following the fusion of the block to the donor site. This technique can have potential complications, such as the fracture of the bone block during drilling, overheating of the bone during screw insertion, and invasion of anatomical structures such as the nasal and maxillary sinuses, the mandibular canal, and the mental foramen. This technique addresses the alternative use of titanium plates and screws to fix the block graft in an attempt to preserve the integrity of the harvested graft.

REPORT OF A CASE

Procedure

A 39-year-old woman presented seeking an implant restoration to support her maxillary full denture. Preliminary examination revealed severe atrophy of the premaxilla due to longstanding use of a maxillary denture following a

Mohamed A. Maksoud, DMD, is in private practice in Jacksonville, Fla.



traumatic extraction of the natural teeth (Fig 1). Computer tomography scanning of the maxilla revealed severe bilateral atrophy of the premaxilla horizontally, which would not allow implant placement (Fig 2). The proposed treatment plan was the use of onlay block graft from the symphysis of the mandible; this augmented the premaxilla and allowed it to be immobilized using titanium straps and screws. Following the augmentation, five endosteal root form implants were placed in the premaxilla to support a fixed, removable prosthesis.

Technique

Two block grafts were harvested from the mandibular symphysis using the technique described by Misch *et al*⁵ and Misch and Misch.⁶ On the recipient site, decortication of the premaxilla was established using a large, round drill (Fig 3). After reshaping of the harvested graft to eliminate sharp edges and to allow for a maximum contact with the recipient site, a double Y titanium plate (Fig 4) was used to strap the harvested graft, allowing the use of short titanium screws on four corners. A mix of demineralized frozen bone allograft, bovine bone (Osteograft N-300, Ceramed Dental, Lakewood, Colo), and autogenous bone harvested from the donor site were used to fill in the voids between the graft block and the recipient site and to allow maximum

coverage to the desired bone width (Fig 5). The surgical site was closed after allowing for a stress-free flap approximation using Vicryl sutures and without the use of a membrane. Six months following the augmentation, a computer topography scan was taken to confirm the bone fill to the desired width and good bone contouring (Fig 6). The surgical site was accessed with a full-thickness flap, and the titanium screws and titanium straps were removed without complications. At that time, five root form implants were placed into the bone at a position that allowed it to be acceptable occlusally (Fig 7).

CONCLUSION

The benefits of this technique lie in the fact that there is no drilling into the block graft, which preserves the integrity of the graft. There is also no chance of graft fracture and no overheating of the bone. Furthermore, short screws can be used, so there is no accidental violation of vital structures. The titanium straps also act as a membrane, which, in addition to stabilizing the graft, guides the bone formation around the block graft. The limitations of this procedure are that in narrow, edentulous spaces, the close proximity of the neighboring teeth will not allow for maximum extension of the straps and placement of the screws.

REFERENCES

1. Buser D, Bragger U, Lang NP, *et al*. Regeneration and enlargement of jaw bone using guided tissue regeneration. *Clin Oral Implant Res*. 1990;1:22–32.
2. Lang NP, Hammerle CHF, Bragger U, *et al*. Guided tissue regeneration in jawbone defects prior to implant placement. *Clin Oral Implant Res*. 1994; 5:92–97.
3. Widmark G, Anderson B, Andrup B, *et al*. Rehabilitation of patients with severely resorbed maxillae by means of implants with or without bone grafts. A one year follow up study. *Int J Oral Maxillofac Implants*. 1998;13:474–482.
4. Fugazzotto PA. Report of 302 consecutive ridge augmentation procedures: technical considerations and clinical results. *Int J Oral Maxillofac Implants*. 1998;13:358–368.
5. Misch CM, Misch CE, Resnik RR, *et al*. Reconstruction of maxillary alveolar defects with mandibular symphysis grafts for dental implants: a preliminary procedural report. *Int J Oral Maxillofac Implants*. 1992;7:360–366.
6. Misch CM, Misch CE. The repair of localized severe ridge defects for implant placement using mandibular bone grafts. *Implant Dent*. 1995;4:261–267.
7. Misch CM. Ridge augmentation using mandibular ramus bone grafts for the placement of dental implants: presentation of a technique. *Prac Periodont Aesthetic Dent*. 1996;8:127–135. ■

←

- FIGURE 1. Clinical view of the premaxilla showing severe horizontal ridge atrophy.
 FIGURE 2. Computer tomography scan of the premaxilla before augmentation.
 FIGURE 3. Decortication of the recipient site using a large drill.
 FIGURE 4. The onlay block graft in place, supported by the titanium strap and screws.
 FIGURE 5. The grafted site filled with demineralized frozen bone allograft and bovine and autogenous bone.
 FIGURE 6. Computer tomography scan of the premaxilla 6 months after augmentation.
 FIGURE 7. Six months following the augmentation, with the endosteal implants in place.