

# LAMINOSS IMMEDIATE-LOAD IMPLANTS: II. CLINICAL CONSIDERATIONS OF OSTEOCOMPRESSION

William M. Locante, DDS  
Maurice Valen

## KEY WORDS

Sinusoidal thread design  
Implant load-bearing areas  
Bone lamination/osteocompression  
Occlusal force-to-bone density  
classification

The sinusoidal thread design of the LaminOss (Impladent Ltd, Holliswood, NY) osteocompressive immediate-load implant is structured with minimal shear interface to function in horizontal planes and stimulate bone growth by the action of streaming potentials at the implant thread surface area. This implant design, when used with a unique surgical instrumentation technique, allows maximum bone to be molded and compacted circumferentially around the sinusoidal implant threads. The surgical technique of bone lamination around larger implant horizontal planes (or load-bearing areas) creates a stable foundation for placing this implant into immediate function. For the past 10 years this surgical procedure has provided patients with immediate function the day of implant placement. The clinical advantage of immediate implant loading enhances care acceptance and patient satisfaction.

## THE SURGICAL ARMAMENTARIUM AND BONE MANIPULATION TECHNIQUES

**T**he goal of an immediate-load implant is to provide sufficient load-bearing areas (LBAs) in horizontal implant planes for immediate and long-term stabilization by surgical osteocompression. With the LaminOss implant system the concept of immediate load provides an additional physiologic feature utilizing the principle of streaming potentials for immediate bone lamination, as has been clinically practiced in orthopedics since the 1800s. In dentistry, the surgical technique of bone compaction is initiated by the LaminOss taps. The

bone lamination within physiologic limits is accomplished by the implant's sinusoidal thread design. To assure proper selection during surgery, the appropriate implant diameters of 3.3 or 4.0 mm are etched on the shank of each drill and tap. They are sequenced according to the surgical protocol in system-specific, highly polished stainless steel surgical cassettes. It is strongly recommended that no substitutions of drills or taps from other systems be used in place of or interchanged with the LaminOss armamentarium, regardless of similar millimeter markings.

*William M. Locante, DDS, is a diplomat of the American Board of Oral Implantology and in private practice at the Southern Dental Implant Center, 850 Willow Tree Circle, Suite 101, Cordova, TN 38018-6376. Address correspondence to Dr Locante.*

*Maurice Valen is the president and director of research and development of Impladent Ltd; adjunct assistant professor, Department of Dental and Materials Science; and lecturer on restorative and prosthodontic sciences, New York University, College of Dentistry. Address correspondence to Mr Valen at 198-45 Foothill Avenue, Holliswood, NY 11423-1611.*

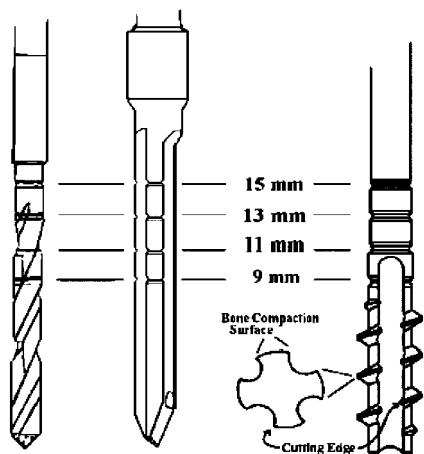


FIGURE 1. Note depth markings on the drills and taps. Taps function as osteotomes by scoring and compacting bone horizontally with minimal bone loss.

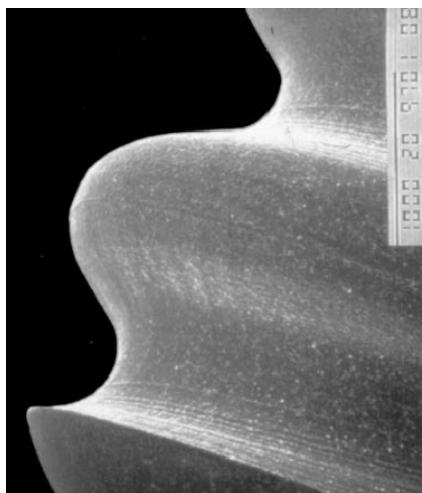


FIGURE 2. SEM of passive pilot cutting thread located above the spherical apex of the implant.

Owing to the novelty of its design, the LaminOss taps function as an osteotome in horizontal planes. Because of the design, the sharp edges and turning action of the taps (at 50 rpm) scores the bone, followed by bone compaction by the flat surface of the tap. The primary tap design is especially advantageous in osteopenic bone, ensuring minimal bone removal as it compacts the bone laterally (Fig 1). Using the primary tap alone without the secondary tap will limit the amount of bone scoring/removal and allow greater bone lamination by the implant

TABLE 1  
Ideal occlusal force-to-bone density classification: occlusal force per tooth position in pounds per square inch (PSI)\*

	FB4	FB2	FB1	FB2	FB2	FB4
Maxilla						
psi	100,110,100	50,40	30,20,10	10,20,30	40,50	100,110,100
Mandible	FB3	FB2	FB1	FB2	FB2	FB3

\*FB<sub>1</sub> describes lamellar bone formation ideal for implants. FB<sub>2</sub>, FB<sub>3</sub>, and FB<sub>4</sub> indicate a decrease in bone quality with an average variation of ±10%. Note that the average force on molars doubles when compared with bicuspids. This phenomena characteristically is due to the second-class lever in the molar region having a mechanical advantage greater than the applied force. From the bicuspid to the incisors, a third-class lever is a function inversely proportional in magnitude based on the inverse law hypothesis having a mechanical advantage less than the applied force.

threads. Tapping may be partially accomplished or eliminated in the maxillary molar region. It should be noted that in the osteopenic maxilla, the implant should not be immediate loaded. In such cases, using the grafting technique described in Part I the LaminOss implant should be placed in supragingiva mode out of occlusal function for a 4-month period to allow the synthetic bioactive resorbable graft (SBRG; OsteoGen, Implants Ltd, Holliswood, NY) to mineralize the osseous site. The LaminOss implant is equipped with a passive pilot cutting thread (Fig 2) and can be inserted in a forceful manner in the untapped site of the maxillary molar region as described in case report 2. For dense bone regions (FB<sub>1</sub> and FB<sub>2</sub>), a secondary tap is provided to widen the osseous thread areas laterally (Table 1). In dense bone with multiple implant osteotomies, all sites may be drilled and tapped sequentially; however, the secondary tap must be used one osteotomy at a time, followed by the *immediate* placement of the implant.<sup>1</sup> Since bone is viscoelastic, it will move toward the center of its osteotomy after compaction; even a slight de-

lay will make insertion of the implant difficult and retapping may be required, especially in dense bone.

In very dense bone, as the primary tap is introduced to the osteotomy for the initial tapping procedure the tap may not follow the 2.5-mm osteotomy for threading; the tap will simply wobble. Such indication will signal the use of the countersink drill to remove the cortical bone crestally by 1 or 2 mm, especially when using a 4 mm-diameter implant. It is not necessary to remove the entire cortical bone to the trabecular structure. If countersinking of the bone is required, using a SBRG will prevent the downward migration of the epithelium and will regenerate bone around the implant neck.<sup>2</sup>

Different bone densities have different load-bearing capacities, and each bone type must be osteocompacted in a fashion that maximizes bone-implant interface. For example, in a less dense bone region (FB<sub>4</sub>), one should consider either placing more implants or choosing longer implants (if adequate vertical height is available) to maximize the LBAs for greater bone-to-implant support (Table 2).

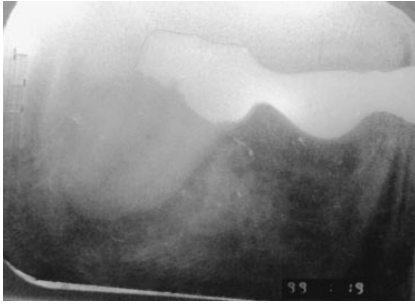


FIGURE 3. The tooth was severely decayed and periodontally involved, requiring removal.

### REVIEW OF SURGICAL PROTOCOL FOR LAMINOSS IMPLANTS

The surgical intent is to prepare a 2.5 mm osteotomy for insertion of a 4 mm implant and to achieve controlled functional osteocompression by each and every sinusoidal thread. Following tissue reflection and by using the provisional bridge as a guide stent, the initial procedure for a 4 mm-diameter implant is to mark the crest of the ridge with either a rosette bur or pilot drill. Removing the stent, the 2-mm depth drill is used to establish trajectory and depth. Following cortical bone penetration, the depth drill provides the best information regarding bone density by the cutting resistance encountered. The finishing drill (2.5 mm) is then taken to the appropriate depth, preferably 1 mm deeper crestally than the implant threads. Depending on the thickness, countersinking the cortex may be required. The residual defect should be grafted with SBRG prior to suturing.

It is also recommended that in spongy bone (FB<sub>4</sub>) the finishing drill not be used. In this osseous environment, the depth drill is taken to a depth of approximately 3 mm less than the selected implant. The primary tap may be used to the same drill depth, permitting the passive pilot thread to guide the implant to its full depth.

In type FB<sub>1</sub> and FB<sub>2</sub> classifications, the primary tap is used for initial bone compaction and is followed by the secondary tap. The function of these taps are similar to osteotomes in preparing

Implant Length	9.0 mm	11.0 mm	13.0 mm	15.0 mm
3.3 mm implant diameter (area in mm <sup>2</sup> )				
Load-bearing area (LBA)	57.2	69.5	81.7	94.0
Total surface area (TSA)	105.2	129.7	154.2	178.8
Passive thread for dense bone regions FB <sub>2</sub> and FB <sub>3</sub>				
4.4 mm implant diameter (area in mm <sup>2</sup> )				
Load-bearing area (LBA)	68.0	82.2	96.4	110.6
Total surface area (TSA)	122.0	150.5	178.9	207.4
Aggressive thread for spongy bone regions FB <sub>3</sub> and FB <sub>4</sub>				

\*A range of implant LBA is given according to the implant length most suitable for long-term success. Note that a 9 mm implant length is not recommended for the maxillary molar region. It is suggested that a minimum of one implant having LBA greater than 80 mm<sup>2</sup> (with an average variation of  $\pm 10\%$ ) be placed per tooth in the molar region.

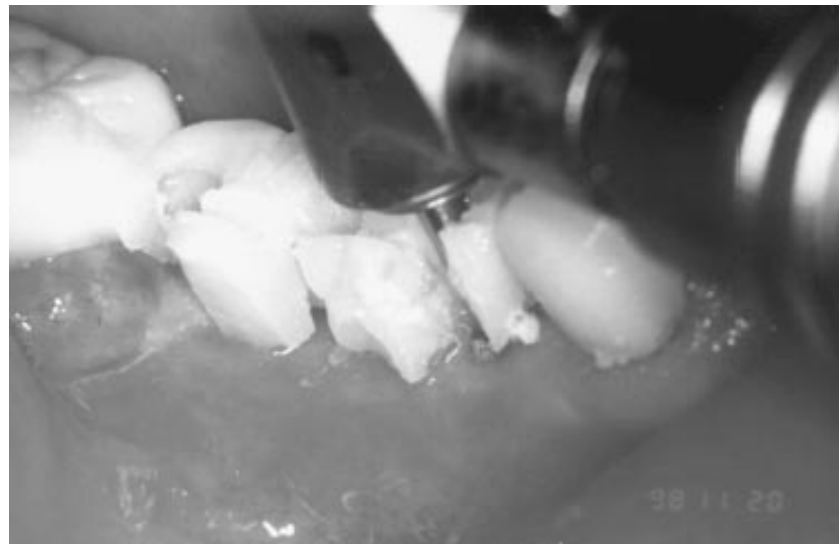

FIGURE 4. Surgical stent in place for intraoral marking.

the osteotomy by compacting bone in horizontal planes to allow the sinusoidal implant thread to accept and mold the bone into a laminated crib. It is imperative at this stage of the osteotomy to immediately insert the implant following the secondary tap procedure as described in the surgical protocol.<sup>1</sup> The implant is placed to its final depth, ideally 1 mm below the ridge. The implant, being a precise osseous-forming device, will accomplish the final threading of the osteotomy, creating maximum three-dimensional bone engagement. Use of the ratchet is advisable if the surgical motor and hand piece used do not provide sufficient

torque to complete osseous tapping procedures and implant delivery. Also, using the ratchet to manually deliver the last two implant threads will permit the clinician to experience solid bone-to-implant fixation within the osteotomy.

Due to the increased horizontal areas (LBA), this device will distribute stresses more uniformly throughout its implant interface. Since bone is strongest in compression<sup>3</sup> and bone can be stimulated via controlled functional osteocompression,<sup>2</sup> this implant can be placed into immediate function with a well-balanced and precise implant-fitting provisional. One can fully under-

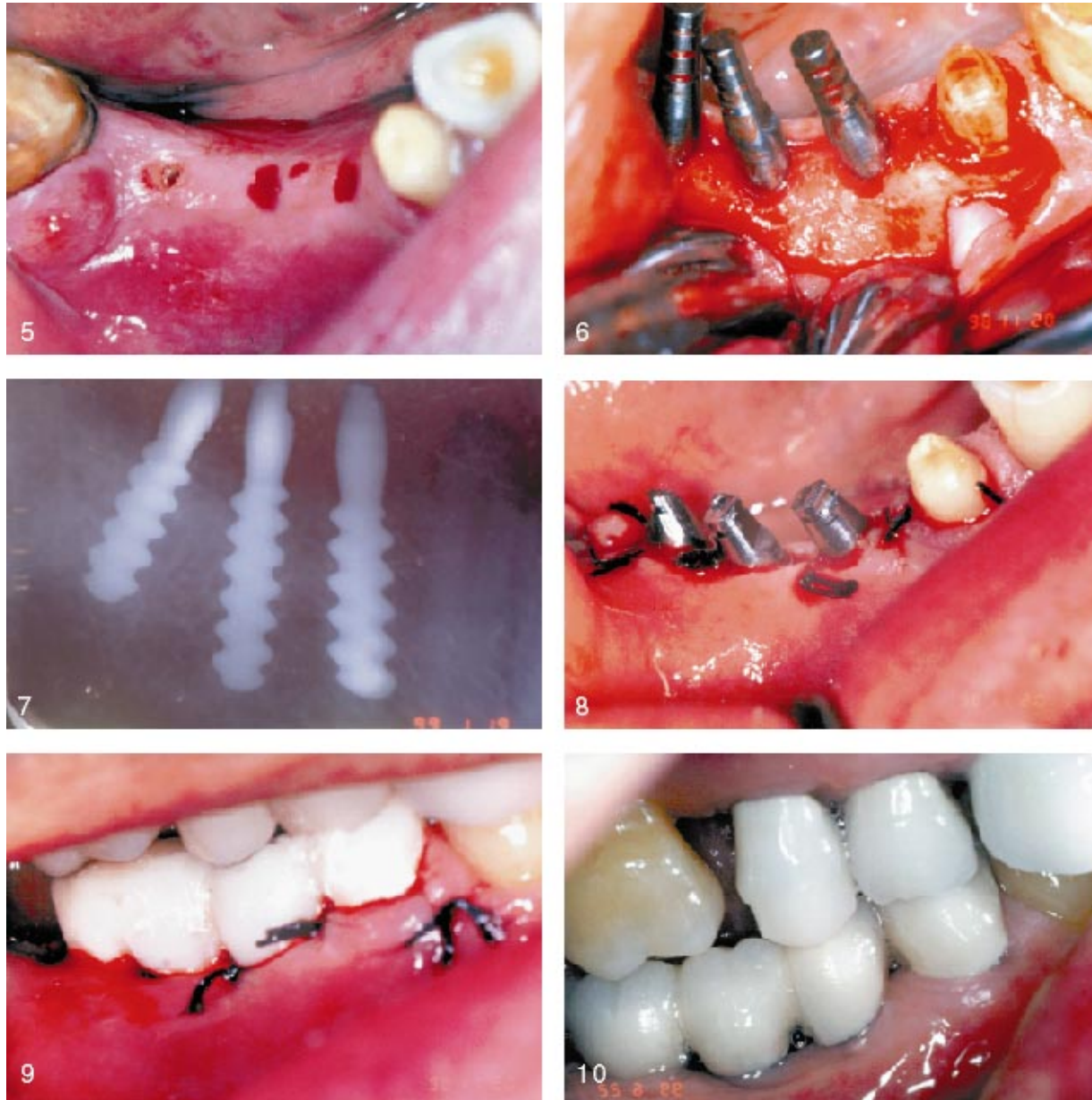


FIGURE 5. Implant sites identified as per X ray. FIGURE 6. Implants placed relevant to bone trajectory. FIGURE 7. X ray showing implant placement. FIGURE 8. The tissue was sutured and the posts prepared using copious amounts of sterile saline. FIGURE 9. Abutments were paralleled and a provisional in full occlusion was fabricated. FIGURE 10. Final restoration was placed into function within 10 weeks.

stand and appreciate the novelty of osteocompression especially in critical osseous circumstances where a clinical solution could be provided to the patient. For instance, in  $FB_4$  bone architecture, it is advisable to verify implant stability at a patient's second visit. The lack of bone resistance by thin trabeculation may not be significant and the implant may require an additional turn

3 to 7 days postsurgically to re-establish immediate fixation. If success is not attained, the "force mineralization technique" described in Part I of this paper should be used, placing the implant out of function. It is prudent to judge a compromised osseous architecture early on so as to be in a position to clinically remedy the outcome. By this approach, the patient is not left in

a compromised clinical state or faced with a failing implant 6 months later.

#### CASE REPORT 1: MANDIBULAR

A 53-year-old man was referred for evaluation of a distal abutment tooth (tooth 32) for a four-unit, fixed partial denture. The tooth was severely decayed and periodontally involved, requiring removal (Fig 3). The patient was

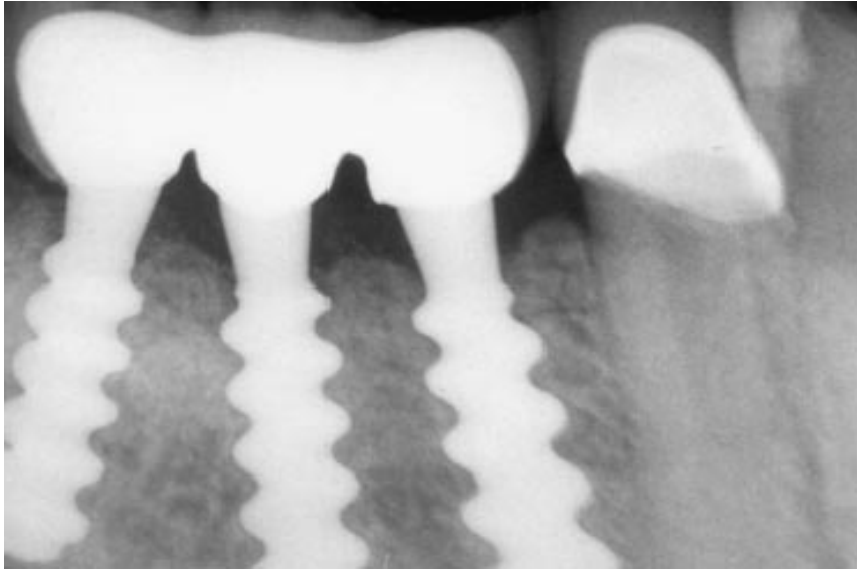


FIGURE 11. Case at 8 months postsurgery in full function.

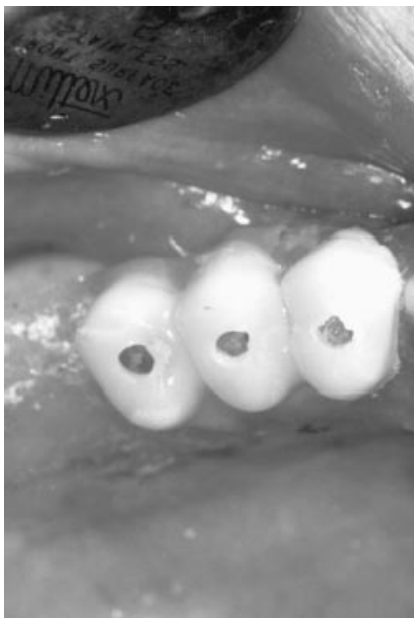


FIGURE 12. Surgical stent in place also served as the provisional.

provided with the choice and explanation regarding delayed and immediate-functioning implants. The patient opted for the immediate-load implant because he would not have to wear a removable partial or go without a functioning prosthesis.

An alginate impression was taken and a surgical stent/provisional was fabricated. The fixed bridge was removed and the surgical stent was

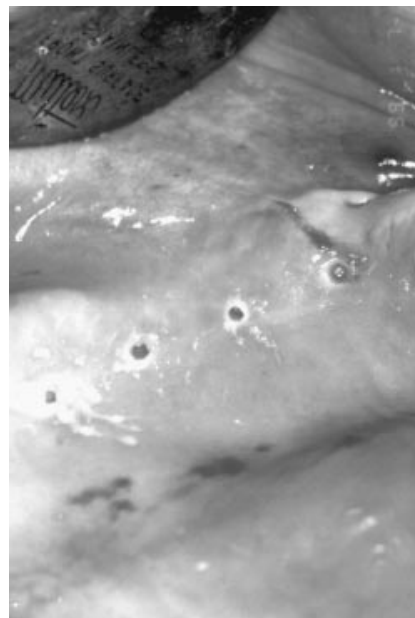

FIGURE 13. Osseous sites were marked crestally through the mucosa.

placed intraorally (Fig 4). Sites were scored anterior to the compromised tooth in a fashion consistent with the surgical protocol (Fig 5). The tooth was removed and sites were prepared. Implants were gently threaded to place (Figs 6 and 7). The tissue was sutured and the posts were then prepared with copious amounts of sterile saline using a 557 bur. Once the implant abutments

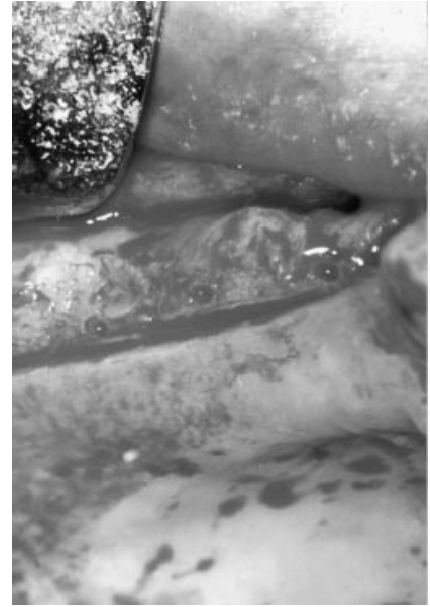


FIGURE 14. Midcrestal incision exposing the topography of the ridge showing osseous markings for a four-unit bridge.

were paralleled, a provisional in full occlusion was fabricated (Figs 8 and 9). The patient was told to function with the provisional in a normal manner, but to avoid extremely hard and chewy foods for the first 3 or more days. The patient was observed at 2-week intervals for 8 weeks. At 8 weeks the implants were stable, and radiographs showed excellent bone adaptation. The patient had no pain throughout the 8-week period. By all clinical and radiographic examination, the implants were firmly secured and pain-free. The patient then returned to his dentist for final fabrication of a fixed prosthesis (Figs 10 and 11).

#### CASE REPORT 2

A 52-year-old woman was referred for an implant evaluation of the maxillary left quadrant. She had an unremarkable health history and had sufficient bone according to radiograph and clinical examination. The patient was given the option of immediate-load implant treatment as well as conventional implant treatment. The patient's missing teeth were very obvious when she smiled, since she was missing all of her teeth distal to the maxillary canine. She

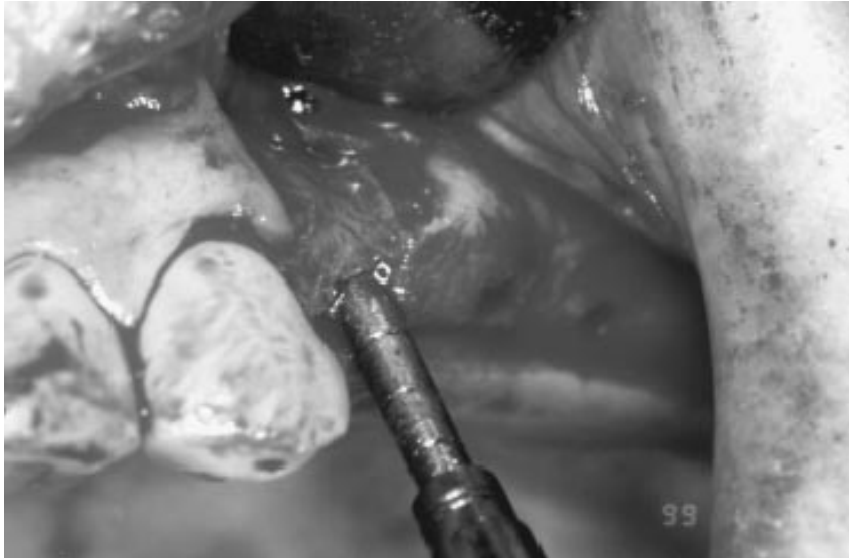

FIGURE 15. In spongy bone, following the depth drill, a 3.0 mm-diameter osteotome is used to open the crestal portion of the osteotomy for insertion of 4 mm-diameter implant as an alternative to countersinking.

opted for the immediate-load implant procedure because this would allow her to function immediately and satisfy her cosmetic concerns. She also did not want to wear a removable prosthesis.

Implant sites were chosen utilizing the surgical stent that would also be used as the provisional to mark the ridge (Figs 12 and 13). A midcrestal incision was made exposing the topography of the ridge for a four-unit bridge (Fig 14). By using the 2-mm depth drill in the molar region for the initial osteotomy, it was noted that the occlusal force-to-bone density classification was approximately  $FB_4$ . The osteotomy was completed with a 2.5 mm-diameter drill to one-third the intended depth. Osteotomes of 3 mm diameter were used to help open the crestal portion of the osteotomy to aid in the insertion of a 4-mm LaminOss implant (Fig 15). The LaminOss is equipped with a passive pilot cutting

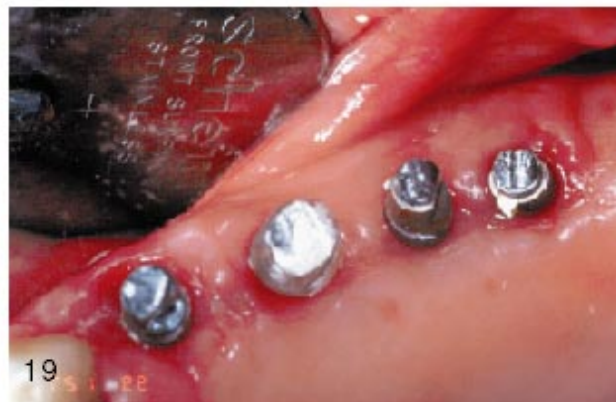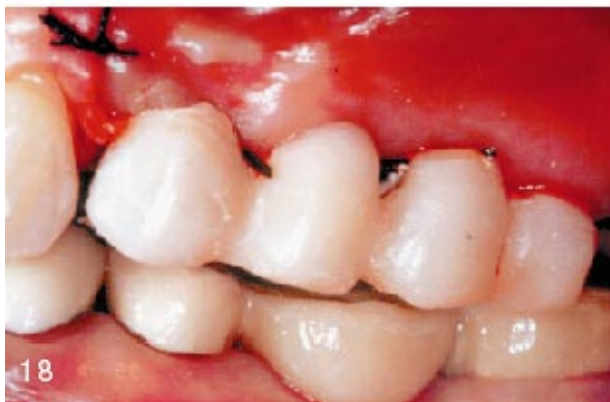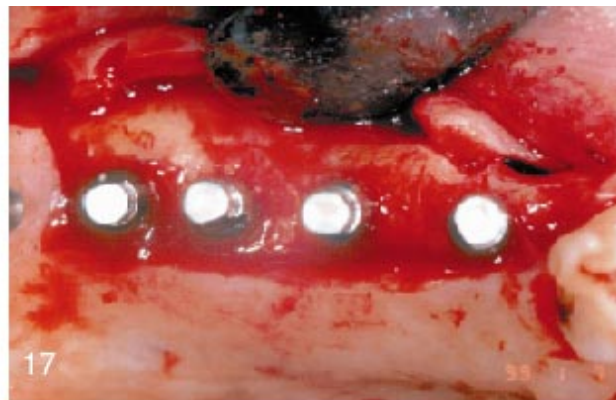


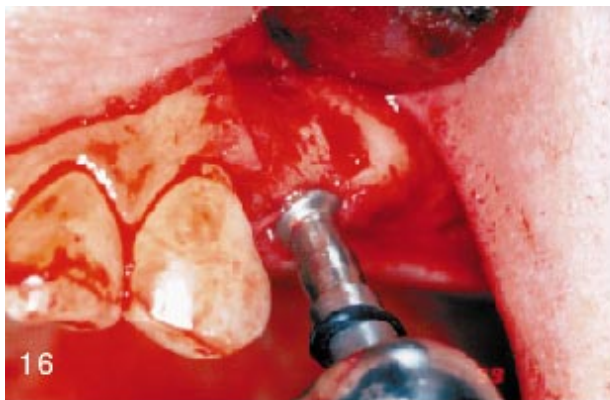FIGURE 16. Implants were inserted using the hand piece, followed by use of the hand ratchet for final seating. FIGURE 17. Each implant is placed to final depth with crestal thread flush or 1 mm below bone level. In such cases, residual defect is grafted with OsteoGen. FIGURE 18. Tissue sutured with fabricated acrylic provisional balanced and adjusted. FIGURE 19. Ten days postsurgery following removal of sutures.

TABLE 3

Bone-to-implant equilibrium under static load for ideal bone density\*

Applied Force (Patient's Force Registration [PSI])	Resisting Force (Required Implant Load-Bearing Area [LBA]) (mm <sup>2</sup> )
Static Compressive Strength of Maxillary Cancellous Bone (10 MPA)	
1	0.444
5	2.220
10	4.445
15	6.670
20	8.900
25	11.120
30	13.350
35	15.570
40	17.790
45	20.020
50	22.240
Static Compressive Strength of Mandibular Cancellous Bone (15 MPA)	
1	0.296
5	1.480
10	2.970
15	4.450
20	5.930
25	7.410
30	8.900
35	10.380
40	11.860
45	13.350
50	14.830

\*Ideal mechanical properties for maxillary and mandibular bone. Cyclic rather than static loading on implants is of concern. Results for LBA above may need to be increased as much as 50% because of various bone densities to achieve a clinical safety factor. One pound of the patient's applied force requires 0.444 mm<sup>2</sup> of implant LBA to be in equilibrium.

thread, and insertion was accomplished without the utilization of taps or countersinking because of osseous spongy consistency. The implant was threaded slowly using the hand piece, then a hand ratchet was used for the last few turns (Fig 16). Crestal grafting may be omitted if the implant should

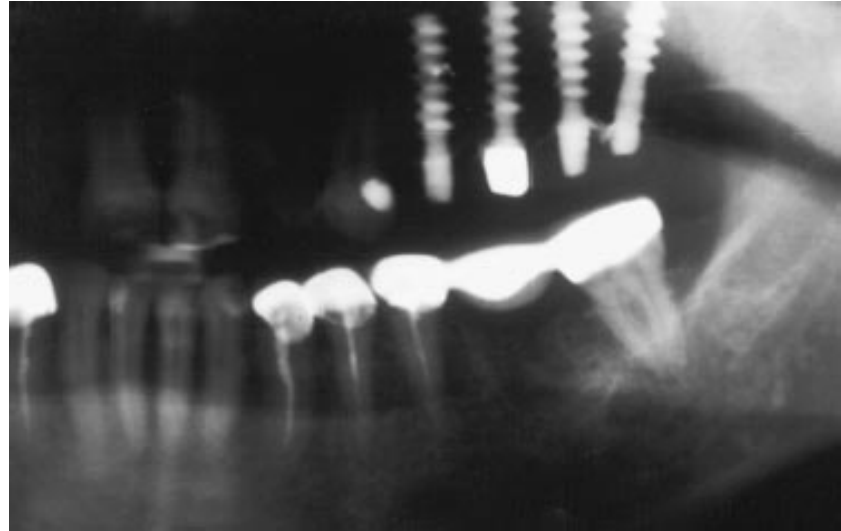


FIGURE 20. Eight weeks postsurgery, provisional was removed and all implants found to be stable and integrated.

be flush with the bone (Fig 17). The tissue was approximated and sutured with 4.0 silk. An acrylic provisional was fabricated, balanced, and adjusted. Excessive contacts were eliminated and uniform contacts in centric occlusion and centric relation were made (Fig 18). The patient returned to the office in 10 days for suture removal (Fig 19) and was seen every 2 weeks for re-evaluation clinically and radiographically for 8 weeks. At 8 weeks postsurgery the provisional was removed and each implant checked. All were found to be stable and integrated clinically without pain. Radiographic evaluations confirmed the clinical findings (Fig 20). The patient was released to return to her referring doctor for fabrication of the final fixed bridge.

DISCUSSION

Under static load in ideal bone density, 1 pound of occlusal force requires 0.444

mm<sup>2</sup> of implant LBA to maintain equilibrium for a maxillary case (Table 3). Table 4 demonstrates the clinical calculations required in questionable osseous sites. The total force that may be experienced by two bicuspids and two molars collectively is approximately 300 psi; therefore, 300 psi × 0.444 mm<sup>2</sup> = 133.2 mm<sup>2</sup> (plus a 40% safety factor) results in an approximate value of 186.48 mm<sup>2</sup> minimal LBA required by this four-unit bridge to attain equilibrium under static conditions. The above calculations satisfy the biomechanical tenets of bone as expressed in Table 3 as the minimum values for implant selection as dictated by the patient's applied force and estimated bone quality in a specific region. The latter two factors may vary (ie, diminished bone quality with high occlusal force magnitude) under cyclic loading and may have a greater destructive output and result in questionable clinical benefit on a long-

TABLE 4

Clinical and biomechanical calculations for case report 2\*

Step	Estimated Calculation	Results	Table Used
1	X-ray evaluation and selection of implants: Two each of 4 × 11 mm and 4 × 13 mm	FB <sub>2</sub> and FB <sub>4</sub>	1
2	Total load-bearing area (LBA) of the four implant selected: (82.2 mm <sup>2</sup> × 2) + (96.4 mm <sup>2</sup> × 2)	357.2 mm <sup>2</sup>	2
3	Total occlusal force experienced by teeth 12, 13, 14, and 15: 40 + 50 + 100 + 110 pounds per square inch	300 PSI	3

\*Tables 1, 2, and 3 were used for typical implant selection to calculate for the maxillary left-quadrant, four-unit bridge.

term basis. Daily function will require an implant with high LBA to maintain cyclic loading in osseous equilibrium. The value of 186.48 mm represents equilibrium under static load conditions and may need to be multiplied by a factor of 2 to satisfy cyclic loading conditions on a long-term basis as calculated in Table 4.

#### CONCLUSION

The sinusoidal thread design has several advantages over more traditional implants: (1) simplified surgical pro-

cedures; (2) significant decrease in treatment time without the risk of trauma by secondary surgery; (3) minimal implant emerging crestally without the need to compromise vascularity buccal lingually; and (4) final position of the soft tissue can be determined with greater tissue reattachment. Complications, such as abutment screw loosening and fractures, have been eliminated. Increased bone density and bone lamination at implant thread interface by immediate-load osteocompressive

implant design can be maintained on a long-term, predictable basis.

#### REFERENCES

1. Valen M. *Surgical Manual and Prosthetic Technique Guide*. Holliswood, NY: Impladent Ltd; 1996.
2. Block CM, Tillmanns HWS, Mefert RM, Zablotsky MH. Histologic evaluation of the LaminOss osteocompressive dental screw: a pilot study. *Compendium*. 1997;18(7):676-685.
3. Cowin SC. *Bone Mechanics*. Boca Raton, Fla: CRC Press, Inc; 1989;81-84, 97-157.