

PRECISE DENTAL IMPLANT PLACEMENT IN BONE USING SURGICAL GUIDES IN CONJUNCTION WITH MEDICAL IMAGING TECHNIQUES

*Thomas Fortin, DDS, PhD
Guillaume Champleboux, PhD
Jacques Lormée, DDS, PhD
Jean Loup Coudert, DDS, PhD*

KEY WORDS

- Surgical template
- Dental implants
- Computed tomography
- X ray
- Esthetics
- Biomechanics
- Computer-assisted surgery

The use of medical imaging techniques to make a very precise surgical guide for implant placement is described. This template is the combination of a currently used template and a very simple mechanical system designed to transfer a preoperatively defined implant position onto the surgical site. With the planning software, the practitioner determines the implant position according both to the ideal position dictated by the final restorative prosthesis and the available volume of bone. The surgical template then communicates the actual implant position to the surgical site. The template can be used not only in critical anatomical situations but also in placing the implant in an ideal position on bone because it eliminates possible manual placement errors and matches planning to prosthetic requirements.

INTRODUCTION

Much has been written about surgical templates for oral implants, which are recommended for accurate placement of the implant on the surgical site while taking into account both the final restorative prosthesis (*ie*, the biomechanical and aesthetic requirements) and the internal anatomy (*ie*, bone volume and the position of vital structures).

These templates are produced in two steps. A study prosthesis is first made on diagnostic casts. Then this prosthesis is duplicated and used as a radiological guide that includes radiopaque material that allows visualization of the tooth position on the radiological exam. Once this ideal prosthetic tooth position and its axis are defined, a computerized tomography (CT) exam is performed with the radiological guide in the mouth. After examination of the CT images, the practitioner defines the final axis to be transferred to the site during surgery. Thus the final axis is a compromise taking into account the ideal prosthetic axis and the residual bone available. The radiological guide can be used without modification¹ or can be transferred onto a

Thomas Fortin, DDS, PhD, is assistant professor in the Department of Oral Surgery at the Dental University of Lyon, 6-8 Place Deperet, 69007 Lyon, France. Address correspondence to Dr Fortin.

Guillaume Champleboux, PhD, is with TIMC-IMAG, Medical University of Grenoble, 38700 La Tronche, France.

Jacques Lormée, DDS, PhD, is in private practice at 71100 Chalon sur Saone, France.

Jean Loup Coudert, DDS, PhD, is a professor in the Department of Oral Surgery at the Dental University of Lyon, 69008 Lyon, France.

surgical guide² for this transfer. The surgical template can also be built at this stage³ without a radiological guide.

When there is a discrepancy between the planned prosthetic trajectory and the possible residual bone trajectory, which is a frequent occurrence,⁴ the transfer of the predefined position to the stent or directly to the site requires manual measurement, although the CT scan provides encoded parameters, reducing the accuracy of the transfer of the planned placement. For this reason, reformatted CT and three-dimensional CT planning are not considered to provide relevant predictability for implant size and anatomical complications.^{5,6} Consequently, many researchers propose using medical imaging technology to help the surgeon in transferring the planned positions to the surgical site with greater accuracy.⁷⁻⁹

This paper presents drilling templates that associate the ease of conventional template use and the accuracy provided by medical imaging technology. Afterward, some of the potential ramifications are discussed.

TECHNIQUE

Following a complete examination of the patient, the restorative dentist makes a study prosthesis on diagnostic casts, which represents the final restorative prosthesis. After satisfactory testing in the patient's mouth, the study prosthesis is duplicated in acrylic resin and then serves as a scanning template. A linear path is drilled through the main axis of the resin tooth. A gutta-percha cone is inserted to relate the ideal prosthetic axis so that it is clearly visible on the X-ray radiograph. A cube made of acrylic resin is then attached to the scanning template so that when it is in the mouth the cube is outside and in front of the lip of the same maxilla. To make this cube, resin is poured to affix two titanium tubes in the desired, highly precise position (Fig 1). CT scans are acquired with the template in the patient's mouth and im-

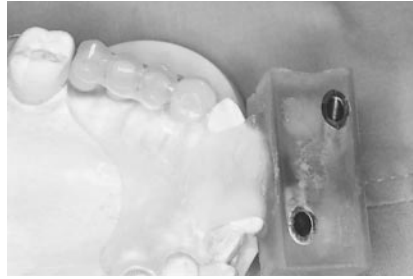

FIGURE 1. Diagnostic waxing of the implant-supported prosthesis is transferred onto a scanning template. To relate the ideal prosthetic axis, gutta-percha pins are inserted through the teeth according to the main axis. An acrylic resin cube is attached in front of this template. Two titanium tubes are included in this cube in a very accurate position.

ages are directly input to an imaging PC computer.

The preoperative plan is done using custom-designed Cadimplant software (Praxim, Grenoble, France). The position of the planned fixture is visualized on three planes: the axial slice and two reformatted views. One of these latter two views is perpendicular to the arch of the jaw, the other is tangential, and they both not only intersect with but pass by the fixture axis. Thus the implant is precisely located in the three-dimensional volume; there is no approximation of the calculated position. Only the axial plane intersects the implant axis. This is a significant improvement over previous techniques because it gives a precise evaluation of the implant dimensions to be transferred. To our knowledge no other planning tools, such as the software mentioned in Demey and Vrielinck⁸ and the commercial package for Sim/Plant (Colombia Scientific, Inc, Columbia, Md), provide these features. They provide only precalculated plans perpendicular to the axial slice.

At the beginning of the planning procedure, the two reformatted planes are initialized with the gutta-percha axis (Fig 2). Taking into account the anatomical structures, the practitioner can interactively change the position of the fixture on each plane. Simulation is carried out in real time. Recalculation

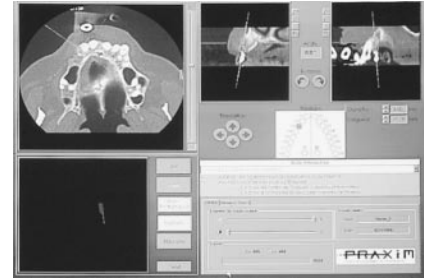


FIGURE 2. The preoperative plan is made with the custom-designed software Cadimplant® (Praxim). The practitioner works on three planes: axial slices (top left), a plane perpendicular to the arch of the jaw (top middle), and one tangential plane (top right). The latter two are passing by the implant position and, at the beginning of the planning procedure, they are initialized with the gutta-percha pins.

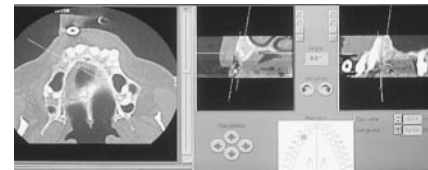


FIGURE 3. The practitioner has changed the implant position and dimensions on the tangential plane. Recalculation on the other planes is carried out in real time so that images of the implant are immediately updated and the other cross-sectional slices are always passing by the implant position. The angle between the implant and the gutta-percha pin is also calculated.

of the other planes is instantaneously performed so that cross-sectional slices are always passing through the implant (Fig 3). When there are several implants, the practitioner works on one implant and then proceeds to the next one with the images of the previously planned implant remaining on the axial slices. If necessary, their position can be changed until the result is satisfactory. To improve the relative position of implants in relation to one another, the practitioner can also use the three-dimensional view showing both the shape of the jaw, the ideal prosthetic axis, and the implant materialized by a cylinder (Fig 4).

Once the final positions of the implants are defined, the scanning template must be drilled in these exact positions. Thus the scanning template is firmly attached to a drilling machine

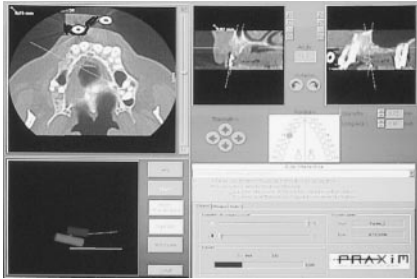

FIGURE 4. When there are several implants to plan, the three-dimensional view (bottom left), the axis of the implants (yellow and green cylinder), and the ideal prosthetic axis (yellow and green lines) can be useful for interimplant properties. It is also possible to mix the shape of the jaw with the implants.




FIGURE 5. The scanning template is drilled on the predefined implant positions by a drilling machine. The resin cube in front of the template is firmly attached to the machine with the help of the titanium tubes.

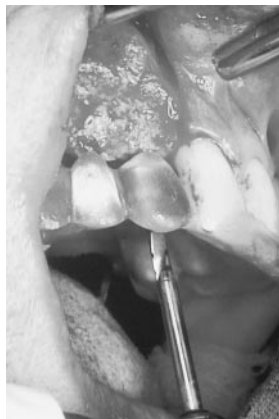

FIGURE 6. The scanning template is transferred onto a conventional surgical template. In front of the incisor the resin cube has been removed. The first osteotomy is done by inserting a small-diameter twist drill through the tube guide.

by placing the resin cube on a dedicated device into the drilling machine and by passing two metal shafts through the two titanium tubes (Fig 5). Al-

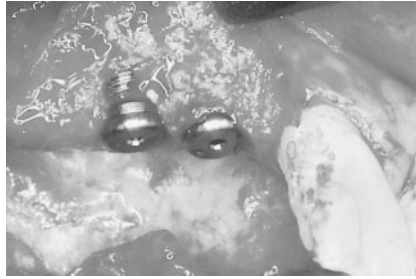

FIGURE 7. Implants in place. Notice the exposed threads on implant 14. This problem is easily solved by bone grafting. This particularity was predictable with the presurgical plan (Fig 4) and illustrates how precise this technique is.

though it is easy to extract the track of the titanium tubes in the resin cube from the CT images, they are used by the entire system to establish a mathematical link between the CT images and the drilling machine so that the position of the planned implant is drilled on the template with high precision at the desired diameter. The error was less than 0.2 mm in translation and 1.1° in rotation in an *in vitro* assessment.¹⁰

The resin cube is then separated from the template, which then becomes a conventional template. Metal tubes are used as bur guides and are inserted through the hole of the template previously realized by the drilling machine. During surgery, after reflexion of the mucoperiosteal flap, the surgical template is placed intraorally, supported by residual teeth or by the hard palate area. The metal tubes are pushed until they make contact with bone. A small-diameter twist drill bur is inserted through the tube guide for the first osteotomy. The diameter of this drill is 0.1 mm less than the internal diameter of the metallic tube. The stent is then removed, the osteotomy is completed to the desired diameter, and the implant is inserted (Figs 6, 7).

DISCUSSION

Compared with other computer-aided systems, the template presented here is very simple to use. No modification in clinical habits is necessary since similar procedures using conventional surgical

guides are currently in use.^{1-3,11} There is no preparation of the injurious flap,⁸ no elaborate presurgical markers,⁹ no expensive technology such as an optical tracking system,^{7,9} and no stereolithographic model.⁸ This new technology requires only that patients remain motionless during CT examination in order to achieve the desired transfer and that the stent be placed in the mouth in the same position during both the CT examination and surgery. This is possible by using a speed spiral CT scan and by supporting stents on the remaining dentition. For a fully edentulous patient, this could turn out to be somewhat inexact. However, the stabilization by the individual form of the hard palate area can be clinically sufficient.¹¹ Slight motion can be tolerated. The most important point is that interimplant properties on the residual crest, with respect to the midsagittal plane, are accurately transferred.

A precise surgical template is particularly useful in cases in which positioning is critical because of anatomical conditions. It helps to avoid vital structures, to place the implant in a thin maxilla, and when cortical plates are parallel to avoid fenestration. When bone anatomy requires very precise placement, it eliminates the need to place shorter or smaller diameter implants than planned in order to provide a necessary margin of safety,⁵ and it allows placing an implant where manual placement would end in failure. Thus with this system more implants are placed for a better distribution of biomechanical constraints, avoiding dramatic biomechanical situations such as cantilever pontic. Furthermore, the application potential of implant treatment is increased.

In other cases, such a template can be considered as optional. Nevertheless, integrating this technology in the implant treatment procedure assures placing the implant in an ideal position on bone because it eliminates possible manual placement errors and matches planning to prosthetic requirements. This has a significant impact on the

systematizing treatment success when considering esthetics and biomechanics. For esthetic success, the correct position and angulation of the implant regarding the supported prosthetic tooth is of utmost importance to obtain a gingival contour similar to that of the neighboring teeth. The Cadimplant system presented here increases the control of biomechanical situations, which is important for long-term success¹² because the actual transfer (1) minimizes both the discrepancy between the abutment and the center of the supported prosthetic crown and the angulation of the implant, depending on the anatomical volume available; and (2) allows difficult procedures such as the actual transfer of a planned tripod.

In short, this template increases the input of the final prosthesis in the surgical treatment. Combining the ability to alter soft and hard tissue architectures and using a very precise template allows the surgical procedure to adhere to the dictates of the final restorative prosthesis.

After further assessment, it is hoped that the introduction of imaging technology in oral implant surgery will modify surgical protocols toward minimally invasive procedures. Reflexion of the mucoperiosteal flap will probably be able to be avoided.

REFERENCES

1. Sicilia A, Noguerol B, Cobo J, Zabalegui I. Profile surgical template: a systematic approach to precise implant placement. A technical note. *Int J Oral Maxillofac Implant.* 1998;13:109–114.
2. Sehti A. Precise site location for implants using CT scans: a technical note. *Int J Oral Maxillofac Implant.* 1993;8:433–438.
3. Kennedy BD, Collins TA, Line PCW. Simplified guide for precise implant placement: a technical note. *Int J Oral Maxillofac Implant.* 1998;13:684–688.
4. Almog DM, Onufrak JM, Hebel K, Meitner SW. Comparison between planned prosthetic trajectory and residual bone trajectory using surgical guides and tomography—a pilot study. *J Oral Implantol.* 1995;4:275–280.
5. Jacobs R, Adriansens A, Naert I, Quirynen M, Hermans R, Van Steenberghe D. Predictability of reformatted computed tomography for pre-operative planning of endosseous implants. *Dentomaxillofac Radiol.* 199;28:37–41.
6. Jacobs R, Adriansens A, Verstreken K, Suetens P, Van Steenberghe D. Predictability of a three-dimensional planning system for oral implant surgery. *Dentomaxillofac Radiol.* 1999;28:105–111.
7. Fortin T, Coudert JL, Champeboux G, Sautot P, Lavallee S. Computer-assisted dental implant surgery using computed tomography. *J Image Guide Surg.* 1995;1:53–58.
8. Demey S, Vrielinck L. Drilling templates for oral implants based on preoperative planning on CT images. In: Lemke HU, Vannier MW, Inamura K, Farman A, eds. *Computer Assisted Radiology.* Berlin, Germany: Elsevier Science; 1999:883–887.
9. Watzinger F, Brikfellner W, Wanschitz F, et al. Computer-aided positioning of dental implants—preliminary results. In: Lemke HU, Vannier MW, Inamura K, Farman A, eds. *Computer Assisted Radiology.* Berlin, Germany: Elsevier Science; 1999:888–893.
10. Champeboux G, Blanchet E, Fortin T, Coudert JL. A fast accurate and easy method to position oral implant according to computed tomography. In: Lemke HU, Vannier MW, Inamura K, Farman A, eds. *Computer Assisted Radiology.* Berlin, Germany: Elsevier Science; 1998:836–841.
11. Misch CM. Bur guide surgical template for implant placement in grafted jaws. *J Oral Implantol.* 1997;4:170–173.
12. Duyck J, Naert IE, Van Oosterwyck H, et al. Biomechanics of oral implants: a review of the literature. *Technol Health Care.* 1997;5:253–273. ■