

# PLATELET-RICH PLASMA APPLICATION IN SINUS GRAFT SURGERY: PART I—BACKGROUND AND PROCESSING TECHNIQUES

Jaime L. Lozada, DDS  
 Nicholas Caplanis, DMD, MS  
 Periklis Proussaefs, DDS, MS  
 John Willardson, DDS  
 Greg Kammeyer, DDS

The uses of cytokine growth factors in soft tissue applications has been reported on. The scientific background and various processing techniques to prepare the autologous materials are reviewed here. An ongoing research project to study grafting of the maxillary sinus for bone regeneration and implant site preparation with the growth factor Platelet Rich Plasma is outlined.

**KEY WORDS**

Retrieval analysis  
 PRP  
 Fibrin Glue  
 Platelet Concentrate  
 Sinus Graft  
 Dental Implant

**INTRODUCTION**

The search for an ideal intra-operative hemostatic agent for soft and hard tissue surgery resulted in the development of a fibrin glue, a hemostatic agent with adhesive properties.<sup>1</sup> Early surgical application of fibrin demonstrated sub-optimal properties attributed to a lack of concentrated fibrinogen as well as to production costs.<sup>2</sup> Further developmental pursuit for this hemostatic agent yielded autologous platelet gel, which was developed as a byproduct of multicomponent plasmapheresis in the early 1990s.

The plasma fraction is further separated with a hard, or long, spin, which separates the platelet concentrate from the platelet-poor plasma (PPP).

Blood fraction concentration is extensively used in hematology. The term *platelet concentrate* (PC) is used in hematology to denote a greater than 1 mL/ $\mu$ L concentration of platelets and is synonymous with the term *platelet-rich plasma* (PRP). This procedure involves drawing blood and centrifuging it in two stages. The first soft, or short, spin separates the straw-colored plasma fraction from the packed red blood

PRP is procured from the centrifuge of autologous blood and then combined with thrombin and calcium chloride to produce a viscous coagulum gel capable of being introduced as a surgical graft material. Documented evidence demonstrates the release of a cascade of growth factors through the activation of the platelets with calcium chloride and thrombin.<sup>3,4</sup> Two of these growth factors are platelet-derived growth factor (PDGF) and transforming growth factor  $\beta$ 1 (TGF- $\beta$ 1). The role of PDGF in the repair of soft tissues has been well documented.<sup>5-7</sup> Recent research describes the importance of platelets in osseous repair. Platelets may act as an exogenous source of growth factors to stimulate the anabolic activity of bone cells.<sup>5,8</sup>

PDGFs are activators of mesenchymal cells. They stimulate cellular che-

All the authors are affiliated with the Loma Linda University School of Dentistry.

Jaime L. Lozada, DDS, is director of Advanced Education in Implant Dentistry in the Department of Restorative Dentistry. Address correspondence to Dr Lozada at the Department of Restorative Dentistry, School of Dentistry, Loma Linda University, Loma Linda, CA 92350. Nicholas Caplanis, DMD, MS, and Periklis Proussaefs, DDS, MS, are assistant professors in Implant Dentistry. John Willardson, DDS and Greg Kammeyer, DDS, are graduate students in Implant Dentistry.

motaxis, proliferation, and gene expression in monocytes, macrophages, and fibroblasts *in vitro*. These cell types are essential for tissue repair. TGF- $\beta$ 1 is known to activate fibroblast to form pro-collagen, which results in collagen deposition within the healing wound.<sup>9</sup>

Recent publications conclude that PDGF and TGF- $\beta$ 1, alone or in combination, increase tissue vascularity, promote fibroblast proliferation, increase the rate of collagen and granulation tissue production, and enhance osteogenesis. The possibility of bone graft enhancement has recently interested researchers and clinicians in exploring the potential of PRP for use in oral, maxillofacial, implant, and periodontal surgery.<sup>10-12</sup> Our center was interested in evaluating the clinical efficacy of PRP in sinus graft surgery.

The purpose of part I of this study is to describe the scientific background and processing techniques for obtaining PRP gel. Part II of this study will report on our clinical histological and histomorphometric results that use PRP within the augmented maxillary sinus.

## MATERIALS AND METHODS

### Patient selection

Twelve partially or completely edentulous patients (10 women and 2 men, mean age  $55.6 \pm 8.9$  years) with atrophic posterior maxillae were treated from June 1999 to March 2000 and retrospectively selected to be part of this study. The patients were examined for medical contraindications, including acute or recurrent sinusitis, uncontrolled systemic diseases, and smoking. By using tomographic images, the bone height in the posterior maxilla was analyzed. The patients were included in the study if less than 5 mm of bone height existed inferior to the maxillary sinus floor and endosseous implant placement was indicated. All patients signed a surgical consent form, consenting to sinus graft surgery and PRP placement. Patient selection, preoperative preparation, and surgical

procedure were performed following the protocol previously outlined by Hanisch *et al.*<sup>13</sup>

### Surgical procedure and graft preparation

The patients were prepared and draped for a standard sterile procedure. Intravenous access was obtained for all patients for PRP collection, as previously described. Six of the 12 patients received intravenous sedatives for conscious sedation. Local anesthetic was administered by using Polocaine 2% with 1:20,000 levonordefrin. The sinus graft procedure followed the technique described by Boyne and James.<sup>14</sup> A crestal incision was made from the canine or premolar area and extended posteriorly to the ipsilateral maxillary tuberosity region. Buccal vertical releasing incisions were made in the canine and tuberosity regions. Mucoperiosteal flaps were raised to expose the lateral wall of the maxillary sinus. An ovoid antrostomy was outlined with a number 4 round bur along the inner limits of the maxillary sinus area. The antrostomy was completed with hand instrumentation by using chisels and a mallet to allow for the in-fracture of the lateral wall of the sinus. The Schneiderian membrane was then carefully elevated within the sinus cavity so it was completely free from the original floor of the sinus cavity, anteriorly, posteriorly, and medially. Concurrently, the lateral wall was elevated inward to create the new relocated sinus floor. The 12 patients were divided into four groups of three patients each. The antral space was then grafted with a mixture of autogenous/PRP, allograft/PRP, xenograft/allograft/PRP, or xenograft/PRP. The graft material and PRP was mixed thoroughly (Table 1). The graft material was then surgically implanted within the subantral space, and the mucoperiosteal flaps were approximated and sutured with horizontal mattress and single interrupted ties. The patients received postoperative antibiotics for 7–10 days (amoxicillin 500 mg TID), as well as analgesics (ibupro-

Graft (g)	Calcium Chloride/ thrombin (cm <sup>3</sup> )	PRP (cm <sup>3</sup> )
.5	.25	1.5
1.0	.50	3.0
2.0	1.02	6.0
3.0	1.50	9.0

\* DCA, DIDECO Compact Advanced Unit; PRP, platelet-rich plasma.

fen 800 mg q6h PRN pain), and were instructed to rinse twice per day with an antimicrobial (chlorhexidine gluconate) rinse.

### Biopsy procedure

Each patient had a single biopsy taken at the time of implant placement and 6 months after the sinus graft surgery. Biopsies were harvested with a 3-mm trephine bur through the approximate center of the graft 10–12 mm in length through a site that would later receive an endosseous root-form implant.

### PRP processing techniques

Two processing methods for plasma sequestration have been used at the Center for Prosthodontics and Implant Dentistry, Loma Linda University: the DIDECO Compact Advanced (DCA) and the HARVEST SmartPREP processing techniques.

#### The DIDECO Compact Advanced Unit

The DCA unit is a versatile centrifuge with multiple applications in medicine. Given its versatility, it is somewhat complex to operate. The protocol for the preparation of PRP with the DCA unit begins with the preparation of the whole blood collection bag. A standard 450-mL blood bag contains 63 mL of anticoagulant solution (citrate phosphate dextrose adenine solution), from which 20 to 25 mL is removed and discarded for processing of PRP. A total of 200–250 mL of whole blood is collected from the patient 30 minutes before the surgery (Fig 1). The DCA unit is prepared with a 55 cm<sup>3</sup> washbowl.

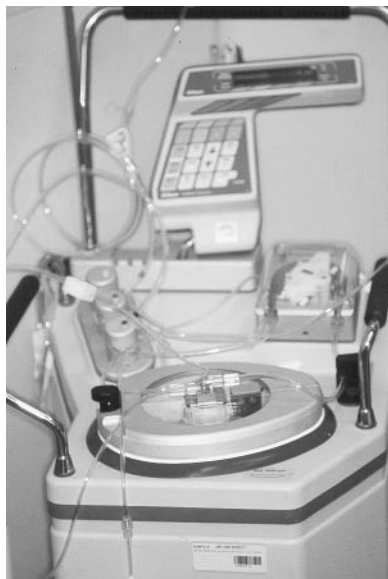

FIGURE 1. The DIDECO Compact Advanced Unit (DCA).

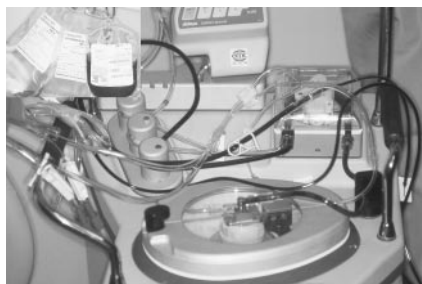

FIGURE 2. DIDECO Compact Advanced Unit pumping blood through the lines into the washbowl.

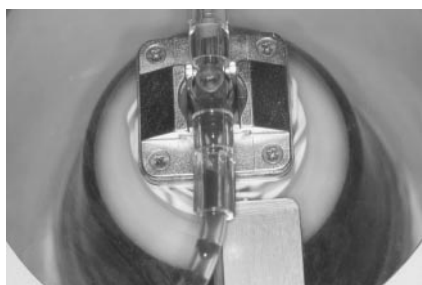

FIGURE 3. The centrifuge unit, at this point, is rotating at approximately 5600 rpm.

All the disposable fittings for blood collection are then located as indicated in the DCA instruction manual.<sup>15</sup> The unit is then programmed to operate with the settings PRP 2, DIDECO 55. When the process is initiated, the unit

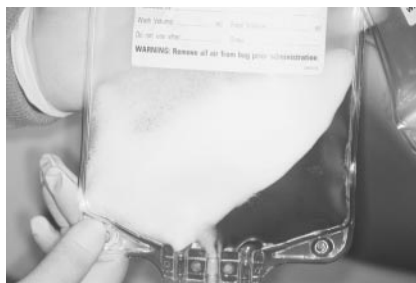

FIGURE 4. Separated platelet-poor plasma to the designated bag.




FIGURE 5. Separated a redirected platelet-rich plasma.

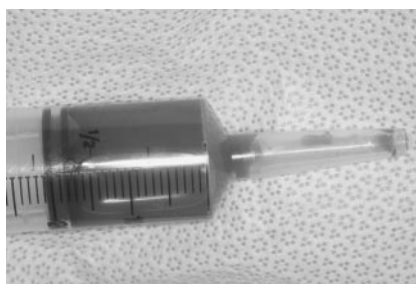

FIGURE 6. (a) Syringe after aspiration of 20cc of platelet-rich plasma; (b) Graft consistency after saturation with platelet-rich plasma and activators.

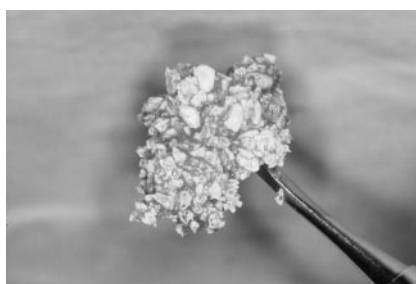


FIGURE 6. Continued.

starts pumping blood through the lines into the washbowl (Fig 2).

The centrifuge unit, at this point, is rotating at approximately 5600 rpm. The blood separation process is moni-

tored until the pump is full (Fig 3). At this point, PPP will flow into a designated bag as “PPP” (Fig 4). Through optical meters, the DCA unit will sense that the buffer coat and the PRP layer are separating and automatically slow the unit to 2400 rpm. At this precise moment, the DCA unit operator should close the PPP lines and redirect the PRP to the properly designated bag (Fig 5). After PRP is collected, some red blood cells can be allowed to flow with the collected PRP. At the end of this process, the operator will have obtained approximately 30–40 cm<sup>3</sup> of autologous PRP (Fig 6a).

The DCA-processed PRP graft material is prepared by placing the required volume of bone graft into a sterile dish. The circulating assistant handles the sterile syringe with the PRP in it, and in a dropwise manner, deposits the PRP through the entire graft material. By using a separate sterile syringe with the calcium chloride/thrombin mixture, the circulating assistant deposits the solution over the PRP-saturated graft material in a dropwise manner, coalescing the graft mass. The surgeon, at this point, mixes the combined materials to initiate the platelet activation. After a few seconds, the graft material turns into a gel consistency and is ready for implantation (Fig 6b).

*The HARVEST SmartPRP Processing Unit*

This most recent method that the authors have used for processing PRP is the HARVEST SmartPRP processing unit. It is capable only of PRP production; however, it is relatively simple to operate. The HARVEST SmartPRP System technology consists of a micro-processor-controlled, automated centrifuge with decanting capability and a functionally closed dual chamber sterile processor. Anticoagulated blood is automatically separated into packed cells and PRP. The separated PRP is automatically decanted into a separate sterile chamber. The PRP is then con-



FIGURE 7. HARVEST SmartPREP.



FIGURE 8. Collected blood transferred to chamber's unit.



FIGURE 9. Chamber with blood placed into SmartPREP unit.



FIGURE 10. Plasma concentrated evident at the bottom of the chamber.



FIGURE 11. Syringe after aspiration of 8 cm<sup>3</sup> of platelet-rich plasma.

FIGURE 12. Special double syringe that equally mixes the platelet-rich plasma and calcium chloride/thrombin mixture while the graft material is saturated with the solutions.

centrated, producing PPP and a (PC; Fig 7).

The initial step in the SmartPREP system is to draw 7 mL of citrate-anticoagulant (ACD-A) into each of the provided 60-mL syringes. Then, 2 mL of the 7 mL of ACD-A is injected into the plasma chamber of the processing disposable. This leaves 5 mL of ACD-A within each of the 60-mL syringes for the whole blood draw, which will be incorporated within the whole blood samples drawn from the patient. Apheresis of the patient's blood into the 60-mL syringes is done 30 minutes before surgery to ensure adequate blood collection and preparation for processing of the PRP. Preparation for the blood withdrawal is typically done with a suitable peripheral vein capable of sufficient flow to fill the 60-mL syringes. The target volume is  $60 \pm 0.5$  mL. Unequal volumes may cause an imbalance during centrifuging. The syringe is inverted several times to ensure adequate mixing of the blood

with the ACD-A to prevent coagulation.

Once collected and adequately mixed with ACD-A, the syringes are immediately transferred to the blood chamber side of the processing disposable (side with the red dot marker; Fig 8). The filled disposable is placed into the centrifuge-swinging bucket in the vertical position (Fig 9). The start button is pressed, and the rotor begins to turn, causing the rotor buckets to reposition to the horizontal position. Red blood cells begin to sediment (soft spin) below the shelf, and PRP emerges above the shelf. After the PRP separation, the rotor is slowed (buckets remain in horizontal position), allowing the PRP to decant from the red blood cell chamber to the plasma chamber. When the PRP decant is complete, the rotor begins to turn again (buckets remain in horizontal position). Platelets in the PRP begin the sediment (hard spin) to the bottom of the plasma chamber. At the hard spin completion, platelets have been concentrated to the bottom of the plasma chamber; the rotor stops, and the buckets are allowed to return to the vertical position. The processing disposable is removed, and it is verified that the whole blood chamber contains packed red blood cells below the whole blood chamber shelf and that PC is evident at the bottom of the plasma chamber containing PPP (Fig 10). By using a blunt cannula with a sterile 10-mL syringe, a small amount of PPP is removed for hematology, and the remainder is used as a bone graft adjunct.<sup>16</sup>

The SmartPREP-processed PRP graft material is prepared by placing the required volume of bone graft in a sterile dish. The PRP and activator are deposited via a special double syringe that equally mixes the PRP and calcium chloride/thrombin mixture while the graft material is saturated with the solutions (Figs 11, 12).

#### SUMMARY

Part I of this study describes the historical background and surgical bene-

fits of PRP in wound healing. Technical aspects of PRP procurement and use have been described. Special emphasis was directed toward the two available processing techniques currently used in our center. Per our literature review, this is the first publication describing the use of PRP as a bone graft adjunct within the augmented maxillary sinus. Part II of this study will present clinical, histologic, and histomorphometric data of sinus biopsies harvested from 12 patients treated with these techniques.

#### REFERENCES

- Gibble J, Ness P. Fibrin glue; the perfect operative sealant? *Transfusion*. 1990;30:741-747.
- Matras H. The use of fibrin glue in oral and maxillofacial surgery. *J Oral Maxillofac Surg*. 1982;40:617-622.
- Cromack DT, Porras-Reyes B, Mustoe TA. Current concepts in wound healing: growth factor and macrophage interaction. *J Trauma*. 1990;30(suppl 12):S129-S133.
- Price GF, Mustoe TA, Altrock BW, Deuel TF, Thomason A. Role of platelet-derived growth factor in wound healing. *J Cell Biochem*. 1991;45:319-326.
- Hudson-Goodman P, Girard N, Jones MB. Wound repair and the potential use of growth factors. *Heart Lung*. 1990;19:379-384.
- Martin P, Hopkinson-Wolley J, Mc-Cluskey J. Growth factors and cutaneous wound repair. *Prog Growth Factor Res*. 1992;4:25-44.
- Myiazono K, Takaku F. Platelet-derived growth factors. *Blood Rev* 1989; 3:269-276.
- Bolander ME. Regulation of fracture repair by growth factors. *Proc Soc Exp Biol Med*. 1992;200:165-170.
- Pierce GF, Vandeberg J, Roudolph R. Platelet-derived growth factor-BB and transforming growth factor beta-1 selectively modulate glycosaminoglycans, collagen and myofibroblast in excisional wound. *Am J Pathol*. 1991;138: 629-637.
- Whitman DH, Berry RL, Green DM. Platelet gel: an autologous alternative to fibrin glue with applications in oral and maxillofacial surgery. *J Oral Maxillofac Surg*. 1997;55:1294-1299.
- Marx ER, Carlson E, Eichstaedt R, Schimmele S, Strauss J, Georgeff K. Platelet-rich plasma. Growth factor enhancement for bone grafts. *Oral Surg Oral Med Oral Pathol Oral Radiol Endod*. 1998;85:638-646.
- Anitua E. Plasma rich in growth factors: preliminary results of use in the preparation of future sites for implants. *Int J Oral Maxillofac Implants*. 1999;14:529-533.
- Hanisch O, Lozada JL, Holmes R, Calhoun CJ, Kan JY, Spiekerman H. Maxillary sinus augmentation prior to placement of endosseous implants: a histomorphometric analysis. *Int J Oral Maxillofac Implants*. 1991;14:329-336.
- Boyne PJ, James RA. Grafting of the maxillary sinus floor with autogenous marrow and bone. *J Oral Surg*. 1980;38:613-616.
- Dideco Compact Advanced. Cell separator for autotransfusion. User manual. Italy: 1998.
- SmartPREP Centrifuge System. *Operator's Manual*. 1999. ■