

# A NONRADIOLOGIC METHOD FOR ESTIMATING BONE VOLUME FOR DENTAL IMPLANT PLACEMENT IN THE COMPLETELY EDENTULOUS ARCH

Dennis Flanagan, DDS

## KEY WORDS

Dental implants  
Bone volume  
Preoperative estimating

A method is described for estimating bone volume and contour for dental implant placement in the edentulous arch.

## INTRODUCTION

When considering a patient for full arch dental implant treatment, there are many factors to evaluate.<sup>1-4</sup> An appropriate method for evaluating available bone volume and contour for dental implant placement is the computed tomography or Denta Scan.<sup>5,6</sup> At times, the patient may not be able to submit immediately for a radiologic scan or the surgeon would like an in office evaluation of the available bone volume and contour. What follows is a nonradiologic method that uses a bone sounding technique to visualize the underlying bone of the totally edentulous arch.<sup>7</sup>

## MATERIALS AND METHODS

The site is examined visually and palpated for anatomical landmarks. Standard periapical and panoramic radiographs are taken to examine the features of the bone planned for osseous host sites. Two sets of study casts are made. One set is mounted in centric re-

lation on an articulator. A diagnostic wax-up is made on the mounted casts to demonstrate the proposed positions of the teeth in the resulting prosthesis and tentative implant positioning. At this time, a surgical guide may be considered but not constructed until specific implant sites are finally selected for the appropriate prosthesis. In order to evaluate the underlying bone for implant position and augmentation, the experienced surgeon may locate tentative implant locations before a diagnostic wax-up is made. These tentative implant locations are selected on the basis of the appropriate spacing for esthetics and support for the resulting prosthesis.<sup>10-12</sup> The tentative sites are located and marked on the unmounted study cast (Figure 1). A vacu-form shell (0.020 inch) is made at each marked site. A hole is drilled at the crest of the ridge with a #2 round burr to provide access for the sounding periodontal probe. Facial and lingual access holes are then located and drilled in a facial lingual plane directly

Dennis Flanagan, DDS, has a private practice and is diplomate of the International Congress of Oral Implantologists and the American College of Forensic Dentistry. Correspondence should be addressed to Dr Flanagan at 1671 West Main Street, Willmantic, CT 06226 (e-mail: flanagan@neca.com).

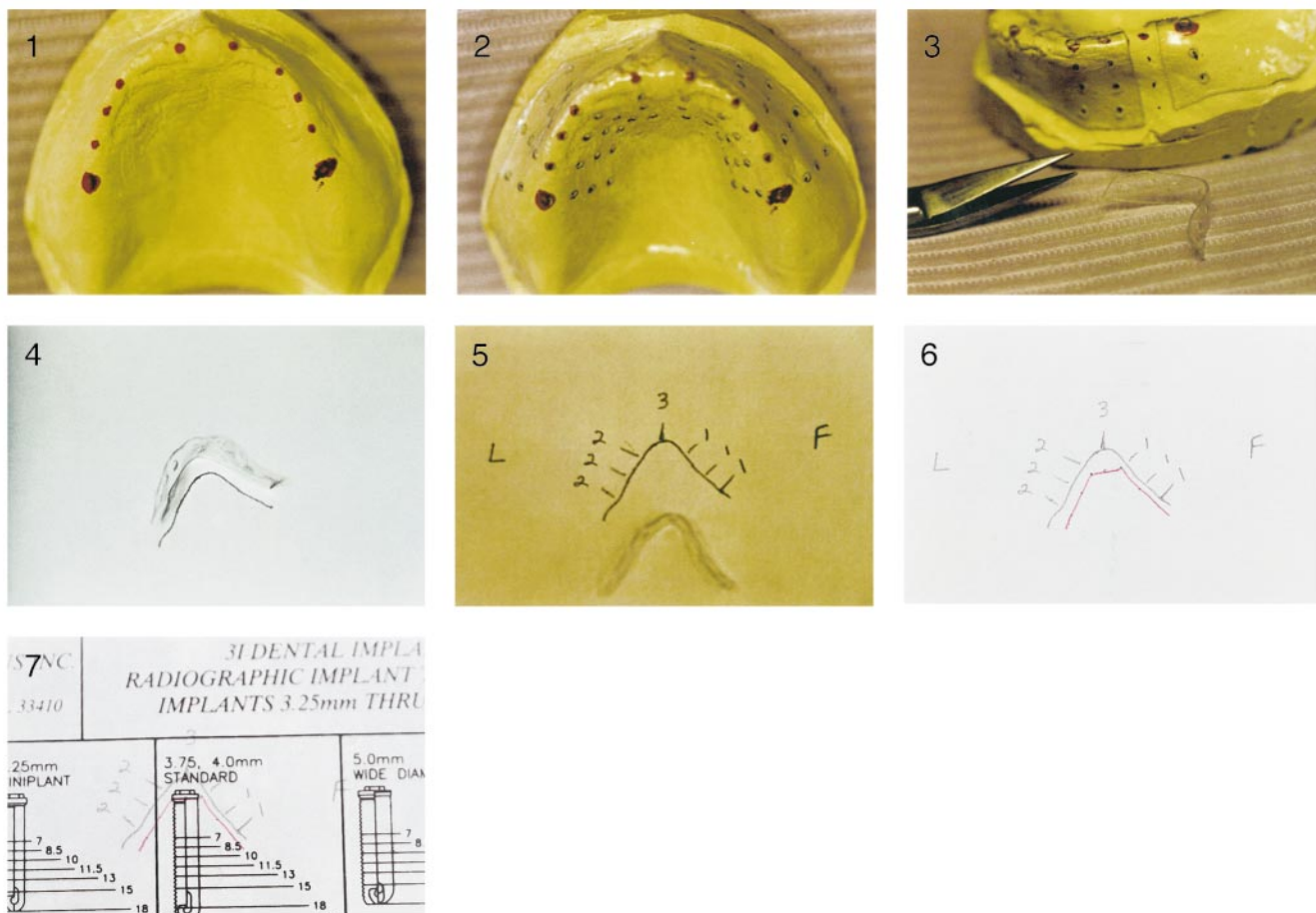


FIGURE 1. Tentative implant sites are marked on the cast.  
 FIGURE 2. Sounding access holes are drilled at the crest, facial and lingual.  
 FIGURE 3. The segments are cut from the shell.  
 FIGURE 4. A tracing is made of the ridge for each proposed site.  
 FIGURE 5. Sounding measurements are marked on the arch tracing.  
 FIGURE 6. The points are connected to show the form of the underlying bone.  
 FIGURE 7. An implant transparency is positioned over the tracing for sizing.

in line with the access hole at the crest of the ridge. The facial and lingual holes are spaced 2–3 mm apart, starting from the crestal hole. The sounding holes are not placed beyond the mucobuccal fold because this tissue can be very unstable and precludes an accurate sounding measurement (Figure 2). The shell provides a template or guide for bone sounding.

At this time, the patient is locally anesthetized, and the shell is placed on the patient’s edentulous ridge. Through the drilled access holes, each site is sounded with a periodontal probe down to hard bone. The measurements are noted for each site. An arch seg-

ment of the shell is carefully cut with scissors, mesial and distal, parallel to the facial lingual plane of the access holes and a releasing cut, resulting in an arched band of shell material. Each segment is cut carefully so as not to distort the segment and to provide an arch of the ridge at each site (Figure 3). The segment is laid on its side and a tracing is made of the ridge with a sharp pencil on the outer, nontissue side of each segment of each site (Figure 4). The noted soundings are marked at their corresponding positions on the arch of the ridge (Figure 5). The points are connected, yielding the bone contour at that site (Figure 6).

Various implant companies provide transparencies of their implants. The appropriate one of these can be placed over each site tracing to give an indication for sizing and position of the implant in that particular site (Figure 7). If a transparency is not available, the dimensions of a proposed implant can be drawn onto the tracing.

**DISCUSSION**

This method provides an arch tracing that demonstrates the contour of the underlying bone that can be used to approximate the fit and positioning of an implant at that particular location in a full arch edentulous scheme. Alter-

nate positions, augmentation, or angulations of the implant can be considered if a particular site is deemed inappropriate for implant placement. This method can be used relatively quickly to evaluate a particular arch in preparation for a computed tomography scan, bone augmentation, and implant surgery.

#### CONCLUSION

This is a preoperative method for evaluating available bone volume and contour at particular implant sites in the edentulous arch.

#### REFERENCES

1. Cranin AN, ed. *Atlas of Oral Implantology*. 2nd ed. St Louis, Mo: CV Mosby; 1999:81–124.
2. Renouard F, Rangert B, eds. *Risk Factors in Implant dentistry*. Chicago, Ill: Quintessence Publishing; 1999:13–142.
3. Kraut RA. Selecting the precise implant site. *J Am Dent Assoc*. 1991; 122(6):59–60.
4. Misch CE, ed. *Contemporary Implant Dentistry*. 2nd ed. St Louis, Mo: CV Mosby; 1999:33–237.
5. Verstreken K, Van Cleynenbreugel J, Marchal G, Naert I, Suetens P, Van Steenberghe D. Computer assisted planning of oral implant surgery: a three dimensional approach. *Int J Oral Maxillofac Implants*. 1996;11:806–810.
6. Todd AD, Gher ME, Quintero G, Richardson AC. Interpretation of linear and computed tomograms in the assessment of implant recipient sites. *J Periodontol*. 1993;64:1243–1249.
7. Flanagan DF. A method for estimating preoperative bone volume for implant surgery. *J Oral Implant*. 2000; 26:262–266.
8. Guerra LR, Finger IM. Principles of implant prosthodontics. In: Block MS, Kent JN, Guerra LR, eds. *Implants in Dentistry*. Philadelphia, Pa: WB Saunders; 1997:82–83.
9. Mericske-Stern R. Treatment concepts of the edentulous jaw. In: Lang NP, Karring T, Lindhe J, eds. *Proceedings of the 3rd European Workshop on Periodontology Implant Dentistry*. Berlin, Germany: Quintessence Publishing; 1999:376–407.
10. Cranin AN. Prosthetic options that influence implant selections. In: Cranin AN, ed. *Atlas of Oral Implantology*. 2nd ed. St Louis, Mo: CV Mosby; 1999:58–67.
11. Tarnow DP, Cho SC, Wallace SS. The effect of interimplant distance on the height of interimplant bone crest. *J Periodontol*. 2000;71:546–549.
12. Tarnow DP, Eskow RN. Preservation of implant esthetics: soft tissue and restorative considerations. *J Esthet Dent*. 1996;8(1):12–19.