

IMMEDIATE IMPLANTS IN FRESH POSTERIOR EXTRACTION SOCKETS: REPORT OF TWO CASES

Mohamed A. Maksoud, DMD

KEY WORDS

Dental implants
Immediate implants
Bone graft
Posterior implants

This article demonstrates the use of an implant insertion method for the posterior region. Following an atraumatic extraction of a posterior tooth, an immediate implant can be placed at the time of the extraction. A surgical technique that involves the insertion of the implant into the interseptal bone of a multirouted posterior tooth extraction socket in a manner to provide initial stabilization of the implant and partial fill of the extraction sockets is described. Bone graft and a membrane are also required to augment the remainder of the extraction socket and provide maximum bone fill around the implant. The advantages, disadvantages, and indications for the procedure are described.

INTRODUCTION

The high success rate of immediate placement of implants in fresh extraction sockets has been documented.¹⁻⁷ Immediate placement has evolved from a pilot study to a predictable procedure.¹⁸ Several investigators have reported a success rate 93.6% higher when these implants are followed for 2 and 5 years.³⁹ Brazily et al⁵ used animal models to compare 48 immediately inserted implants with conventionally placed implants. When both techniques were compared, there were no significant changes in bone-to-implant interface 7 months following the delivery of the prosthesis. The main advantage advocating the use of this procedure is the preservation of the integrity of the extraction socket for exact positioning of the implant fixture^{7,8}; it also shortens treatment time when compared with conventional implant protocol, which requires a healing period following the extraction prior to the

implant treatment. Although the osseointegration time has proved to be similar to that of conventional implants,¹⁰ the use of bone graft material and membrane can lengthen that time. Osseous healing of the implant showed a great deal of variability in the arch on which the implants are placed and on the original anatomy of the implant site.¹⁰ The two main difficulties of the procedure were reported to be the insufficient available bone for ideal implant placement and prolonged treatment time.^{7,11} Although the procedure has been successful and predictable in the anterior region or in a single-rooted extraction socket, fewer articles describe attempts to place an implant in the posterior region. The main reason is the topography of the resultant extraction socket, which is 2-rooted on mandibular and 3-rooted in a maxillary molar area.

Case 1

A 42-year-old white woman presented with tooth 30 showing a destructive

Mohamed A. Maksoud, DMD, is in private practice in Jacksonville, Florida. Address correspondence to Dr Maksoud at 9109 Baymeadows Road, Suite 3, Jacksonville, FL 32256.

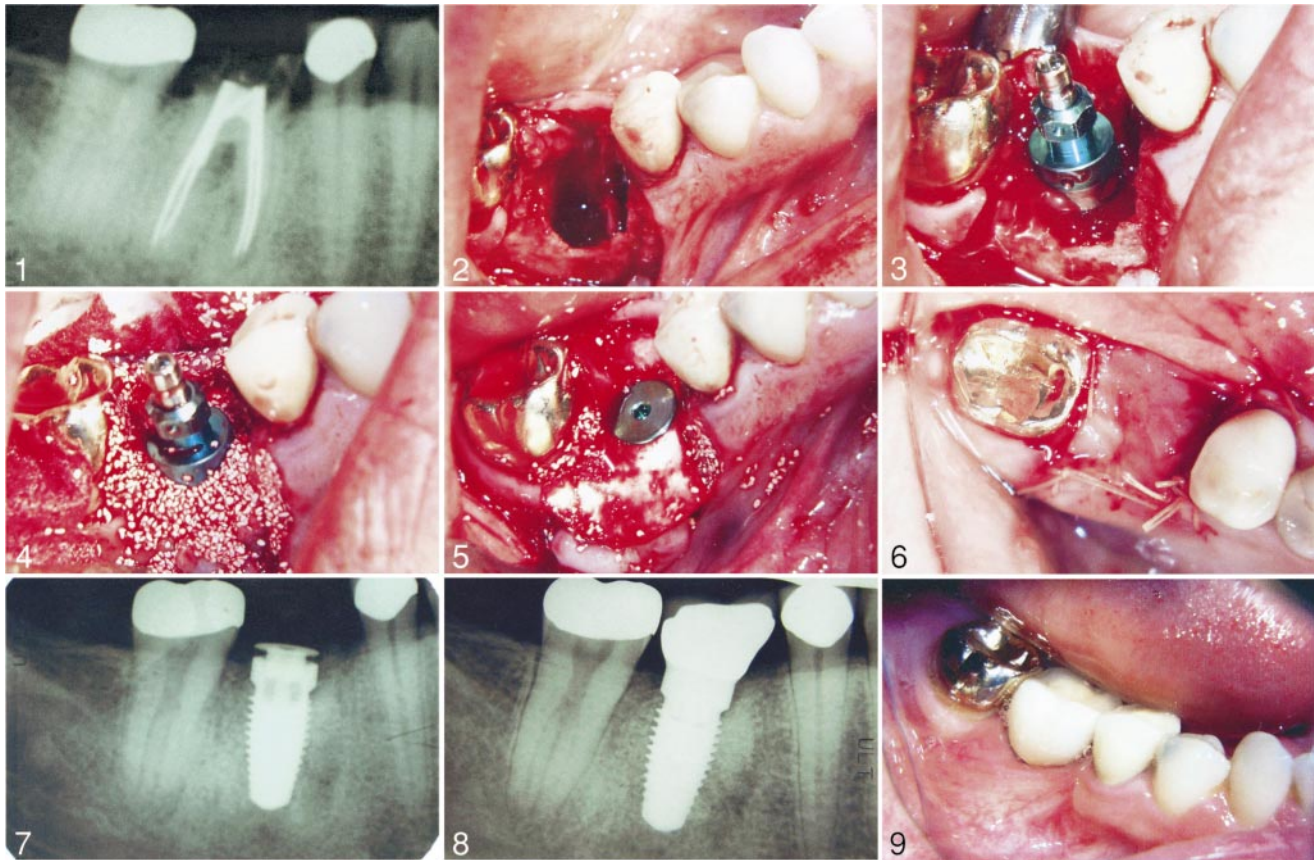


FIGURE 1. Radiographic view of case 1 preoperatively. FIGURE 2. Clinical view of the extraction socket after the extraction. FIGURE 3. Clinical view of the implant in place. FIGURE 4. Clinical view of the implant with the bone augmentation graft. FIGURE 5. The grafted material around the implant covered with the collagen membrane. FIGURE 6. The buccal and lingual flaps sutured. FIGURE 7. Radiographic view of the implant 3 months after the procedure. FIGURE 8. Radiographic view of the restored implant. FIGURE 9. Clinical view of the restored implant.

tooth structure at the gingival margin (Figure 1). The tooth was declared nonrestorable because of the massive tooth destruction. A crown-lengthening procedure was not indicated because of the close proximity to the furcation area. Her recommended treatment plan was an extraction of tooth 30 followed by an immediate placement of an endosseous implant. Review of the medical history revealed no significant medical problems or medications. The diameter and the length of the implant were selected using an overlay. The length was selected to extend 2 to 3 mm beyond the apices of the tooth to be extracted. Following local anesthesia, a fissure bur was used to section the tooth buccolingually, ensuring complete separation of the mesial and distal halves of the tooth. Us-

ing surgical elevators and forceps, the 2 halves were then retrieved as atraumatically as possible to preserve the integrity of the extraction socket. This was followed by buccal and lingual intrasulcular incisions with buccal vertical releasing incisions mesial and distal to tooth 30. Following the reflection of the flaps, the integrity of the extraction socket was then examined for any dehiscence or fenestrations (Figure 2). Using the supplied drills, the initial osteotomy was made with a surgical template as a guide into the interseptal bone, which was followed by the consecutive drills to the desired final diameter and length of the proposed implant. After verification of the position of the osteotomy in relation to the inferior mandibular canal, a 5 mm in diameter, 13 mm in length SteriOss (No-

ble BioCare, Yorba Linda, Calif) Replace Select implant was then inserted into position at the level of the bone crest (Figure 3). The gap between the implant body and the boundaries of the socket were then filled with bovine (Osteograft/N300, Geramed Dental, Lakewood, Colo) and mixed with freeze demineralized bone allograft (Allgro, Sulzer Calcitek, Carlsbad, Calif (Figure 4). It was then covered with a collagen membrane (BioMend, Sulzer Calcitek). The membrane was then secured into position using the cover screws of the implant (Figure 5). The edges of the two flaps were then trimmed to excise the epithelium and allow for healing of the flap edges. Using the surgical blade, the buccal flap was then undermined to allow for maximum manipulation and was then

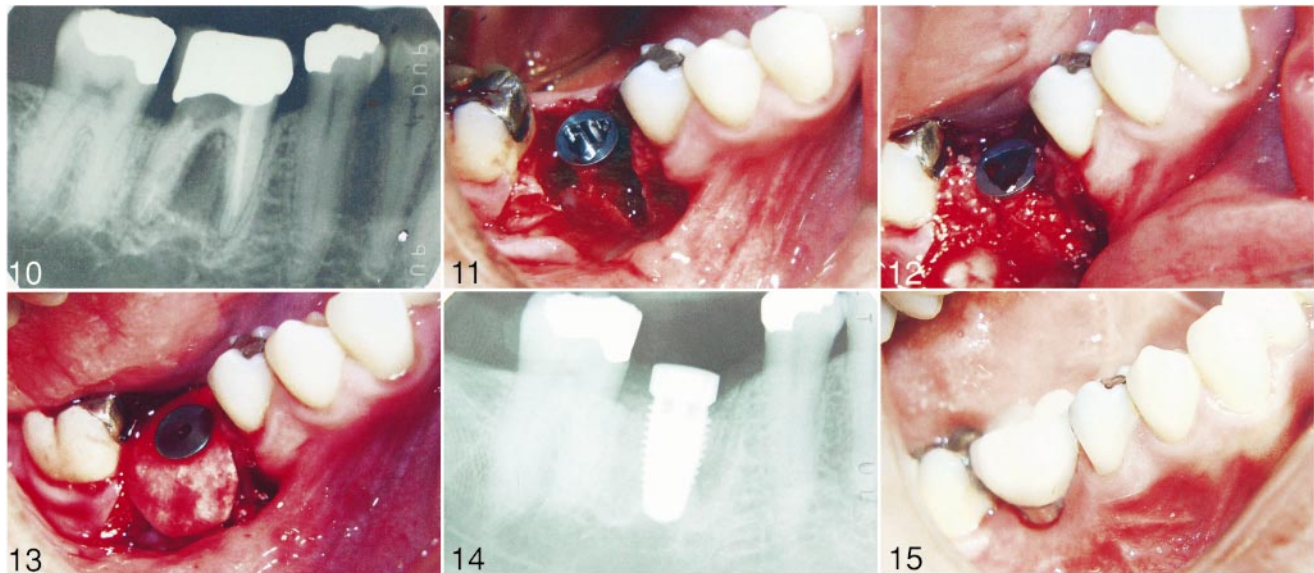


FIGURE 10. Radiographic view of case 2 preoperatively. FIGURE 11. Clinical view of the implant into the extraction socket. FIGURE 12. Clinical view of the implant with the bone augmentation material. FIGURE 13. Clinical view of the collagen membrane covering the graft material. FIGURE 14. Radiographic view of the implant 3 months after the procedure. FIGURE 15. Clinical view of the restored implant.

sutured to the lingual flap using Vicryl sutures in an interrupted manner (Figure 6). Following the procedure, the patient has shown uneventful healing without membrane exposure. Three months following the procedure, a radiograph was taken, which showed complete resolution of the extraction socket through bone fill with a slight resorption of the crestal bone (Figure 7). This was followed by complete restoration of the implant crown (Figures 8 and 9).

Case 2

A 56-year-old white man presented with tooth 30 showing severe distal caries underneath a full crown with a large radiolucent area between the mesial and the distal roots (Figure 10). The tooth was nonrestorable because of the severe caries extension and the radiolucent area. The patient presented for extraction of tooth 30 and replacement with an immediate implant. Review of the medical history revealed no abnormal findings that would disqualify him from having an implant treatment. Following local anesthesia, the full crown was removed with no complication. A fissure bur was then used to section the tooth buccolingually,

making sure complete separation of the mesial and distal roots was achieved. This was followed by extraction of both mesial and distal roots without complications. A full-thickness mucoperiosteal flap was reflected at the buccal and the lingual with a mesial and distal vertical releasing incisions. Following the extraction, granulation tissue was removed from the extraction socket, leaving almost 80% of the extraction socket walls intact. At this point, drilling was established using a surgical stent to create an osteotomy that would eventually receive a 5-mm SteriOss Replace Select implant 13 mm in length. The implant was inserted engaging the buccal, lingual, and interseptal bone (Figure 11). The void between the implant body and the extraction socket was filled with autogenous bone harvested from the buccal plate of bone of tooth 30 (Figure 12). This was covered with collagen BioMend membrane and the flap was sutured to the lingual after releasing the buccal flap with an undermining incision (Figure 13). The patient was followed for 3 months following the insertion of the implant and showed no complications with the healing. A peri-

apical radiograph was taken at that point, which revealed complete bone fill of the extraction socket plus complete integration of the grafted bone with the implant body (Figure 14). This was also followed by restoration of the implant crown (Figure 15).

DISCUSSION

Clinical studies on the placement of immediate implants in fresh extraction sockets have revealed predictable results and a very easy-to-follow technique.^{8,12-14} Histological studies have also shown similar predictable results.^{15,16} However, anterior placement of immediate implants is more predictable because of the remaining configuration of the extraction socket that is compatible with that of the commercially available implant diameters.

Due to the possibility of loss of the remaining socket walls in a posterior extraction site and the width of the extraction socket plus the number of the extraction sockets, posterior immediate implants became somehow a challenge to the surgeon. Skillful engagement of the interseptal bone is the key for the initial stabilization of the implant; however, if that initial stabilization can-

not be achieved, augmentation of the extraction socket will need to be completed at that time, and the implant can be inserted at a later date. Although the 2 cases reported were in the mandible, the maxillary molar extraction socket should provide similar results.

The use of the bovine, allograft bone graft material, and the membrane is the sole opinion of the author because of a repetitive success rate using that combination in multiple cases. Several researchers have studied the immediate implant insertion with or without a membrane with superior results when a membrane was used.¹⁷⁻²⁰ Simon et al²¹ studied the use of different filling materials with bone and membrane on human models and discovered that predictable bone formation was produced when autogenous bone was used. Also, they showed integrated bone around the titanium implant surfaces. Immediate implants have been documented in the literature by Rosenquist,⁹ who showed immediate implants followed for 67 months with a mean success rate of 92.6% in implants that replaced teeth extracted because of periodontitis and 95.84% for other reasons. Although the main reason for the extraction in these cases was not due to periodontal disease, the remaining bone quality and quantity will dictate the use of either immediate or conventional implants placement.

In conclusion, the above described procedure is advised in cases where implant placement is planned and an area of the extraction socket configuration can be preserved and will not be compromised by traumatic extraction or an existing chronic infection. The patient should be aware that the fore-closure of that procedure is inevitable if prognosis of the implant success is compromised. The 2 documented cases are among several similar cases that represent a procedure that can be beneficial and predictable.

REFERENCES

- Schwartz-Arad D, Grossman Y, Chaushu G. The clinical effectiveness of implants placed into fresh extraction sites of molar teeth. *J Periodontol.* 2000; 71:839-844.
- Cornelini R. Immediate transmucosal implant placement: a report of 2 cases. *Int J Periodont Rest Dent.* 2000; 20:199-206.
- Tolman D, Keller E. Endosseous placement immediately following dental extraction and alveoplasty: preliminary report with 6-year follow-up. *Int J Oral Maxillofac Implant.* 1991;6:24-26
- Mazor Z, Peleg M, Redlich M. Immediate placement of implants in extraction sites of maxillary impacted canines. *J Am Dent Assoc.* 1999;12:1767-1770.
- Barzilay I, Greser GN, Iranpour B, Natiella N Jr. Immediate implantation of a pure titanium implant into an extraction pocket: report of a pilot procedure. *Int J Oral Maxillofac Implant.* 1991;6:277-284.
- Krump JL, Barnett BG. The immediate implant: a treatment alternative. *Int J Oral Maxillofac Implant.* 1991; 6:19-23.
- Lazzara R. Immediate implant placement into extraction sites: surgical and restorative advantages. *Int J Periodont Rest Dent.* 1989;9:333-343.
- Parel SM, Triplett RJ. Immediate fixture placement: treatment planning alternative. *Int J Oral Maxillofac Implant.* 1990;5:337-345.
- Rosenquist B, Grenthe B. Immediate placement of implant into extraction sockets: implant survival. *Int J Oral Maxillofac Implant.* 1996;11:205-209.
- Barzilay I, Greser GN, Iranpour B, Proskan HM. Immediate implantation of a pure titanium implant into extraction socket of macaca fascicularis. Part I. Clinical and radiographic assessment. *Int J Oral Maxillofac Implant.* 1996;11:489-497.
- Arlin M. Immediate placement of dental implants into extraction sockets: surgically related difficulties. *Oral Health.* 1993;83:23-24.
- Ashman A. An immediate tooth root replacement: implant cylinder and synthetic bone combination. *J Oral Implantol.* 1990;16:28-38.
- Fugazzotto PA. Immediate implant placement and GPR in humans: a case report and histologic evaluation. *Int J Periodont Rest Dent.* 1999;19:457-463.
- Brunel G, Benque E, Elharar F, et al. Guided bone regeneration for immediate nonsubmerged implant placement using bioabsorbable materials in beagle dogs. *Clin Oral Implant Res.* 1998;9:303-31.
- Parr GR, Steflik DE, Sisk AL. Histomorphometric and histologic observation of bone healing around immediate implants in dogs. *Int J Oral Maxillofac Implant.* 1993;8:534-540.
- Wilson TG Jr, Schenk R, Buser D, Cochran D. Implants placed in immediate extraction sites: a report of histologic and histometric analysis of human biopsies. *Int J Oral Maxillofac Implant.* 1998;13:333-341.
- Kohal RJ, Mellas B, Hurzeler MB, et al. The effects of guided bone regeneration and grafting on implant placed into immediate extraction socket: an experimental study in dogs. *J Periodontol.* 1998;69:927-937.
- Schwartz D, Chaschuscu G. Immediate implant placement: a procedure without incision. *J Periodontol.* 1998;69:743-750.
- Gher ME, Quintero G, Assad D, et al. Bone grafting and guided bone regeneration for immediate implants in humans. *J Periodontol.* 1994;65:881-891.
- Gher ME, Quintero G, Sandifer JP, et al. Combined dental implants and guided tissue regeneration therapy in humans. *Int J Periodont Rest Dent.* 1994;14:332-347.
- Simion M, Dahlin C, Trisi P, Piatelli A. Qualitative and quantitative comparative study on different filling materials used in bone tissue regeneration. A controlled clinical study. *Int J Periodont Rest Dent.* 1994;14:199-215. ■