

ALTERNATIVE TO THE INFERIOR ALVEOLAR NERVE BLOCK ANESTHESIA WHEN PLACING MANDIBULAR DENTAL IMPLANTS POSTERIOR TO THE MENTAL FORAMEN

Alfred A. Heller, DDS, MS
Wesley E. Shankland II, DDS, MS, PhD

KEY WORDS

Local anesthesia
Mandible
Implant
Inferior alveolar
Paresthesia
Mental nerve
Infiltration

Local anesthesia block of the inferior alveolar nerve is routinely taught throughout dental education. This commonly used technique eliminates all somatosensory perception of the mandible, mandibular teeth, floor of the mouth, ipsilateral tongue, and all but the lateral (buccal) gingivae. Generally, the dentist or surgeon desires these structures to be anesthetized. However, in the placement of mandibular implants, it may be useful for the patient to be able to sense when the inferior alveolar nerve is in danger of being damaged, possibly producing permanent paresthesia. In this article, the technique of mandibular infiltration prior to mandibular implant placement in the mandible is discussed.

INTRODUCTION

Inferior alveolar anesthesia has been used effectively to facilitate all types of dental procedures.¹ Total inferior alveolar nerve (IAN) block anesthesia assures patient comfort during surgical placement of mandibular implants, giving the dentist the opportunity to perform necessary surgical procedures in a pain-free environment.

Linkow² reported a 7-year study of placing blade implants in 1970. Conventional block anesthesia of the IAN was used because most mandibular dental treatments required total anesthesia of this large nerve for restorative as well as surgical procedures. Dentists

have been highly trained to effectively administer this anesthetic block.

Three major postoperative complications may occur with the use of block anesthesia of the IAN when placing mandibular implants: (1) prolonged mandibular anesthesia, during which time the patient may injure his or her tongue or lip in a variety of ways; (2) systemic toxicity from iatrogenic, intra-arterial injection of local anesthetic solution; and, most importantly when placing mandibular implants, (3) injury to the inferior or mental nerves, unbeknown to the patient or doctor until after the effects of the block anesthesia have subsided.

Alfred A. Heller, DDS, MS, is in private practice in Westerville, Ohio. Address correspondence to Dr Heller at 145 Green Meadows Drive, Westerville, OH 43081.

Wesley E. Shankland II, DDS, MS, PhD, is in private practice in Columbus, Ohio.

By contrast, mandibular infiltration has been routinely avoided because of its questionable effectiveness. However, this attitude has generally been based on conjecture and anecdotal information rather than on scientific study.

This article presents information concerning the successful use of mandibular infiltration anesthesia for the placement of thousands of mandibular dental implants, producing not one case of permanent inferior alveolar or mental nerve injury. Three patients exhibit a localized permanent parathesia of the lower lip measuring 1.5 cm × 1.5 cm in diameter both of the exterior and interior surfaces. All experience awareness when probing the buccal gingival anterior tissue on the affected side of the mouth.

METHODS AND MATERIALS

The first author has utilized mandibular infiltration since 1969, placing over 8000 dental implants in the mandible. One carpule (1.8 mL) of lidocaine is deposited in the lingual tissue and one carpule of lidocaine is deposited in the buccal tissue (see Figures 1 and 2). After approximately 5 minutes allowing for anesthetic effect, one carpule of lidocaine is deposited, taking care to place the anesthetic solution just under the buccal and lingual periosteum, applying enough pressure with the solution to raise the tissue in a bubble fashion (see Figures 3 and 4). It is suggested that subperiosteal penetration of the needle be spaced every 15 to 20 mm. With total tissue anesthesia, the operator has the freedom to reflect the tissue and drill into the receptor bone with little fear that the patient will experience pain with the procedure.

Before the surgical treatment is started, a diagnostic periapical x-ray is obtained utilizing the long-cone technique.³ The x-ray is placed parallel to the occlusal plane and taken at 90 degree angulation to measure the exact height of bone superior to the IAN canal housing. Periapical x-rays taken at right angles to the occlusal plane minimize distortion of alveolar bone height

(Figure 5). Panoramic radiographs inherently have a distortion factor of 12 to 30%, which makes such a radiographic view a poor diagnostic technique for accurately and safely determining exact amounts of available bone for mandibular implant placement.⁴

If the periapical x-ray shows there to be approximately 14 mm of available bone above the IAN canal, it is suggested that the surgeon place a pilot drill to a depth of 8 to 10 mm and take a periapical x-ray with the surgical pilot drill in place (Figure 6). The Ergonom-X (x-ray packet; Salvin Co, Charlotte, NC), which contains both developer and fixer in the same packet as the film, is recommended because it can be sterilized and used in a sterile surgical setting. After exposure, the chemicals are pushed into an enclosed area housing the exposed film. This allows for a total sterile surgical environment to be maintained as well as producing a diagnostic film in 50 seconds.

Measurement of the remaining available bone inferior to the pilot drill is then obtained and the doctor may proceed to a depth of adequate length to within 1 to 2 mm of the IAN canal. Another periapical radiograph could be taken at final drill depth if the surgeon has a question about the exact location of the IAN canal. An immediate postoperative x-ray showing implant placement is highly recommended (Figure 7).

If the patient experiences sensitivity during the preparation of the implant receptor site, the buccal and lingual tissues are again injected with subcutaneous anesthesia, forcing anesthetic solution between the periosteum and the underlying bone. After waiting approximately 2 to 3 minutes, the receptor site is reentered with a metal right-angled explorer to the depth of the last drill that elicited pain. The doctor probes in all directions within the receptor site, attempting to elicit pain. If no pain is experienced, the proper width and depth of drill necessary for an implant of sufficient size and shape

to ensure a good prosthetic result is placed in the bone.

Do not inject into the bone receptor site since the anesthetic solution could penetrate the bony walls of the IAN canal, anesthetizing the inferior alveolar nerve, thus in effect causing total block anesthesia. Even with intravenous sedation, patients are able to tell the surgeon that they have sensitivity when the IAN canal is encroached upon.

When there is only 6 to 8 mm of available bone superior to the IAN bony canal, a pilot drill is placed into the receptor implant site at a desired, premeasured depth. A periapical x-ray is then taken at 90 degrees to determine the exact height of remaining receptor bone above the IAN canal. Often, the drill can be intentionally placed on top of the bony canal to utilize the most available bone. Since the patient does not have nerve block anesthesia, the patient can tell verbally or with body movement if they are feeling sensitivity from the receptor site bone drilling.

If the patient expresses perceived pain from the drilling at a certain depth, always believe the patient, even if the patient is under the influence of deep intravenous anesthesia (Figure 2).

Patients are reevaluated in 2 weeks at suture removal appointments and then at 2-, 4-, and 6-month intervals. Periapical radiographs are taken to follow the progress of osteointegration.

RESULTS

Over 8000 mandibular implants have been placed using infiltration anesthesia over 30 years. Only three patients have permanent paresthesia (numbness), about 1.5 cm × 1.5 cm in diameter, of the lower lip on both the exterior and interior surfaces. All three patients can detect pin pricking on the buccal surface tissue in the cuspid to central region. None of the three patients feel the anesthetized area is objectionable nor does the loss of sensation alter their routine of daily living.

Approximately 85 to 100 patients reported a transient paresthesia during

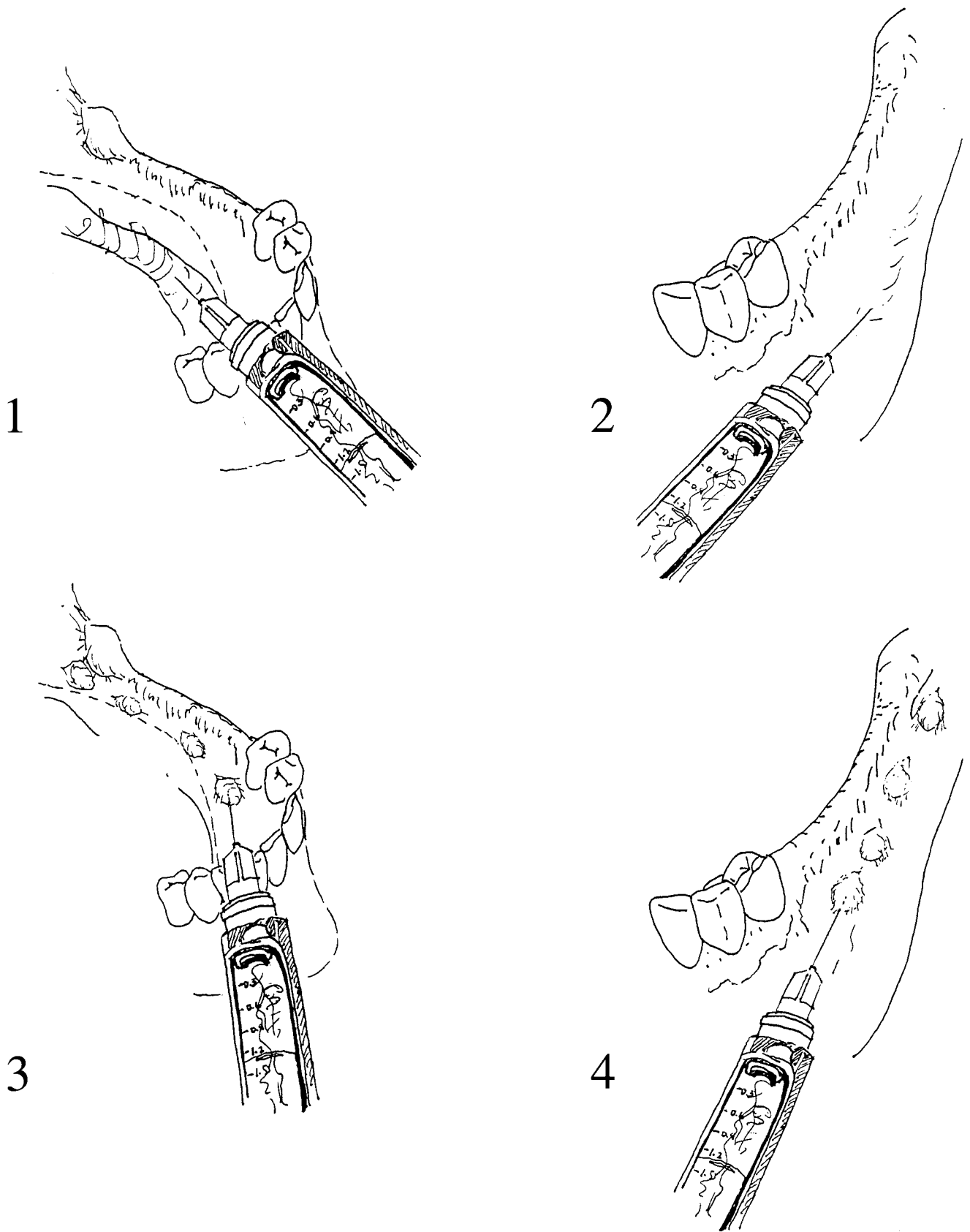


FIGURE 1. Lidocaine infiltrates into the lingual vestibule.
FIGURE 2. Lidocaine infiltrates into the buccal vestibule.
FIGURES 3 AND 4. Lidocaine injection under the periosteum to raise the tissue.

the first 3 to 6 months following implant placement surgery. Most of those transient loss-of-feeling patients recovered within the first 3 to 4 weeks of surgery.

DISCUSSION

The most common block anesthetic technique of the IAN was first described by Halstead nearly a century ago and bears his name. In this technique, the inferior alveolar nerve is approached in the pterygomandibular space via an intraoral route at the mandibular foramen as the nerve enters the mandible. This commonly taught procedure has a success rate of only 71 to 87%.^{5,6}

The Gow-Gates method of mandibular anesthesia, which was introduced in 1973,⁷ utilizes both extraoral and intraoral landmarks that are coordinated by two reference planes. Briefly, the patient is instructed to open as wide as possible and the contents of the anesthetic carpule are deposited in the upper portion of the pterygomandibular space just anterior and inferior to the junction of the neck and head of the mandibular condyle. Producing a slower onset of anesthesia than does the Halstead technique, the Gow-Gates efficacy was reported by Sisk⁷ as nearly 95% after 10 minutes. Again, profound mandibular anesthesia may be achieved, but such complete anesthesia, which eliminates the patient's ability to alert the dental surgeon concerning possible nerve injury, is not desired when placing mandibular implants.

Vazirani⁸ in 1960 and Akinosi⁹ in 1977 both described a mandibular block technique now known as the Akinosi technique. Unlike the Halstead or Gow-Gates technique, the patient's mouth is closed with teeth in occlusion when the Akinosi method is administered. The anesthetic is deposited in the middle portion of the pterygomandibular space. Like the two other forms of block anesthesia of the IAN, the Akinosi produces total block anesthesia and, like the others, is considered by these authors as a less desirable meth-

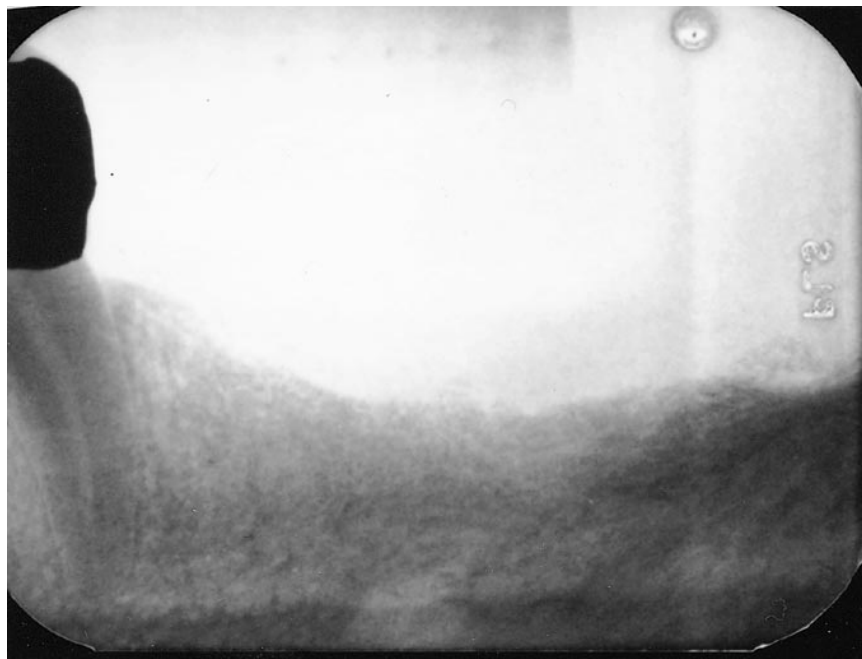

FIGURE 5. Periapical x-ray taken at right angle.

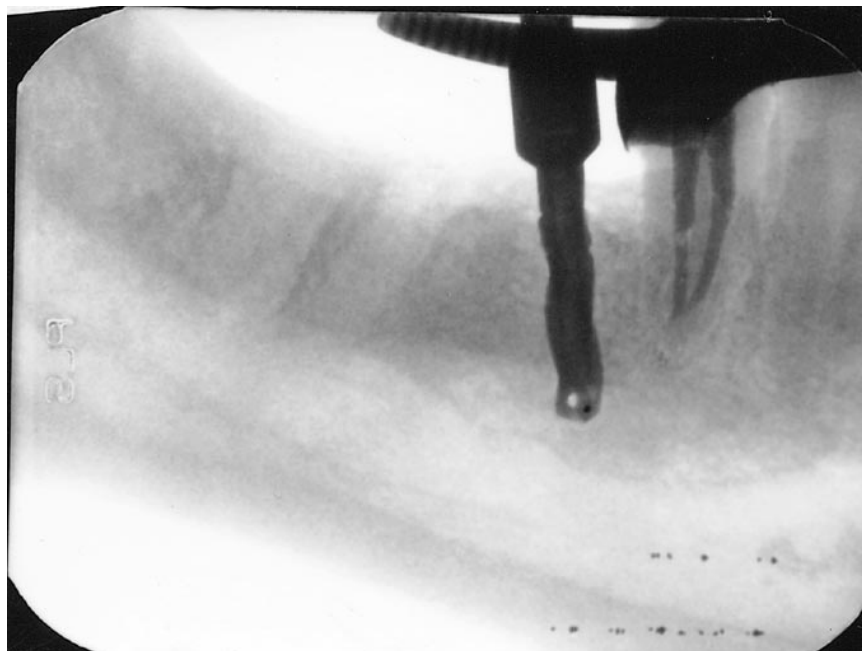


FIGURE 6. Periapical x-ray with surgical pilot drill in place.

od for local anesthesia administration when placing dental implants. Success rates of 77%¹⁰ to 93%⁵ have been reported.

The method described above has been used successfully by the primary author (AH) since 1969. Over 11000 dental implants (both root forms and

blades) have been successfully placed, using infiltration anesthesia without permanent injury to the inferior alveolar or mental nerves. Some patients experienced temporary paresthesia due to implant drill or bur trauma during preparation of the implant receptor sites, but in all cases, this transient par-

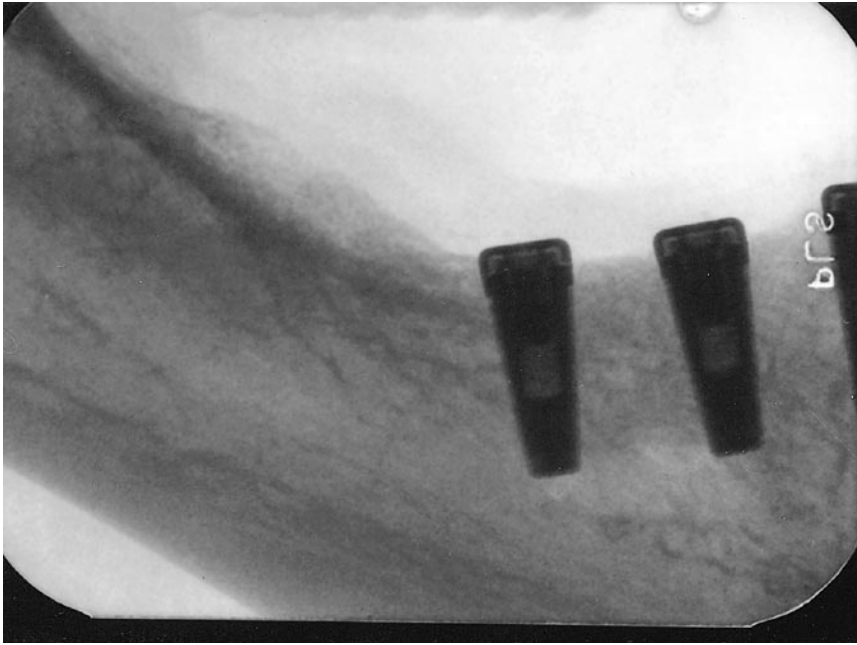


FIGURE 7. Postoperative x-ray of implant placement.

esthesia resolved within 5 months of the surgical procedure(s).

These successful results are not surprising. Infiltration anesthesia, using a dental syringe and small-gauge needle (27 or 30 gauge), has been proposed for routine operative dental procedures by several authors,¹¹⁻¹⁸ especially with pediatric patients. These procedures have included restorative procedures, endodontic procedures, and even extraction of teeth.

Intraosseous injection of the inferior alveolar nerve for localized mandibular anesthesia has also been proposed by several investigators.¹⁹⁻²¹ Although this technique provides excellent local and confined mandibular anesthesia, the potential of damaging the inferior alveolar and mental nerves is similar to that of a total block of the IAN. Intraosseous anesthesia is quite helpful in differential diagnosis of orofacial pain problems originating in a specific tooth or the mandible,²² but the iatrogenic injury of mandibular nerves disqualifies this technique, in the present authors' clinical opinion, from its use in mandibular anesthesia for implant placement.

Recently, a bioadhesive delivery sys-

tem as an alternative to both block and infiltration anesthesia has been suggested.¹⁵ Although effective enough to permit nonpainful extraction of teeth in 81.63% of cases attempted,¹⁵ patients complained of a bitter taste. In addition, adequate anesthesia for surgical procedures required 15 to 20 minutes, while infiltration required only 3 to 4 minutes. Further, the anesthetic effects of infiltration are more controllable and are not as diffuse as with a bioadhesive system.

Anatomically, there is no question concerning the efficacy of maxillary infiltration anesthesia. The maxillary alveolus is thin and porous in comparison with that of the mandible. Although given lectures on the technique of giving a second division block of the trigeminal nerve for maxillary block anesthesia, dental students rarely perform this rather difficult procedure and instead are instructed in proper infiltration of the maxilla. However, the present authors disagree with the assertion that the mandibular block is the one type of mandibular anesthesia that should be used during implant procedures.

Mandibular osseous anatomy has

been considered too dense and too thick by anatomists and dentists alike for infiltration techniques since the advent of local anesthesia at the beginning of the 20th century. In theory, the dense, compact bone of the medial (lingual) and lateral (buccal) surfaces of the mandible do not permit diffusion of local anesthetic into the medullary spaces of the mandible, thus not prohibiting depolarization of the mandibular nerves, chiefly the inferior alveolar. However, we have not found that to be true clinically and, in the gross anatomy laboratories, numerous unnamed mandibular foramina have been observed. This finding corroborates those of several other investigators. For example, Sutton²³ found 2449 accessory or unnamed foramina in 300 dried human mandibles. Madeira et al²⁴ reported the presence of accessory foramina in the human mandibular symphysis region in 87.3 to 96.2% of specimens studied. In addition, Pogrel et al²⁵ reported that branches of the mental nerve reenter the labial (lateral) surface of the mandible to supply lower incisors.

Many of those who use block anesthesia of the IAN when placing implants maintain that, during surgical procedures, the inferior alveolar canal can be felt or sensed and that therefore careful osseous surgery will avoid violation of this large canal and its contents. Unfortunately, one cannot assume any integrity of the inferior alveolar canal. Oliver²⁶ reported that, in 60% of dissected specimens, the mandibular canal contained the entire inferior alveolar nerve. However, in the remaining 40%, the inferior alveolar nerve spread out and a distinct canal was not present. Carter and Keen²⁷ confirmed Oliver's findings.

In addition, Nortje et al,²⁸ Carter and Keen,²⁷ and others^{29,30} have demonstrated, using human cadaver dissections, that the inferior nerve is often not a single nerve but a vast plexus of various conformations. Again, block anesthesia of the IAN would totally anesthetize all these plexes, whereas infil-

tration would still permit the patient to inform the doctor if his or her surgical procedures were stimulating branches of the inferior alveolar plexus.

Most interesting were the findings of Schejtmán et al,³¹ Langlais et al,³² and Barker and Lockett.³³ Shankland³⁴ corroborated these findings. All these researchers reported discovering multiple mandible accessory foramina in the ramus and posterior mandibular regions, which, according to their observations, transmitted aberrant or additional branches of the IAN. Most of these nerves would not be anesthetized by any of the three types of IAN blocks, thereby making block anesthesia inadequate. On the other hand, infiltration anesthesia would not only provide for anesthesia of the unusual presentations of trigeminal branches but also allow for adequate yet safe anesthesia for the placement of mandibular implants because the major portions of the IAN would not be blocked.

CONCLUSIONS

Based on our observations and clinical experience, we conclude the following:

- (1) Infiltration anesthesia is safe and effective when used for surgical placement of mandibular implants.
- (2) Although providing adequate local anesthesia, infiltration does not totally block the inferior alveolar or mental nerves, thereby permitting the patient, whether sedated or not, to alert the surgeon if either of these nerves are at risk of being damaged in the surgical procedure(s).
- (3) Infiltration anesthesia tremendously reduces the risk of parathesia when compared with IAN block anesthesia. Thus, this method could be utilized safely as an alternate method of mandibular block anesthesia.

REFERENCES

1. Peterson LJ. *Contemporary Oral and Maxillofacial Surgery*. St Louis, Mo: Mosby; 1988.

2. Linkow LI. Statistical analysis of 173 implant patients. *Dent Clin N Am*. 1970;14:185.

3. Weine FS. *Endodontic Therapy*. St Louis, Mo: Mosby; 1972.

4. Klinge B. Location of the mandibular canal: comparison of macroscopic findings, conventional radiography and computed tomography. *Int J Oral Maxillofac Implants*. 1989;4:327-332.

5. Malamed SF. *Handbook of Local Anesthesia*. 3rd ed. St Louis: Mosby-Year Book; 1990.

6. Gow-Gates GA. Mandibular conduction anesthesia: a new technique using extraoral landmarks. *Oral Surg Oral Med Oral Pathol*. 1973;36:321-328.

7. Sisk AL. Evaluation of the Gow-Gates mandibular block for oral surgery. *Anesth Prog*. 1985;32:143-146.

8. Varirani SJ. Closed mouth mandibular nerve block: a new technique. *Dent Digest*. 1960;66:10-13.

9. Akinosi SJ. A new approach to the mandibular nerve block. *Br J Oral Surg*. 1977;15:83-87.

10. Todorovic L, Stajcic Z, Petrovic V. Mandibular versus inferior dental anesthesia: clinical assessment of 3 different techniques. *Int J Oral Maxillofac Surg*. 1986;15:733-738.

11. Wright GZ, Weinberger SJ, Marti R. The effectiveness of infiltration anesthesia in the mandibular primary molar region. *Pediatr Dent*. 1991;13:278-283.

12. Dudkiewicz A, Schwartz S, Lali-berte R. Effectiveness of mandibular infiltration in children using the local anesthetic ultracaine (articaine hydrochloride). *J Can Dent Assoc*. 1987;53:29-31.

13. Schwartz HC. Local anesthesia. *J Am Dent Assoc*. 1974;89:157-163.

14. Sharaf AA. Evaluation of mandibular infiltration versus block anesthesia in pediatric dentistry. *ASDC J Dent Child*. 1997;64:276-281.

15. Oulis CJ, Vadiakas GP, Vasilopoulou A. The effectiveness of mandibular infiltration compared to mandibular block anesthesia in treating primary molars in children. *Pediatr Dent*. 1996;18:301-305.

16. Meldrum A. Infiltration analge-

sia of primary mandibular molars. *N Z Dent J*. 1992;88:64.

17. Donohue D, Garcia-Godoy F, King DL, Barnwell GM. Evaluation of mandibular infiltration versus block anesthesia in pediatric dentistry. *J Dent Child*. 1993;60:104-106.

18. Taware CP, Mazumdar S, Pendharkar M, Adani MH, Devarajan PV. A bioadhesive delivery system as an alternative to infiltration anesthesia. *Oral Surg Oral Med Oral Pathol Oral Radiol Endodontol*. 1997;84:609-615.

19. Dunbar D, Reader A, Nist R, Beck M, Meyers WJ. Anesthetic efficacy of the intraosseous injection after an inferior alveolar nerve block. *J Endodontol*. 1996;22:481-486.

20. Coggins R, Reader A, Nist R, Beck M, Meyers WJ. Anesthetic efficacy of the intraosseous injection in maxillary and mandibular teeth. *Oral Surg Oral Med Oral Pathol Oral Radiol Endodontol*. 1996;81:634-641.

21. Reisman D, Reader A, Nist R, Beck M, Weaver J. Anesthetic efficacy of the supplemental intraosseous injection of 3% mepivacaine in irreversible pulpitis. *Oral Surg Oral Med Oral Pathol Oral Radiol Endodontol*. 1997;84:676-682.

22. Shankland WE. Craniofacial pain syndromes that mimic temporomandibular joint disorders. *Ann Acad Med Singapore*. 1995;24:83-112.

23. Sutton RN. The practical significance of the mandibular accessory foramina. *Aust Dent J*. 1974;19:167-173.

24. Madeira MC, Percinoto C, Silva MGM. Clinical significance of supplementary innervation of the lower incisor teeth: a dissection study of the mylohyoid nerve. *J Prosthet Dent*. 1978;46:608-614.

25. Pogrel MA, Smith R, Ahani R. Innervation of the mandibular incisors by the mental nerve. *J Oral Maxillofac Surg*. 1997;55:961-963.

26. Oliver E. Le canal dentaire inferieur et son nerf chez l'adulte. *Ann Anat Path Anat Norm Md Chir*. 1927;4:975-987.

27. Carter RB, Keen EN. The intra-mandibular course of the inferior alveolar nerve. *J Anat*. 1971;108:433-440.

28. Nortje CJ, Farman AG, Grotepass

FW. Variations in the normal anatomy of the inferior dental (mandibular) canal: a retrospective study of panoramic radiographs from 3612 routine dental patients. *Br J Oral Surg.* 1977;15:55-63.

29. Starkie C, Stewart D. The intra-mandibular course of the inferior alveolar dental nerve. *J Anat.* 1931;65:319-323.

30. Anderson LC, Kosinski TF, Men-

tag PJ. A review of the intraosseous course of the nerves of the mandible. *J Oral Implant.* 1991;17:394-403.

31. Schejtman R, Devoto FCH, Arias NH. The origin and distribution of the elements of the human mandibular retromolar canal. *Arch Oral Biol.* 1967;12:1261-1267.

32. Langlais RP, Broadus R, Glass BJ. Bifid mandibular canals in pano-

ramic radiographs. *J Am Dent Assoc.* 1985;110:923-926.

33. Barker BCW, Lockett BC. Multiple canals in the rami of a mandible. *Oral Surg Oral Med Oral Pathol.* 1972;34:384-389.

34. Shankland WE. The position of the mental foramen in Asian Indians. *J Oral Implant.* 1994;10:118-123. ■