

# AN INCISION DESIGN TO PROMOTE A GINGIVAL BASE FOR THE CREATION OF INTERDENTAL IMPLANT PAPILLAE

Dennis Flanagan, DDS

## KEY WORDS

Dental implants  
Incision design  
Interdental

A surgical flap method that promotes reproduction of the interdental papilla for endosseous dental implant treatment is described. This incision design allows lifting of the gingiva without disrupting the periosteum and its blood supply.

## INTRODUCTION

When preparing to place a dental implant in a proposed edentulous site, it is important to consider reproduction of the periodontal architecture in the aesthetic zone.<sup>1-4</sup> In the edentulous site, the remaining attached gingiva should be adequate to provide periodontal support for the implant restoration.<sup>5</sup> Reproduction of the interdental papillary architecture may be an important part of the appearance of the resulting implant treatment.<sup>6</sup> What follows is a method and design of the surgical flap to promote reproduction of the interdental papilla for endosseous dental implant treatment.

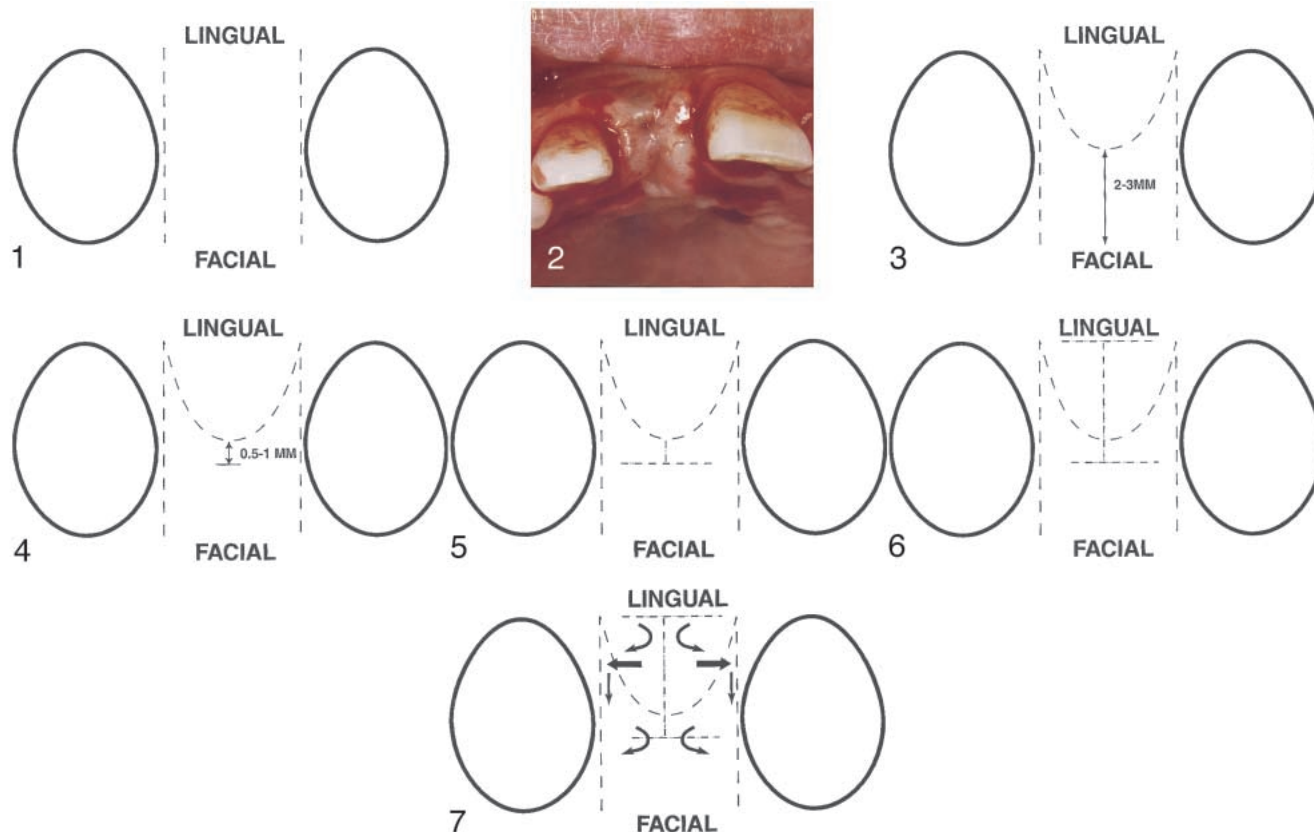
## MATERIALS AND METHODS

First, study casts, radiographs, patient, and site evaluations are made in the usual fashion in preparation for dental implant surgery.<sup>7-9</sup> A surgical guide can be constructed.<sup>10-12</sup> The implant should be placed so that the facial aspect is lingual to the facial line aspects of the adjacent teeth to allow for an appropriate emergence profile.<sup>2</sup> The im-

plant platform should be 2 to 4 mm apical to the cemento-enamel junction of the adjacent teeth.<sup>2</sup> The tooth to implant space at the mesial and distal should be 2 mm.<sup>13</sup> Other authors advocate at least 1 mm of bone or 1.5 mm of space between the implant and the adjacent tooth in the anterior area.<sup>14</sup> A 3 to 5 mm dimension from the bone to proximal contacts should be planned in order to promote interdental papilla formation, although this dimension has not been fully studied.<sup>15</sup>

On the study cast, the incision design is drawn before it is performed on the patient's implant site. A partial thickness flap that does not include periosteum is used. The incision design begins in the facial-attached gingival at the facial proximal line angle of the adjacent tooth and proceeds lingually, bisecting the adjacent gingival crest with a #15-C Bard-Parker scalpel ending just beyond the proximal lingual line angle. Both mesial and distal incisions are made (Figures 1 and 2). The incision is redirected from the lingual toward the facial with the #15-C or #12 blade and continued so as to

Dennis Flanagan, DDS, is in private practice. Address correspondence to Dr Flanagan at 1671 West Main Street, Willimantic, CT 06226.



FIGURES 1-7. FIGURE 1. Facial lingual incisions. FIGURE 2. Facial lingual incisions. FIGURE 3. Arched incision connecting lingual endpoints. FIGURE 4. Arch crest incision. FIGURE 5. Proximally directed cuts. FIGURE 6. Final incision design. FIGURE 7. Arrows showing flaps folded proximally.

create an arch ending at the opposite proximal lingual line angle and connecting to the lingual of the facial-lingual incision. The crest of the arch should be 2 to 3 mm from the facial line aspect of the adjacent teeth (Figure 3). It is beneficial to have an adequate zone of facial-attached gingival remaining for periodontal support.

Another facial-lingual incision is made that bisects the lingual gingival arch. From this facial-lingual incision, 2 small cuts with a #12 blade are made toward their respective proximals, creating small wings, again taking care not to sever the wing or flap (Figure 6). The flaps and wings are undermined, and a partial thickness flap is lifted. The created wings are tucked under the flap toward the proximals. Figure 7 shows the arrows of positioning for the flap and wings (Figure 7). A paper model of the incisions dem-

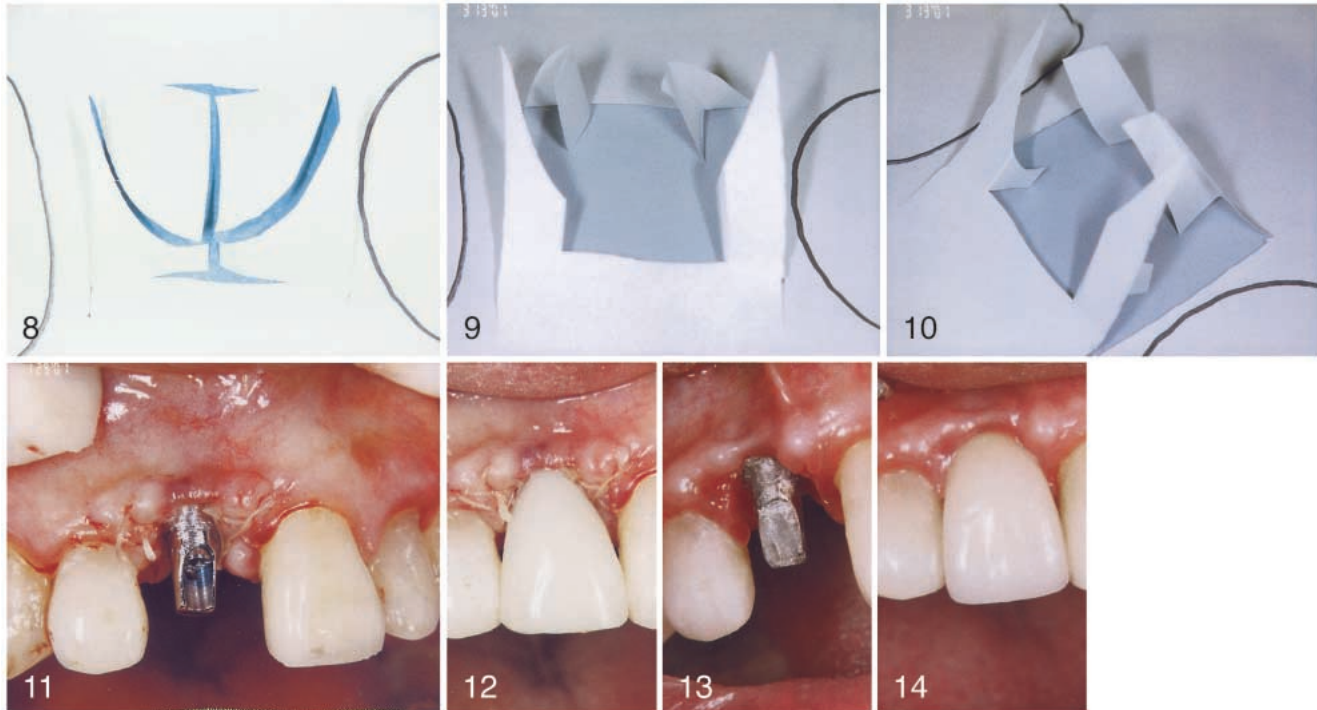
onstrates how the wings are oriented before being positioned proximally (Figures 8-10). The model also demonstrates the proximal suture method for the wings and how they may be supported by a provisional crown (Figures 11 and 12).

This design is probably better used as a second-stage procedure using a well-constructed provisional crown to provide a gingival emergence profile. Usually, 5-0 Vicryl sutures are needed to hold the flap and wings in position between the adjacent tooth and the provisional crown or healing element. From a practical point of view, the final positioning of the flap and wings may need to be done after the gingival healing element or provisional crown is in place. The healing element or provisional crown supports the gingival flap and wings and promotes a base for the formation of interdental papillae and

the gingival emergence profile for the crown restoration. The crown restoration is completed in the usual fashion maintaining a 3 to 5 mm dimension from the bone crest to the interproximal contact area. Papillae forms 6 weeks postoperatively (Figure 13). Figure 14 shows the final result.

#### DISCUSSION

This incision design allows lifting of the gingiva without disrupting the periosteum and its blood supply. The extreme ends of the flaps go a small distance beyond the crest of the ridge to minimally compromise the blood supply to the flap.<sup>16</sup> The incision does not cut into the attachment of the adjacent teeth. The interdental papilla can be important in the aesthetic zone to some patients and practitioners.<sup>17</sup> When the crown restoration is placed, the interdental contact area should be



FIGURES 8–14. FIGURE 8. Paper model demonstrating incision design. FIGURE 9. Paper model showing spatial orientation. FIGURE 10. Paper model showing suturing complete. FIGURE 11. Suturing complete. FIGURE 12. Provision crown in place. FIGURE 13. Six weeks postoperative. FIGURE 14. Fourteen weeks postoperative.

3 to 5 mm from the bone crest to promote papilla formation.<sup>18,19</sup>

#### CONCLUSION

This incision design is advantageous because it provides a gingival base for interdental papillae creation between an endosseous dental implant and the adjacent teeth.

#### REFERENCES

1. Renouard F, Rangert B. *Risk Factors in Implant Dentistry*. Chicago: Quintessence; 1999:30–31.
2. Spielman H. Influence of the implant position on the aesthetics of the restoration. *Pract Periodont Aesthet Dent*. 1996;8:897–904.
3. Saadoun A, LeGall M, Touati B. Selection and ideal tridimensional implant position for soft tissue aesthetics. *Pract Periodont Aesthet Dent*. 1999;11:1063–1072.
4. Phillips K, Kois J. Aesthetic peri-implant site development: the restorative connection. *Dent Clin N Am*. 1998;42:57–70.
5. James RA, McKinney RV, Mefert RM. Tissues surrounding dental implants. In: Misch CE, ed. *Contemporary Implant Dentistry*. 2nd ed. St Louis: Mosby; 1999:240–241.
6. Chang M, Wennstrom J, Odman P, Andersson B. Implant supported single-tooth replacements compared to contralateral natural teeth: crown and soft tissue dimensions. *Clin Oral Implants Res*. 1999;10(3):185–194.
7. Misch CE, Dietsh-Misch F. Diagnostic casts, preimplant prosthodontics, treatment prostheses and surgical templates. In: Misch CE, ed. *Contemporary Implant Dentistry*. 2nd ed. St. Louis: Mosby; 1999:135–162.
8. Renouard F, Rangert B. *Risk Factors in Implant Dentistry*. Chicago: Quintessence; 1999:13–66.
9. Flanagan D. A method for estimating preoperative bone volume for implant surgery. *J Oral Implantol*. 2000;26:34–38.
10. Cranin AN. Root form implant surgery: generic. In: Cranin AN, ed. *Atlas of Oral Implantology*. 2nd ed. St Louis: Mosby; 1999:176.
11. Misch CE, Dietsh-Misch F. Diagnostic casts, preimplant prosthodontics, treatment prostheses and surgical templates. In: Misch CE, ed. *Contemporary Implant Dentistry*. 2nd ed. St. Louis: Mosby; 1999:145–148.
12. Klein M, Abrams M. Computer-guided surgery utilizing a computer-milled surgical template. *Pract Proced Aesthet Dent*. 2001;13(2):165–169.
13. Lekholm U. The surgical site. In: Lindhe J, Karring T, Lang NP, eds. *Clinical Periodontology and Implant Dentistry*. 3rd ed. Copenhagen: Munksgaard; 1998:899.
14. Finger IM, Guerra LR, Boner N. In: Block MS, Kent JN, Guerra LR, eds. *Implants in Dentistry*. Philadelphia: WB Saunders; 133.
15. Tarnow D, Cho SC, Wallace SS. The effect of inter-implant distance on the height of inter-implant bone crest. *J Periodontol*. 2000;71:546–549.
16. Auty C, Siddiqui A. Punch technique for preservation of interdental

tal papillae at nonsubmerged implant placement. *Implant Dent.* 1999;8:160–166.

17. Chang M, Odman P, Wenstrom J, Andersson B. Esthetic outcome of implant-supported single-

tooth replacements assessed by the patient and by prosthodontists. *Int J Prosthodont.* 1999;12:335–341.

18. Salama H, Salama M, Garber D, Adar P. Developing optimal peri-implant papillae within the esthetic zone:

guided soft tissue augmentation. *J Esthet Dent.* 1995;7(3):125–129.

19. Tarnow D, Eskow RN. Preservation of implant esthetics: soft tissue and restorative considerations. *J Esthet Dent.* 1996;8:12–19.