

# RECONSTRUCTION OF THE SEVERELY RESORBED ATROPHIC EDENTULOUS RIDGE OF THE MAXILLA AND MANDIBLE FOR IMPLANT REHABILITATION: REPORT OF A CASE

Shou-Yen Kao, DDS, DMSc  
Tze-Cheung Yeung, DDS, MS  
I-Chiang Chou, DDS  
Richard Che-Shoa Chang, DDS,  
MS

## KEY WORDS

Atrophic ridge  
Reconstruction  
Maxilla  
Mandible  
Implant  
Bone graft  
Sinus lifting  
Anterior osteotomy

*Shou-Yen Kao, DDS, DMSc, is an associate professor of Oral and Maxillofacial Surgery, No. 201, Sec II, Shih-Pai Road, Oral and Maxillofacial Surgery, Department of Dentistry, Taipei-Veterans General Hospital, Taipei, Taiwan, ROC. He is also with the School of Dentistry, National Yang-Ming University, Taiwan. Correspondence should be addressed to Dr Kao.*

*Tze-Cheung Yeung, DDS, MS, is an attending doctor in Prosthetic Dentistry, Taipei Veterans General Hospital, as well as the School of Dentistry, National Yang-Ming University, Taiwan.*

We describe a case with a severely resorbed atrophic edentulous ridge in both the maxilla and mandible. The maxilla was reconstructed using a sinus-lifting procedure and onlay bone graft. The mandible was reconstructed by anterior osteotomy with an interpositional sandwich iliac bone graft at the symphysis area, subperiosteally with iliac bone chips mixed with hydroxylapatite bilaterally at the posterior atrophic ridge, and vestibuloplasty with a split thickness skin graft (STSG). After full-mouth implant rehabilitation, a 5-year follow-up of this case shows a satisfactory result.

## INTRODUCTION

**T**he thin, sharp, and shallow, severely atrophic alveolar ridge often hinders oral rehabilitation with implants. Therefore, the atrophic ridge must be rebuilt with the aid of reliable techniques of bone grafting in order to meet the basic requirements of implant surgery.<sup>1-6</sup> These requirements include a sufficient

*I-Chiang Chou, DDS, is a resident in Oral and Maxillofacial Surgery, Taipei Veterans General Hospital, and is with the School of Dentistry, National Yang-Ming University.*

*Richard Che-Shoa Chang, DDS, MS, is professor and dean of Oral and Maxillofacial Surgery, Taipei Veterans General Hospital, and is with the School of Dentistry at National Yang-Ming University.*

width and height of the rebuilt ridge to accommodate the dimensions of implanted fixtures, which will ensure the long-term stability of the grafted bone.<sup>7</sup> Meanwhile, the augmented ridge might also need a second-stage vestibuloplasty with a skin or mucosal graft to create an ideal contour of the vestibule as well as a keratinized zone around the implant. In the severely resorbed alveolar ridge, both maxilla and mandible can present a jaw discrepancy with a skeletal class III tendency and loss of vertical dimension that will further hinder the possibility of implant rehabilitation.<sup>2,7</sup> The rehabilitation of severe alveolar bone atrophy in the maxilla or mandible can thus be problematic if it is not carefully planned. However, a successful recon-

struction can be achieved with a comprehensive design, reliable technique, and multistage treatment.

#### CASE REPORT

##### *History and clinical examination*

A 65-year-old male patient seeking implant rehabilitation presented with severely atrophic edentulous ridges in both arches. Complete dentures had been used for 15 years without satisfaction. The patient denied a history of smoking, betel chewing, or alcohol consumption. The patient was physically healthy and denied medical history of systemic or local diseases contraindicating bone graft or implant surgery. The laboratory data of routine blood and serum biochemical analysis were within normal limits.

Intraorally, the maxilla demonstrated a bowl-shaped resorption pattern with only a partially preserved ridge contour in premaxilla (Figure 1a). The atrophic ridge in the mandible had sunk to the basal bone with only a thin band of keratinized gingivae between the sublingual gland and buccal mucosa (Figure 2a). A panoramic radiogram showed the maxilla with bilaterally enlarged maxillary sinuses close to the thin cortical surface of the atrophic ridge. The mandible had a pencil-thin appearance with mental foramen located near the crestal bone. The lateral cephalogram showed the symphysis bone to be only 1.5 cm in height and a severe skeletal class III pattern of jaw relationship (Figure 3a and b).

##### *Diagnosis and treatment plan*

An unfavorable condition for implant rehabilitation was present in both arches due to severe bone resorption. To cope with this, the study models of the patient were transferred to the articulator for analysis. Reconstruction of the atrophic ridge with various bone augmentation techniques before implant surgery was planned. The need of vestibuloplasty following bone augmentation of the jaw was also explained to the patient.

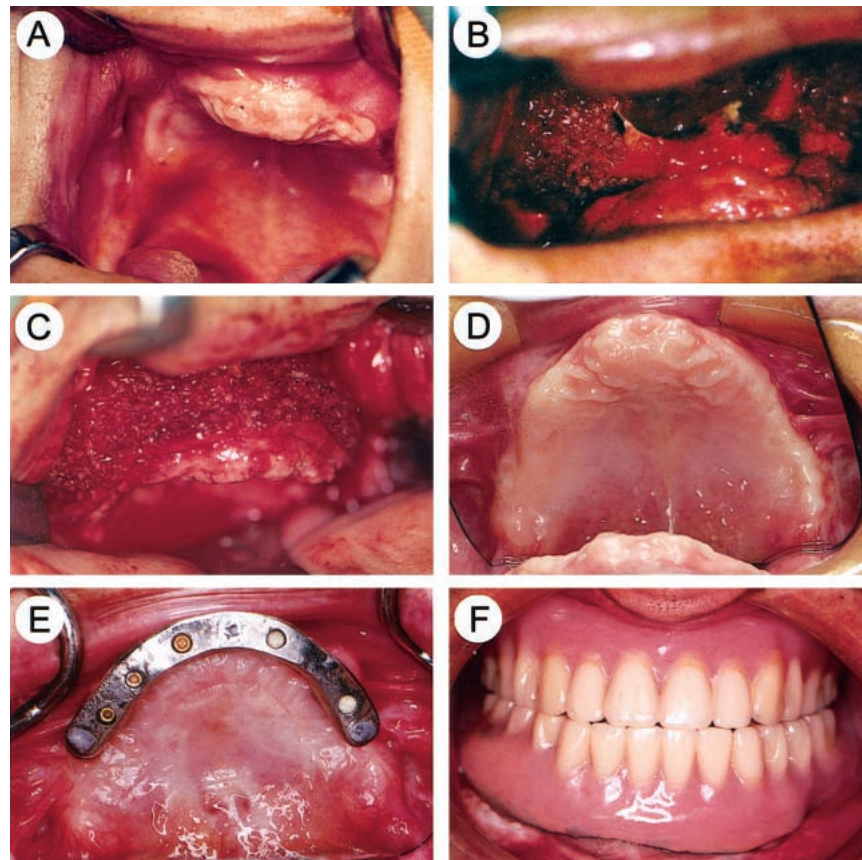


FIGURE 1. Reconstruction of the maxilla. (a) The bilateral severely atrophic ridge showing a bowl-shape resorption. (b) A radical sinus-lifting procedure grafted with an inlay iliac bone block and chips. (c) A large volume of iliac bone chips augmenting the maxilla and the atrophic ridge. (d) Improved contour of the atrophic ridge after bone augmentation. (e) Nine months after fixture implantation, a curved milled bar-type device for supporting the overdenture. (f) The rehabilitation completed by a pair of overdentures.

##### *Surgical procedure*

The reconstructive surgery was performed under general anesthesia. The patient was aseptically prepared and draped. Before surgery, 10 mg of Decadron, 3000000 units of crystal penicillin and 80 mg of gentamicin were intravenously given. Two teams of surgeons operated, respectively, at the oral region for the reconstructive approach and at the pelvic region for harvesting the iliac bone graft.

For reconstruction of the maxilla, a surgical stent was prepared that transferred a simulated augmented ridge from the study model of the maxilla. The vestibular incision was performed on alveolar mucosa 5 mm above the mucogingival junction extending from the right first molar to the left first mo-

lar. Direct access to the anterior wall of the maxilla was made bilaterally to expose the zygomatico-alveolar buttress, canine fossae, and canine buttress. The palatal mucosa flap was also denuded subperiosteally to fully expose the sharp and thin alveolar ridge. Extreme care was taken to radically elevate the sinus membrane from the bone window opened at the bilateral canine fossae. The floor, lateral wall, and posterior wall of the sinus membrane were meticulously detached and pushed upward for about 2 cm. The iliac bone blocks and chips were positioned within the maxillary sinus floor (Figure 1b). The iliac bone chips were further used to cover the outer wall of the exposed maxillary bone on both labial/buccal and palatal sides for ridge and outer

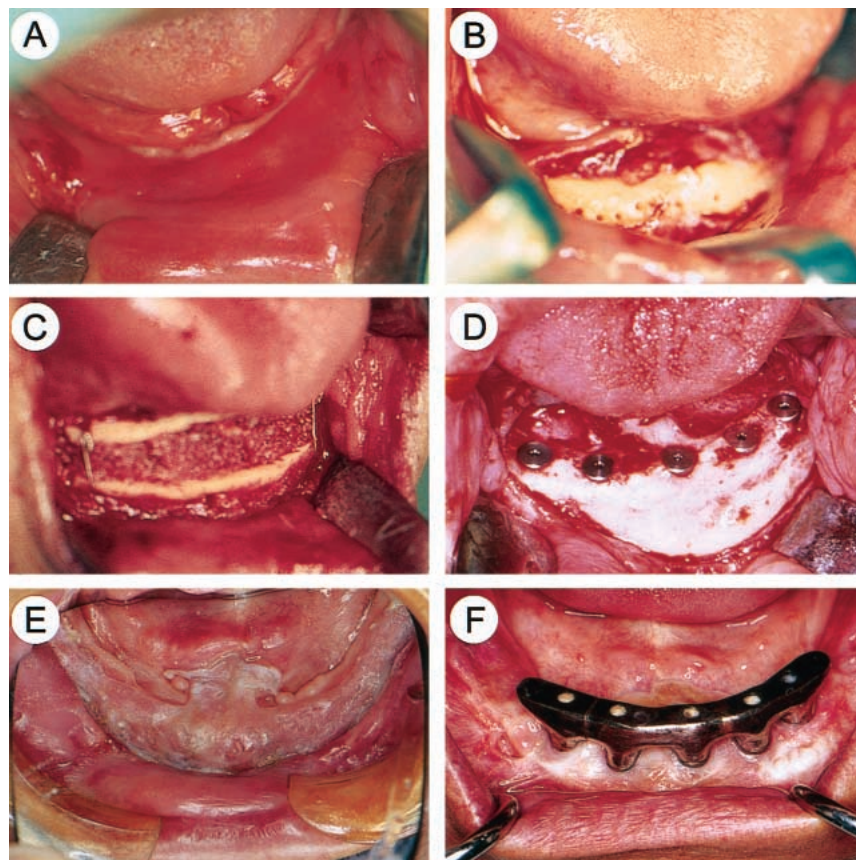


FIGURE 2. Reconstruction of the mandible. (a) The severely atrophic ridge of the mandible only detectable with a thin strip of keratinized gingivae. (b) Anterior osteotomy approach with midhorizontal separation at the symphysis bone. (c) An interposed inlay graft with iliac bone block and chips for ridge augmentation at the symphysis area. (d) Perfect regeneration and integration of the grafted bone seen at implant surgery. (e) The augmented ridge contour improved by vestibuloplasty with a split thickness skin graft (STSG). (f) A curved milled bar-type device for supporting the overdenture.

contour augmentation (Figure 1c). Two resorbable collagen membranes measuring  $3 \times 4$  cm were used to cover the augmented maxilla on both sides. A long horizontal releasing incision was made at the periosteum of the labial mucosa flap at a higher position so that the mucosa flap could be advanced to completely cover the augmented maxilla without tension. The wound was securely closed in 2 layers with resorbable suture material of 4-0 Dexon. The maxilla with a large amount of grafted bone was bimanually contoured and protected by the preformed surgical stent with a soft-liner, which was secured using circumzygomatic suspension for 2 weeks. The contour of the atrophic ridge and relatively retruded maxilla was thus im-

proved by this procedure (Figures 1d, 3c and d).

Implant surgery was primarily planned at the symphysis area of the mandible. A labial incision at the alveolar mucosa with direct access to the cortical bone at the symphysis area was used, followed by blunt dissection bilaterally to the mental foramen. An anterior osteotomy was performed with the symphysis bone further separated by a midhorizontal cut using an electromotor sagittal saw followed by vertical cuts bilaterally in front of the mental foramen (Figure 2b). A  $1 \times 1 \times 5$  cm iliac bone block along with bone marrow chips was placed as a sandwich inlay graft between the upper suspended fragment and the lower basal bone of the mandible and was

immobilized by stainless steel wire (Figure 2c). The ridge behind the mental foramen was also augmented using a subperiosteal tunneling technique with iliac bone chips and Calcitite 2040 hydroxylapatite particles (Calcitek Inc, Carlsbad, Calif; Figure 3c and d). The wound was then closed with the method previously described for the maxilla.

Nine months later, surgical implantation was performed using endosteal 3I dental implant (Implant Innovations Inc, Palm Beach Gardens, Fla) with 7 fixtures in the maxilla and 5 fixtures in the mandible under local anesthesia in an ambulatory surgery (Figure 2d). Three months after implantation, a vestibuloplasty with a split thickness skin graft (STSG) was performed in order to increase the intraoral ridge height. In a vestibuloplasty procedure, a midcrestal incision deepened to the supraperiosteal layer was performed from the symphysis to the retrotrigone area. Sharp and blunt dissection separating the labiobuccal flap from the lingual flap was continued to expose the edentulous ridge that was covered by the periosteum. Several horizontal mattress sutures connecting the labiobuccal flap and the lingual flap from the lower border of the mandible were used for maintaining the exposure of the ridge crest. The STSG measuring  $3 \times 7$  cm in width and 0.01 inch in thickness was harvested with an electrodermatome from the skin of the left thigh. The STSG was immobilized by a surgical stent using circummandibular wire fixation (Figure 2e). After another 3 months, the second-stage operation for exposure of implanted fixtures was performed in the mandible and maxilla. All implant fixtures were found firmly anchoring within the bone in the mandible. However, the third implant fixture in the left maxilla suffered significant bone loss and was removed a few weeks later (Figure 3e). Only 5 of the 6 implant fixtures were used for the prosthesis by preserving the last 1 in the right maxilla due to the requirements of the occlusal design (Figure

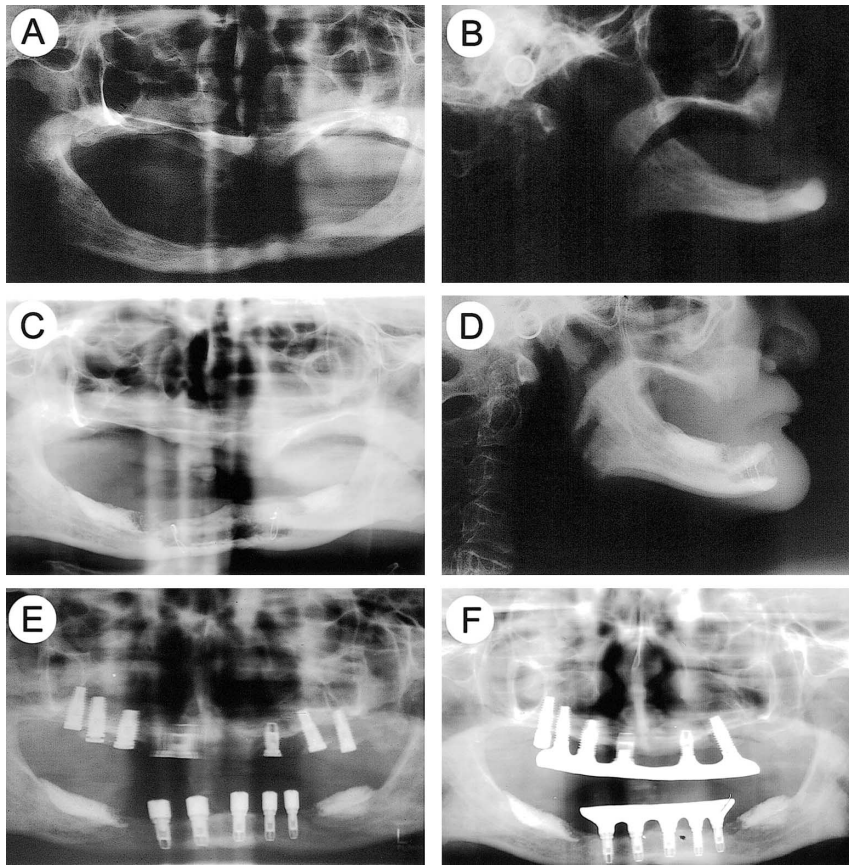


FIGURE 3. Radiographic examination. (a) The preoperative panoramic film showing the floor of the maxillary sinus close to the ridge crest and a pencil-thin atrophic ridge in the mandible. (b) Preoperative lateral cephalogram showing the severe atrophic ridge with a skeletal class III jaw relation. (c) The postoperative panoramic film showing the augmented sinus and ridge in the maxilla and the reconstructed ridge in the mandible. (d) The postoperative jaw relation was improved by this reconstruction. (e) Five fixtures securely anchoring in the mandible after the second-stage operation. The third implant fixture in the left maxilla seen with significant bone loss at the second stage operation was removed afterward. (f) Panoramic radiograph at the 5-year follow-up showing the stability of reconstruction. The milled bar supported by 5 implant fixtures in each jaw is functioning well.

3f). Implant-supported overdentures with milled bar and Magfit magnetic attachments (Aichi Steel Corp, Tokyo, Japan) were completed for both jaws with satisfactory results (Figures 1e and f, 2f). After a regular follow-up at 5 years, the bone stability of the reconstructed jaws was seen in the radiograph (Figure 3f).

#### DISCUSSION

Of all the donor sites of humans, the ilium can provide the largest amount of viable bone with osteogenetic potential for reconstruction. Previous literature mentioned a potential morbidity of using this donor site.<sup>8</sup> This patient experienced no such complications.

For reconstructing the atrophic ridge of the maxilla, a radical sinus-lifting procedure by insertion of bone blocks and chips measuring 2 cm in height guaranteed the length enough for fixture placement. The large volume of iliac bone chips covering the outer side of the maxilla improved the contour of the edentulous ridge and the decreased skeletal class III jaw relation between the maxilla and mandible. A predicted resorption did occur in the grafted iliac bone at the first stage of implant surgery. Focal augmentation of any osseous defects around the implants was performed with demineralized freeze-dried bone allograft covered by Gore Resolut

bioabsorbable membranes (W. L. Gore and Associates Inc, Flagstaff, Ariz) for guided bone regeneration.

In the mandible, the iliac bone block grafted at the site of the bone gap created by an anterior osteotomy had an excellent integration with recipient bone.<sup>9</sup> Although this allowed five  $4 \times 15$  mm fixtures to be implanted at the symphysis area, the augmentation procedure behind the mental foramen was performed primarily for uniformly aligning the posterior edentulous ridge with the anterior augmented region at the symphysis area. After bone augmentation and implant surgery, the augmented ridge in the mandible was still clinically invisible because of the compromised shallow vestibule and high mentalis muscle attachment. A vestibuloplasty with STSG was thus selected for improving the soft tissue condition of the augmented ridge.

#### CONCLUSION

The implant rehabilitation for the severely atrophic alveolar ridge of aged patients has challenged the surgeons for a long time. A careful design with the aid of reliable bone grafting techniques and soft tissue management could still fulfill the basic requirements of implant surgery such as the patient in this case, who was satisfied with the chewing function and stability of his prosthesis after a regular follow-up of 5 years. This case report suggests that an implant restoration with long-term stability can still be achieved in the severely compromised edentulous ridges.

#### REFERENCES

1. Keller EE, Tolman DE, Eckert S. Surgical-prosthetic reconstruction of advanced maxillary bone compromise with autogenous onlay block bone grafts and osseointegrated endosseous implants: a 12-year study of 32 consecutive patients. *Int J Oral Maxillofac Implants.* 1999;14:197-209.
2. Verhoeven JW, Cune MS, Terlou M, et al. The combined use of endosteal implants and iliac crest onlay

grafts in the severely atrophic mandible: a longitudinal study. *J Oral Maxillofac Surg.* 1997;26:351-357.

3. Astrand P, Nord PG, Branemark PI. Titanium implants and onlay bone graft to the atrophic edentulous maxilla: a 3-year longitudinal study. *J Oral Maxillofac Surg.* 1996;25:25-29.

4. Jensen J, Sindet-Pedersen S. Autogenous mandibular bone grafts and osseointegrated implants for reconstruction of the severely atrophied

maxilla: a preliminary report. *J Oral Maxillofac Surg.* 1991;49:1277-1287.

5. Garg AK. Augmentation grafting of the maxillary sinus for placement of dental implants: anatomy, physiology, and procedures. *Implant Dent.* 1999;8:36-46.

6. Lazzara RJ. The sinus elevation procedure in endosseous implant therapy. *Current Opin Periodontology* 1996;3:178-183.

7. Jennings DE. Treatment of the

mandibular compromised ridge: a literature review. *J Pros Dent.* 1989;61:575-579.

8. Cocklin J. Autogenous bone grafting—complications at the donor site. *J Bone Joint Surg.* 1988;46:290-296.

9. Egbert M, Stoelinga PJ, Blijdorp PA, et al. The “three-piece” osteotomy and interpositional bone graft for augmentation of the atrophic mandible. *J Oral Maxillofac Surg.* 1986;44:680-687.