

DELAYED IMMEDIATE SINGLE-STEP MAXILLARY SINUS LIFT USING AUTOLOGOUS FIBRIN ADHESIVE IN LESS THAN 4-MILLIMETER RESIDUAL ALVEOLAR BONE: A CASE REPORT

Amornpong Vachiramon, DDS, MSc, DBA
Wendy C. Wang, BDS, MSc, MClintDent
Tharin Vachiramon, DDS, MPH

KEY WORDS

Dental implant
Sinus lift
Osteotome technique
Bone graft
Fibrin adhesive

This paper presents a combination of techniques to replace a missing first premolar in an atrophic posterior maxillary ridge with less than 4 mm of residual bone. Simultaneous sinus lift and implant placement were carried out as a delayed-immediate procedure 6 weeks following the extraction of the premolar. The osteotome technique was used to gain primary stability. Demineralized freeze-dried bone and deproteinized cancellous bovine bone (Bio-Oss) were used to create the bone volume. Autologous fibrin adhesive was subsequently used to stabilize the bone grafting materials both in the sinus and on the coronal part of the implant. This combined technique preserves the alveolar bone after extraction; simplifies the primary closure; avoids a second surgical site; and reduces the total operation time, cost, and inconvenience to the patient.

INTRODUCTION

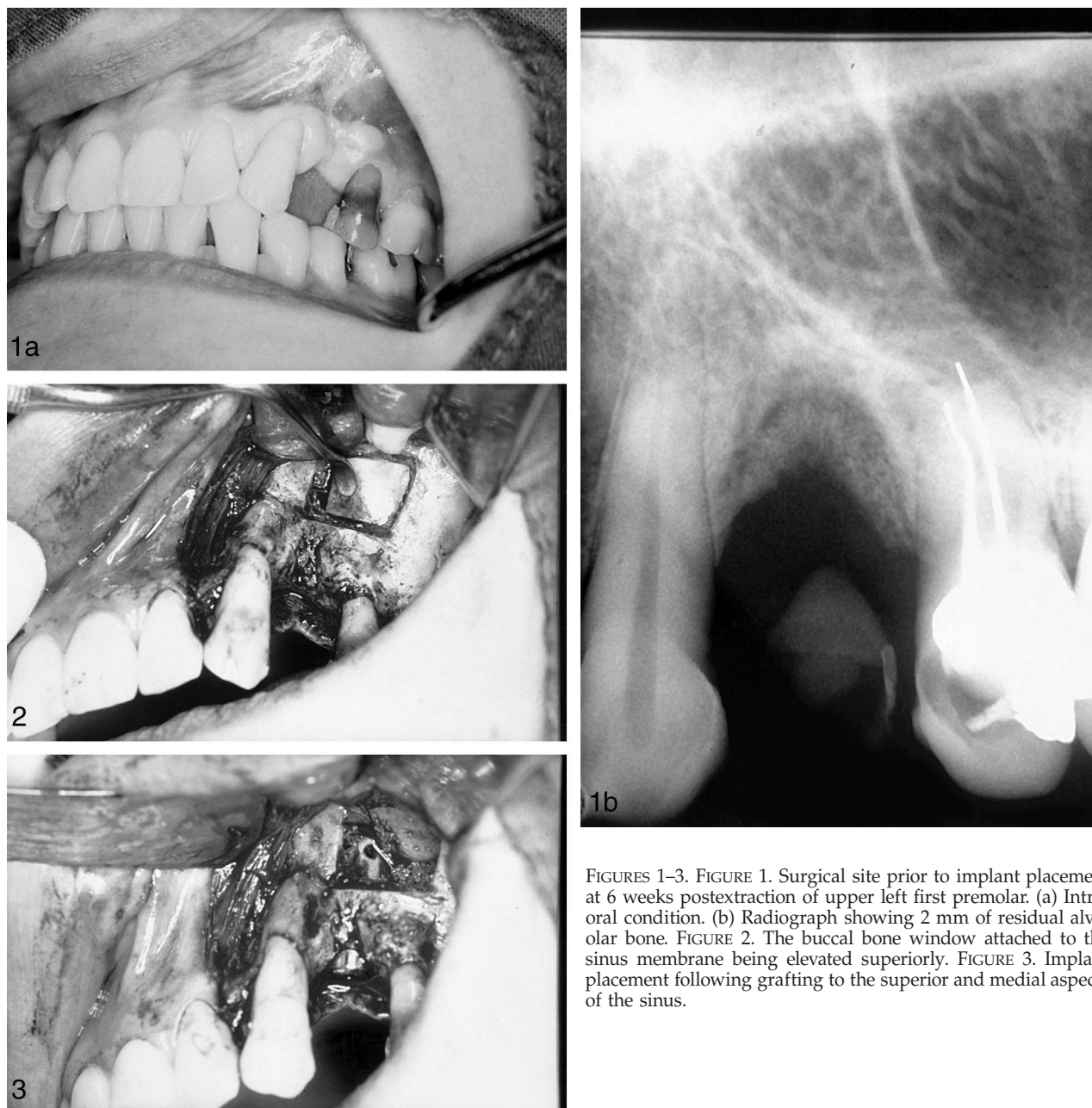
The use of osseointegrated implants is an acceptable and successful method for oral rehabilitation in patients who have adequate quantity and quality of bone for the placement of implants.¹ Delayed-immediate implantation is defined as implant placement carried out 6 to 8 weeks following tooth loss or extraction. This procedure allows re-epithelialization of the extraction site, and therefore ensures a more secure wound closure over the grafting material and implant than immediate implantation.²

In a grossly atrophic posterior maxillary ridge, the lack of bone due to pneumatization of the maxillary sinus and resorption of bone can present difficulties for surgeons.³ In 1980, Boyne and James⁴ described the elevation of the maxillary sinus floor through the lateral sinus wall to augment the atrophic posterior wall. The sinus lift and the implant placement may be carried out simultaneously or as 2 separate procedures,⁴⁻⁷ depending on the amount of bone available for primary stability. The general consensus is that the simultaneous single-step procedure should be reserved for pa-

Amornpong Vachiramon, DDS, MSc, DBA, MFDSRCPS(Glasg), FDSRCS(Eng), is in private practice. Correspondence should be addressed to Dr Vachiramon at 207 Gray's Inn Road, London, WC1X 8UW, United Kingdom.

Wendy C. Wang, BDS, MSc, MClintDent, FRACDS is in private practice.

Tharin Vachiramon, DDS, MPH, is in private practice.



FIGURES 1-3. FIGURE 1. Surgical site prior to implant placement at 6 weeks postextraction of upper left first premolar. (a) Intra-oral condition. (b) Radiograph showing 2 mm of residual alveolar bone. FIGURE 2. The buccal bone window attached to the sinus membrane being elevated superiorly. FIGURE 3. Implant placement following grafting to the superior and medial aspects of the sinus.

tients who have at least 5 mm of alveolar bone in the posterior maxilla.⁵

Fibrin adhesive has been used widely in oral and maxillofacial surgery.⁸ Autologous fibrin adhesive is composed of 2 components, autologous cryoprecipitate and bovine thrombin/calcium chloride solution, which, when mixed together, result in fibrin gel.⁹

This paper presents the single-step sinus lift technique, carried out 6

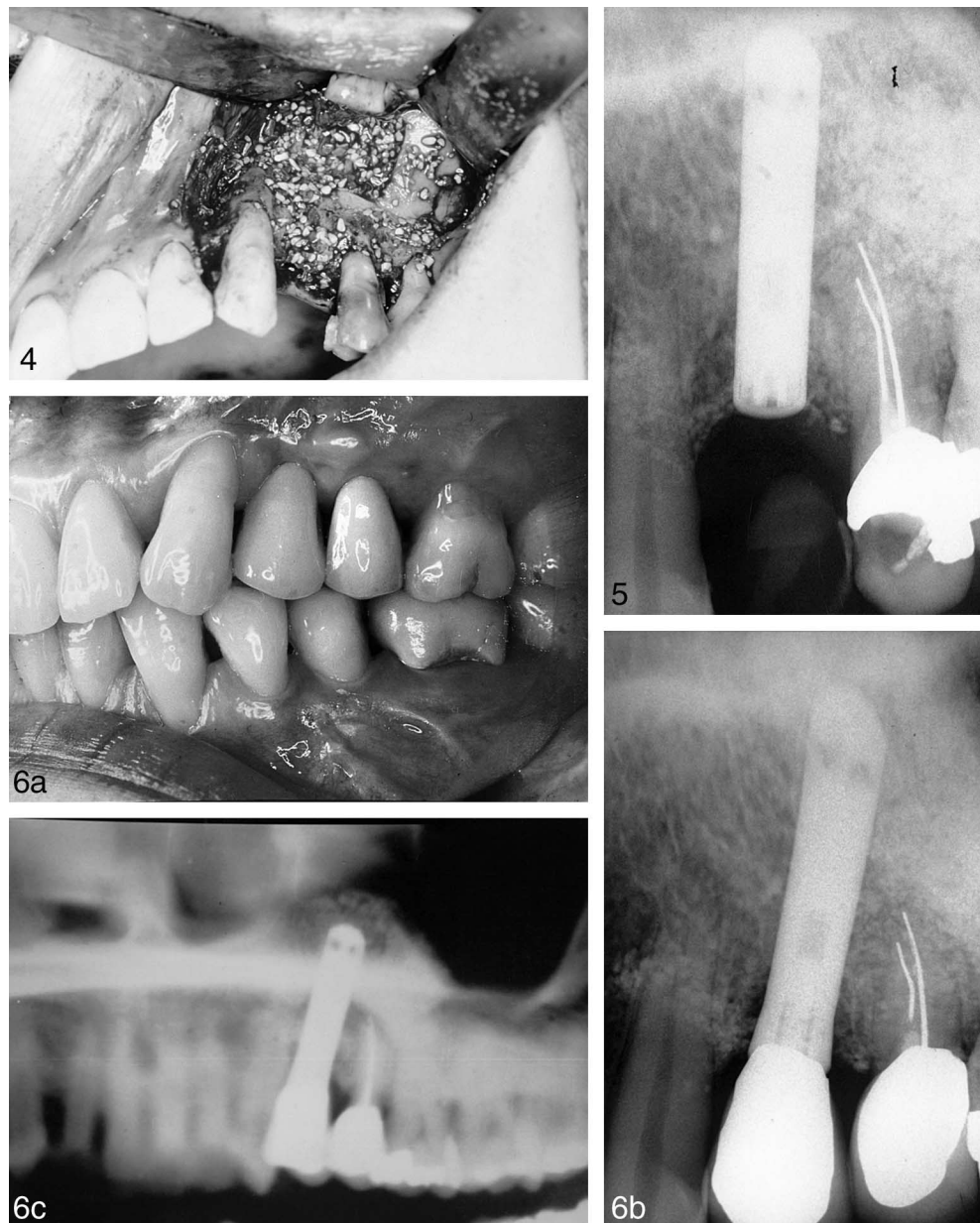weeks following the extraction of a premolar, in a patient with less than 4 mm of alveolar bone remaining in the posterior maxilla.

CASE DESCRIPTION AND RESULTS

A 42-year-old woman presented with a vertical root fracture of the upper left first premolar. The tooth was extracted 6 weeks prior to implant placement (Figure 1a and b). One unit of the pa-

tient's blood was taken 1 week prior to the procedure for the preparation of an autologous fibrin adhesive.

On the day of the procedure, the patient was prepared and draped in the conventional way under sterile conditions. Local anesthesia was used and a crestal incision was made toward the palatal aspect of the edentulous ridge. This extended beyond the limits of the planned osteotomy with consideration



FIGURES 4–6. FIGURE 4. Grafting materials packed around the implant fill up remaining spaces of the sinus and are stabilized by autologous fibrin adhesive. FIGURE 5. Periapical radiograph at second-stage surgery. FIGURE 6. Three-year postoperative results: (a) clinical condition; (b) periapical radiograph; (c) panoramic radiograph showing elevation of the sinus.

of the amount and position of the attached gingivae. Additional vertical relieving incisions were made in the buccal vestibule to facilitate the reflection of the full mucoperiosteal flap. A full thickness flap was then reflected from the underlying bone. Once the lateral maxillary wall was exposed, a square window was prepared. A round diamond bur was used at slow speed in a

high-torque straight handpiece with copious saline irrigation. Meticulous care was taken to avoid perforating the sinus membrane. A blunt instrument was used to tap the osteotome gently to ensure that the island of bone was penetrated all around. A sinus elevator was then used to rotate the bone lid attached to the membrane superiorly (Figure 2). The sinus membrane was

protected while the implant site was prepared. With the aid of the surgical stent, a pilot drill was used to guide the implant location on the alveolar ridge. The implant site was then enlarged with conical osteotomes. Using the smallest osteotome first, followed by increasingly larger osteotomes, the diameter of the implant site was made slightly smaller than that of the im-

plant. The osteotome technique was employed to increase the bone density around the implant site and to aid the primary stability of the implant.¹⁰

DeminerIALIZED freeze-dried bone (DFDB; LifeNet, Virginia Beach, Va) and deproteinized cancellous bovine bone (Bio-Oss, Osteohealth Co, Shirley, NY) in 1:1 ratio were mixed with sterilized saline. Any excess saline was removed with dry gauze. The mixture was then loaded into a syringe and injected into the maxillary sinus and packed against the medial and superior aspects of the sinus. The bone-grafting materials were stabilized by the autologous fibrin adhesive on the superior and medial aspects of the sinus in order to ensure adequate bone coverage on the implant. A 15-mm hydroxyapatite-coated cylindrical dental implant (Sulzer Calcitek, Carlsbad, Calif) was placed into the prepared implant site (Figure 3). Once the proper position of the implant was confirmed, the mixture of the grafting materials was carefully injected to fill up the lateral portion of the sinus and the exposed coronal part of the implant. Optimal adaptation to the surface of the implant was ensured. The autologous fibrin adhesive was then used to stabilize the grafting materials in both areas (Figure 4). The periosteum under the buccal flap was relieved until primary closure could be achieved. Closure was gained with 4-0 Vicryl vertical mattress sutures. Postoperative instructions, antibiotics, and analgesics were given.

Second-stage surgery was carried out 9 months later (Figure 5). A porcelain fused to metal crown was subsequently fitted. The 3-year follow-up examination showed no signs or symptoms of implant failure (Figure 6a, b, and c).

DISCUSSION

Implant rehabilitation in patients with less than 5 mm of bone height in the posterior region of the maxilla usually requires separate surgeries for bone augmentation and implant placement,

which could lead to increased treatment time and higher costs. This paper presents the delayed-immediate single-step sinus lift procedure in a patient with less than 4 mm of residual bone. Delaying the single-step sinus lift 6 weeks following the tooth extraction allowed for the elimination of possible infection, the achievement of a maximum osteoblastic process, and complete wound covering that would simplify the placement of the grafting materials.¹¹ This method reduced the number of operations, treatment time, and cost. In addition, the whole procedure could be carried out under local anesthesia and could avoid a second surgery site.

The advantages of using autogenous bone include no immunogenic reaction or possibility of cross infection. It is also a source of osteoprogenitor cells. However, there is the need for a second surgical site with the increased morbidity and surgical time.¹² DFDB has been used as a sinus lift augmentation material because of its osteoconductive and osteoinductive properties.¹³ Valentini et al¹⁴ used Bio-Oss as a grafting material for the sinus lift procedure and demonstrated histologically intimate contact between newly formed bone and the particles of the graft with no overt signs of resorption of the graft particles. The combination of DFDB and Bio-Oss seems to be a suitable material to augment the maxillary sinus due to the combined osteoinductive property of DFDB and osteoconductive property of Bio-Oss.

Tayapongsak et al⁹ demonstrated that autologous fibrin adhesive accelerated the bone graft healing process in addition to the adhesive and hemostatic properties. Momtaheni et al¹⁵ emphasized the importance of stabilization of bone graft materials and used fibrin adhesive to provide immobilization of the graft materials and to repair membrane tear in sinus lift procedures. Bosch et al¹⁶ demonstrated that fibrin adhesive improved bone graft incorporation and remodeling by significantly reducing the size of the

gaps between bony fragments and accelerating the revascularization. Moreover, multiplication of bacteria in the fibrin clot was significantly slower than in the comparable blood clot. In addition, using fibrin adhesive to stabilize the bone graft materials avoided the possible complications associated with membranes used for guided bone regeneration, such as membrane perforation, infection, bone loss, and even loss of implants.¹⁷

CONCLUSION

This paper presents a method, using a combination of techniques, to replace missing teeth in patients with atrophic posterior maxillary alveolar bone. Simultaneous sinus lift and implant placement were carried out 6 weeks following the extraction of the upper left premolar as a delayed-immediate procedure. The 6-week delay allowed for simplified primary closure following grafting. The osteotome technique was used to achieve primary stability of the implant. DFDB and Bio-Oss were the bone grafting materials chosen to create the bone volume, and autologous fibrin adhesive was used to stabilize the grafting materials. This technique reduced the number of operations and avoided a second surgical site. It also offered a shorter total treatment time, preserved alveolar bone after extraction, and minimized complications with an aesthetically pleasing result.

ACKNOWLEDGMENTS

We would like to thank Mr Colin Hopper and Mr Colin Haylock for their help and advice.

REFERENCES

1. Adell R, Eriksson B, Lekholm U, Branemark PI, Jemt T. Long-term follow-up study of osseointegrated implants in the treatment of totally edentulous jaws. *Int J Oral Maxillofac Implants.* 1990;5:347-359.
2. Spiekermann H. *Implantology.* New York: Thieme Medical; 1995: 267.
3. Branemark PI, Adell R, Al-

- brektsson T, Lekholm U, Lindstrom J, Rockler B. An experimental and clinical study of osseointegrated implants penetrating the nasal cavity and maxillary sinus. *J Oral Maxillofac Surg.* 1984;42:497–505.
4. Boyne PJ, James RA. Grafting of the maxillary sinus floor with autogenous marrow and bone. *J Oral Surg.* 1980;38:613–616.
5. Chanavaz M. Maxillary sinus: anatomy, physiology, surgery, and bone grafting related to implantology—eleven years of surgical experience (1979–1990). *J Oral Implantol.* 1990;16:199–209.
6. Tatum H. Maxillary and sinus implant reconstructions. *Dent Clin North Am.* 1986;30:207–229.
7. Small SA, Zinner ID, Panno FV, Shapiro HJ, Stein JI. Augmenting the maxillary sinus for implants: report of 27 patients. *Int J Oral Maxillofac Implants.* 1993;8:523–528.
8. Sullivan SM, Bulard RA, Meaders R, Patterson MK. The use of fibrin adhesive in sinus lift procedures. *Oral Surg Oral Med Oral Pathol.* 1997;84:616–619.
9. Tayapongska P, O'Brien DA, Monteiro CB, Arceo-Diaz LY. Autologous fibrin adhesive in mandibular reconstruction with particulate cancellous bone and marrow. *J Oral Maxillofac Surg.* 1994;52:161–165.
10. Summers RB. A new concept in maxillary implant surgery: the osteotome technique. *Compendium.* 1994;15:152, 154–156, 158.
11. Nir-Hadar O, Palmer M, Soskolne WA. Delayed immediate implants: alveolar bone changes during the healing period. *Clin Oral Implants Res.* 1998;9:26–36.
12. Tong DC, Rioux K, Drangsholt M, Beirne OR. A review of survival rates for implants placed in grafted maxillary sinuses using meta-analysis. *Int J Oral Maxillofac Implants.* 1998;13:175–182.
13. Sailer HF. A new method of inserting endosseous implants in totally atrophic maxillae. *J Craniomaxillofac Surg.* 1989;17:299–305.
14. Valentini P, Abensur D, Densari D, Graziani JN, Hammerle C. Histological evaluation of Bio-Oss in a 2-stage sinus floor elevation and implantation procedure. A human case report. *Clin Oral Implant Res.* 1998;9:59–64.
15. Momtaheni DM, Schweitzer K, Muenchinger F. Technique for stabilization of autogenous cancellous bone grafts in sinus lift procedures. *Oral Surg Oral Med Oral Pathol.* 1994;78:14–16.
16. Bosch P, Lintner F, Arbes H, Brand G. Experimental investigations of the effect of the fibrin adhesive on the Kiel heterologous bone graft. *Arch Orthop Trauma Surg.* 1980;96:177–185.
17. Celletti R, Davarpanah M, Etienne D, et al. Guided tissue regeneration around dental implants in immediate extraction sockets: comparison of e-PTFE and a new titanium membrane. *Int J Periodont Rest Dent.* 1994;14:242–53.