

# TRANSPositionED FLAP VESTIBULOPLASTY COMBINED WITH IMPLANT SURGERY IN THE SEVERELY RESORBED ATROPHIC EDENTULOUS RIDGE

Shou-Yen Kao, DDS, DMSc  
Tze-Cheung Yeung, DDS, MS  
Kai-Feng Hung, DDS  
I-Chiang Chou, DDS  
Chen-Hsian Wu, DDS  
Richard Che-Shoa Chang, DDS, MS

## KEY WORDS

Vestibuloplasty  
Edentulous  
Resorption

All the authors are affiliated with Taipei Veterans Hospital.

Shou-Yen Kao, DDS, DMSc, is an associate professor in Oral and Maxillofacial Surgery in the School of Dentistry at Taipei Veterans General Hospital, National Yang-Ming University, No 201, Sec II, Shih-Pai Road, Taipei, Taiwan, Republic of China. Address correspondence to Dr Shou-Yen Kao.

Tze-Cheung Yeung, DDS, MS, is an attending doctor in Prosthetic Dentistry.

Kai-Feng Hung, DDS, is a resident in Oral and Maxillofacial Surgery.

I-Chiang Chou, DDS, is a resident in Oral and Maxillofacial Surgery.

Chen-Hsian Wu, DDS, is a resident in Oral and Maxillofacial Surgery.

Richard Che-Shoa Chang, DDS, MS, is professor and dean of Oral and Maxillofacial Surgery.

The use of transpositioned flap (lipswitch) vestibuloplasty combined with implant surgery in patients with severely resorbed atrophic edentulous ridges is reviewed. The cases of 17 patients with severely resorbed atrophic edentulous ridges at the mandible undergoing implant rehabilitation were reviewed. Lipswitch vestibuloplasty was followed immediately by the implant surgery. Postoperative follow-up consisted of clinical and radiographic examinations. Seventeen patients with atrophic ridges (12 class II and 5 class III) each had 2 implant fixtures placed in the mandible as abutments for a clip and bar overdenture. The average time of follow-up was 6 years. Before surgery, all patients had severely atrophic ridges with a compromised shallow vestibule of varying degrees. Satisfactory results were observed in regard to the immediate and long-term morphology of the vestibule, the health of the peri-implant tissue, the stability of implant fixtures, and the functionality of the prostheses. The lipswitch vestibuloplasty offers a safe and convenient method of surgical access for implant fixture installation, with the advantage of rebuilding the vestibule of a compromised atrophic ridge in the anterior mandible.

## INTRODUCTION

A variety of methods for the surgical approach to the host bone and osseous reconstruction for installation of titanium endosteal implants have been proposed over the last decade.<sup>1-6</sup> It is generally agreed that soft tissue management is as important as bone condition for implant installation. The signs of success-

ful soft tissue management include healthy mucosa around implant fixtures, an adequate attached zone of keratinized gingivae around the fixture, no intervening frenum or high muscle attachment close to the fixture, and an appropriate probing depth of peri-implant gingivae sulcus. However, these results might not be easily obtained because of the compromised ridge con-

TABLE 1  
Clinical features of 17 patients

Age (years)	59 ± 7
Gender	
Men	9
Women	8
Classification of ridge	
Class II	12
Class III	5
Average ridge height	20 ± 4
Number of fixtures, by tape	
4 × 13 mm	8
4 × 15 mm	19
4 × 18 mm	7
Average of sulcus depth at 6-years follow-up	2.5 ± 0.6 mm
Wound dehiscence with implant exposure	3
Number of implants with bone fenestration <2 mm	5

ditions in patients with severely resorbed atrophic alveolar ridges. In these cases, the keratinized gingivae might be limited and the frenum or muscle attachment might be close to the ridge crest with a shallow vestibule.<sup>7,8</sup> Therefore, implant surgery using conventional access in such conditions might require another procedure for vestibuloplasty. In order to maintain an adequate morphology of the vestibule and to achieve stability of peri-implant tissue, we have used lip-switch vestibuloplasty combined with implant surgery for patients with severely atrophic edentulous alveolar ridges in the symphysis area of the mandible.<sup>9-11</sup> In this analysis, we reviewed the surgical management and the status of follow-up in 17 of these patients.

#### PATIENTS AND METHODS

Seventeen patients (9 men, 8 women; average age 59 ± 7 years) with severely resorbed atrophic edentulous ridges in their mandibles who underwent implant surgery in Taipei Veterans General Hospital were evaluated (Table 1). Because actual ridge heights and forms vary considerably between and within sexes, an anatomically based classification of the atrophic ridge was done based on the criteria previously described by Kent

et al in 1983.<sup>8</sup> There were 12 class II and 5 class III edentulous ridges in these patients. Besides the varying anatomic morphology of the atrophic ridges, different degrees of compromised soft tissue conditions at the anterior atrophic ridge area due to bone resorption and high mentalis muscle attachment with shallow vestibule were also observed (Figure 1a). Radiographic examination revealed all cases with a severely atrophic ridge from symphysis to the body area (Figure 2a). The vertical height of the atrophic ridges was measured, with an average of 20 ± 4 mm at the symphysis area under lateral cephalogram. Three patients with class III atrophic ridges had mental foramen very close to the ridge crest, whereas those of the others were at least 5 mm below the ridge crest. All of these cases were carefully evaluated pre-surgically using wax models of the teeth. A surgical stent with drill guides showing the correct position of the fixture insertion was utilized in each case during surgery. Before and after surgery, the patients all participated in an intensive program of oral hygiene instruction.

Each patient was aseptically prepared and draped periorally. Before surgery, 10 mg of Decadron, 3 000 000 units of crystal penicillin, and 80 mg

of gentamicin were given intravenously. Under intraoral nerve block and local anesthesia with Xylocaine (1:100 000 epinephrine), surgery was performed using the lipswitch method modified from Kazanjian's labial vestibuloplasty.<sup>9-11</sup> A sagittal view of the surgical procedure is shown in Figure 3. A circumvestibular incision was made at about 1.5 cm labial to the ridge crest from canine to canine region. The mucosal flap was carefully dissected submucosally using a No. 15 surgical knife or a small dissector. The mucosal flap was further raised subperiosteally by a horizontal incision along the ridge crest to expose the cortical bone. The mucosal flap could then be raised backward underneath the periosteum to expose the lingual cortical bone as needed. The remaining soft tissue with periosteum on the labial cortical bone close to the ridge crest was detached downward to the depth of the newly created vestibule. The periosteal flap was further sutured anteriorly with a mucosal edge left by the vestibular incision at the lower lip. The sharp, thin, and narrow crestal bone was then trimmed down with an electromotor carbide bur under an adequate water-cooling system until a flat bone table with a buccolingual diameter wide enough for fixture insertion was obtained. Two fixtures (3I, Implant Innovations Inc, Fla) were implanted at the bilateral canine region in each patient (Figure 1b). Finally, the mucosal flap was sutured to the periosteum flap at the bottom of the newly created vestibule (Figure 3a-d). A morphologically improved vestibule is created postoperatively (Figure 1c). Five months after fixture implantation, a secure osseous integration around the fixtures is achieved (shown in radiograph; Figure 2b). The second-stage surgery was performed by a midcrestal incision to allow fixture exposure and to transfer healing abutments onto the fixtures. To preserve a zone of keratinized gingivae around the implant

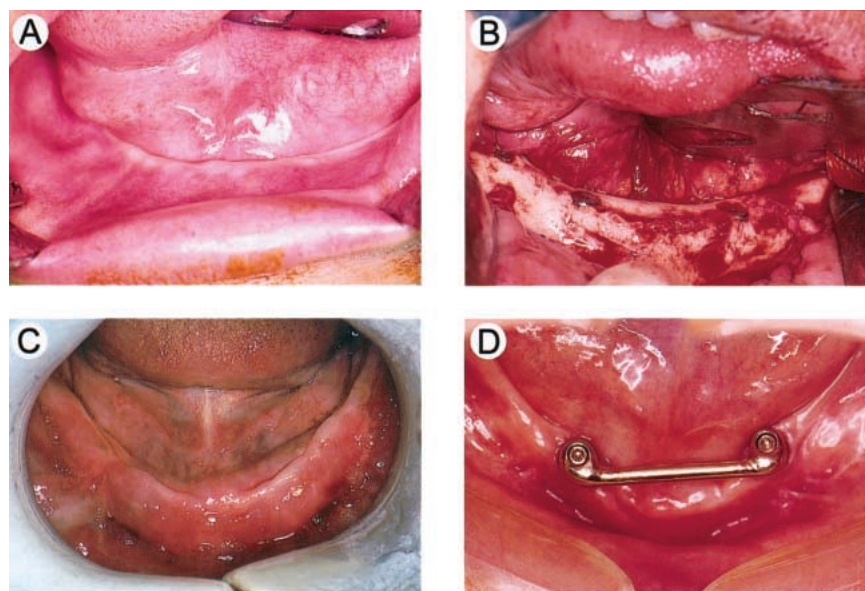


FIGURE 1. A 57-year-old female patient with a class II atrophic ridge with implant-supported overdenture rehabilitation. (A) Compromised soft tissue conditions at the anterior atrophic ridge of the mandible with bone resorption and high mentalis muscle attachment. (B) After fully uncovering and trimming down the sharp, thin, and narrow crestal bone, the bone table was wide enough to provide implantation of fixtures. (C) An improved contour of the vestibule 2 weeks after surgery. (D) A casting bar-type connector on 2 standard abutments for supporting the overdenture.

fixture, the gingivae should be split off labiolingually by a horizontal crestal incision at the second-stage operation for the exposure of implant fixtures. If keratinized attached gingivae are not exactly located on the top of implant fixtures, an apically positioned flap can be made to relocate the keratinized gingivae around the healing abutment of the implant fixture. Afterward, prosthodontic treatment was completed with a clip and bar overdenture supported by a casting connector between 2 standard abutments (Figure 1d). These patients were regularly followed for clinical observation and for radiographic examination at 6-month intervals.

#### RESULTS

All 17 patients received a lipswitch vestibuloplasty for the first-stage implant surgery at the anterior atrophic ridge of the mandible. The sizes of the implant fixtures varied from  $4 \times 13$  mm to  $4 \times 18$  mm (see Table 1). Seven patients (5 class III and 2 class II) had similar management by lipswitch vestibuloplasty at their atro-

phic ridges behind the mental foramen due to high attachment of the buccinator muscle and a shallow buccal vestibule. Postoperatively, there was exposure of 3 fixtures due to mucosal flap dehiscence. At the second-stage surgery, there were 5 implants with minimal fenestration or bone loss within 2 mm at the superficial crestal bone around the fixtures. All cases had improved labial contour of the vestibule at the surgical sites. A prosthesis of a clip and bar overdenture supported by fixture abutments and their casting connector was designed. After delivery of their prostheses, all patients needed 2–3 follow-up visits within the initial 3 months for denture adjustment. Two patients with class III severely atrophic ridges having a superficially located mental foramen felt mild discomfort and required denture adjustments for an additional 6 months. With an average of 6 years' follow-up, all the fixture abutments were firm and stable, with a mean probing depth of peri-implant gingivae sulcus less than  $2.5 \pm 0.6$  mm (see Table 1).

The retention, stability, function, and cosmetic appearance of the dentures were excellent.

#### DISCUSSION

A severely atrophic ridge in aged patients has long been an obstacle for an ideal dental rehabilitation by a conventional complete denture.<sup>7</sup> To cope with this, a variety of methods for increasing retention, stability, or even supporting ability for the prosthesis have been considered.<sup>1–4</sup> Unfortunately, bone augmentation with or without grafting vestibuloplasty for the class II and class III atrophic ridges still often cannot meet the basic needs for making a conventional prosthesis with good retention, stability, and support. It is generally agreed that supporting the prosthesis with endosteal implants can dramatically improve the results.

Another question is how many implants are needed for the patients with such severely atrophic ridges. Usually, the class II and class III atrophic edentulous ridges behind the mental foramen are not suitable for regular fixture

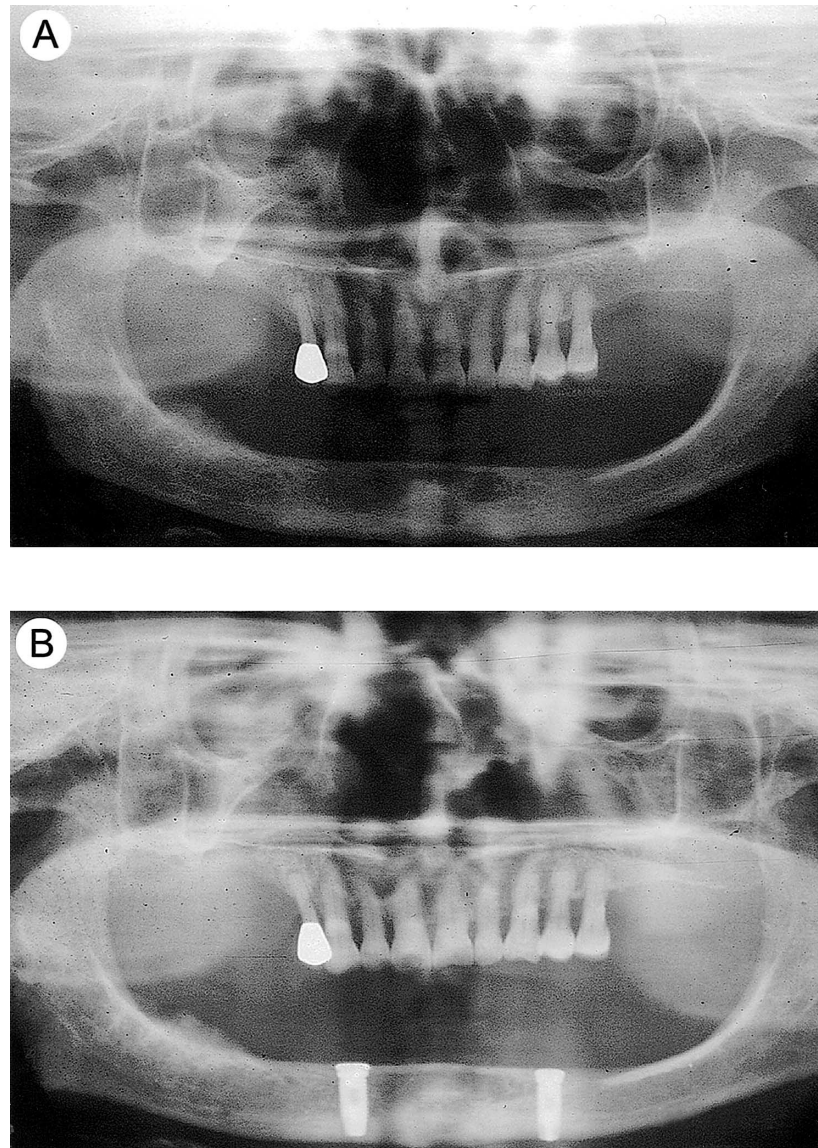


FIGURE 2. Radiographs of the same patient as in FIGURE 1. (A) A vertical bone height of approximately 2.2 cm at the symphysis area. (B) Excellent integration between host bone and two 18-mm implant fixtures 5 months after surgery.

placement due to the lack of adequate bone height above the inferior alveolar canal. Therefore, denture designs with 2–5 fixtures between the bilateral mental foramen can provide different tracks of treatment from fixed to removable prostheses. In these 17 patients, a clip and bar overdenture supported by 2 implant fixtures gave good results.

Besides the type and mechanical design of the implant prosthesis, the compromised soft tissue condition at

these atrophic ridges raises another important consideration. The severely atrophic edentulous ridge at the mandible often presents with a sharp and thin contour with a high attachment of the mentalis and buccinator muscle in need of vestibuloplasty.<sup>8</sup> In such conditions, conventional methods of raising a full-thickness mucoperiosteal flap with midcrestal, labial, and lingual approaches cannot improve the underlying problems and may even leave a more severely compromised vestibule

after surgery. Therefore, we proposed the method of lipswitch vestibuloplasty in combination with implant surgery to provide access sufficient to improve the aforementioned problems in a single procedure. This method provides several advantages as follows: (1) it eliminates the need for another surgery for soft tissue management; (2) a secure mucosal flap for covering the fixture is created; (3) the morphology of the labial vestibule is improved; and (4) the keratinized attached gingivae is

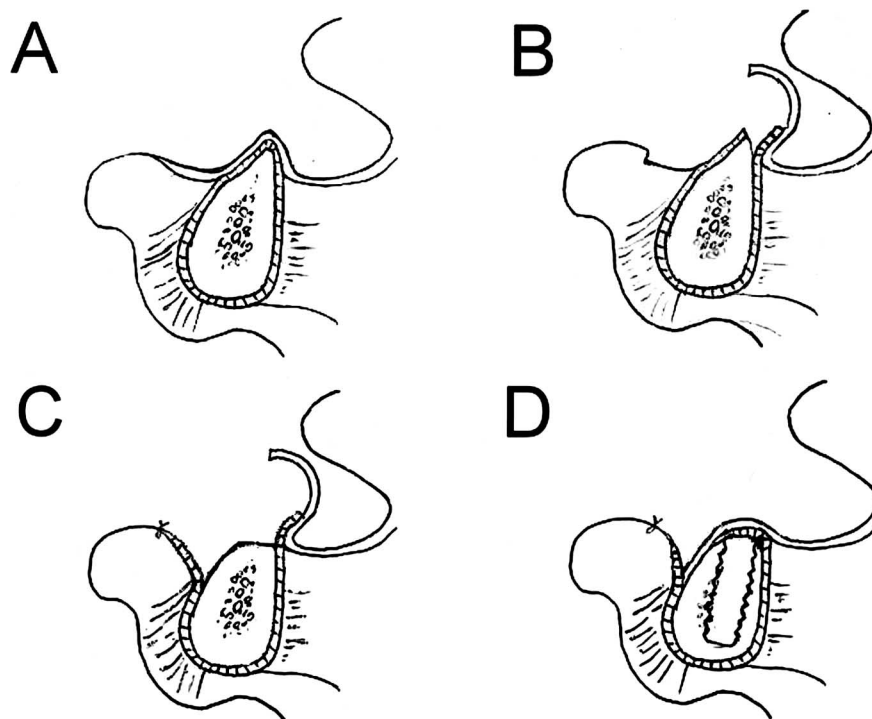


FIGURE 3. Sagittal sections of the lip, mandible, and tongue demonstrating the procedure and management of the transpositioned mucosal flap and periosteum flap prior to implant surgery. (A) A compromised vestibule with a shallow and thin atrophic edentulous ridge and high mentalis muscle attachment. (B) The mucosal flap being raised to the lingual cortex to fully uncover the ridge crest. (C) The ridge crest is trimmed down to accommodate the fixture. (D) The transpositioned mucosal flap and periosteum flap provides secure coverage of implant fixtures without dehiscence and a great improvement in vestibular morphology.

preserved for use as peri-implant tissue at the second-stage operation. In some cases, such as when the attachment of the buccinator muscle in the class III atrophic ridge is high, the lipswitch vestibuloplasty can also be performed at the region behind the mental foramen to improve the morphology of the vestibule. This certainly improves the retention and stability of the final prosthesis.

Although there is some controversy about the need for complete primary closure over the implant, and various flap design modifications have been developed to help obtain such closure, it is agreed that a good flap design can ensure adequate tissue mobility to attain primary closure of the wound. This greatly facilitates postoperative care, minimizes complications, and maximizes the predictability of the procedure. In the severely atrophic ridge with shallow vestibule, flap design must be carefully

planned to provide adequate access for proper implant fixture installation as well as tension-free soft tissue closure. The lipswitch method with the transpositioned mucosal flap and periosteum flap can provide the advantage of primary closure. However, it is critical to avoid creating tension on the flaps, because tension causes ischemia and the primary closure can be lost, such as in 1 case with wound dehiscence in this group of patients.

#### SUMMARY

This article addressed a method of using lipswitch vestibuloplasty combined with implant surgery in patients with severely atrophic class II and class III edentulous ridges. This method provides the advantages of access to the host bone for easier implant fixture installation, improved morphology of the vestibule, convenience of performing vestibuloplasty and implant surgery at

one time, and the preservation of the keratinized gingivae. The design of a clip and bar overdenture supported by 2-fixture abutments and connectors had a satisfactory result.

#### REFERENCES

1. Boyne PJ, Cole MD, Stringer D, et al. A technique for osseous restoration of deficient edentulous maxillary ridges. *J Oral Maxillofac Surg.* 1985;43:87-91.
2. Astrand P, Nord PG, Branemark PI. Titanium implants and onlay bone graft to the atrophic edentulous maxilla: a 3-year longitudinal study. *J Oral Maxillofac Surg.* 1996;25:25-29.
3. Jensen J, Sindet-Pedersen S. Autogenous mandibular bone grafts and osseointegrated implants for reconstruction of the severely atrophied maxilla: a preliminary report. *J Oral Maxillofac Surg.* 1991;49:1277-1287.
4. Verhoeven JW, Cune MS, Terlouw

M, Zoon MAOW, de Putter C. The combined use of endosteal implants and iliac crest onlay grafts in the severely atrophic mandible: a longitudinal study. *J Oral Maxillofac Surg.* 1997;26:351–357.

5. Becker W, Becker B. Guided bone regeneration for implants placed into extraction socket and for implant dehiscences: surgical techniques and case reports. *Int J Periodont Rest Dent.* 1990;10:376–391.

6. Buser D, Dula K, Belser UC, Hirt

H-P, Berthold H. Localized ridge augmentation using guided bone regeneration. II. Surgical procedure in the mandible. *Int J Periodont Rest Dent.* 1995;15:10–29.

7. Jennings DE. Treatment of the mandibular compromised ridge: a literature review. *J Prosthet Dent.* 1989;61:575–579.

8. Kent JN, Quinn JH, Zide MF, Guerra LR, Boyne PJ. Alveolar ridge augmentation using nonresorbable hydroxylapatite with or without autoge-

nous cancellous bone. *J Oral Maxillofac Surg.* 1988;41:629–642.

9. Kethley JL. The lipswitch: a modification of Kazanjian's labial vestibuloplasty. *J Oral Surg.* 1978;36:701–705.

10. Wessberg GA. Transpositional flap technique for mandibular vestibuloplasty. *J Am Dent Assoc.* 1979;98:929–933.

11. Moon AC. Transpositional flap vestibuloplasty of the maxilla. *J Oral Maxillofac Surg.* 1983;41:272–273.