

# BONE REGENERATION GRAFT MATERIALS

David L. Hoexter, DMD

## KEY WORDS

Regeneration  
Osteoinduction  
Osteoconduction  
Alloplastic

This article focuses on the materials used for the regeneration, rather than repair, of the osseous support needed to anchor both teeth and implants. Once the bone was supportive, but now it is insufficient and must be restored. Specifically, the article examines different materials that aid in regeneration, as well as ones that do not. The pros and cons of osteoinduction and osteoconduction are compared. Autogenous, allographic, alloplastic, and xenographic materials are delineated and their intended purpose is described. These materials build the foundation of osseous support toward a functional future.

## INTRODUCTION

**B**one grafting therapy has become an integral part of dentistry. Patients are becoming more aware of grafting as a treatment modality and expect better predictability, fit, function and esthetics. Today, with the introduction of advanced bone grafting techniques and the use of sophisticated bone replacement graft materials, it is possible to increase the volume, width, and height of bone in deficient areas to regenerate the tissues supporting questionable teeth and to permit the placement of implants in ideal positions and angulations, which will result in more acceptable and predictable restorations.

Bone replacement graft materials have played an important role in regenerative dentistry for many years. At present we are being introduced to a host of new technology that will continue to improve the predictability and success rates of grafting procedures. There are four basic divisions of bone grafts: autogenous, allographic, alloplastic, and xenographic.

The ideal bone replacement graft material (BRGM) has always been au-

togenous bone.<sup>1-4</sup> This material forms bone by the processes of osteogenesis, osteoinduction, and osteoconduction. Osteogenesis is the mechanism of forming bone directly from osteoblasts. Osteoinductive materials are capable of inducing the transformation of mesenchymal cells into osteoblasts, thereby enhancing bone growth. Osteoconduction is the process that permits bone apposition from existing bone.

Autogenous bone is derived from the individual for whom the graft is intended. It has long been considered the gold standard of BGRM. It consists of two components. The first is a natural anatomical structure for scaffolding cellular invasion and for graft and host site support. The second offers a component of primarily type I collagen that provides pathways for vascularity and resilience. The vitality of such grafts may vary in their duration, some lasting a shorter duration than desired. Such grafts are harvested from the surgical patient from whom a second surgical wound site must be used. The use of autogenous bone, however, offers the promise of high levels of success while

*David L. Hoexter, DMD, is a clinical professor of periodontology at the University of Pittsburgh, Pittsburgh, Pa, and is in private practice. Address correspondence to Dr Hoexter at 654 Madison Avenue, New York, NY 10021.*

avoiding the possibilities of antigenicity.

Allografts are tissues taken from individuals of the same species as the hosts.<sup>5-21</sup> There are three main divisions: (1) frozen, (2) freeze-dried, and (3) freeze-dried demineralized. They come in different forms: particulate, gels, and putties. A major advantage of their use is that the material is readily available without the requirement of a secondary surgical site. They provide a source of type I collagen, which is the sole organic component of bone. However, they do not produce the inorganic calcium or scaffolding necessary for bone regeneration. Allographic bone must be processed to guarantee safety.

Alloplasts are synthetic. They contribute to the repair of osseous defects and to the enhancement of osseous ingrowth.<sup>22-38</sup> The chemical composition, physical form, and differences in surface configuration result in varying levels of bioresorbability. The varying nature of available commercial graft materials (porosity, geometries, differing solubilities and densities) will determine the resorption of these calcium phosphate-based graft materials.

Xenografts are derived from other species. They are materials with their organic components totally removed. With their removal, concern about immunological reactions becomes nonexistent. The remaining inorganic structure provides a natural architectural matrix as well as an excellent source of calcium.<sup>39-41</sup> The inorganic material also maintains the physical dimension of the augmentation during the remodeling phases.<sup>42</sup>

Suppliers, manufacturers, and users of BRGMs have been striving to meet the standards set by those who advocate the use of autogenous bone. For the past several decades, synthetic hydroxylapatites were used when adequate amounts of autogenous bone were not available. Synthetic, dense, nonresorbable hydroxylapatite is osteoconductive and biocompatible and permits bone apposition from adjacent bone. It does not form bone, and it will

not increase the volume of vital bone in a deficient area; therefore, synthetic hydroxylapatite has limited indications. One use is augmentation for the placement of conventional dentures. However, because this dense material neither resorbs nor remodels, implant placement through a grafted site is virtually impossible, thus further limiting its value.

Synthetic hydroxylapatite (tricalcium phosphate [TCP]) is also available in a resorbable form. As it resorbs, a readily available source of calcium becomes available in sites that have osteogenic potential. It is an osteoconductive material composed of very small, nonfused crystals, which yield cumulatively an extremely high surface area. It is a material of choice in 4 and 5 wall defects such as extraction sockets. Without grafting, such areas often will undergo facial ridge resorption, resulting in loss of the buccolingual dimension of the ridge.

Surgeons welcomed the introduction of xenografts containing calcium phosphate bone replacement.<sup>41-46</sup> Xenografts such as anorganic bovine-derived bone material (ABM) offered the mechanical and architectural components of bone that had been lacking in the synthetics. Because this material supplies a natural form of hydroxylapatite, it provides the readily available source of calcium that is so essential for bone formation. This material also fails to satisfy the standards set by those of autogenous bone because it does not have the organic, cellular component. To be effective in the process of bone regeneration, as with the synthetics, it must be placed in an osteogenic environment.

Combining the ABM with demineralized freeze-dried bone allograft (DFDBA) will satisfy the requisite formula of 2 components that have the potential to encourage the formation of natural bone. DFDBA is derived from human cadaver bone. It must be thoroughly screened, tested, and processed to eliminate any donor disease that

might threaten the health of the recipient.<sup>41</sup>

Research has shown dramatic variability in the osteoinductive properties of DFDBA. Some donor bone has shown no activity at all and simply provided a source of type I collagen. Osteoinduction, which can be demonstrated by bioassay analysis, offers a high probability of stimulating the growth of bone cells. But even the highest-quality DFDBA will not satisfy the 2-component model required to stimulate the formation of a mineral component (TCP), which must be added to satisfy the demands of this function.

In the past score of years, clinicians have learned to use the BGRMs that most satisfy the needs of specific sites, patients, and treatment plans.<sup>47-52</sup> Combinations of materials are used that are chosen from a wide variety of synthetics, xenografts, and allografts, often in conjunction with tissue-regenerative barrier membranes, all with the common goal of stimulating the formation of autogenous bone.<sup>52-56</sup>

As a result of research on the use of recombinant bone morphogenetic proteins (BMP) and tissue-derived growth factors for osseous regeneration, these materials have been positioned as the definitive answer for future osseous regeneration. BMPs are osteoinductive compounds that encourage new bone formation. At least 7 structurally unique BMPs have been identified that can induce bone formation as well as accelerate the process of bone regeneration. BMPs act as a signal in initiating and regulating specific tissue formation. This activity leads to a series of developmental processes that include chemotaxis, proliferation, and differentiation, which result in the transient formation of cartilage (endochondral bone formation) and the production of living bone tissue. At this time, both the technology and the production of the material are quite expensive. The effectiveness of BMPs in inducing new bone formation is in part contingent on delivery of these mole-

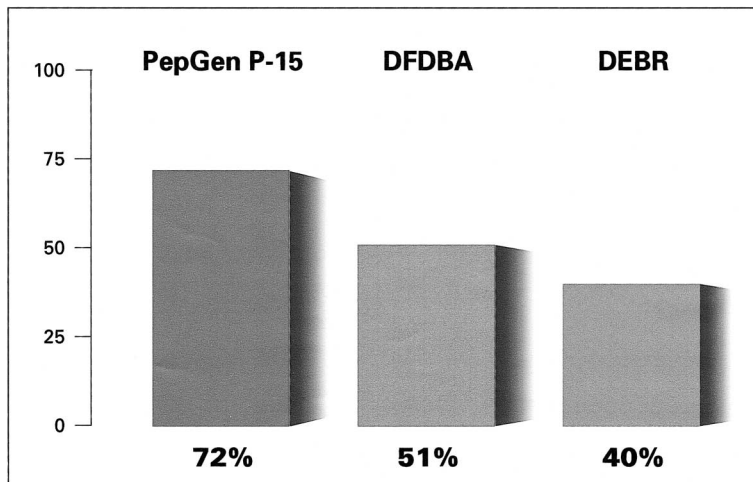


FIGURE 1. DFDBA<sup>2</sup> (demineralized freeze-dried bone allograft): Percent defect fill ( $P \leq .05$ ).

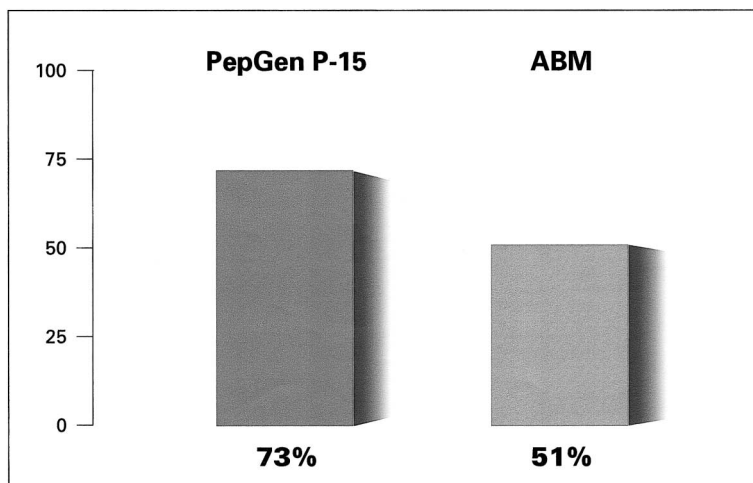


FIGURE 2. ABM (anorganic bovine bone mineral): Percent defect fill ( $P \leq .05$ ).

cules in a predictable manner. Several different materials that include both natural and synthetic polymers and bioceramics have been evaluated as potential carriers for BMP. To date, collagen has shown the most promise. However, because of the unpredictable nature of collagen metabolism, large levels of variability in the clinical effectiveness of BMP can be expected. Although BMPs hold promise as an advanced means for bone regeneration, their arrival in the marketplace has been long delayed. The latest reports suggest that approval for their use in humans in the United States may still be 2–3 years in the future.

Incorporation affecting the activity

of cellular processes into the design of biomaterials has been approached in additional allied efforts. In October 1999, an alternate method was approved by the Food and Drug Administration. It was based on the use of natural osteogenic phenomena.

Scientists and clinicians have long recognized the importance of collagen as a biomaterial because of its singular role as a major component of bone. The primary function of collagen is to act as tracks on which cells can move. Whereas collagen influences the cellular processes, the hydroxylapatite provides the structural and morphological support required for cell attachment. The advances in molecular modeling

techniques have allowed a close examination of the collagen molecule. Detailed analyses have revealed that a 15-residue amino acid sequence within a chain of type I collagen is responsible for its cell-binding functions.<sup>57</sup> This discovery led to the isolation and production of a synthetic material called P-15. As a first step, to mimic the physiological nature of bone, a composite of P-15 and natural anorganic bone mineral (ABM) was examined. ABM/P-15 is a synthetic, collagen-like agent that imitates autogenous bone. The inorganic/mechanical component, ABM, is composed of calcium phosphate and duplicates the natural anatomic structure of autogenous bone necessary for cellular invasion. The organic component is represented by P-15. The synthetic 15-amino-acid peptide, which repeats the cell-binding domain of type I collagen, modulates cell bonding, migrations, proliferation, and differentiation.<sup>57–59</sup>

This material, PepGen P-15 (CeraMed, Lakewood, Colo), provides a tissue-engineered hospitable biomimetic habitat for cells and serves as a bonelike substitute for autogenous bone grafts. In clinical studies, PepGen P-15 demonstrated an increased expression of growth factors TGF $\beta$ ,<sup>57–59</sup> the agents associated with osteodifferentiation. PepGen P-15 has been demonstrated and clinically shown to have predictable benefits over other currently marketed bone graft replacement materials (Figures 1 and 2).<sup>41,44,60</sup>

The research and development of bone replacement graft materials is promising and continues to approach the production of the ultimate material. In the interim, the BRGM that most closely resembles the standard awarded to autogenous bone should be the practitioner's first choice.

#### ACKNOWLEDGMENTS

The author wishes to acknowledge E. Burger, B. Atkinson, and J. Zeizer for their assistance in the preparation of this article.

## REFERENCES

1. Robinson RE. Osseous coagulum for bone induction. *J Periodontol.* 1969;40:503-510.
2. Schallhorn RG, Hiatt WH, Boyce W. Iliac transplants in periodontal therapy. *J Periodontol.* 1970;41:566-580.
3. Froum SJ, Thaler R, Scopp JW, Stahl SS. Osseous autografts. I. clinical responses to bone blend or hip marrow grafts. *J Periodontol.* 1975;46:515-521.
4. Barnett JD, Mellonig JT, Gary JL, Towle HJ. Comparison of freeze-dried bone allograft and porous hydroxylapatite in human periodontal defects. *J Periodontol.* 1989;60:231-237.
5. Schallhorn RG, Hiatt WH. Human allografts of iliac cancellous bone and marrow in periodontal osseous defects. II. clinical observations. *J Periodontol.* 1972;43:67-81.
6. Sandors JJ, Sepe WW, Bowers GM, et al. Clinical evaluation of freeze-dried bone allografts in periodontal osseous defects. Part III. composite freeze-dried bone allografts with and without autogenous bone grafts. *J Periodontol.* 1983;54:1-8.
7. Mabry TW, Yukna RA, Sepe WW. Freeze-dried bone allografts combined with tetracycline in the treatment of juvenile periodontitis. *J Periodontol.* 1985;56:74-81.
8. Schrad SC, Tussing GJ. Human allografts of iliac bone and marrow in periodontal osseous defects. *J Periodontol.* 1986;57:205-210.
9. Quintero G, Mellonig JT, Gambill VM, Pelleu GB. A six-month clinical evaluation of decalcified freeze-dried bone allografts in periodontal osseous defects. *J Periodontol.* 1982;60:231-237.
10. Bowen JA, Mellonig JT, Gray JL, Towle HJ. Comparison of decalcified freeze-dried bone allograft and porous particulate hydroxyapatite in human periodontal osseous defects. *J Periodontol.* 1989;60:647-654.
11. Rummelhart JM, Mellonig JT, Gray JL, Towle HJ. A comparison of freeze-dried bone allograft and demineralized freeze-dried bone allograft in human periodontal osseous defects. *J Periodontol.* 1989;60:655-663.
12. Nery EB, Lynch KL, Hirthe WM, Mueller KH. Bioceramic implants in surgically produced infrabony defects. *J Periodontol.* 1975;46:328-347.
13. Hoexter DL. The use of durapatite ceramic implant in the treatment of juvenile periodontitis: a case report. *Compendium of Continuing Education.* 1986;7(7):458-467.
14. Piatelli A, Scarano A, Corigliano M, Piatelli M. Comparison of bone regeneration with the use of mineralized and demineralized freeze-dried bone allografts: a histological and histochemical study in man. *Biomaterials.* 1996;17:1127-1131.
15. Quintero G, Mellonig JT, Gambill VM, Pelleu GB. A six-month clinical evaluation of decalcified freeze-dried bone allografts in periodontal osseous defects. *J Periodontol.* 1982;53:726-730.
16. Mellonig JT. Decalcified freeze-dried bone allograft as an implant material in human periodontal defects. *Int J Periodontics Restorative Dent.* 1984;4(6):40-55.
17. Reynolds MA, Bowers GM. Fate of demineralized freeze-dried bone allografts in human intrabony defects. *J Periodontol.* 1996;67:150-157.
18. Francis J, Brunsvold M, Prewett A, Mellonig J. Clinical evaluation of an allogeneic bone matrix in the treatment of periodontal osseous defects. *J Periodontol.* 1995;66:1074-1079.
19. Becker W, Becker BE, Caffesse R. A comparison of demineralized freeze-dried bone and autologous bone to induce bone formation in human extraction sockets. *J Periodontol.* 1994;65:1128-1133.
20. Smukler H, Landi L, Setayesh R. Histomorphometric evaluation of extraction sockets and deficient alveolar ridges treated with allograft and barrier membrane: a pilot study. *Int J Oral Maxillofac Implants.* 1999;14:407-416.
21. Schwartz Z, Mellonig JT, Carnes DL Jr, et al. Ability of commercial demineralized freeze-dried bone allograft to induce new bone formation. *J Periodontol.* 1996;67:918-926.
22. Rabalais ML, Yukna RA, Mayer ET. Evaluation of durapatite ceramic as an alloplastic implant in periodontal osseous defects. I. initial six-month results. *J Periodontol.* 1981;52:680-689.
23. Meffert RM, Thomas JR, Hamilton KM, Brownstein CN. Hydroxylapatite as an alloplastic graft in the treatment of human periodontal osseous defects. *J Periodontol.* 1985;56:63-73.
24. Kenney EB, Lekovic V, Han T, Carranza FA Jr, Dimitrijevic B. The use of a porous hydroxylapatite implant in periodontal defects. I. clinical results after six months. *J Periodontol.* 1985;56:82-88.
25. Yukna RA, Harrison BG, Caudill RE, Evans GH, Mayer ET, Miller S. Evaluation of durapatite ceramic as an alloplastic implant in periodontal osseous defects. II. twelve-month reentry results. *J Periodontol.* 1985;56:540-547.
26. Yukna RA, Cassingham RJ, Caudill RE, et al. Six-month evaluation of calcitite (hydroxyapatite ceramic) in periodontal osseous defects. *Int J Periodontics Restorative Dent.* 1986;6(3):35-45.
27. Yukna RA. Osseous defect responses to hydroxylapatite grafting versus open flap debridement. *J Clin Periodontol.* 1989;16:398-402.
28. Yukna RA. Clinical evaluation of coralline calcium carbonate as a bone replacement graft material in human periodontal osseous defects. *J Periodontol.* 1994;65:177-185.
29. Evans GH, Yukna RA, Cambre KM, Gardiner DL. Clinical regeneration with guided tissue barriers: an analysis of the current literature. *Curr Opin Periodontol.* 1997;4:75-81.
30. Boetto J, Freeman E. Histologic evaluation of durapatite in experimental periodontal defects. *J Can Dent Assoc.* 1984;50:239-244.
31. Sapkos S. The use of Periograf in periodontal defects: histologic findings. *J Periodontol.* 1986;57:7-13.
32. Froum S, Stahl SS. Human intraosseous healing responses to the placement of tricalcium phosphate ce-

ramic implants. II. thirteen to eighteen months. *J Periodontol.* 1987;58:103–109.

33. Hoexter DL. The use of tricalcium phosphate (synthograft). Part I: its use in extensive periodontal defects. *Jnl Houston District Dent Soc.* November 1987:22–23.

34. Froum SJ, Kushner I, Scopp IW, Stahl SS. Human clinical and histologic responses to durapatite implants in intraosseous lesions: case reports. *J Periodontol.* 1982;53:719–725.

35. Stahl SS, Froum SJ. Histologic and clinical responses to porous hydroxylapatite implants in human periodontal defects: Three to twelve months postimplantation. *J Periodontol.* 1987;58:689–695.

36. Carranza FA Jr, Kenney EB, Lekovic V, Talamante E, Valencia J, Dimitrijevic B. Histologic study of healing of human periodontal defects after placement of porous hydroxylapatite implants. *J Periodontol.* 1987;58:682–688.

37. Kenney EB, Lekovic V, Sa Ferreira JC, Han T, Dimitrijevic B, Carranza FA Jr. Bone formation within porous hydroxylapatite implants in human periodontal defects. *J Periodontol.* 1986;57:76–83.

38. Becker W, Clokie C, Sennerby L, Urist MR, Becker BE. Histologic findings after implantation and evaluation of different grafting materials and titanium micro screws into extraction sockets: case reports. *J Periodontol.* 1998;69:414–421.

39. Zaner DJ, Yukna RA. Particle size of periodontal bone grafting materials. *J Periodontol.* 1984;55:406–409.

40. Callan DP, Rohrer MD. Use of bovine-derived hydroxyapatite in the treatment of edentulous ridge defects: a human clinical and histologic case report. *J Periodontol.* 1993;64:575–582.

41. Yukna RA, Callan DP, Krauser JT, et al. Multi-center clinical evaluation of combination anorganic bovine-derived hydroxyapatite matrix (ABM)/cell binding peptide (P-15) as a bone replacement graft material in human

periodontal osseous defects: 6-month results. *J Periodontol.* 1998;69:655–663.

42. Misch CE, Dietsh F. Bone grafting materials in implant dentistry. *Implant Dent.* 1993;2(3):158–167.

43. Gross JS. Bone grafting materials for dental applications: a practical guide. *Compend Cont Educ Dent.* 1997;18(10):1013–1018, 1020–1022, 1024.

44. Yukna RA, Krauser JT, Callan DP, Evans GH, Cruz R, Martin M. Multi-center clinical comparison of combination anorganic bovine-derived hydroxyapatite matrix (ABM)/cell binding peptide (P-15) and ABM in human periodontal osseous defects: 6-month results. *J Periodontol.* 2000;71:1671–1679.

45. Richardson CR, Mellonig JT, Brunsvold MA, McDonnell HT, Cochran DL. Clinical evaluation of Bio-Oss: A bovine-derived xenograft for the treatment of periodontal osseous defects in humans. *J Clinical Periodontol.* 1999;26:421–428.

46. Laurell L, Gottlow J, Zybutz M, Persson R. Treatment of intrabony defects by different surgical procedures: a literature review. *J Periodontol.* 1998;69:303–313.

47. Lovelace TB, Mellonig JT, Mefert RM, Jones AA, Nummikoski PV, Cochran DL. Clinical evaluation of bioactive glass in the treatment of periodontal osseous defects in humans. *J Periodontol.* 1998;69:1027–1035.

48. Hoexter DL. The use of decalcified freeze-dried bone allograft (DFDBA) for more successful endosseous implants. *Implantologist.* 1983–1984;3(1):13–18.

49. Hoexter DL. Endosteal lade implants with tricalcium phosphate—a technique for a more predictable prognosis. *New York Jnl Dent.* 1986;56(6):214–220.

50. Ong M, Eber RM, Korsnes MI, et al. Evaluation of a bioactive glass alloplast in treating periodontal intrabony defects. *J Periodontol.* 1998;69:1346–1354.

51. Heijl L, Heden G, Svardstrom G, Ostgren, A. Enamel matrix deriva-

tive (EMDOGAIN) in the treatment of intrabony periodontal defects. *J Clin Periodontol.* 1997;24(9, pt 2):705–714.

52. Hoexter DL. Poncho-guided tissue regeneration. *J Oral Implantol.* 1991;17:418–422.

53. Mellonig JT, Triplett RG. Guided tissue regeneration and endosseous dental implants. *Int J Periodontics Restorative Dent.* 1993;13:108–119.

54. Becker W, Becker BE, Berg L, Prichard J, Caffesse R, Rosenberg E. New attachment after treatment with root isolation procedures: report for treated class III and class II furcations and vertical osseous defects. *Int J Periodontics Restorative Dent.* 1988;8:8–23.

55. Nyman S, Gottlow J, Karring T, Lindhe J. The regenerative potential of the periodontal ligament: an experimental study in the monkey. *J Clin Periodontol.* 1982;9:257–265.

56. Gottlow J. *New Attachment Formation by G.T.R.* Department of Periodontology, University of Gothenburg, Sweden; 1986.

57. Bhatnagar RS, Qian JJ, Wedrychowska A, Sadeghi M, Wu YM, Smith N. Design of biomimetic habitats for tissue engineering with P-15, a synthetic peptide analogue of collagen. *Tissue Eng.* 1999;5(1):53–65.

58. Bhatnagar RS, Qian JJ, Wedrychowska A, Dixon E, Smith N. Biomimetic habitats for cells: ordered matrix deposition and differentiation in gingival fibroblasts cultured on hydroxyapatite coated with a collagen analogue. *Cells and Mater.* 1999;9(2):93–104.

59. Bhatnagar RS, Qian JJ, Wedrychowska A, Smith N. Construction of biomimetic environments with a synthetic peptide analogue of collagen. *Mater Res Soc Symp Proc.* 1998;530:43–54.

60. Yukna RA, Krauser JT, Callan DP, Evans GH, Cruz R, Millicent M. Thirty-six month follow-up of 25 patients treated with combination anorganic bovine-derived hydroxyapatite matrix (ABM)/cell-binding peptide (P-15) bone replacement grafts in human intrabony defects. I. clinical findings. *J Periodontol.* 2002;73(1):123–128.