

BONE CONTACT AROUND ACID-ETCHED IMPLANTS: A HISTOLOGICAL AND HISTOMORPHOMETRICAL EVALUATION OF TWO HUMAN-RETRIEVED IMPLANTS

Marco Degidi, MD, DDS
Giovanna Petrone, DDS, PhD
Giovanna Iezzi, DDS
Adriano Piattelli, MD, DDS

KEY WORDS

Acid etching
Bone contact
Osseotite
Implant surface

The surface characteristics of dental implants play an important role in their clinical success. One of the most important surface characteristics of implants is their surface topography or roughness. Many techniques for preparing dental implant surfaces are in clinical use: turning, plasma spraying, coating, abrasive blasting, acid etching, and electropolishing. The Osseotite surface is prepared by a process of thermal dual etching with hydrochloric and sulfuric acid, which results in a clean, highly detailed surface texture devoid of entrapped foreign material and impurities. This seems to enhance fibrin attachment to the implant surface during the clotting process. The authors retrieved 2 Osseotite implants after 6 months to repair damage to the inferior alveolar nerve. Histologically, both implants appeared to be surrounded by newly formed bone. No gaps or fibrous tissues were present at the interface. The mean bone-implant contact percentage was 61.3% ($\pm 3.8\%$).

Marco Degidi, MD, DDS, is a visiting professor in the Dental School at the University of Chieti, Italy, and is in private practice in Bologna, Italy.

Giovanna Petrone, DDS, PhD, is a postdoctoral fellow in the Dental School, University of Chieti, Italy.

Giovanna Iezzi, DDS, is a research fellow in the Dental School, University of Chieti, Italy.

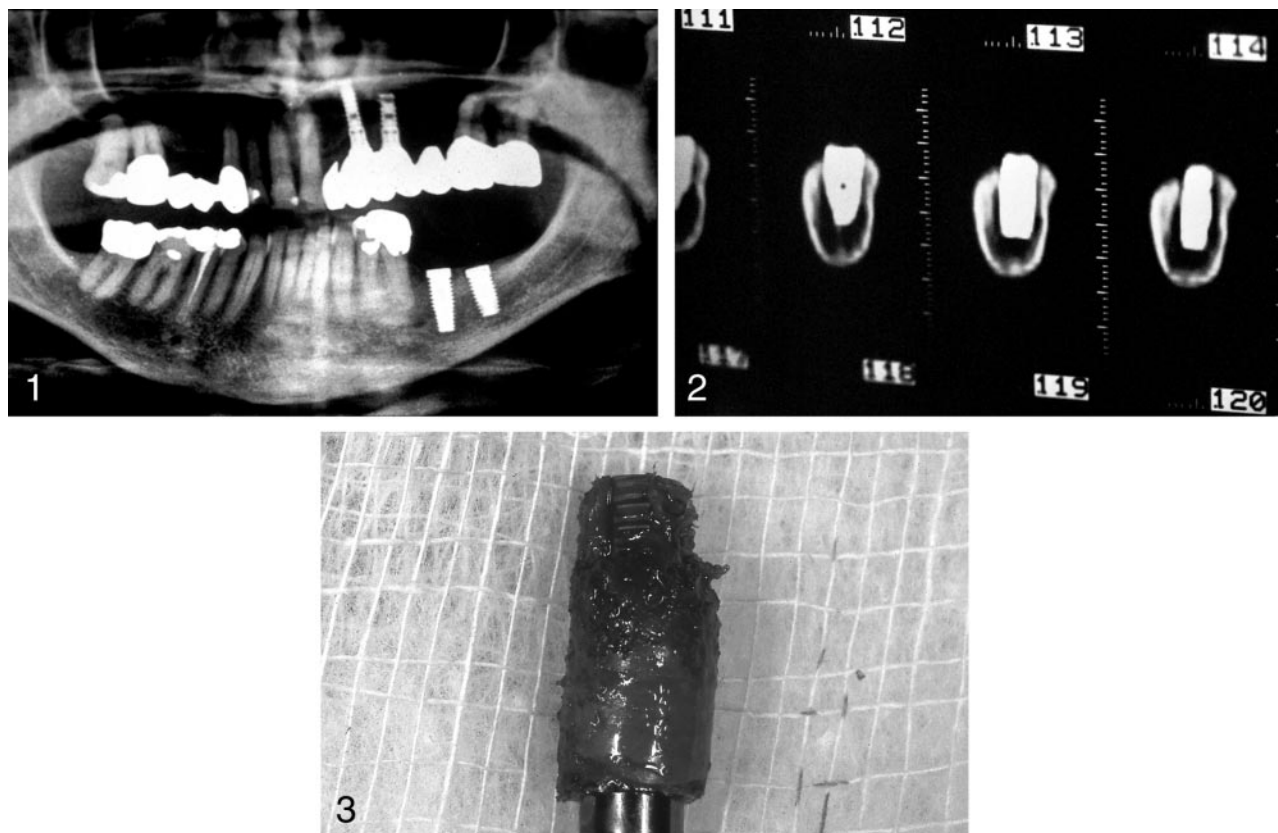
Adriano Piattelli, MD, DDS, is a professor of Oral Medicine and Pathology and dean and director of studies and research at the Dental School, University of Chieti, Italy. Address correspondence to Dr Piattelli at Via F. Sciucchi 63, Chieti, Italy 66100 (e-mail: apiattelli@unich.it).

INTRODUCTION

Initial stability of an implant is important for successful tissue integration, and early osseointegration is important for long-term implant stability.^{1,2} Improved survival of dental implants in areas of poor bone quality and quantity is important, and this fact inspired a search for an improved surface that could enhance bone-implant contact percentages.³ These implant surface features have been demonstrated to be the only ones that influence the amount of bone-implant contact

percentage and interface shear strength.^{3,4} Modifications of the implant surface features produce an increase of the retention between the implant and the bone by enlarging the contact surface, increasing the biomechanical interlocking between implant and bone, and by enhancing osteoblast activity with an earlier formation of bone at the interface.³⁻⁵

An increase of the bone-implant contact percentages with increasing roughness of the implant surface has been reported.⁶⁻¹⁰ Greater surface



FIGURES 1-3. FIGURE 1. The implants have been inserted in the left mandible. FIGURE 2. CT scan. The implants are near to the inferior alveolar nerve. FIGURE 3. One of the retrieved implants.

roughness increases the implant surface area and increases the potential for interlocking of bone into the implant surface.^{11,12} However, surface roughness is not the only aspect of surface topography affecting osseointegration of dental implants; for example, the increased surface roughness does not explain the differences observed when comparing sandblasted and titanium plasma-sprayed surfaces.¹¹ Other factors that probably have a role are ionic charge, surface energy, and surface tension.⁷⁻¹¹

Acid etching appears to greatly enhance the potential for osseointegration, especially in the earliest stages of peri-implant bone healing. Moreover, with this technique there is no need for external agents that could contaminate the implant surface.¹¹ Acid treatment produces a clean, highly detailed surface texture that lacks entrapped surface material and impurities.^{2,11} This

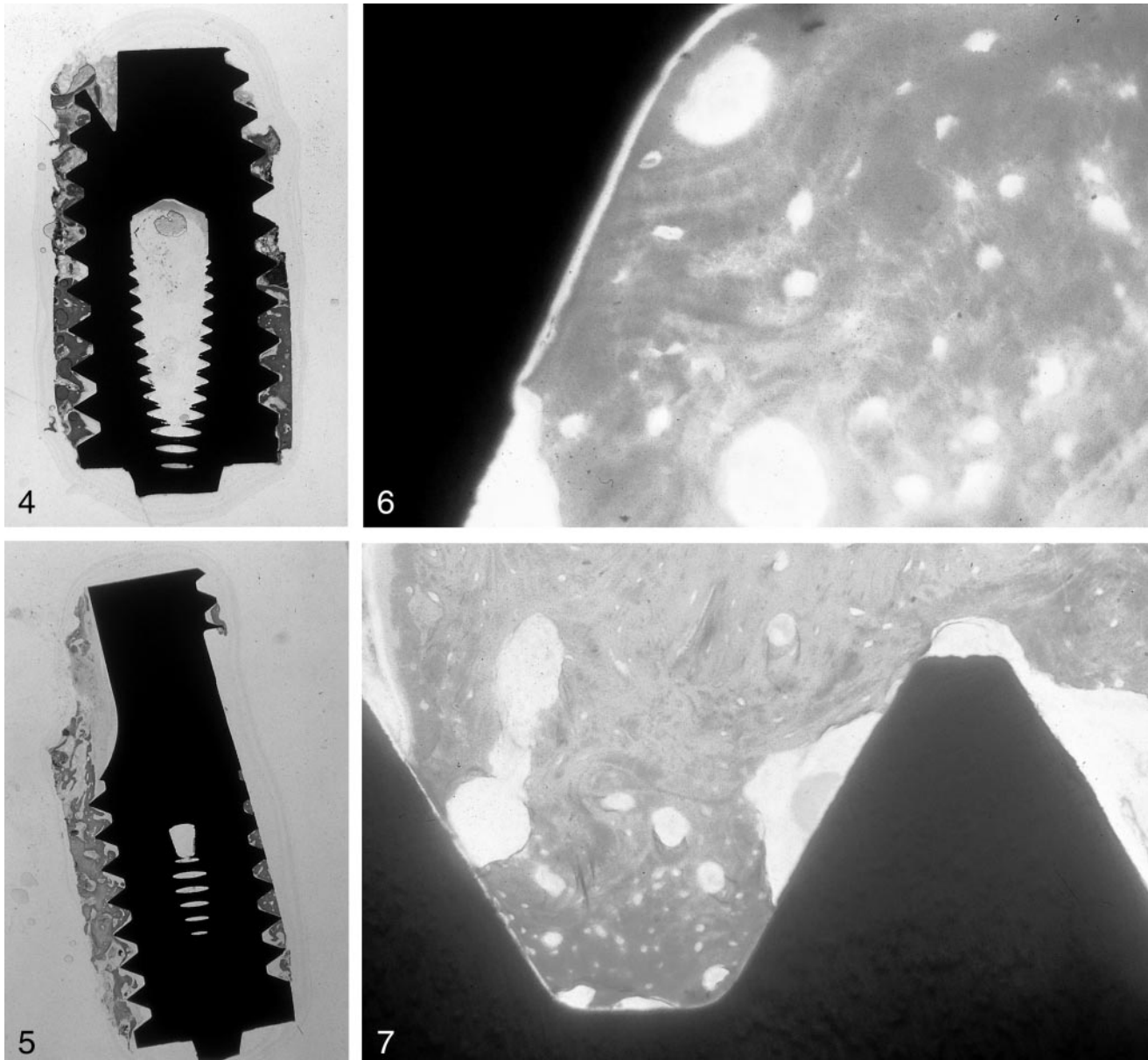
textured implant surface has been reported to have a positive affect on the biologic response of bone in terms of early bone apposition, a higher percentage of direct bone-to-implant contact, and strong implant anchorage.^{2,11} Acid etching creates an even distribution of very small (1 to 2 μm) peaks and valleys and large features of 6 to 10 μm .^{2,11}

Chehroudi et al¹³ showed that a modification of the implant surface topography influenced the frequency and the amount of bone deposited adjacent to implants, and the areas of mineralization were guided by the surface topography. Surface roughness alters the responsiveness of osteoblasts to systemic hormones.¹⁴ Only a few studies of in situ osseointegrated implants without complications and with an intact bone-implant interface have been reported in the literature.¹⁵⁻¹⁸ The analysis of human specimens is ex-

tremely useful to validate the experimental results obtained from animals. The aim of our study was a histologic and histomorphometric report of 2 implants with an acid-etched surface that were removed after 6 months because of damage to the inferior alveolar nerve in order to evaluate the healing events in the peri-implant tissues around this type of surface.

CASE REPORT

In another clinic, a 56-year-old female patient underwent the insertion of 2 threaded, acid-etched, titanium, screw-shaped implants (Osseotite, 3i, Implant Innovations, West Palm Beach, Fla) in the left mandible (Figure 1). Two months after the surgical procedure, the patient started to experience a dull pain in the left mandible; this pain increased in the following months, and 6 months after the surgical procedure the patient was referred to one of us



FIGURES 4-7. FIGURE 4. At low-power magnification, newly formed bone can be observed at the implant-bone interface (Toluidine blue and acid fuchsin, original magnification $\times 12$). FIGURE 5. Newly formed bone is present at the bone-implant interface. FIGURE 6. No gaps are present at the interface (Toluidine blue and acid fuchsin, original magnification $\times 200$). FIGURE 7. Newly formed bone and marrow spaces are present at the interface with the implant (Toluidine blue and acid fuchsin, original magnification $\times 100$).

(M.D.). The patient complained of increasing pain and paresthesia; it was then decided to remove both implants. A CT scan showed that the implants were in close contact with the inferior alveolar nerve (Figure 2). The implants were retrieved with a 5 mm trephine (Figure 3).

The specimens were immediately stored in 10% buffered formalin and

processed to obtain thin ground sections with the Precise 1 Automated System (Assing, Rome, Italy).¹⁹ The specimens were dehydrated in an ascending series of alcohol rinses and embedded in a glycolmethacrylate resin (Technovit 7200 VLC, Kulzer, Wehrheim, Germany). After polymerization the specimens were sectioned longitudinally along the major axis of the im-

plant with a high-precision diamond disc at about 150 μm and ground down to about 30 μm .

Three slides were obtained for each implant and stained with acid fuchsin and toluidine blue. A double staining with von Kossa and acid fuchsin was also done to evaluate the degree of bone mineralization, and one slide per implant, after polishing, was im-

mersed in AgNO₃ for 30 minutes and exposed to sunlight; the slides were then washed under tap water, dried and immersed in basic fuchsin for 5 minutes, and then washed and mounted.

The percentage of bone contact was calculated using a light microscope (Laborlux S, Leitz, Wetzlar, Germany) connected to a high-resolution video camera (3CCD, JVC KY-F55B, JVC Professional Products, Milan, Italy) and interfaced to a monitor and PC (Intel Pentium III 1200 MMX, Intel Ireland Ltd, Kildare, Ireland). This optical system was associated with a digitizing pad (Matrix Vision GmbH, Oppenweiler, Germany) and a histometry software package with image-capturing capabilities (Image-Pro Plus 4.5, Media Cybernetics Inc, Immagini and Computer Snc, Milan, Italy).

RESULTS

Radiographically and clinically, both implants appeared to be osseointegrated. At low-power magnification both implants appeared to be surrounded by newly formed bone (Figures 4 and 5). At higher magnification, the bone was compact and mature with small marrow spaces (Figure 6). Remodeling areas were present. In some portions of the interface the bone appeared in close contact with the implant surface, whereas in other areas marrow spaces were present (Figure 7). The bone-implant contact percentage for both implants was a mean 61.3% ($\pm 3.8\%$). No inflammatory or multinucleated cells were present. No foreign body reaction was found at the bone-implant interface. The newly formed bone showed many viable osteocytes. No epithelial downgrowth was observed at the interface.

DISCUSSION

Implant surface modifications are important because direct bone-implant contact is created between the molecules of the bone tissue and the titanium dioxide layer at the implant surface.¹ The geometric properties of the

surface produce mechanical restrictions on the cytoskeletal cell components, which are involved in the spreading and locomotion of the cells.²⁰ Cellular adhesion is related to surface-free energy of the substratum, and surfaces with a low surface-free energy are reported to be less adhesive.²⁰ Surface roughness seems to have an effect on the osteoblast differentiation and the formation of a differentiated matrix.²¹ Surface roughness may be one of the most important factors determining long-term implant success, especially in low bone quality and quantity areas.²²

The proliferation and differentiation of cells has been reported to be enhanced by surface roughness,^{23,24} and Mustafa et al²² demonstrated that DNA synthesis appeared to be dependent on surface roughness. Osteoblast matrix formation and mineralization, in a multilayering culture system, is modified by surface topography.²¹ The Osseotite surface is created by a process of thermal dual acid etching with hydrochloric and sulfuric acids; this treatment produces a clean surface with no embedded materials or impurities on the surface.²⁵

It has been reported that acid etching enhanced early endosseous integration to a level similar to that observed around the more complex titanium plasma-sprayed surface.² The acid treatment seems to have an additional stimulating influence on bone apposition.⁶ This acid attack helps in producing a more stable adhesion of the blood clot, and this fact could help obtain intimate and earlier bone contact.²⁶⁻²⁸ Osteoblast-like cells respond to increasing surface roughness with a decreased proliferation and an increased differentiation of the osteoblasts: alkaline phosphatase, osteocalcin, Transforming Growth Factor beta, and PGE₂ production is increased²⁴. Abrahamsson et al³ found that the proportion of mineralized bone between threads and outside the threads was nearly identical in turned and Osseotite implants; this fact could indicate

that the surface characteristics of an implant may influence tissue reactions only in a narrow area near the implant surface. Klokkevold et al¹¹ compared the resistance to removal torque forces in the femur of rabbits. They used 2 surfaces: acid-etched (Osseotite) and machined. It was found that after a 2-month healing period the force necessary to remove the acid-etched implants was 4 times greater than that needed in the machined implants. The osteoconductive nature of the microtextured Osseotite surface may increase the rate at which new bone forms on the implant.²⁹⁻³² The higher and earlier bone contact reported for thermal dual-etched surfaces has been attributed to the fixation of fibrin to the surface, to an enhancing of bone growth through enhancing levels of bone growth factors, and to an increased activation of platelets that leads up to an up-regulation of osteogenic responses.³²

ACKNOWLEDGMENTS

This work was partially supported by the National Research Council (CNR) and by the Ministry of Education, University, and Research (MIUR), Rome, Italy.

REFERENCES

- Ericsson I, Johansson CB, Bystedt H, Norton MR. A histomorphometric evaluation of bone-to-implant contact on machine-prepared and roughened titanium dental implants: a pilot study in the dog. *Clin Oral Implant Res.* 1994;5:201-206.
- Klokkevold PR, Johnson P, Dadgostari S, Caputo A, Davies JE, Nishimura RD. Early endosseous integration enhanced by dual acid etching of titanium: a torque removal study in the rabbit. *Clin Oral Implant Res.* 2001;12:350-357.
- Abrahamsson I, Zitzmann NU, Berglundh T, Wennenberg A, Lindhe J. Bone and soft tissue integration to titanium implants with different implant topography: an experimental

study in the dog. *Int J Oral Maxillofac Implants*. 2001;16:323–332.

4. Cochran DL, Nummikoski PV, Higginbottom FL, Hermann JS, Makins SR, Buser D. Evaluation of an endosseous titanium implant with a sandblasted and acid-etched surface in the canine mandible: radiographic results. *Clin Oral Implant Res*. 1996;7:240–252.

5. Wennenberg A, Albrektsson T, Anderson B, Kroll JJ. A histomorphometric and removal torque study of screw-shaped titanium implants with three different surface topographies. *Clin Oral Implant Res*. 1995;6:24–30.

6. Buser D, Schenk RK, Steinemann S, Fiorellini JP, Fox CH, Stich H. Influence of surface characteristics on bone integration of titanium implants: a histometric study in miniature pigs. *J Biomed Mater Res*. 1991;25:889–902.

7. Wennenberg A, Ektessabi A, Albrektsson R, Johansson C. One year follow-up of differing surface roughnesses placed in rabbit bone. *Int J Oral Maxillofac Implants*. 1997;12:486–494.

8. Wennenberg A, Albrektsson T, Andersson B. Bone tissue response to commercially pure titanium implants blasted with fine and coarse particles of aluminum oxide. *Int J Oral Maxillofacial Implants*. 1996;11:38–45.

9. Wennenberg A, Albrektsson T, Johansson C, Andersson B. Experimental study of turned and grit-blasted screw-shaped implants with special emphasis on effects of blasting material and surface topography. *Biomaterials*. 1996;17:15–22.

10. Wennenberg A, Hallgren C, Johansson C, Danelli S. A histomorphometric evaluation of screw-shaped implants each prepared with two surface roughnesses. *Clin Oral Implant Res*. 1998;9:11–19.

11. Klokkevold PR, Nishimura RD, Adachi M, Caputo A. Osseointegration enhanced by chemical etching of titanium surface: a torque removal study in the rabbits. *Clin Oral Implant Res*. 1997;8:442–447.

12. Schwartz Z, Kieswetter K, Dean DD, Boyan BD. Underlying mech-

anisms at the bone surface interface during regeneration. *J Periodontal Res*. 1997;32:166–171.

13. Chehroudi B, McDonnell D, Brunette DM. The effects of micromachined surfaces on formation of bone-like tissue on subcutaneous implants as assessed by radiography and computer image processing. *J Biomed Mater Res*. 1997;34:279–290.

14. Lohmann CH, Sagun R, Sylvia VL, et al. Surface roughness modulates the response of MG 63 osteoblast-like cells to 1,25-(OH)₂D₃ through regulation of phospholipase A₂ activity and activation of protein kinase A. *J Biomed Mater Res*. 1999;37:139–151.

15. Ledermann PD, Schenk RK, Buser D. Long-lasting osseointegration of immediately loaded bar-connected TPS screws after 12 years of function: a histologic case report of a 95-year-old patient. *Int J Periodont Rest Dent*. 1998;18:553–563.

16. Rohrer MD, Sobczack RR, Prasad HS, Morris HF. Postmortem histologic evaluation of mandibular titanium and maxillary hydroxyapatite-coated implants from 1 patient. *Int J Oral Maxillofac Implants*. 1999;14:579–586.

17. Proussaefs PT, Tatakis DN, Lozada J, Caplanis N, Rohrer MD. Histologic evaluation of hydroxyapatite-coated root-form implants retrieved after 7 years in function: a case report. *Int J Oral Maxillofac Implants*. 2000;15:438–443.

18. Proussaefs P, Lozada J, Ojano M. Histologic evaluation of threaded HA-coated root-form implants after 3.5 to 11 years of function: a report of three cases. *Int J Periodont Rest Dent*. 2001;21:21–29.

19. Piattelli A, Scarano A, Quaranta M. High-precision, cost-effective system for producing thin sections of oral tissues containing dental implants. *Biomaterials*. 1997;18:577–579.

20. Den Braber ET, De Ruijter JE, Smits HTJ, Ginsel LA, Von Recum AF, Jansen JA. Effect of parallel surface microgrooves and surface energy on cell growth. *J Biomed Mater Res*. 1995;29:511–518.

21. Cooper LF, Masuda T, Whitson SW, Yliheikkilä P, Felton DA. Formation of mineralizing osteoblast cultures on machined, titanium oxide grit-blasted, and plasma-sprayed titanium surfaces. *Int J Oral Maxillofac Implants*. 1999;14:37–47.

22. Mustafa K, Wennenberg A, Wroblek J, Hultenby K, Silva Lopez B, Arvidson K. Determining optimal surface roughness of TiO₂ blasted titanium implants material for attachment, proliferation and differentiation of cells derived from human mandibular alveolar bone. *Clin Oral Implant Res*. 2001;15:515–525.

23. Martin JY, Schwartz Z, Hummert TW, Schraub DM, Simpson J, Cochran DL. Effect of titanium surface roughness on proliferation, differentiation and protein synthesis of human osteoblast-like cells. *J Biomed Mater Res*. 1995;29:389–401.

24. Schwartz Z, Lohmann CH, Oefinger J, Bonewald LF, Dean DD, Boyan BD. Implant surface characteristics modulate differentiation behavior of cells in the osteoblastic lineage. *Adv Dent Res*. 1999;13:38–48.

25. Testori T, Wiseman L, Woolfe S, Porter SS. A prospective multicenter clinical study of the Osseotite implant: four-year interim report. *Int J Oral Maxillofac Implants*. 2001;16:193–200.

26. Cochran DL, Buser D. Bone response to sandblasted and acid-attacked titanium: experimental and clinical studies. In: Davies JE, ed. *Bone Engineering*. Toronto, Canada: Em Squared; 2000;391–398.

27. Buser D, Nydegger T, Hirt HP, Cochran DL, Nolte LP. Removal torque values of titanium implants in the miniature pigs. *Int J Oral Maxillofac Implants*. 1998;13:611–619.

28. Cordioli G, Majzoub Z, Piattelli A, Scarano A. Removal torque and histomorphometric investigation of different titanium surfaces: an experimental study in the rabbit tibia. *Int J Oral Maxillofac Implants*. 2000;15:669–674.

29. Testori T, Smukler-Moncler S, Francetti L, et al. Immediate loading of Osseotite implants: a case report and histologic analysis after 4 months of

occlusal loading. *Int J Periodont Rest Dent.* 2001;21:451–459.

30. Khang W, Feldman S, Hawley CE, Gunsolley J. A multicenter study comparing dual acid-etched and machined-surfaced implants in various bone qualities. *J Periodontol.* 2001;72:1384–1390.

31. Novaes AB, Souza SLS, de Oliveira PT, Souza AMMS. Histomorphometric analysis at the bone-implant contact obtained with 4 different implant surface treatments placed side by side in the dog mandible. *Int J Oral Maxillofac Implants.* 2002;17:377–383.

32. London RM, Roberts FA, Baker DA, Rohrer MD, O'Neal RB. Histologic comparison of a thermal dual-etched implant surface to machined, TPS, and HA surfaces: bone contact in vivo in rabbits. *Int J Oral Maxillofac Implants.* 2002;17:369–376.