

A COMPARISON OF ALLOGENEIC AND AUTOGENOUS ILIAC MONOCORTICAL GRAFTS TO AUGMENT THE DEFICIENT ALVEOLAR RIDGE IN A CANINE MODEL.

I. CLINICAL STUDY

A. Norman Cranin, DDS, DEng,
Edmond Demirdjan, DDS
Robert DiGregorio, PharmD

KEY WORDS

Autogenous
Allogeneic
Monocortical onlay graft
Demineralized freeze-dried bone
Canine model

A. Norman Cranin, DDS, DEng, is a clinical professor of Oral and Maxillofacial Surgery and Implant Dentistry, NYU College of Dentistry, New York, NY, and is the editor-in-chief of the Journal of Oral Implantology. Address correspondence to Dr Cranin at 232 Kelly Boulevard, Staten Island, NY 10314 (e-mail: ncranin@optonline.net).

Edmond Demirdjan, DDS, and Robert DiGregorio, PharmD, are with the Brookdale University Hospital and Medical Center, Brooklyn, NY.

A canine model was used to compare autogenous alveolar ridge augmentation bone grafting with allogeneic grafts. Defects were created by premolar extractions and measured by radiopaque markers. These markers were used for subsequent measurements made before and after grafting, and after animal sacrifice to evaluate the status of the grafted sites. The results were unexpected and disappointing.

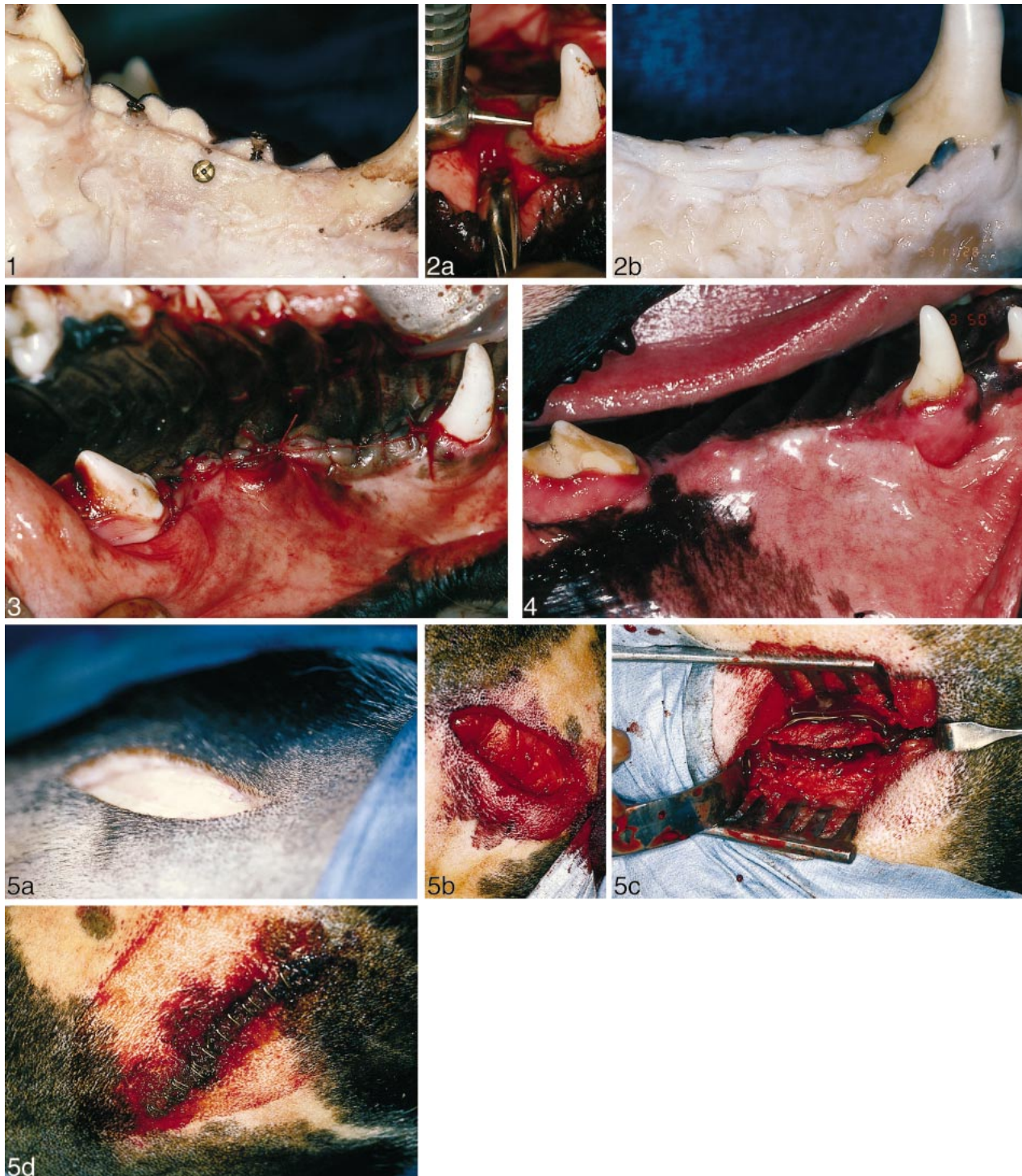
INTRODUCTION

Alveolar bone loss is a natural consequence of tooth loss. Lekholm and Zarb¹ have described the pattern of bone loss of the edentulous ridge. Dental implants placed in deficient ridges have higher failure rates than those placed in ridges with more bone. When successful, esthetic results may be unsatisfactory or the implants may be subjected to force vectors that are thought to be deleterious to long-term implant survival.² To counteract these potentially harmful results, alveolar ridge augmentation either prior to or at the time of implant placement has been advocated.³⁻⁷

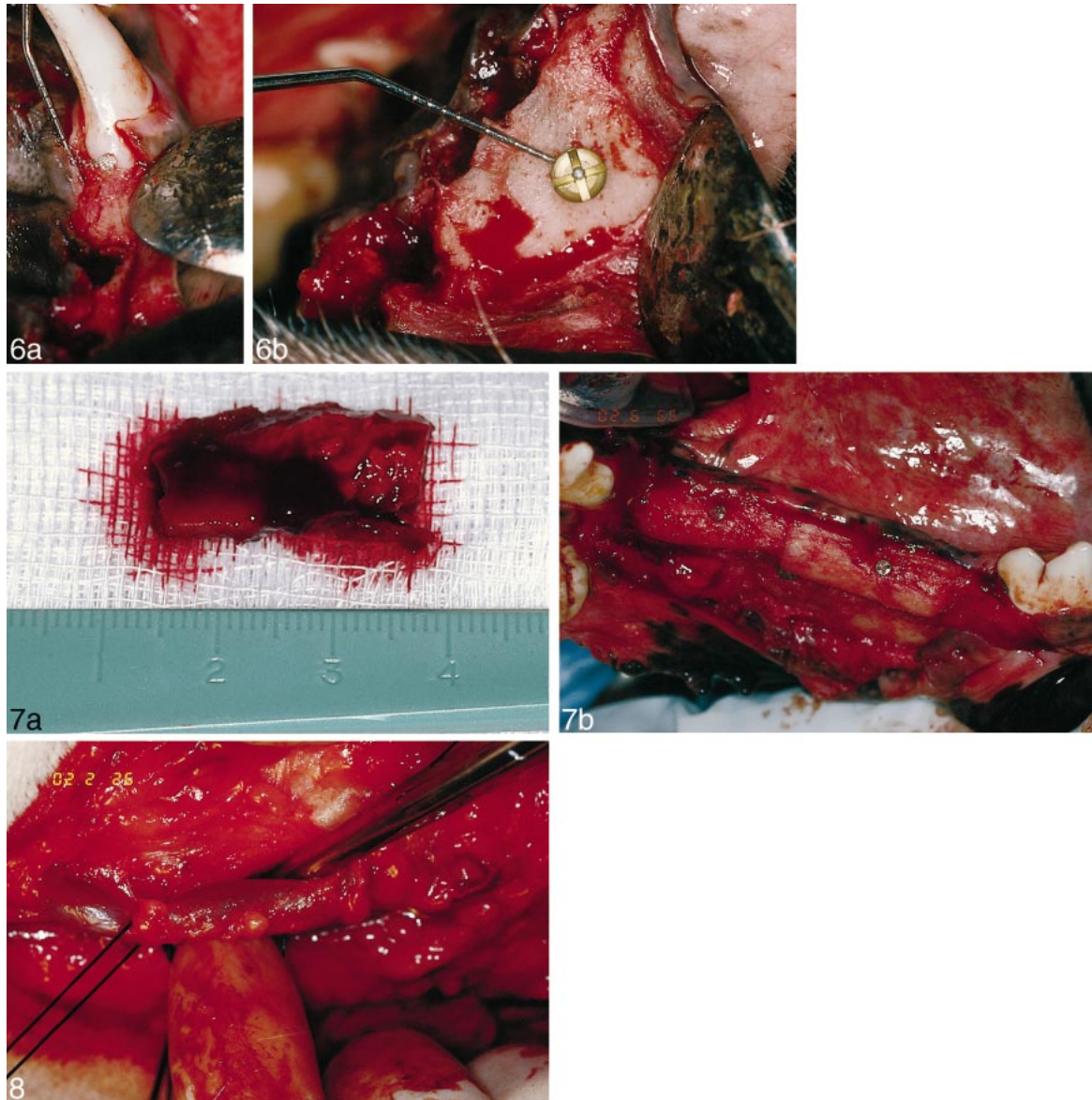
Guided bone regeneration (GBR) is

a technique often used to augment the severely deficient ridge.^{4,5} With the added benefits offered by barrier membranes, implants are placed either at the time of grafting or by subsequent approaches. Although successful osseous reconstruction often results, there has been criticism of these techniques, including inconsistent bony fill,⁸ questionable levels of osseointegration,³ instability of the newly generated bone,⁹ and infection associated with dehiscence of the membranes.^{4,6,10,11}

Because of these potential and actual problems, the use of autogenous monocortical onlay grafts inserted prior to implant placement has been advocated as one viable method to achieve predictable bony enlargements



FIGURES 1–5. FIGURE 1. At the time of the edentulating procedures, the tissues were opened and titanium screws were placed 6 mm beneath the crestal levels to serve as markers for postoperative measurements. FIGURE 2. (a) and (b) Inverted cone burs were used to prepare for the insertion of amalgam markers at the cervices of the molars and canines adjacent to the edentulous study areas. FIGURE 3. Primary closures were achieved after placing the markers. FIGURE 4. Healing at all 20 sites was uneventful. FIGURE 5. (a), (b), (c), and (d) Twelve weeks later, incisions were made overlying the posterior iliac crests, and sharp and blunt dissection was employed in order to reveal the periosteum. After its reflection, burs and osteotomes were used to harvest cortico-medullary blocks. Closures were achieved using skin staples.



FIGURES 6–8. FIGURE 6. (a) and (b) Immediately following the harvesting, the 4 quadrants of each experimental animal were exposed surgically. Prior to affixing the grafts to the 4 quadrants of edentulous ridges, both horizontal and vertical measurements were made in order to record dimensional changes. FIGURE 7. (a) and (b) Both allogeneic and autogenous bone blocks were soaked in saline/blood and gentamicin solution and then were affixed with lag screws to the underlying host sites. FIGURE 8. After sacrifice the animals were perfused with 10% neutral formalin via the dissected carotid arteries and jugular veins.

to create optimal sites for implantation.^{7,12} A shortcoming of this technique, however, is the need for a second surgical (donor) site and the morbidity associated with this surgery. Demineralized allogeneic monocortical ilium blocks have become available. The ability of demineralized allogeneic bone to promote bony ingrowth has been well documented.^{13,14} Therefore, information was sought regarding the

possibilities that these blocks might serve as alternatives to autogenous monocortical blocks for ridge augmentation.

Aim

The aim of this study was to examine and compare the behavior of autogenous monocortical blocks as compared with demineralized allogeneic monocortical blocks to augment deficient

mandibular alveolar ridges in a dog model. Clinical and histologic examinations were used to compare the results of using the 2 graft materials.

MATERIALS AND METHODS

Five mongrel dogs, each 25 kg or greater, were used. The 4 quadrants of each animal were used for 20 quadrants, 18 of which were experimental; the remaining 2 served as controls. Three

distinct stages of the study were delineated: (1) dental extraction, (2) augmentation, and (3) sacrifice. Prior to each procedure, the dogs were anesthetized with 30 mg/kg of intravenous pentobarbital sodium, intubated, and maintained with oxygen and a continuous D5W drip. Boli of barbiturate were added as necessary to maintain anesthesia.

In each of the 20 quadrants, a full-thickness mucoperiosteal flap was elevated and the 4 premolar teeth from the mandible and 3 from the maxillae were extracted using the classical hemisection technique.¹⁵ At a point approximately midway between the canine and molar teeth in each quadrant, a single 4 × 1.6-mm titanium bone screw was placed 6 mm apical to the newly created alveolar crest on the buccal surface. The head of each screw was countersunk in order to avoid irritation to the overlying soft tissues. Additionally, 2-mm diameter amalgam fillings were made at the cervices of the canine and molar teeth (Figures 1, 2a and b). The titanium screws and the amalgam fillings served as reference points to mark changes in bone dimensions over time. Primary closure was then achieved using 4-0 Vicryl (Johnson and Johnson, New Brunswick, NJ) continuous horizontal mattress sutures (Figure 3).

The dogs were observed postoperatively in the recovery area until they were safely reactive, at which point they were returned to their cages. A single postoperative intramuscular dose of 600 000 units of Bicillin was given to each in the gluteus muscle. Pain control was achieved with Buprenex 0.3 mg IM every 6 hours for 3 days, followed by doses as needed. Each dog was maintained on a pureed diet for 2 weeks, followed by a regular diet of dog chow.

A 12-week period was allowed to elapse to permit initial alveolar resorption and healing (Figure 4). After that time, each of the 18 experimental quadrants was grafted. Ten quadrants received an allogeneic graft, and 8 quad-

rants received an autogenous graft. Each of the dogs was anesthetized as previously described, and harvesting of grafts from the posterior iliac crests was performed. Each dog was secured to the operating table in a prone position with both legs extended caudally. Under strict sterile conditions, the area overlying the right posterior iliac crest was shaved, prepared with Betadine, and draped for isolation. A 2% lidocaine solution with 1:50 000 epinephrine was used to infiltrate the surgical site. Using a number 10 scalpel blade, a 6-cm incision was made over the iliac crest. The subcutaneous tissue, gluteal fat, and thoracolumbar fascia were incised using electrocautery. An incision was made through the crestal origin of the middle gluteal muscle on the tuber sacral starting at the cranial dorsal iliac spine and extending caudally for 4 cm. An elevator was used to strip the periosteum along with the overlying middle and deep gluteal muscles laterally and the iliocostalis and longissimus lumborum muscles medially. The crest and the wing of the ilium were then exposed inferiorly for a distance of 3 cm. Using dental drills with copious saline irrigation, two 2 × 1.5-cm osteotomies were made and the monocortical blocks created were elevated by using an osteotome as a lever (Figure 5, a-d). The harvested blocks were stored in a sterile container containing normal saline to which was added 80 mg of gentamicin sulfate, marrow blood, and medullary bone that had been retrieved at operation using a gouge. After establishing hemostasis at the donor site, primary wound closure was achieved in layers using 3-0 Vicryl sutures for the deeper layers and staples for the skin. Bacitracin ointment was applied over the incision prior to dressing it.

The Pacific Coast Tissue Bank (Los Angeles, Calif) provided canine allogeneic bone in the form of demineralized split ilium blocks and demineralized cortical powder. It had been sterilized using ethylene oxide gas and freeze dried in the same manner as hu-

man allografts. Physically and dimensionally, it was clearly comparable with the autogenous specimens that had been harvested. The manufacturer's recommended protocol for rehydration was used just prior to surgery. The allografts were transferred to sterile containers containing normal saline with 80 mg of gentamicin sulfate added at room temperature. The solution was changed twice to remove residues of gas sterilization. The bone powder was rehydrated for 30 minutes and the blocks for 3 hours.

In all of the 18 experimental quadrants, midcrestal incisions were made with 2 vertical releasing incisions on the facial surfaces and full-thickness mucoperiosteal flaps were elevated. At this point 4 measurements were made prior to grafting: (1) the distance between the base of the head of the marker screw and the buccal plate to determine horizontal bone loss; (2) the distance from the crest of the ridge to the center of the marker screw to determine vertical bone loss in the center of the edentulous segment; and (3) and (4) the distances from the bases of the marker amalgams in the canine and first molar to the crest of the ridge to determine vertical bone loss adjacent to these teeth (Figure 6a and b). Upon completion of recording the bone loss of the residual alveolar ridge, the grafting processes were initiated. All recipient sites were prepared to receive the grafts by perforating the buccal cortical plates using a one-half round bur in a high-speed handpiece at multiple sites (from 16 to 20 times) in order to stimulate bone marrow bleeding. The mucosal flaps then were undermined to separate them from the underlying periosteum, which ensured adequate flap mobility for tension-free primary closures. Following this, the host sites were grafted with either allogeneic or autogenous bone as indicated in Table 1.

The donor tissues were trimmed and smoothed as required so that they would fit the host bone beds with minimal underlying deficiencies. Single

TABLE 1
Quadrant number and graft type*

Dog	Right Maxilla	Left Maxilla	Left Mandible	Right Mandible
1	1	2	3	4
2	5	6	7	8
3	9	10	11	12
4	13	14	15	16
5	17	18	19	20

*Experimental quadrants—autogenous graft: 1, 4, 5, 7, 11, 12, 16, 17, 20. Experimental quadrants—allogeneic graft: 2, 3, 6, 8, 9, 10, 14, 15, 18. Control quadrants—no graft: 13, 19.

holes were placed through the bone blocks with burs. They were affixed to the host bone deeply enough to assure positive retention with 2.0×6.0 -mm and 2.0×8.0 -mm lag screws.¹⁶ Small peripheral deficiencies were filled with autogenous medullary chips or allogeneic demineralized powder as appropriate (Figure 7a and b). Measurements were taken to record the amount of horizontal and vertical augmentation using the previously placed amalgam markers and screws, the buccal plates, and the alveolar crests as references. The flaps were closed using 4-0 Vicryl horizontal mattress sutures.

The dogs were observed in the recovery area until they were safely re-active, at which point they were returned to their cages. They received postoperative IM Bicillin 600 000 units in their gluteus muscles. Pain control consisted of Buprenex 0.3 mg every 6 hours over the course of 3 days followed by doses as required. For the remainder of the study the dogs were kept on soft diets. The skin staples were removed after 14 days.

After 6 months of healing the dogs were sacrificed. Under general anesthesia the common carotid and anterior jugular veins were catheterized bilaterally. Sacrifice was completed by the administration of an overdose of pentobarbital and potassium chloride. This was followed by saline flush exsanguination of the carotid arteries using 110 mm of Hg pressure with a return via the jugular veins and finally with the perfusion of 10% neutral formalin until a return was noted, at which time the vessels were ligated (Figure 8).¹⁵

The 4 jaw quadrants of each dog were resected and intact ridge measurements were recorded; then, mid-crestal incisions were made with 2 vertical releasing incisions on the facial surfaces, and full thickness mucoperiosteal flaps were reflected. Measurements were taken using amalgam markers and screws as well as the buccal plates and the alveolar crests as references in the same manner as prior to grafting. Examination was done for quantitative evaluations between the immediate preaugmentation and post-sacrifice levels of mineralization and osseous integration of all the grafted sites (Figure 9a and b). Each of the specimens then was fixed in 10% neutral formalin, demineralized with formic acid, embedded in nitrocellulose, and sectioned serially in a buccolingual direction. Histologic examinations were done with light microscopy after H&E staining; these results will be found in Part II of this article.

RESULTS

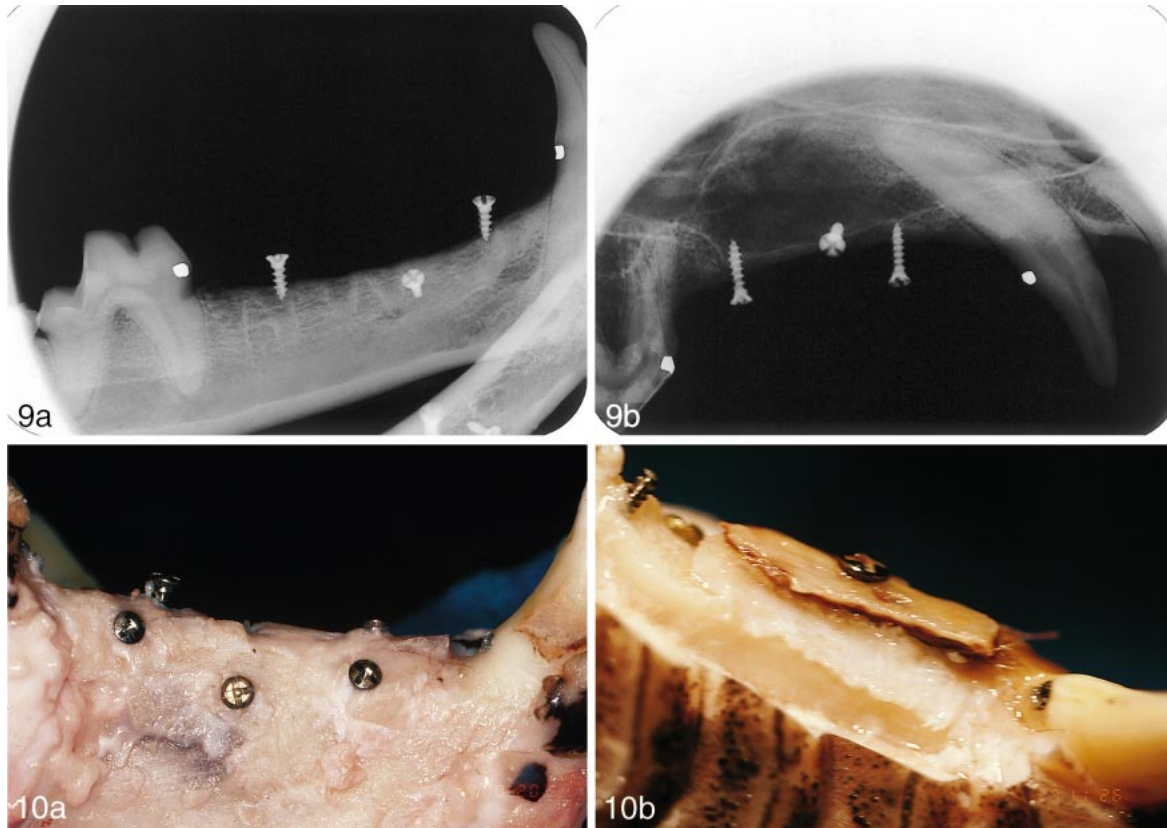
Differences in the outcome of this study based on the 2 selected graft materials were determined by comparing the height and width of the grafts in 18 grafted experimental quadrants and 2 nongrafted control quadrants and by analyses of histologic specimens. Measurements were made (1) prior to grafting, (2) immediately after grafting, and (3) upon sacrifice of each host animal. Calculations were made to determine (1) the volume of augmentation sites (immediate postgraft), (2) the amount of graft resorption (postsacrifice), and (3) the percent of grafted ma-

terial that had become integrated to the host bone in regard to four references: (a) width, (b) height at center of edentulous section, and (c) and (d) height at terminal ends of the edentulous section adjacent to the canine and molar teeth. Measurements of resorption at the time of sacrifice compared the experimental quadrants with the control quadrants. Graft integration percentages were recorded among the experimental quadrants. Statistically significant differences were determined using a repeated measures analysis of variance (ANOVA; SPSS Win 7.0) with a significance level set at 0.05.

Prior to grafting there were no statistically significant differences in the amount of alveolar resorption between any of the 20 quadrants at any of the 4 reference points. Resorption of bone was measured clinically after sacrifice as well and it was determined that again after eliminating the extremes there were no statistically significant differences among the control and experimental quadrants, which demonstrated that there was no significant variation of augmentation levels regardless of the graft material used (Table 2).

In a subgroup analysis, it was noted that the quantity of surviving graft material varied in respect to the different reference points. The center of the edentulous segments had retained more of the graft material than the peripheral areas immediately adjacent to the teeth. Upon sacrifice, the percentage of graft volume, however, was not statistically significantly different between the types of grafts concerning (1) mandible vs maxilla, (2) width augmentation vs height augmentation, and (3) edentulous section of ridge vs areas adjacent to teeth (Table 2).

In addition to the measurements described, the gross and subjective appearance of each graft was rated on a 4-point categorical scale: (1) "good," (2) "fair," (3) "mostly resorbed," and (4) "completely resorbed." A grafted site was considered good if there was clear evidence of a substantial amount



FIGURES 9–10. FIGURE 9. (a) and (b) These postoperative radiographs were exposed at the sixth month. Both maxilla and mandible reveal the presence of the amalgam and titanium screw markers as well as the lag screws that had been used to affix the grafts. Poor mineralization is reflected by these films; this is a consistent early phenomenon found to be associated with humans who have undergone similar procedures. FIGURE 10. (a) and (b) These specimens, studied after they were resected from the jaws, reveal both success and failure. The mandibular quadrant has all of the screws and markers in place and little to indicate loss of dimensions. The maxillary quadrant shows a nonviable separating graft in a seriously resorbed site. Both were allogeneic sites.

of surviving graft material at sacrifice, and fair if there was clear evidence of graft material but not in substantial amounts. Mostly resorbed described those quadrants where only a hint of surviving graft volume existed, and those quadrants that exhibited no signs of any surviving graft material were included in the completely resorbed group. A good or fair outcome was considered a success; those areas that were mostly or completely resorbed were considered as failures (Figures 10a and b).

Four grafts were determined to be successful; 3 of them were allogeneic and were rated as good, and the fourth was autogenous and was rated as fair. Five of the grafts were completely resorbed and 9 were mostly resorbed, for a total of 14 grafts being considered failures. Although there were more

successful outcomes in gross appearance in the allogeneic group, a greater number of these grafts were determined to have completely resorbed as compared with the autogenous group. When compared statistically in the χ^2 test (SPSS Win. 7.0), there were no statistically significant differences in the gross appearances of the grafts.

DISCUSSION

The most interesting aspect of this study is the high percentage of partly and completely resorbed grafts. Despite the fact that prior to mucoperiosteal elevation all but 2 quadrants appeared to have presented favorable ridge forms, only 4 of 18 study sites were adjudged to be successful on a basis of clinical evaluation of the exposed ridges. Of these, 75% represented the allogeneic group. Since hereto-

fore we had considered autogenous bone to be the gold standard when used in human grafting procedures, and retrospective reviews have indicated high percentages of success, some aspects of this study require closer evaluation. The demineralized freeze-dried bone grafts did only slightly better than the autogenous specimens and, with few exceptions, the gross appearances of the host site interfaces of both showed disappointing results. This is not typical of our clinical observations on the use of these materials in uncontrolled and random human studies.¹⁶ A review of the clinical results in this study indicated a slight preference for operative site: 3 were found to be successful in maxillae (where the vascularity was found to be more abundant), and 1 was considered successful in mandibles.

TABLE 2
Clinical results—mucosa-covered and denuded*

Dog	Quadrant	Graft Type	Mucosa	Denuded	% Change†	Comment‡
1	UR	autogenous	normal	bony	+30	fair
1	UL	allogeneic	normal	resorbed	-10	failed
1	LL	allogeneic	normal	bony	+90	good
1	LR	autogenous	normal	fibrous	-20	poor
2	UR	autogenous	knife-edge	friable	-20	poor
2	UL	allogeneic	normal	bony	+40	good
2	LL	autogenous	normal	friable	+20	failed
2	LR	allogeneic	normal	resorbed	+20	poor
3	UR	allogeneic	normal	bony	+50	good
3	UL	allogeneic	normal	mixed	0	failed
3	LL	autogenous	normal	fibrous	+10	poor
3	LR	autogenous	normal	mixed	+20	poor
4	UR	control	normal	bony	0	good
4	UL	allogeneic	knife-edge	friable	-50	failed
4	LL	allogeneic	normal	fibrous	-20	poor
4	LR	autogenous	normal	mixed	+30	poor
5	UR	autogenous	normal	knife-edge	-20	poor
5	UL	allogeneic	normal	fibrous	+20	poor
5	LL	control	normal	bony	0	good
5	LR	autogenous	normal	fibrous	-80	failed

*Mucosal refers to ridge appearance prior to stripping the mucoperiosteum. Denuded refers to clinical appearance of ridge after soft tissue reflection. Percent change of size from original healed edentulous ridge to same site at the end of the study ($\pm 10\%$). UR indicates upper right; UL, upper left; LL, lower left, LR, lower right. The rating was assigned to each quadrant using criteria cited in *Methods*: good, fair (successful); partly resorbed (poor); completely resorbed (failed).

†Percent change of graft after denuding, as compared with pregraft volume, as measured with calipers.

‡Integration of graft to host bone was observed at sites marked "good" as 50%–80%; at sites marked "fair," as 20%–49%.

Dogs heal well and about 3 times more rapidly than humans do,¹⁷ and they have served well in other implant-related studies.¹⁸ The low levels of success here may be attributed to cage biting, which was noted among the animals in this group despite the extensive use of effective analgesics for 72 postoperative hours. The use of their paws appeared to be another deleterious factor that may have contributed to failure. Further Discussion, Summary, and Conclusions will follow Part II of this article.

ACKNOWLEDGMENTS

Dr John Ley prepared this research protocol and was a member of the early operating team. The participation of Drs Michael Katzap and Colleen Watson is acknowledged. Appreciation is extended to Effem Moghilevsky, DVM. This study was made possible in part by a generous grant from the Pacific Coast Tissue Bank and from funds

available to the Brookdale Implant Group from the John and Florence Lawrence Foundation and the Barasch Family Foundation.

REFERENCES

- Lekholm U, Zarb GA. Patient selection and preparation. In: Branemark P-I, Zarb GA, Albrektsson T, eds. *Tissue-Integrated Prosthesis: Osseointegration in Clinical Dentistry*. Chicago: Quintessence; 1985:199–209.
- Jemt T, Lekholm U. Implant treatment in edentulous maxillae: a five-year follow-up report on patients with different degrees of jaw resorption. *Int J Oral Maxillofac Implants*. 1995;10:303.
- Becker W, Schenk R, Higuchi K, et al. Variations in bone regeneration adjacent to implants augmented with barrier membranes alone or with demineralized freeze-dried bone or autologous grafts: a study in dogs. *Int J Oral Maxillofac Implants*. 1995;10:143–154.
- Buser D, Bragger U, Lang NP, et

al. Regeneration and enlargement of jaw bone using guided tissue regeneration. *Clin Oral Implant Res*. 1990;1:22–32.

5. Buser D, Dula K, Belser U, et al. Localized ridge augmentation using guided bone regeneration. I. Surgical procedure in the maxilla. *Int J Periodont Rest Dent*. 1993;13:29–45.

6. Jovanovic SA, Spiekermann H, Richter EJ. Bone regeneration around titanium dental implants in dehiscence defect sites: a clinical study. *Int J Oral Maxillofac Implants*. 1992;7:233–245.

7. Misch CM. Comparison of intra-oral donor sites for onlay grafting prior to implant placement. *Int J Oral Maxillofac Implants*. 1997;12:767–776.

8. Palmer RM, Floyd PD, Palmer PJ, et al. Healing of implant dehiscence defects with and without expanded polytetrafluoroethylene membranes: a controlled clinical and histological study. *Clin Oral Implant Res*. 1994;5:98–104.

9. Becker W, Lekholm U, Dahlin C, et al. The effect of clinical loading on bone regenerated by GTAM barriers: a study in dogs. *Int J Oral Maxillofac Implants*. 1994;9:305–313.

10. Jovanovic SA, Schenk RK, Orsini M, et al. Supracrestal bone formation around dental implants: an experimental dog study. *Int J Oral Maxillofac Implants*. 1995;10:23–31.

11. Simon M, Baldoni M, Rossi P, et al. A comparative study of the effectiveness of e-PTFE membranes with and without early exposure during the healing period. *Int J Periodont Rest Dent*. 1994;14:167–180.

12. Misch CM, Misch CE. The repair of localized severe ridge defects for implant placement using mandibular bone grafts. *Implant Dent*. 1996; 4(4):261–267.

13. Narang R, Ruben MP, Harris MH, Wells H. Improved healing of experimental defects in the canine mandible by grafts of decalcified allogeneic bone. *Oral Surg Oral Med Oral Pathol*. 1970;30:142–150.

14. Narang R, Wells H. Stimulation of new bone formation on intact bones of decalcified allogeneic bone matrix.

Oral Surg Oral Med Oral Pathol. 1971;32:668–676.

15. Cranin AN, Sirakian A, Russell D, Klein M. The role of incision design and location in the healing of alveolar

ridges and implant host sites. *Int J Oral Maxillofac Implants.* 1998;3:483–491.

16. Cranin AN, Klein M, Simons A. *Atlas of Oral Implantology.* 2nd ed. St. Louis: Mosby; 1999:160–162.

17. Roberts WE. Bone tissue interface. *J Dent Ed.* 1988;52:804–809.

18. Cranin AN. Dog v man. Presentation made at NYU College of Dentistry: October 14, 2001; New York, NY.