

IMPORTANT ARTERIAL SUPPLY OF THE MANDIBLE, CONTROL OF AN ARTERIAL HEMORRHAGE, AND REPORT OF A HEMORRHAGIC INCIDENT

Dennis Flanagan, DDS

KEY WORDS

Dental implants
Lingual artery
Facial artery
Inferior alveolar artery
Mylohyoid artery
Submental artery
Sublingual artery
Hemorrhage

Penetration of the mandibular cortex during dental implant surgery may damage 3 important arteries and could lead to life-threatening circumstances. To lessen the likelihood of lateral angulations and cortical perforations, dental implants of less than 14 mm may be considered for the mandible. The courses of the inferior alveolar, facial, and lingual arteries and their branches are reviewed. Management of hemorrhage from a branch of the lingual or facial arteries may require an extraoral approach for ligation, because the mylohyoid, sublingual, and submental arteries can anastomose and be anatomically variable as well. A violation of 1 of these may be difficult to manage and lead to a compromise of the airway. A cortical perforation may be avoided by studying the anatomy of the ridge being treated. This article discusses what procedures to perform to obtund bleeding from 1 of these arteries and the technique of performing an emergency tracheotomy.

INTRODUCTION

Three arteries that provide the major blood supply to the mandible are important for dental implantology. These are the lingual, facial, and inferior alveolar arteries. The first 2 arise directly from the external carotid, a major artery. All 3 supply structures in and around the mandible. A perforation of the facial or lingual cortex of the mandible and a severance of a branch of 1 of these arteries during an osteotomy may result in a life-threatening situation. Uncontrolled bleeding from the lingual artery, if left unchecked, may cause an expanding ecchymosis that could com-

promise the airway and/or blood volume and may result in fatality.

REVIEW OF THE ANATOMY

Lingual artery

The lingual artery arises from the external carotid artery between the superior thyroid and facial arteries (Figures 1, 2, and 3). In 20% of cases, the facial and lingual arteries arise from a common trunk; rarely will the lingual and superior thyroid arteries arise from a common stem. The first portion is crossed by the hypoglossal nerve and is contained within the carotid triangle. This anatomic triangle is formed by the sternocleidomastoid muscle

Dennis Flanagan, DDS, is in the private practice of general dentistry. Address correspondence to Dr Flanagan at 1671 West Main Street, Willimantic, CT 06226 (e-mail: dffdds@mindspring.com).

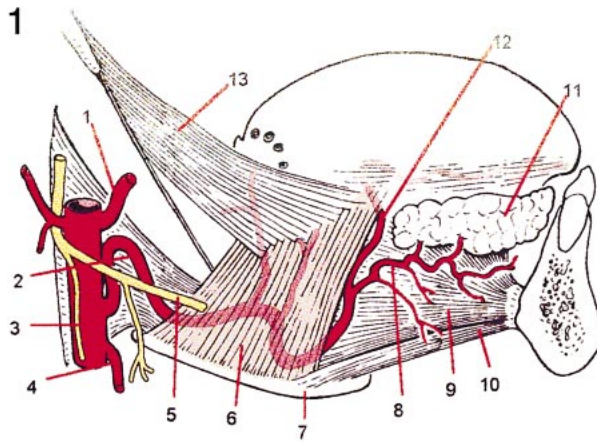


FIGURE 1. Key: (1) Facial artery; (2) lingual artery; (3) external carotid artery; (4) superior thyroid artery; (5) hypoglossal nerve; (6) hypoglossus muscle; (7) hyoid bone; (8) sublingual artery; (9) genioglossus muscle; (10) geniohyoid muscle; (11) sublingual salivary gland; (12) deep lingual artery; (13) styloglossus muscle. LifeART image copyright (2003), Lippincott Williams & Wilkins. All rights reserved.

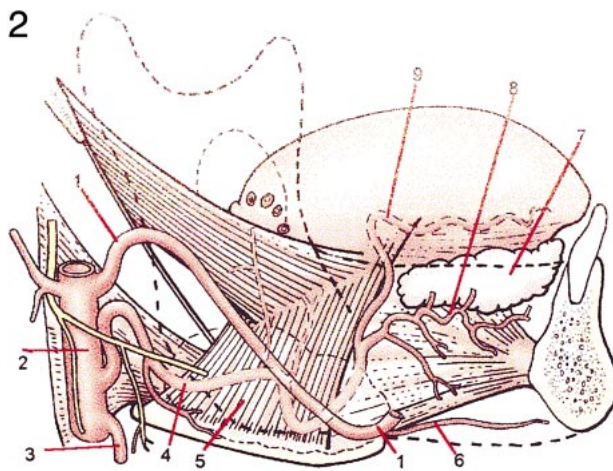


FIGURE 2. Key: (1) Facial artery; (2) external carotid artery; (3) superior thyroid artery; (4) lingual artery; (5) hypoglossus muscle; (6) submental artery; (7) sublingual salivary gland; (8) sublingual artery; (9) deep lingual artery. LifeART image copyright (2003), Lippincott Williams & Wilkins. All rights reserved.

posteriorly, superior belly of the omohyoid muscle inferiorly, and superiorly by the stylohyoid muscle and posterior belly of the digastric muscle. This first portion of the artery also rests on the medial constrictor pharyngeal muscle and is covered by the cervical fascia and platysma muscle. The artery then courses medially and cranial to the greater horn of the hyoid bone. It then turns inferiorly and facially to form a loop and crosses the hypoglossal nerve. This loop of the artery also lies on the medial pharyngeal constrictor, covered first by the tendon of the di-

gastric and the stylohyoid and then by the hyoglossus muscle. Then it passes deep to the digastric and stylohyoid muscles and goes medially to course between the hyoglossus and genioglossus muscles. The terminal portion then rises into the tongue and runs along the underside of the tongue to the tip.

The branches of the lingual artery are the suprahyoid, dorsal lingual, sublingual, and the deep lingual (also known as the profunda linguae or ranine artery).

The suprahyoid branch runs along the superior border of the hyoid bone

and supplies the muscles attached to this bone (geniohyoid, hyoglossus, mylohyoid, sternohyoid, omohyoid, thyrohyoid, digastric, stylohyoid, chondroglossus, and constrictor pharynges muscles). The artery then anastomoses with the contralateral artery of the same name.

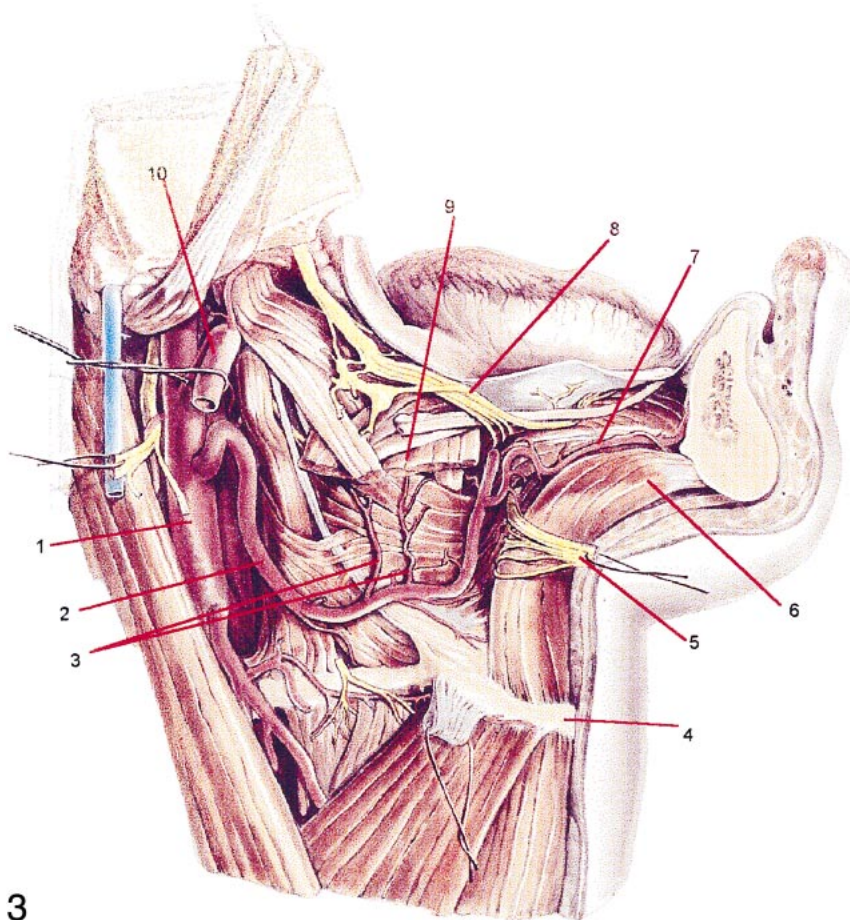
The dorsal lingual arteries have 2 or 3 branches that arise under the hyoglossus muscle and ascend to the posterior portion of the tongue to supply the dorsum of the tongue, mucous membrane of the area, glossopalatine arch, tonsil, soft palate, and epiglottis. These branches then anastomose with the branches of the opposite side.

The sublingual branch arises from the lingual artery at the point the anterior margin of the hyoglossus muscle is crossed. The branch then courses between the genioglossus and mylohyoid muscles and continues on to supply the sublingual salivary gland, the mylohyoid and surrounding muscles, and the mucous membranes and gingivae of the mandible. One more distal branch runs medially in the anterior lingual mandibular gingivae to anastomose with the contralateral artery. Another branch goes through the mylohyoid muscle and connects with the submental branch of the facial artery.

The deep lingual artery is the tortuous terminal portion of the lingual artery. It runs along the undersurface of the tongue between the inferior longitudinal muscle and the mucous membrane on the lateral side of the genioglossus muscle. At this point it is accompanied by the lingual nerve. The distal end anastomoses with the contralateral terminus at the tip of the tongue.

Facial artery

The facial artery originates from the external carotid, superior to the lingual artery, which is in the carotid triangle and medial to the ramus (Figure 2). It passes deep to the digastric and stylohyoid muscles and arches anteriorly to enter a groove on the submandibular salivary gland. From here it is ac-



3

FIGURE 3. Key: (1) External carotid artery; (2) lingual artery; (3) dorsal lingual arteries on the genioglossus muscle; (4) hyoid bone; (5) hypoglossal nerve (cut and retracted); (6) genioglossus muscle; (7) sublingual artery; (8) lingual nerve; (9) hypoglossus muscle (cut); (10) facial artery. LifeART image copyright (2003), Lippincott Williams & Wilkins. All rights reserved.

accompanied by the facial vein. It then becomes superficial and winds around the inferior border of the mandible at the anterior border of the masseter muscle to enter the face (Figure 4). It crosses the cheek, follows along the side of the nose, and ends at the medial commissure of the eye, where it is known as the angular artery. The facial artery is extremely tortuous, which permits it to accommodate the movements of the face and mandible without compromising its integrity or its vascular function.

There are 2 main branches of the facial artery: the facial and cervical.

The 5 branches of the facial portion supply the facial areas about the eye, nose, and lips. There are 4 branches of

the cervical portion. The ascending palatine and tonsillar branches supply the structures of the pharynx, soft palate, and auditory tube. The glandular branch consists of 3 or 4 vessels that supply the submandibular gland, lymphatics, and the overlying skin. The submental branch is the largest of the cervical branches and arises from the facial artery (Figures 2 and 4). At this site it leaves the groove of the posterior submandibular gland and runs anteriorly on the surface of the mylohyoid muscle inferior to the body of the mandible and deep to the digastric muscle. The submental branch anastomoses with the sublingual branch of the lingual artery and with the mylohyoid branch of the inferior alveolar artery.

At the symphysis of the mandible, the submental branch turns superiorly beneath the border of the mandible and divides into its superficial and deep branches. The superficial branch approaches the surface and runs on the inferior labial levator muscle and anastomoses with the inferior labial artery. The deep portion runs deep to the inferior labial levator, supplies the lip, and anastomoses with the inferior labial and mental arteries.

Inferior alveolar artery

The inferior alveolar artery arises from the maxillary artery, which is the larger of the 2 terminal branches of the external carotid (Figure 5). As the inferior alveolar artery descends, it gives off the mylohyoid artery before entering the mandibular foramen and the mandibular canal. At the first molar, it divides into the mental and incisal branches. The incisal branch continues in the mandibular canal anterior to the mental foramen and presents branches to the incisor teeth and finally to anastomose with its contralateral mate. The mental branch emerges from the mental foramen to supply the chin and lower lip and anastomose with the submental and inferior labial arteries, which are branches of the facial artery.

The mylohyoid artery leaves the inferior alveolar artery and runs on the medial surface of the mandible in the mylohyoid groove and continues to supply the mylohyoid muscle. A small lingual branch can arise from the inferior alveolar artery near its origin and descend with the lingual nerve to supply the mucosa of the floor of the mouth.¹

REPORT OF A HEMORRHAGIC INCIDENT

A 57-year-old woman, with a noncontributory medical history, fractured her mandibular right first molar. A radiograph revealed that the fracture was subosseous and the tooth was deemed unrestorable. The right mandible was anesthetized by means of a right inferior alveolar nerve block. The tooth

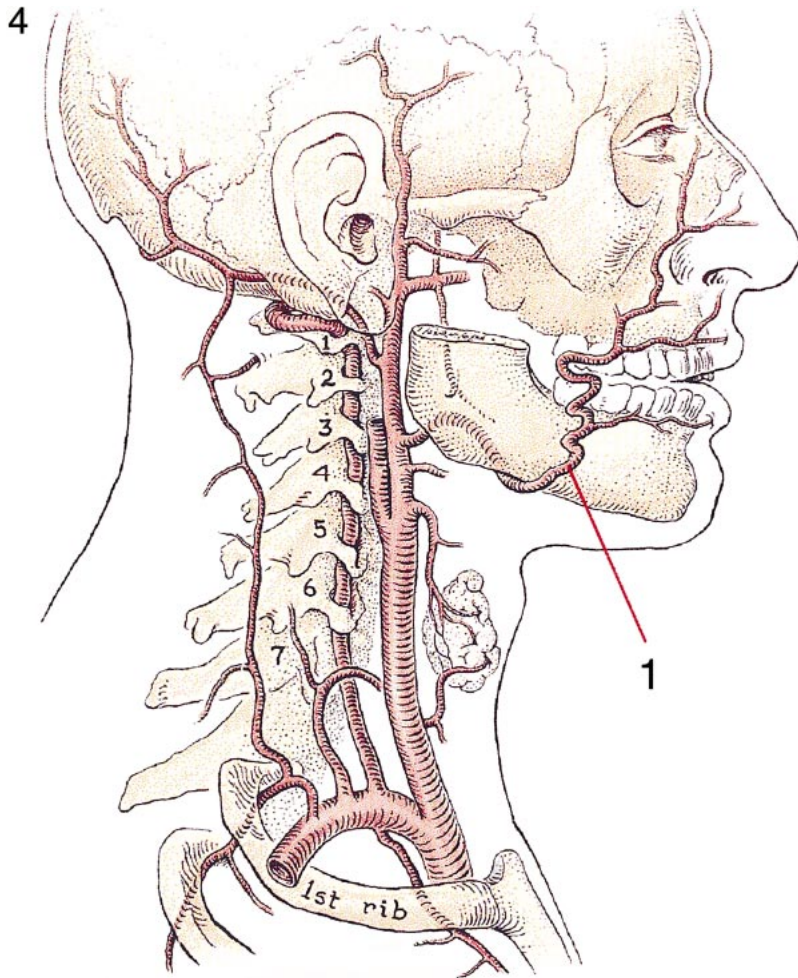


FIGURE 4. Key: (1) Facial artery. LifeART image copyright (2003), Lippincott Williams & Wilkins. All rights reserved.

was sectioned into mesial and distal roots and removed without incident. Upon its removal a bleeding arteriole originating from a nutrient canal was noted. It originated in the sublingual tissue and passed through the lingual cortical plate into the molar furca. The lingual aspect of the body of the mandible was palpated. At a point near the apical area on the lingual surface of the mandible, finger pressure obtunded the bleeding. Nonetheless, continued compression did not maintain hemostasis. Injection of lidocaine with 1:100,000 epinephrine directly into the bleeding nutrient canal was unsuccessful. An unsuccessful effort was made to ligate the artery before it entered the mandible. Because it was positioned tightly against the mandible and cov-

ered with a wide band of attached gingivae, there was a risk of damaging the artery with the suture needle at the point where the ligation was attempted. Therefore only 1 such attempt was made. A 2×2 sponge tamponade was placed and held under biting pressure for several minutes, which proved to be successful in stopping the bleeding. A combination of using the vasoconstrictor, intravascular embolization, and tamponade were probably responsible for the cessation of bleeding. A collagen sponge (Colla-Plug, Integra Life Sciences, Plainsboro, NJ) was sutured into the socket with chromic gut. The patient was instructed in postoperative care and reappointed for follow-up. Healing was uneventful with no recurrence of bleeding.

DISCUSSION

The incident described was relatively minor; however, it was indicative of what may occur should a larger arteriole or artery be violated. This arterial bleeder was probably a branch of the submental artery, the main supplier of this area. The nutrient canal may have been successfully blocked with a particulate alloplast, xenoplast, or xenograft brought and compressed into the canal with a small amalgam carrier and then packed with a small amalgam condenser.

Tamponade over extended periods of time (15 minutes or more) is of significant value and is usually the first action to take. Direct ligation of the bleeding vessel is often the most effective means of stopping arterial blood flow. Arterial retraction, however, may make ligation difficult.

A torn artery may bleed intermittently, whereas a severed artery may stop bleeding by retraction but later bleed again. If the bleeding cannot be controlled, a determination as to the origin of the branch is required. Because of anatomic variations in this midbody, lingual, mandibular location, the possible origin of the bleeder should include the mylohyoid, sublingual, and submental arteries. Digital palpation may indicate the originating branch. A decision then must be made as to the feasibility of ligating the branch itself, which may originate from the mylohyoid, facial, or lingual arteries. If it were a branch of the submental artery, that branch or the facial artery itself would need to be ligated. If the bleeding continued after that, the lingual artery would require ligation.

Life-threatening upper airway obstruction from hemorrhage has been reported from situations including puncture wound of the tongue, head trauma, biopsy of a floor of the mouth lesion, and the severance of an artery supplying the mandible during an implant procedure.²⁻⁶ Interestingly, tissue plasminogen activator, a thrombolytic agent, has been reported to cause bleeding from a branch of the lingual artery.⁷

5

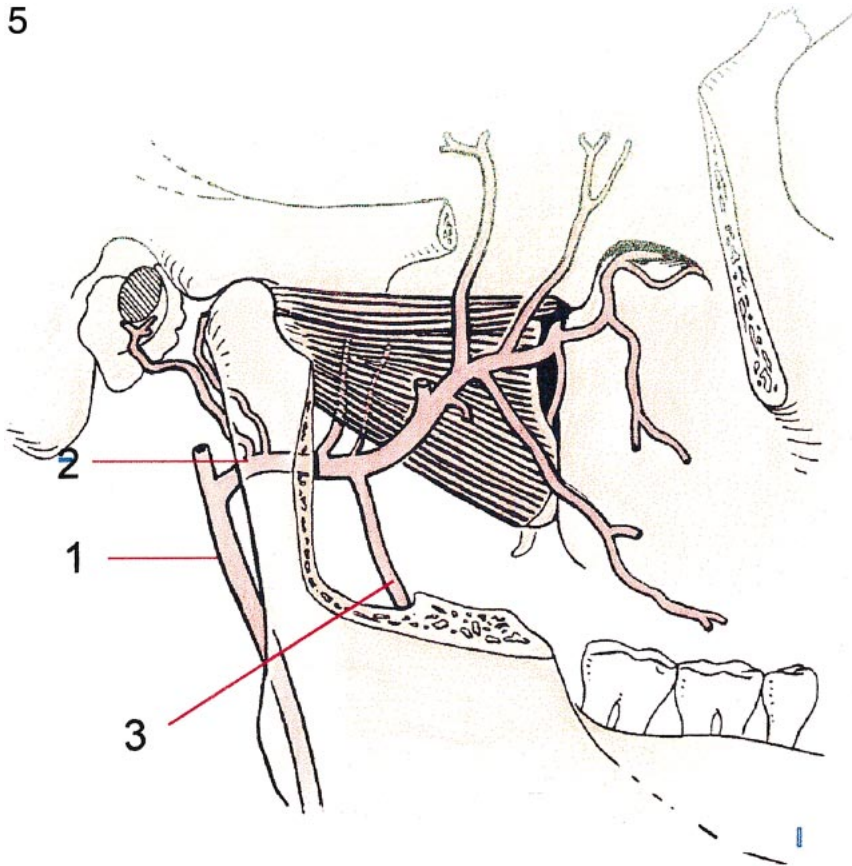


FIGURE 5. Key: (1) External carotid artery; (2) maxillary artery; (3) inferior alveolar artery. LifeART image copyright (2003), Lippincott Williams & Wilkins. All rights reserved.

The facial artery is a major extraosseous source of blood supply to the body of the mandible and its periosteum.⁸ Doppler ultrasound studies showed that reverse flow of the facial artery was observed by applying manual pressure to the lower border of the mandible.⁹ This indicates significant blood flow from anastomoses with other arteries, so a ligation may not seriously compromise the tissue supplied, but a cut facial artery may have significant bleeding from both proximal and distal ends. Ligation of the distal end may need to be considered as well.

The mylohyoid branch of the inferior alveolar artery can be severed by an implant that perforates the mandibular lingual cortex in the molar region. Bleeding control may best be accomplished with finger pressure against the medial side of the mandible just

distal to the root of the third molar. Ligation of this artery may be practically impossible in an emergency. A dissection over the artery may incur further damage and exacerbate the situation.

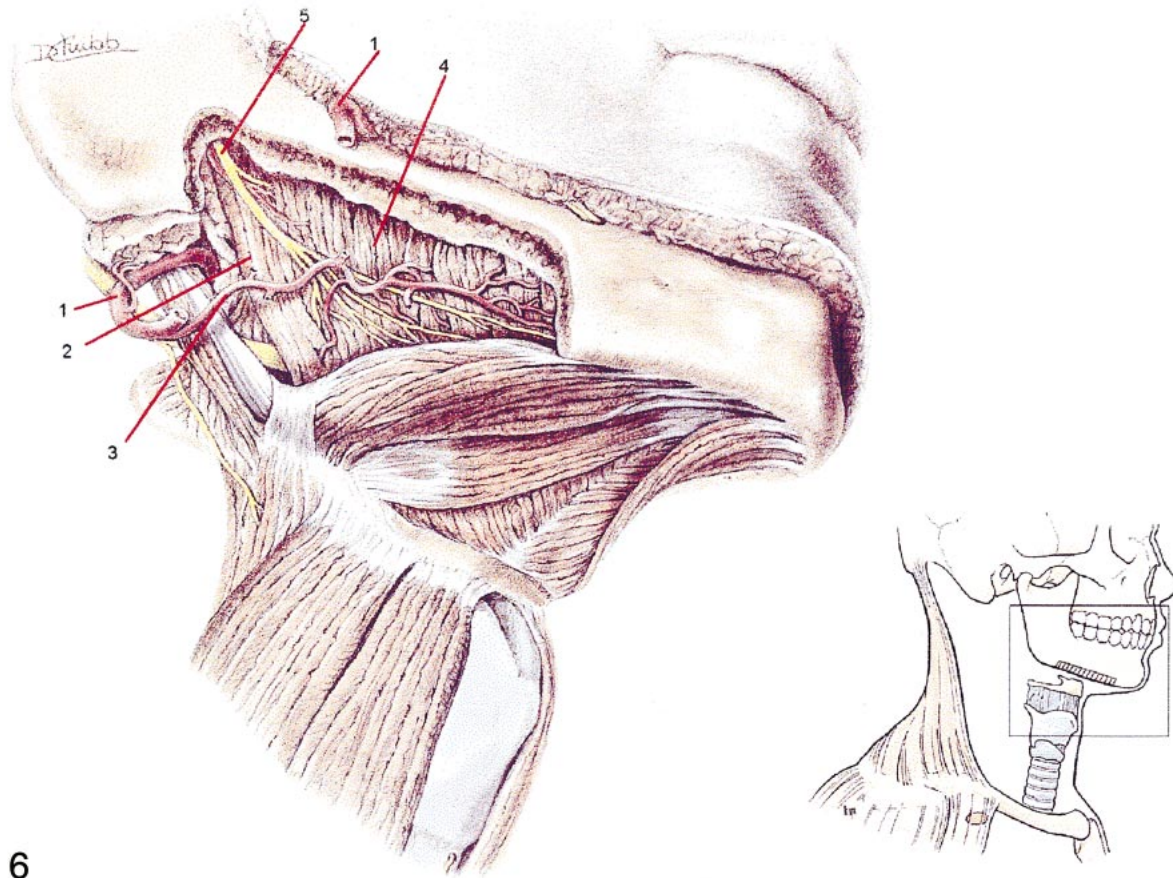
The mandibular canal is usually located to the lingual side and close to the inferior border of the mandible. The inferior alveolar artery is usually located superior to the mandibular nerve in the mandibular canal in the molar region.¹⁰ An osteotomy that enters the mandibular canal would probably first sever the artery before contacting the nerve. During surgery in this area, arterial bleeding from the osteotomy may indicate violation of the mandibular canal and the inferior alveolar artery but may not be a violation of the nerve. However, the loss of the neural blood supply or an intraneural hematoma may result in a neuropathy of the inferior alveolar nerve.

The lingual artery seems fairly resistant to atherosclerosis and can maintain a robust blood flow even in aging patients. Severing a branch may be a serious event. If a branch of the lingual artery is severed, a ligation of the lingual artery as it courses through Pirogoff's Triangle may be performed. This anatomical triangle is a subdivision of the submandibular or digastric triangle. It is bordered by the hypoglossal nerve superiorly, the posterior margin of the mylohyoid muscle anteriorly, and the posterior belly of the digastric muscle posteriorly with the floor formed by the hyoglossus muscle. Pirogoff's Triangle has been reported to be present in 58.2% of dissections. The lingual artery was found deep to the digastric tendon and superior to the hyoid bone in 67% of the dissections studied.

The lingual artery may be ligated extraorally.^{11,12} Because the submental artery may anastomose with the lingual (sublingual) artery, a severance of this artery may require controlling the blood flow of both.

A ruptured lingual artery can cause a sudden swelling in the submandibular area, dislocate the trachea to the contralateral side, and compromise the airway.¹³ Pseudoaneurysms (dilations or cavities of the artery, also called pulsatile hematomas) of the lingual artery that may be responsible for hemorrhage if damaged during implant surgery have been reported.¹⁴ The lingual artery becomes more tortuous with age.¹⁵ Also, it has been reported that with age the lingual artery may show rupture and proliferation of intimal elastic fiber. A decrease of the area of the lumen in relation to the total area of the cross section of the artery occurs with advancing age as well.¹⁶ Therefore, the media and intima of the lingual artery thicken by fibrosis outwardly, but only after about age 60 does the lumen decrease in cross section.¹⁷

The anastomoses of the lingual artery with its contralateral mate occur throughout the tongue, with the num-



6

FIGURE 6. Key: (1) Facial artery; (2) posterior belly of the digastric muscle; (3) submental artery; (4) mylohyoid muscle; (5) mylohyoid nerve. LifeART image copyright (2003), Lippincott Williams & Wilkins. All rights reserved.

ber of connections increasing as the artery progresses to its tip.¹⁸

The blood supply of the floor of the mouth and lingual gingiva can be offered by the sublingual or the submental artery. These are branches of the lingual and facial arteries, respectively. The submental artery may be considered the main blood supply of this area, since in 53% of the cases studied, the sublingual artery was small, insignificant, or absent.¹⁹ Hemorrhage in this area may be assessed by first identifying the trunk that supplies the bleeding branch. This can be determined by applying broad pressure to the lower medial border of the mandible or bimanual digital compression at the site where the facial artery crosses and the submental artery originates (Figures 2 and 6). A cessation or attenuation of bleeding may indicate that the bleeding branch is from the sub-

mental or facial artery, and ligation here may be indicated. Otherwise, ligation of the lingual artery may be indicated. However, anastomoses may indicate the need for ligation of both the facial and lingual arteries.

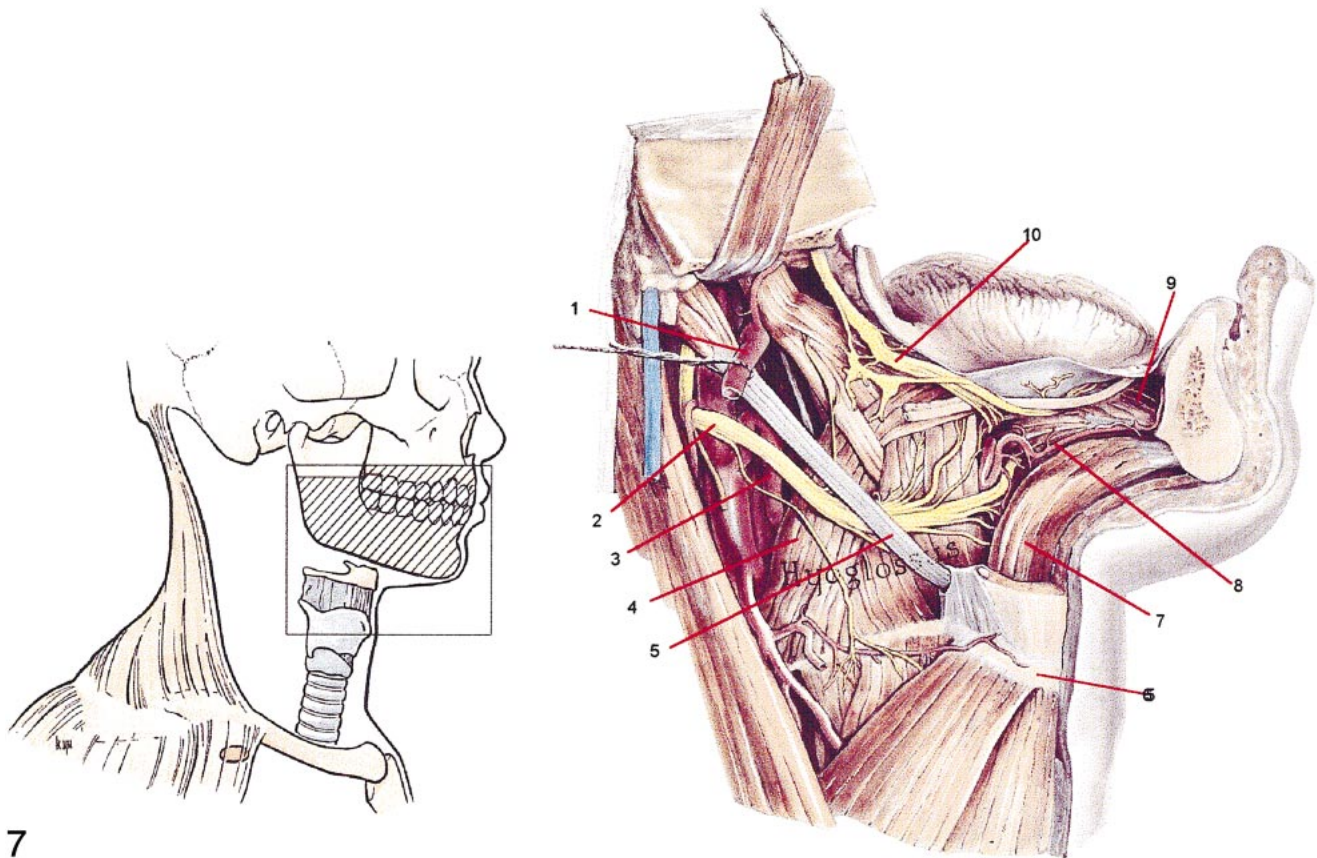
Apparently severance of these arterial branches during implant surgery, although relatively small, can cause exsanguination quickly, and therefore the patient's life may be threatened. These arteries are usually in the range of 1 to 2 mm internal diameter of the lumen. A simple calculation shows that at an estimated blood flow from the cut end of an artery of 0.2 mL per beat at 70 beats/min, it is possible for 14 mL of blood to escape in 60 seconds. In 30 minutes an estimated 420 mL could be lost, the approximate volume of a grapefruit. This amount of blood may accumulate in a submandibular space to compromise the airway. A sign of

impending distress is a protruding tongue. The tongue and epiglottis may be forced into the pharynx and larynx, closing off the trachea.

Because there are many anastomoses in this area among branches of the lingual, facial, and mylohyoid arteries, consideration must be given as to where bleeding may be arrested.

When cut, many arteries stop bleeding with pressure applied at the cut end. It has been shown as well that arteriole constriction can be produced by hypovolemia, an undesirable condition.²⁰

Electrocautery, laser, argon beam coagulators, the harmonic scalpel (ultrasonic frictional heating), and vasoconstrictive medications can also be used to stop bleeding.²¹⁻²⁵ In addition, ice-pack compress has been used to aid cessation of a bleeding lingual artery



7

FIGURE 7. Key: (1) Facial artery; (2) hypoglossal nerve; (3) lingual artery; (4) hypoglossus muscle; (5) posterior belly of the digastric muscle; (6) hyoid bone; (7) geniohyoid muscle; (8) sublingual artery; (9) genioglossus muscle; (10) lingual nerve. LifeART image copyright (2003), Lippincott Williams & Wilkins. All rights reserved.

(C. Lindquist DDS, oral communication).

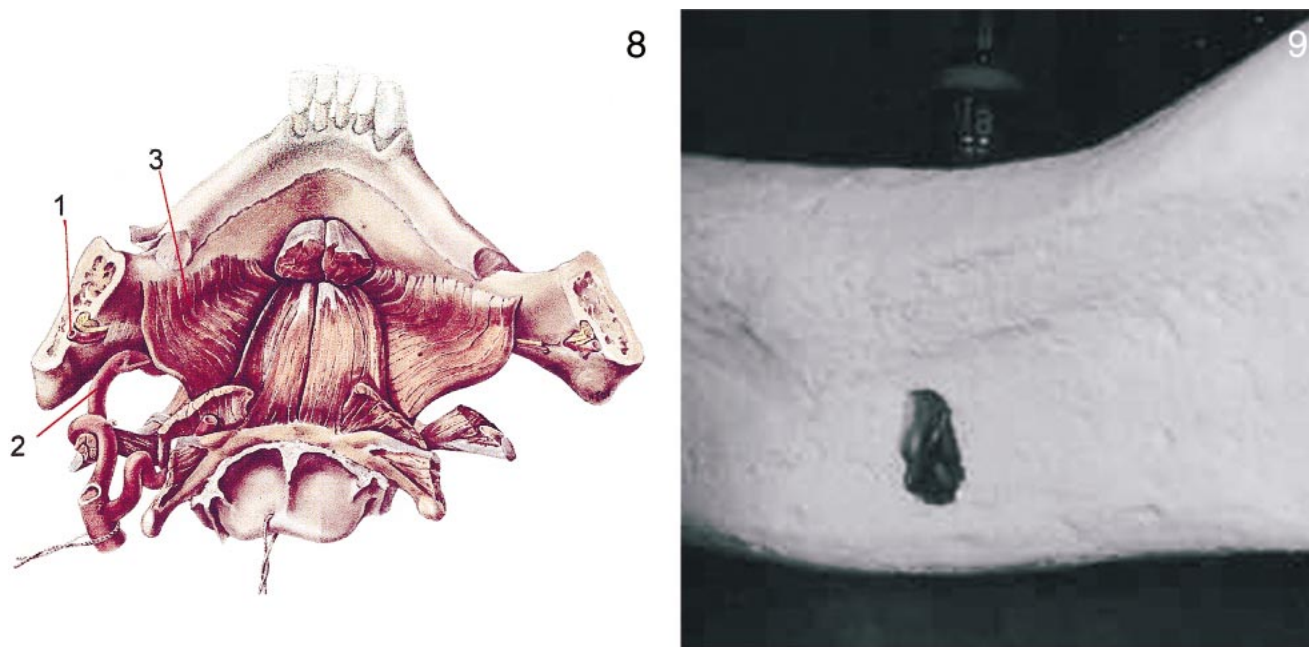
A submandibular approach may be necessary for ligation of the lingual and/or facial arteries. This is accomplished by making an incision 2 finger breadths (35–40 mm) medial to (below) the inferior border of the mandible. Access to the capsule of the submandibular gland is made by dissection through the platysma muscle and the superficial layer of the deep cervical fascia. The gland is mobilized for retraction. The facial artery now may be located, and care should be taken not to injure the now-exposed facial artery and vein. The submental artery branches off at the submandibular gland and is located about 37 mm posterior to the menton (Figures 2, 4, 7, and 8). Ligation by compression of the submental artery at a point here may be considered. If bleeding is not ar-

rested, then these vessels can be carefully retracted superiorly with the gland. Both bellies and the tendon of the digastric muscle, hypoglossal nerve, and vein are usually apparent. The hypoglossus muscle provides the floor for these structures. Its fibers run more vertical, are more delicate, and are deeper colored than the nearby mylohyoid muscle. The hypoglossus muscle can now be split apart to expose the lingual artery below for ligation. It may be visible for a short distance before it passes deep to the hypoglossus muscle. In most cases the lingual artery will be inferior or deep to the superior border of the digastric tendon (which can be 4–10 mm wide) and about 2 to 4.5 mm inferior or deep to the hypoglossal nerve. The lingual artery is usually about 3 to 10 mm above the hyoid bone.

The sublingual artery may be ligat-

ed as it runs at the forward edge of the hypoglossus muscle. If access is made superior of the hypoglossal nerve, then the lingual vein (venae comitans) may be found, which sometimes may be bifurcated on either or both sides of the hypoglossus muscle. There is anatomical variation in this area, which may find the lingual artery superficial to the hypoglossus muscle.¹² In the case of floor of the mouth bleeding, the submental or facial artery should be ligated first, and then the lingual artery ligated if bleeding is not arrested.

The sublingual artery is the continuance of the lingual artery and courses between the genioglossus muscle and the sublingual salivary gland before it goes superficially just beneath the mucous membrane of the floor of the mouth, which may allow easier surgical access for ligation in a more anterior severance.²⁶ This submandibular li-



FIGURES 8–9. FIGURE 8. Key: (1) Inferior alveolar and mylohyoid arteries; (2) facial artery; (3) mylohyoid muscle. FIGURE 9. A misdirected osteotomy may perforate the mandibular cortex. LifeART image copyright (2003), Lippincott Williams & Wilkins. All rights reserved.

gation procedure is intricate and complex and may be best performed by an experienced head and neck surgeon.

An emergency access airway may need to be considered in the event of a sudden and excessive hemorrhage or if extreme distortion of the area precludes a surgical entry for ligation. One report stated significant swelling in 2 minutes of perforating the sublingual artery.²⁷ An emergency cricothyrotomy can be made by a transverse incision close to the upper rim of the cricoid cartilage to avoid the branch of the cricothyroid artery. However, this incision must be carried through the conus elasticus and is close to the vocal cords. This may result in a subsequent laryngeal scarring and stenosis and is not considered safe. Another entry below the thyroid and cricoid cartilages, at about the fourth, fifth, and sixth tracheal rings or behind the thyroid isthmus at the second, third, and fourth rings can be done. Below the level of the thyroid, the trachea is deeper and large vessels may be present. A penetration 1 cm below the cricoid cartilage between the second and third cartilage rings may be the best emergency entry

point. Insertion of a 13-gauge needle may provide an adequate opening until a tracheostomy can be done. The thyroid isthmus is usually below the first 2 tracheal cartilage rings, and no large blood vessels are usually present at this level, although the inferior thyroid vein may run in front of the trachea here.^{26,28} This vein may be palpated with the fingertip and pushed to 1 side with finger pressure to prevent its severance with the initial incision.

The cross-sectional shape of the mandible makes it more likely for a lingual cortical perforation than a facial perforation. However, the implant surgeon must always be aware of aberrant osseous contours. Palpation of the ridge contour, computerized tomograms, magnetic resonance imaging, and bone-sounding techniques are helpful in avoiding a cortical perforation.²⁹ Palpation of the ridge during the osteotomy may help prevent an adverse event. In-office emergency kits for maintaining an airway are a requirement for the implant surgeon.

SUMMARY

There are 3 important arteries that supply the mandible and are impor-

tant considerations for dental implant surgery: the inferior alveolar (and its branch, the mylohyoid); the facial (its branch, the submental artery); and the lingual (its branch, the sublingual artery). A misdirected osteotomy that penetrates the mandibular cortex may sever a branch of 1 of these and possibly create a life-threatening situation (Figure 9). An atrophic edentulous ridge may allow these arteries to lie against the mandible.

A bleeding artery at the lingual surface of the posterior mandible may be the mylohyoid artery and possibly be controlled by applying finger pressure to that site and/or pressure at the bleeding point until it stops. Ligation of this artery may be difficult or impossible. A bleeding artery at the middle lingual of the mandible may be caused by a severance of the submental artery and require control of the facial and lingual arteries by surgical ligation. Since it is very common for the submental, sublingual, and mylohyoid arteries to anastomose among themselves and anatomic variation is not uncommon, control of a severed artery in this area may become a serious com-

plication. Arterial bleeding at the lingual of the anterior mandible may be caused by a terminal branch of the sublingual or submental arteries. These terminal arteries are usually of small diameter and may be controlled at the cut end by compression, vasoconstrictive injections, cautery, or ligation. A bleeding artery on the facial aspect of the mandible, which may be the facial artery or a branch, may be controlled by compression or finger pressure at the inferior border of the mandible, or it may require surgical ligation. Arterial retraction may preclude local ligation. Implants of less than 14 mm in length have been recommended for use in the mandible to lessen the likelihood of perforations.⁵

The implant surgeon should consider maintaining relationships with appropriate specialists who may be called to intervene in such instances. It is imperative, however, that the implant surgeon acquire an in-depth understanding of the arterial supply of the mandible and the techniques required to obtund bleeding and maintain an airway. As soon as a bleeding event is realized, an immediate tamponade should be applied to the area and a laryngeal airway should be considered to preclude a later forced installation. Immediate hospitalization may be necessary.

REFERENCES

- Goss CM, ed. The arteries. In: *Gray's Anatomy: Anatomy of the Human Body*. 2nd ed. Philadelphia: Lea & Febiger; 1967: 583–592.
- Kattan B, Snyder HS. Lingual artery hematoma resulting in upper airway obstruction. *J Emerg Med*. 1991; 9:421–424.
- Chase CR, Hebert JC, Farnham JE. Post-traumatic upper airway obstruction secondary to a lingual artery hematoma. *J Trauma*. 1987;27:953–954.
- Burke RH, Masch GL. Lingual artery hemorrhage. *Oral Surg Oral Med Oral Pathol*. 1986;62:258–261.
- Givol N, Chaushu G, Halamish-Shani T, Taicher S. Emergency tracheostomy following life-threatening hemorrhage in the floor of the mouth during immediate implant placement in the mandibular canine region. *J Periodontol*. 2000;71:1893–1895.
- Mason ME, Triplett RG, Alfonso WF. Life-threatening hemorrhage from placement of a dental implant. *J Oral Maxillofac Surg*. 1990;48:201–204.
- Wrenn K. Tissue plasminogen activator-associated lingual artery hemorrhage. *Ann Emerg Med*. 1990;19: 1184–1186.
- MacGregor AD, MacDonald DG. Vascular basis of lateral osteotomy of the mandible. *Head Neck*. 1994;16:135–142.
- Zhao Z, Li S, Xu J, et al. Color Doppler flow imaging of the facial artery and vein. *Plast Reconstr Surg*. 2000; 106:1249–1253.
- Li N, Zhao B, Tan C. Intramandibular course and anatomic structure of the inferior alveolar nerve canal [in Chinese]. *Zhonghua Kou Qiang Yi Xue Za Zhi*. 2001;36:446–447.
- van Es RJ, Thuau H. Pirogoff's Triangle revisited: an alternative site for microvascular anastomosis to the lingual artery. A technical note. *Int J Oral Maxillofac Surg*. 2000;29:207–209.
- Homze EJ, Harn SD, Bavitz BJ. Extraoral ligation of the lingual artery: an anatomic study. *Oral Surg Oral Med Oral Pathol Oral Radiol Endod*. 1997;83: 321–324.
- Saino M, Akasaka M, Najajima M, et al. A case of a ruptured lingual artery aneurysm treated with endovascular surgery [in Japanese]. *No Shinkei Geka*. 1997;25:835–839.
- Mitchell RB, Pereira KD, Lazar RH, Long TE, Fournier NF. Pseudoaneurysm of the right lingual artery: an unusual cause of severe hemorrhage during tonsillectomy. *Ear Nose Throat J*. 1997;76:575–576.
- Soikkonen K, Wolf J, Mattila K. Tortuosity of the lingual artery and coronary atherosclerosis. *Br J Oral Maxillofac Surg*. 1995;33:309–311.
- Ohuchi T, Nakade O, Kanno H, et al. Aging in the human tongue from autopsies. Histometrical study. 1. Degree of stenosis of lingual arteries [in Japanese]. *Higashi Nippon Shigaku Zasshi*. 1990;9:33–39.
- Semba I. A histometrical analysis of age changes in the human lingual artery. *Arch Oral Biol*. 1989;34: 483–489.
- Vujaskovic G. Anastomosis between the left and the right lingual artery [in Serb-Croatian (Roman)]. *Stomatol Glas Srb*. 1990;37:267–274.
- Bavitz JB, Harn SD, Homze EJ. Arterial supply to the floor of the mouth and lingual gingiva. *Oral Surg Oral Med Oral Pathol*. 1994;77:323–235.
- Scalia S, Burton H, Van Wylen D, et al. *J Trauma*. 1990;30:713–718.
- Lantis JC II, Durville FM, Connolly R, Schwaitzberg SD. Comparison of coagulation modalities in surgery. *J Laparoendosc Adv Surg Tech*. 1998;8:381–394.
- Gill BS, MacFayden BV Jr. Ultrasonic dissectors and minimally invasive surgery. *Semin Laparosc Surg*. 1999;6:229–234.
- McGinnis DE, Strup SE, Gommella LG. Management of hemorrhage during laparoscopy. *J Endourol*. 2000; 14:915–920.
- Siperstein AE, Berber E, Morokoyun E. The use of the harmonic scalpel vs conventional knot tying for vessel ligation in thyroid surgery. *Arch Surg*. 2002;137:137–142.
- Bowling DM. Argon beam coagulation for post-tonsillectomy hemostasis. *Otolaryngol Head Neck Surg*. 2002;126:316–320.
- Hollinshead WH. *Anatomy for Surgeons of the Head and Neck*. 3rd ed. Philadelphia: Lippincott Williams & Wilkins; 1982.
- Niamtu J. Near-fatal airway obstruction after routine implant placement. *Oral Surg Oral Med Oral Pathol Oral Radiol Endodontol*. 2001;92:597–600.
- Goss CM, ed. Trachea and branch. In: *Gray's Anatomy: Anatomy of the Human Body*. 2nd ed. Philadelphia: Lea & Febiger; 1967:1137.
- Flanagan DF. A method for estimating preoperative bone volume for implant surgery. *J Oral Implantol*. 2000; 26:262–266.