

# OCCLUSAL PRINCIPLES AND CLINICAL APPLICATIONS FOR ENDOSSEOUS IMPLANTS

Brian J. Jackson, DDS

## KEY WORDS

Periodontal ligament  
Stress  
Implant-protected occlusion  
Orientation jig

Endosseous implant dentistry has become a predictable clinical modality. The role of the restorative dentist is to minimize overload to the crestal bone by utilizing implant occlusal principles. The prosthetic stages of treatment should follow a disciplined sequence. This article reviews occlusal principles and clinical applications for long-term success of endosseous implants.

## INTRODUCTION

The utilization of oral implantology in the field of dentistry is growing at a rapid rate. The surgical and prosthetic disciplines of the field have demonstrated evidence-based success rates, encouraging more widespread use by the dental profession. Although the surgical aspect of the field has expanded into many high-profile areas (ie, immediate implant placement, distraction osteogenesis, and the orthodontic anchorage implant), it is the prosthetic aspect that is most critical for long-term success. More specifically, the occlusal considerations for implant-supported prostheses make a major contribution to ensure predictable results.<sup>1</sup>

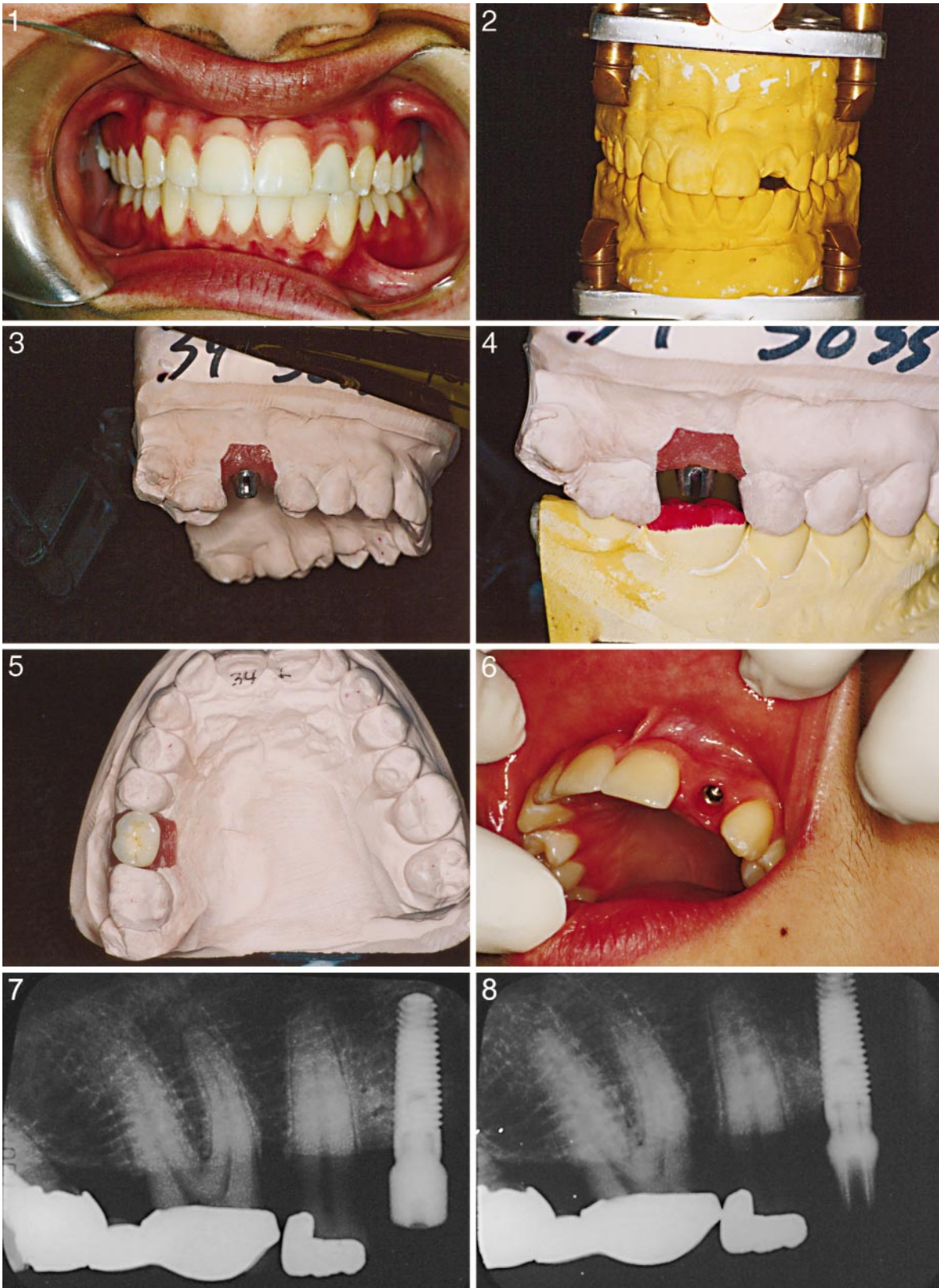
The responsibilities of the surgeon and the restorative dentist are to minimize occlusal overload to the bone at the implant interface.<sup>2-7</sup> First, a proper diagnosis is made that will lead to a satisfactory treatment plan. Second, a surgical template must be developed to insure ideal implant placement. Third, a passive interim prosthesis of adequate retention and form with an acceptable occlusal scheme is required.

Finally, the utilization of progressive loading to improve the density of bone adjacent to the implant will allow the reduction of stress at the peri-implant cervices.<sup>8,9</sup> These factors are essential to improve the long-term prognosis of implant-supported prostheses.

## METHODS

Implant-protected occlusion principles should be observed during all reconstructive stages of treatment.<sup>10,11</sup> First, the natural dentition must be evaluated for occlusal prematurities and adjusted prior to implant reconstruction (Figures 1 and 2). The natural dentition should be equilibrated to minimize eccentric interferences and to establish a harmonious centric occlusion. Second, the final implant abutments and crowns should be evaluated prior to the patient's appointment (Figures 3 and 4). The abutment should demonstrate proper axial taper and an intraocclusal space for sufficient metal framework and porcelain application. Centric occlusion, lateral excursions, and protrusive movements should be evaluated from the articulated stone models. It is essential that the dental

Brian J. Jackson, DDS, privately practices dentistry in Utica, New York. Address correspondence to Dr Jackson, 2534 Genessee Street, Utica, NY 13502 (e-mail: Slajacoburdds@aol.com).



FIGURES 1–8. FIGURE 1. Centric occlusion. FIGURE 2. Articulated diagnostic models—centric occlusion. FIGURE 3. Implant abutment—axial taper. FIGURE 4. Implant abutment—interocclusal distance. FIGURE 5. Implant-supported crown—reduced buccal-lingual dimension. FIGURE 6. Gingival sulcus—normal. FIGURE 7. Periapical radiograph—healing collar attached to implant. FIGURE 8. Periapical radiograph—abutment implant.

laboratory be guided in their understanding of the elements of implant occlusion. The soft-tissue model, height of the abutment, and buccal-lingual dimension of the crown or bridge should be inspected prior to the final placement of the prosthesis (Figure 5). The soft-tissue implant model should correspond to the clinical sulcus probing depths to ensure a clinically acceptable emergence profile. The buccal-lingual dimension of the crown or bridge should be reduced in comparison with the natural tooth it replaces. At the implant-supported crown placement procedure appointment, the soft and hard tissues surrounding the endosseous implant must be evaluated (Figures 6 and 7). The soft tissues should not exhibit signs of inflammation such as redness, edema, and purulent discharge. The hard tissues should exhibit minimal crestal bone loss (<2 mm) at the preocclusal load stage. A radiograph of the implant-abutment interface is an essential benchmark for future bone protection (Figure 8). A standard repeatable radiographic technique (ie, X-ray cone positioning device) should be employed to confirm the preload crestal bone levels and complete abutment seating. Implant abutments should be hand tightened, their positions confirmed using an acrylic orientation jig and verified with a radiograph prior to final screw tightening with a calibrated torque wrench to 30 Ncm. The acrylic orientation jig serves to confirm that the abutment placement on the working model corresponds with the same position intraorally (Figures 9 and 10). The orientation jig is instrumental in the placement of the implant abutments into their correct positions. The role of the acrylic jig is most useful when multiple abutments with numerous hexagonal sides are part of the implant reconstruction (Figures 11 and 12). After abutment placement, the interproximal contact points for the implant-supported crowns can be adjusted and the occlusion corrected. It is essential to establish only axial occlusal contacts on

implant crowns, which will increase the compressive axial forces and decrease shear/tensile or angled forces. Endosseous implants should have zero to minimal contacts during centric occlusion and lateral and protrusive excursions. Protrusive movements should permit the anterior teeth to disocclude the posterior implants. If the anterior components are implants, 2 or more should be splinted together. On completion of the occlusal equilibration, the final restoration is cemented with temporary cement and a radiograph is taken (Figure 13). The radiograph should be evaluated and residual cement removed with a nonmetal instrument to avoid scratching of endosseous implants.

#### DISCUSSION

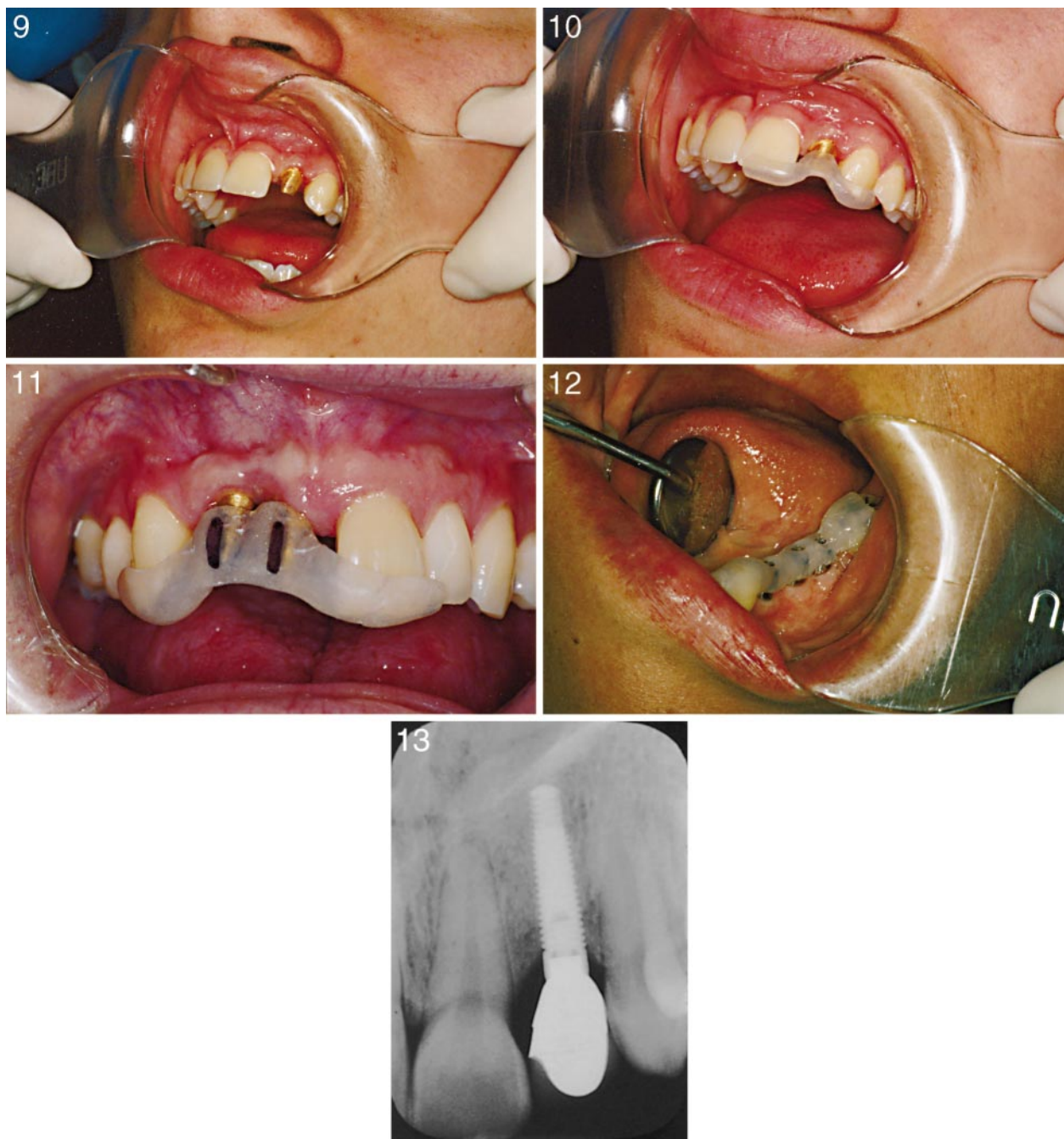
It is critical for the practitioner to appreciate the differences between natural teeth and endosseous implants in regard to the application of stress. The most significant difference is created by the periodontal ligament and its unique properties. This vital structure unique to natural teeth allows for stress distribution, mobility, occlusal trauma tolerance, and proprioception. Endosseous implants lack a periodontal ligament, thereby lacking the properties of that structure. The periodontal ligament allows forces to be dissipated away from the crest and toward the apex of the tooth. The endosseous implant demonstrates no significant movement, which results in greater forces being directed at the crest of the surrounding bone. Because there is no shock-absorber effect, as is seen with natural teeth, implants subjected to excessive occlusal loads will demonstrate microscopic stress fractures, fatigue, cement breakdown, and screw loosening.

The proprioceptive properties of the periodontal ligament assist in the monitoring of centric and excursive forces. Natural teeth exhibit pain sensations, which are considered to be a protective mechanism. Endosseous implants have no proprioceptive mech-

anism to signal excessive force. They may experience a slow, dull pain that delivers a delayed reaction to the host site. These factors may contribute to long-term problems that will jeopardize the survival of implants. It is essential that the implant dentist view the occlusal forces as the weakest link in the dental implant system.<sup>12</sup>

Researchers and clinicians appreciate that natural teeth and endosseous implants have distinctive shape differences. Natural teeth present with very different cross-sectional shapes compared with the circular shape of implants. The varying morphology of natural teeth is influenced by their positions in the arch. They are designed to withstand occlusal trauma by appropriate distribution of forces. The circular shape of endosseous implants makes them less effective during eccentric jaw movements. If one compares the cross-section of a molar to a wide-body implant, there are significant differences in the total surface areas of each.

The major objective of an implantologist is to develop an implant occlusal scheme that will recognize and utilize natural tooth movement. Movement of natural teeth may be from 8 to 28  $\mu$ m. Endosseous implants demonstrate virtually no movement.<sup>13,14</sup> Therefore, for the patient with a tooth and implant-borne reconstruction, attention must be paid to the occlusal scheme. Implant protective occlusion (IPO) is developed from a concept that refers to a specially designed occlusal plan.<sup>15</sup> The IPO is a medially positioned, lingualized occlusion adapted to natural resorptive patterns. Its primary goal is to direct occlusal loads to the implant bodies within the physiologic limits of each patient. It aims at decreasing the forces of occlusal contacts and increasing the number of implants, and their diameters. Thus, if they are subjected to angled loads, unfavorable crown-implant ratios or supporting the cantilever portions of prostheses, they will be able to respond more successfully.



FIGURES 9–13. FIGURE 9. Intraoral abutment placement. FIGURE 10. Intraoral acrylic abutment orientation jig (1 unit). FIGURE 11. Acrylic abutment orientation jig (2 units). FIGURE 12. Acrylic abutment orientation jig (3 units). FIGURE 13. Periapical radiograph—final restoration, implant, abutment, porcelain-fused-to-metal crown.

The management of angled forces and abutments is an essential aspect of implant prosthodontics. Angled forces increase the amounts and types of stress, converting them to a higher level of shear. Angled abutments also exhibit problems due to their inability to direct forces along the long axes. As a

result, it is essential to revise implant numbers, sizes, and locations to optimize occlusal force distribution. The need for surgical ridge augmentation may be indicated in order to improve the labial placement of implants.

Occlusal table width is a critical parameter that the restorative dentist

must assess. The width of the occlusal table may be related to the width of the implant body. It influences the amount of force needed for mastication, buccal-lingual ridge lap dimensions, and porcelain fracture. Wide occlusal tables often cause offset contacts during mastication and parafunction. Therefore,

the buccal-lingual dimensions should be minimized in order to reduce the force required to penetrate a bolus of food. This feature will diminish the levels of stress to the supporting bone.

Another beneficial factor is to increase the total surface area of the implants. This will reduce stress to the bone and can be accomplished by using wider implants and/or splinting standard-size implants together. Of benefit would be to change from a fixed prosthetic reconstruction to a removable design. This is particularly critical when treating a patient who has a parafunctional habit (ie, bruxism).

The utilization of cantilevers is practiced in implant dentistry. Because occlusion is so critical for long-term success, it should be designed, when feasible, to direct forces through the implant bodies and away from any distal cantilevers. This will reduce compressive forces on the distal cantilevers, as well as minimize shear and tensile forces on the more anterior implant abutments. Contact must be avoided at the distal aspects of cantilevers during lateral excursions. Particular attention should be made to the endosseous implant anterior-posterior (A-P) spread, which will determine the length of the cantilevers.<sup>16</sup> As the A-P spread increases, so can the length of the cantilevers. A general rule on cantilever length is  $1.5 \times$  the A-P spread.

#### CONCLUSION

The role of the restorative dentist is to understand the responsibilities to minimize occlusal overload and its deleterious effects. The importance of a proper diagnosis leading to a treatment plan providing adequate support must

be appreciated and the differences between natural teeth and dental implants understood, which would allow the development of an implant-protected occlusion. More specifically, treatment plans containing angled abutments, wide occlusal tables, less than optimal cumulative surface areas, and cantilevers should be alleviated or minimized prior to initiation of therapy. These principles will encourage predictable, satisfactory results.

#### ACKNOWLEDGMENT

The author wishes to acknowledge Melanie Fink and Anita Jones for their assistance in the preparation of this article.

#### REFERENCES

- Misch CE. Occlusal considerations for implant-supported prostheses. In: Misch CE, ed. *Contemporary Implant Dentistry*. St. Louis, Mo: Mosby; 1993:705-733.
- Cranin AN. *Atlas of Oral Implantology*. New York, NY: Georg Thieme Verlag; 1993:18-52.
- Brunski JB. Influence of biomechanical factors at the bone-biomaterial interface. In: Davies JE, ed. *The Bone-Biomaterial Interface*. Toronto: University of Toronto Press; 1991:391-405.
- Brunski JB. Biomechanics of dental implants. In: Block MS, Kent JN, eds. *Endosseous Implants for Maxillofacial Reconstruction*. Philadelphia, Pa: Saunders; 1995:22-39.
- Brunski JB, Hurley E. Implant-supported prostheses: biomechanical analyses of failed cases. In: Hochmuth RM, Langrana NA, Hefzy MS, eds. *1995 Bioengineering Conference BED*. Vol. 29. New York, NY: American Society of Mechanical Engineers; 1995:447-448.
- Brunski JB, Skalak R. Biomechanical considerations. In: Worthington P, Branemark P-I, eds. *Advanced Osseointegration Surgery*. Chicago, Ill: Quintessence; 1992:15-39.
- Brunski JB, Hipp JA, Cochran GVB. The influence of biomechanical factors at the tissue-biomaterial interface. In: Hanker JS, Giammara BL, eds. *Biomedical Materials and Devices*. Pittsburgh, Pa: Materials Research Society; 1995:505-515.
- Misch CE. Progressive bone loading. *Pract Periodont Aesthet Dent*. 1990;2:27-30.
- Misch CE. Progressive bone loading. In: Misch CE, ed. *Contemporary Implant Dentistry*. St. Louis, Mo: Mosby; 1993:623-650.
- Cranin AN. *Atlas of Oral Implantology*. New York, NY: Georg Thieme Verlag; 1993:213-226.
- Cranin AN. *Atlas of Oral Implantology*. New York, NY: Georg Thieme Verlag; 1993:227-247.
- Isidor F. Loss of osseointegration caused by occlusal load of oral implants. A clinical and radiographical study in monkeys. *Clin Oral Implant Res*. 1996;7:143-152.
- Parfitt GS. Measurement of the physiologic mobility of individual teeth in an axial direction. *J Dent Res*. 1960;39:68.
- Sekine H. Mobility characteristics and tactile sensitivity of osseointegrated fixture-supporting systems. In: van Steenberg D, ed. *Tissue Integration in Oral Maxillofacial Reconstruction*. Elsevier, Amsterdam; 1986:306-332.
- Misch CE, Bidez MW. Implant protected occlusion, a biomechanical rationale. *Com Cont Dent Educ*. 1994; 15(11):1330-1343.
- English C. The critical A-P spread. *Implant Soc J*. 1990;1:2-3.