

EDITOR'S NOTE: Drs Wood and Winkler and Mr Lanza are to be congratulated for developing this fascinating innovation. Although the case described involved the presence of mandibular natural teeth, the conditions indicating the utilization of the labial bar can apply to mandibles that have been restored with implants (eg, large tori, lingually inclined implants). Therefore, the authors were asked to submit this interesting paper to the Journal of Oral Implantology.

THE MANDIBULAR LABIAL BAR MAJOR CONNECTOR

Robert Wood, DMD
Sheldon Winkler, DDS
John Lanza, BA

KEY WORDS

Labial bar
Removable partial denture
Framework
Major connector

Robert Wood, DMD, is assistant professor of Restorative Dentistry and assistant director of the Removable Prosthodontic Clinic at Temple University School of Dentistry, Philadelphia, PA.

Sheldon Winkler, DDS, is professor of Restorative Dentistry at Temple University School of Dentistry, 3223 North Broad Street, Philadelphia, PA 19140-5096. He formerly served as professor and chairman of the Department of Prosthodontics at Temple University. Correspondence should be addressed to Dr Winkler at swinkdent@aol.com.

John Lanza, BA, is a dental laboratory technician, Department of Restorative Dentistry, Temple University School of Dentistry, Philadelphia, PA.

The lower labial bar is rarely indicated as a major connector for a removable partial denture. It can be used satisfactorily when large mandibular tori interfere with conventional lingual bar placement or when the lower teeth are severely lingually tipped and placement of a lingual bar is not possible.

INTRODUCTION

The mandibular labial bar is used so infrequently that many removable partial denture textbooks do not include any information on this major connector. However, in certain situations, the lower labial bar is the major connector of choice.

There are two situations when the use of a labial bar should be considered. Mandibular lingual tori can be extremely large and interfere with the satisfactory placement of a conventional lingual bar. The lower anterior teeth and/or premolars can be lingually inclined to such an extent that satisfactory placement of a lingual bar is not possible.

Unless surgery is contraindicated or refused by the patient, surgical removal of mandibular tori is the treatment of choice.

In the case of extreme lingual inclination of the lower anterior teeth

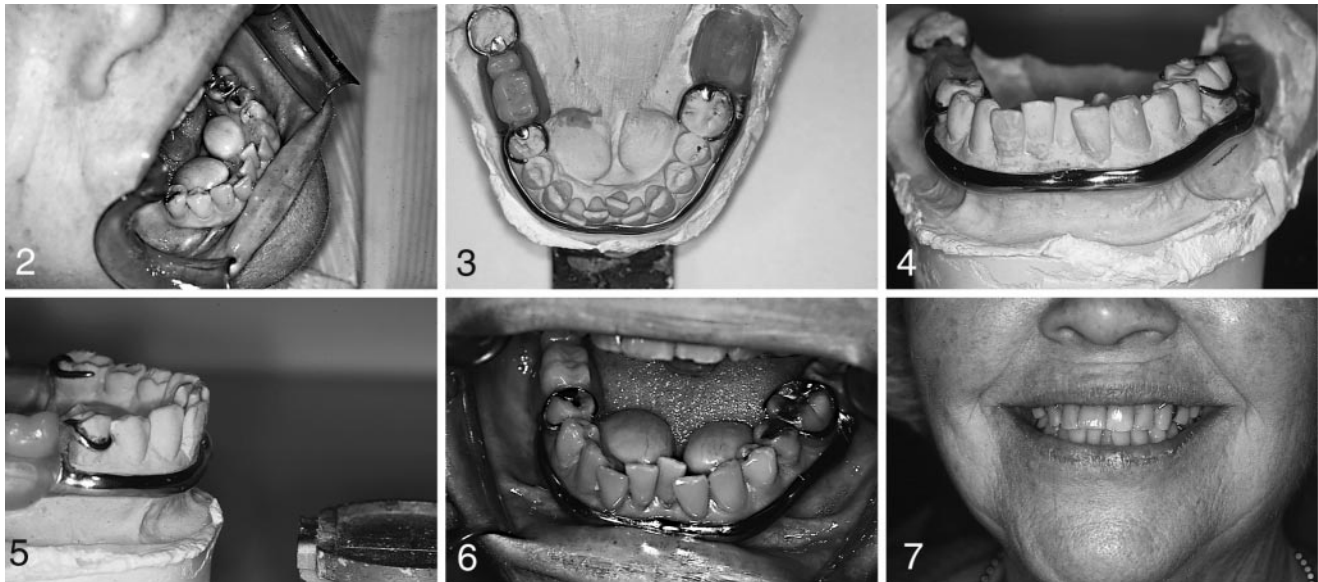
and/or premolars, other alternatives can be considered. The teeth can be recontoured or restored. Orthodontic treatment can be considered. However, in the case of severe lingual tipping, a labial bar generally is the only satisfactory choice.

THE LOWER LABIAL BAR

The labial bar connects the saddles on the left and right sides of a partial denture and can also include an anterior saddle (Figure 1). Like a conventional

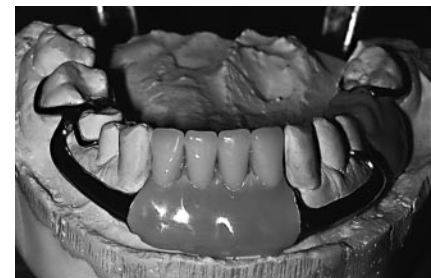

FIGURE 1. Labial bar mandibular removable partial denture with anterior saddle.



FIGURES 2–7. FIGURE 2. A 69-year-old female patient with large bilateral mandibular tori. FIGURE 3. Occlusal view of lower partial denture framework with labial bar. FIGURE 4. Facial view of chromium alloy mandibular labial bar on master cast. FIGURE 5. Lateral view of labial bar. Note relief provided for the bar. FIGURE 6. Intraoral view of completed labial bar mandibular removable partial denture. Note large mandibular tori. FIGURE 7. Lower facial view of patient with upper and lower removable partial dentures in place. Note absence of lower lip distortion.

lingual bar, it is pear shaped and requires relief. It proceeds across the mucosa labial to the anterior mandibular teeth and often buccally to the premolars, preferably as low as possible below the gingival margins of the teeth.

It can be difficult for a patient to adjust to a labial bar as a result of its location between the inner surface of the lower lip and the labial gingiva. In some cases, the labial bar can distort the lower lip and annoy the patient. The lower the bar is placed, the less the possibility of distortion of the lower lip and the better the esthetic result.

During the laboratory wax-up, the

dental technician must ascertain that the path of insertion permits easy insertion and removal of the prosthesis by the patient.

CASE REPORT

A 69-year-old Caucasian woman presented at the Removable Prosthodontic Clinic of Temple University School of Dentistry. Examination revealed that the patient was missing several posterior teeth. Because the patient had no interest in implants, upper and lower removable partial dentures were treatment planned to replace the missing teeth.

Extremely large mandibular tori were present (Figure 2). The patient refused surgical removal of the bony exostoses. Because of the size and location of the tori, a labial bar was designed for the lower prosthesis. Upper and lower removable partial dentures were fabricated, with a lower labial bar serving as the major connector for the lower partial denture cast framework (Figures 3 through 7).

After 1 year of use, the patient was pleased with the esthetics, comfort, and function of the upper and lower removable prostheses. She did not experience any discomfort from the labial bar.