

# USE OF MAGNETIC ABUTMENTS FOR SHORT ENDOSSEOUS IMPLANTS FOLLOWING A FIBULA BONE GRAFT IN AN ORAL CANCER PATIENT: A CASE REPORT

*Junnosuke Ishii, DDS, PhD  
Tatsuya Yoshida, DDS  
Satoshi Yokoo, DDS, PhD  
Takahide Komori, DDS, PhD*

## KEY WORDS

**Magnetic abutment  
Dental implants  
Vascularized fibula graft**

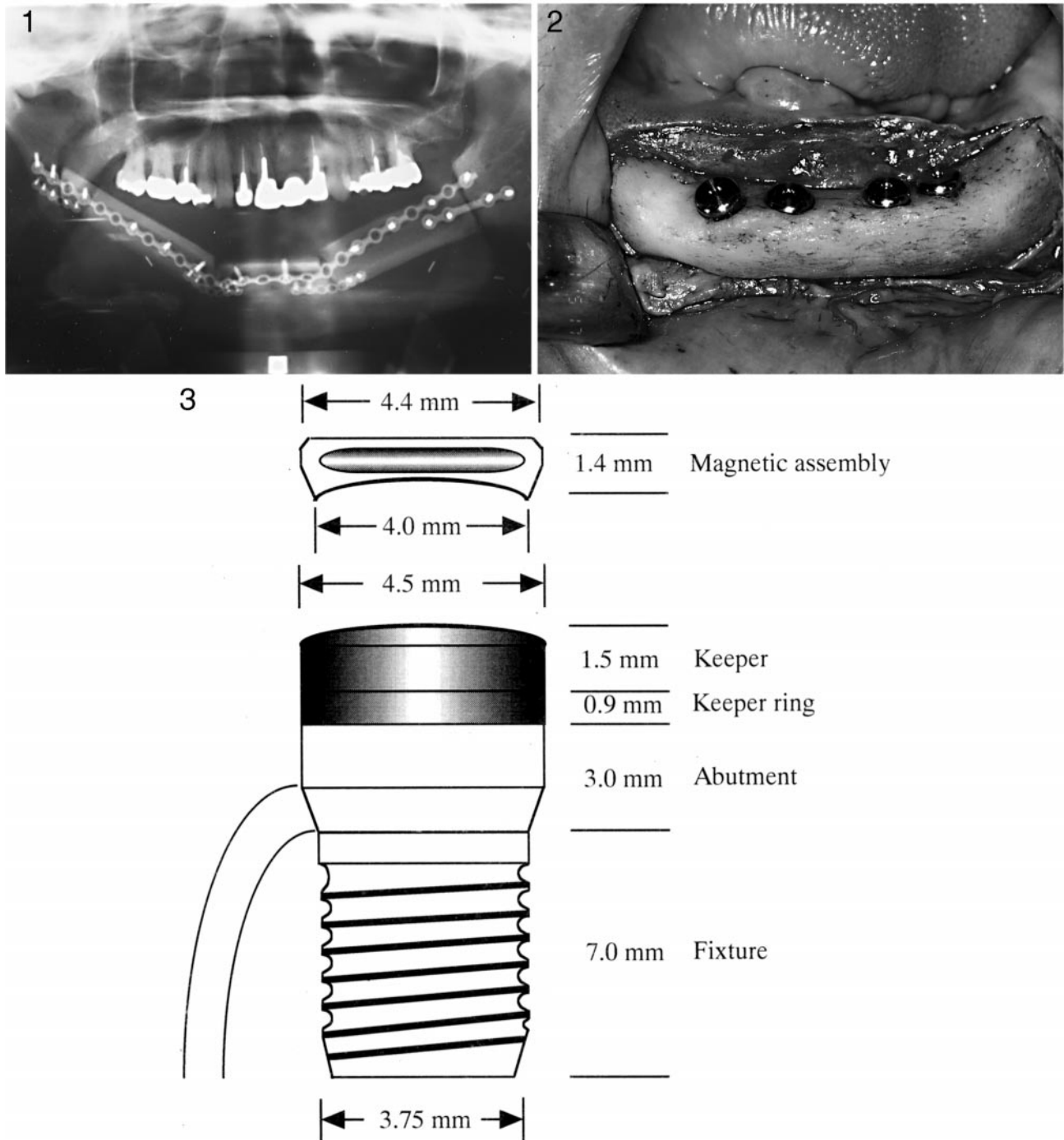
Dental implant treatment is an indispensable portion of oral rehabilitation in patients who are to undergo reconstructive surgery following the removal of an oral cancerous lesion. However, ideal dental implant treatment cannot be achieved easily in patients who have undergone mandibular reconstruction with a free vascularized flap, usually because of the limited length, height, and width of the bone graft. Shorter implants (<10 mm in length) therefore are occasionally used in vascularized fibula graft sites. In such cases, however, shorter implants tend to be overloaded, thereby endangering its longevity. In this article, we discuss how a magnetic abutment system was introduced for such a patient. This was designed to discourage overloading of the mandatory short implants. The outcome was successful without overloading 1.5 years after the placing of the mandibular overdenture.

## INTRODUCTION

The free vascularized flap following removal of oral cancer recently has been greatly improved. Vascularized iliac,<sup>1</sup> scapula,<sup>2</sup> radius,<sup>3</sup> and fibula<sup>4</sup> grafts have been used for mandibular reconstruction after mandibular resection as a treatment for progressive cancer of the tongue and the floor of the mouth, as well as for aggressive cases of gingival carcinoma. Although dental implant treatment is indispensable to oral rehabilitation in such patients, ideal implant treatment cannot be easily

achieved in such patients. The number and length of the implants required for these patients may be restricted because of the limited dimensions of the host bone. Short implants (<10 mm) tend to suffer from overloading, thereby endangering their longevity. In addition, a decreased number of implants can be placed, which will necessitate changing the prosthetic design to an overdenture. For those patients who suffer from an encumbered oral environment, the bar attachments used in overdentures often induce tongue discomfort and speech difficulties. To cor-

*Junnosuke Ishii, DDS, PhD, Tatsuya Yoshida, DDS, Satoshi Yokoo, DDS, PhD, and Takahide Komori, DDS, PhD are from the Department of Oral and Maxillofacial Surgery, Kobe University Graduate School of Medicine, Kobe, Japan. Address correspondence to Dr Junnosuke Ishii, Department of Oral and Maxillofacial Surgery, Kobe University Graduate School of Medicine, 7-5-2, Kusunokicho, Chuo-ku, Kobe 650-0017, Japan (e-mail: ishijun@med.kobe-u.ac.jp).*



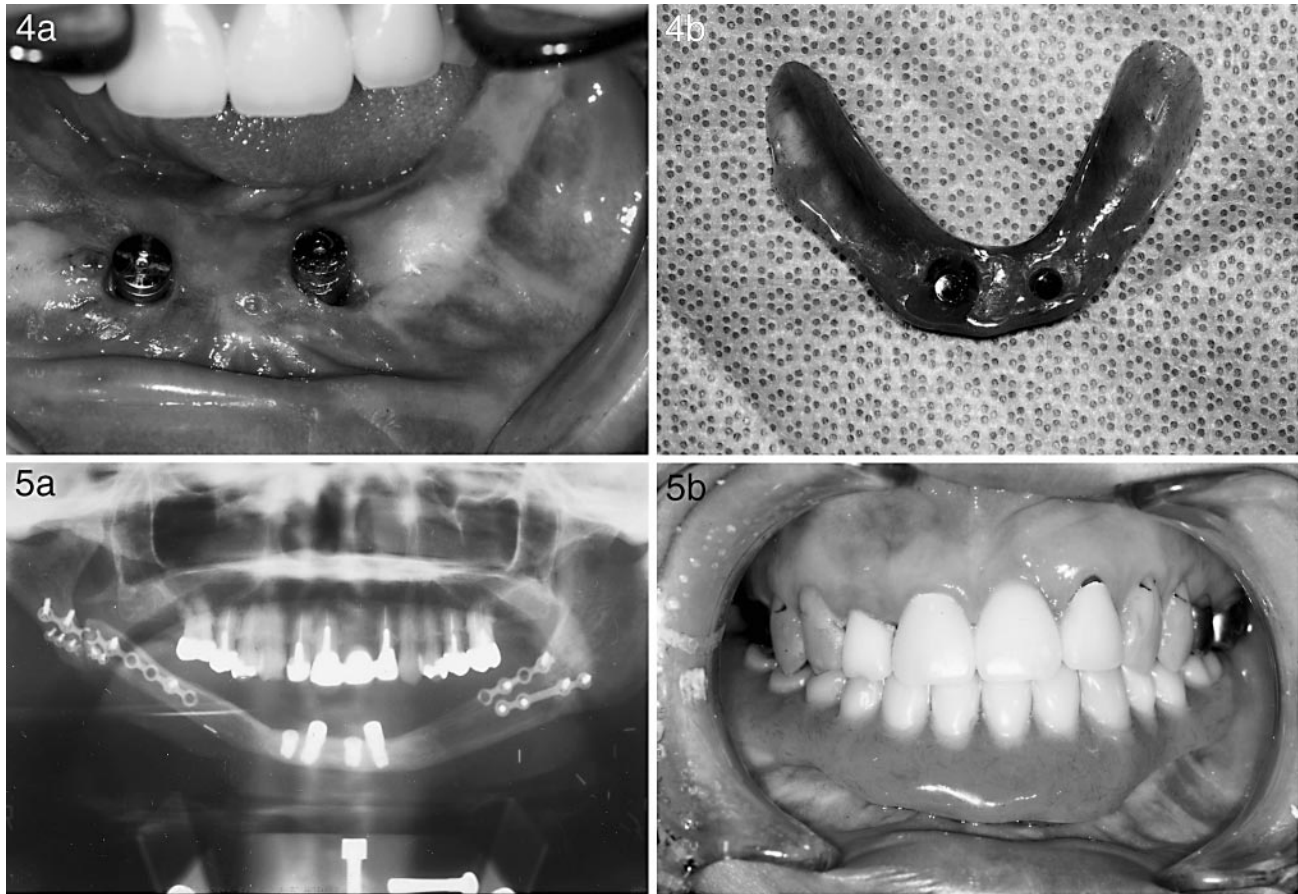
FIGURES 1-3. FIGURE 1. Panoramic radiograph immediately postoperative showing reconstruction with the vascularized fibula graft extending from the right to the left mandibular angle region. FIGURE 2. Intraoperative view of placement of short implants. FIGURE 3. Illustration of the magnetic abutment system.

rect these problems, magnetic abutments were used for dental implant restoration in a patient who presented with a long-span, vascularized fibula graft.

CASE REPORT

A 45-year-old Japanese woman was referred to the Department of Oral and Maxillofacial Surgery at Kobe Universi-

ty in February 1999 complaining of an ulcer of the right mandible. A panoramic radiograph showed an alteration in architecture of the body of the mandible. An enhanced magnetic resonance



FIGURES 4–5. FIGURE 4. (a) Intraoral view after placing the keeper on the abutment. (b) The magnetic assembly is connected to the overdenture. FIGURE 5. (a) Panoramic radiograph after 15 months of the prosthetic load showing an adequate bone-implant interface. (b) Intraoral view after placement of the overdenture.

image confirmed the extent of the lesion, showing growth to the contralateral side of the mandible. Biopsy examination of the specimen revealed that the lesion was a squamous cell carcinoma. She underwent a radical resection extending from the mandibular right to the left angles, bilateral radical neck dissections, and mandibular reconstruction with a vascularized fibula graft in March 1999 (Figure 1). One year later, she underwent removal of the fat tissue of the skin pedicle followed by vestibuloplasty. Subsequently, a mandibular denture was fabricated for her, but it was not satisfactory because of instability. Therefore, dental-implant-based treatment was planned.

Plates and screws that fixed the grafted fibula were removed to create greater room. This was followed by measurements of the depth of the

graft, which was recorded as 8 mm at the point of the fibula, although 10 mm had been noted immediately postoperatively. Branemark implants (Nobel Biocare, Japan, Tokyo) were placed in the grafted bone in May 2001. At the first planning stage, the use of a bar attachment to connect the abutments with an overdenture had been suggested. A total of 4 implants (diameter, 3.75 mm; length, 7 mm) were used in the grafted anterior part of the mandible (Figure 2).

However, a magnetic abutment system (MAGFIT-IP, Aichi Steel Co, Nagoya, Japan), which is composed of a dome-shaped keeper (diameter, 4.5 mm; height, 1.5 mm), a keeper ring (diameter, 4.5 mm; height, 0.9 mm), and a magnetic assembly (diameter, 4.4–4.0 mm; height, 1.4 mm; retentive force, 600 gf) became commercially available

prior to the second-stage surgery (Figure 3). Therefore, the original plan for rehabilitation was altered. Two of the 4 cover screws were removed, permitting the connection of the healing abutments. After wound healing was complete, 2 standard abutments of 3 mm in length were connected. Subsequently, a new overdenture was fabricated.

The magnetic abutment system was used to fix the overdenture to the implants. First, the keeper ring and the keeper were connected to each standard abutment using a screwdriver from the Branemark implant system and this was followed by setting the magnetic assembly on each keeper. Then, 2 holes of approximately 5 mm in diameter were made in the anterior labial side of the new overdenture, correlated with the position of each magnetic assembly. This allowed the magnetic assembly to



be attached to the overdenture using acrylic resin (Figure 4). Satisfactory stabilization was achieved, which permitted the patient to eat a much broader spectrum of food. The design of the superstructure and the less-than-rigid relationship it had with the underlying support mechanism deterred overloading (Figure 5).

#### DISCUSSION

A variety of vascularized bone grafts, including iliac,<sup>1</sup> scapula,<sup>2</sup> radius,<sup>3</sup> and fibula<sup>4</sup> have been used for mandibular reconstruction. However, each has drawbacks. The iliac crest harvest may lead to complications such as injury to the femoral cutaneous nerve, abdominal herniation, and prolonged gait pain,<sup>5</sup> although it can provide significant amounts of bone volume.<sup>6</sup> The scapula has limited width<sup>7</sup> and length, although the height is adequate to accommodate implants. The radius is of limited length<sup>7</sup> and it does not offer adequate bone volume for implant placement.<sup>8</sup> Donor-site morbidity is relatively high because fracture of the donor radius may occur.<sup>9</sup>

The fibula is the most appropriate source for mandibular reconstruction long-span defects because it can be made available in lengths of up to 25 cm.<sup>10</sup> Therefore, it has become popular for use in mandibular reconstruction. It is also suitable to encourage implant osseointegration because of its bicortical structure despite its limited height.<sup>11</sup> Recently, distraction osteogenesis techniques were used to enhance severely resorbed mandibles, which permitted the use of larger implants.<sup>12</sup> Chiapasco et al reported the use of longer implants in the fibula after the use of distraction osteogenesis.<sup>13</sup> However, some problems may occur with its use, including (1) difficulty in determining direction, (2) possibility of segmental necrosis, (3) potential fracture of the treated bone, and (4) longer duration of treatment.

#### SUMMARY AND CONCLUSIONS

In this study, a grafted bone 18 cm in length was needed to reconstruct the

mandible. It was considered that fibular grafting was the most favorable reconstruction technique. It has been reported that the average height of the fibula is about 10 mm.<sup>6</sup> In the present case, the height of the fibula at the midline was less than 10 mm. Success was achieved despite the use of implants of minimal length. Shorter implants are often used for severely resorbed mandibles<sup>14</sup> and for bone-anchored facial prostheses.<sup>15</sup> However, this quality tends to cause overloading, which would threaten longevity, especially if the ratio of implants to superstructures is greater than 1:1.<sup>16</sup> In this study, the ratio of implants to superstructures (1:1.30), is reduced by using a magnetic abutment system rather than a ball or bar attachment because the total thickness of the keepers are only 2.4 mm. If a ball or bar attachment had been used to connect the abutments, an unfavorable ratio of implants to superstructures would have been introduced. In addition, the dome-shaped keeper contributes to minimizing overloading because its specific structure reduces masticatory forces. It is suggested that the magnetic abutment system is useful not only for grafted fibulas but also for severely resorbed jaws.

#### REFERENCES

1. David DJ, Tan E, Katsaros J, Sheen R. Mandibular reconstruction with vascularized iliac crest: a 10-year experience. *Plast Reconstr Surg.* 1988;82:792-803.
2. Sullivan MJ, Baker SR, Crompton R, Smith-Wheelock M. Free scapular osteocutaneous flap for mandibular reconstruction. *Arch Otolaryngol Head Neck Surg.* 1989;115:1334-1340.
3. Vaughan ED. The radial forearm free flap in orofacial reconstruction: personal experience in 120 consecutive cases. *J Craniomaxillofac Surg.* 1990;18:2-7.
4. Serra JM, Paloma V, Mesa F, Balasteros A. The vascularized fibula graft in mandibular reconstruction. *J Oral Maxillofac Surg.* 1991;49:244-250.
5. Kurz LT, Garfin SR, Booth RE. Harvesting autogenous iliac bone grafts. A review of complications and techniques. *Spine.* 1989;14:1324-1331.
6. Frodel JL, Funk GF, Capper DT, et al. Osseointegrated implants: a comparative study of bone thickness in four vascularized bone flaps. *Plast Reconstr Surg.* 1993;92:449-458.
7. Hidalgo DA. Aesthetic improvements in free-flap mandible reconstruction. *Plast Reconstr Surg.* 1991;88:574-585.
8. Hayter JP, Cawood JI. Oral rehabilitation with endosteal implants and free flaps. *Int J Oral Maxillofac Surg.* 1996;25:3-12.
9. Vaughan ED. The radial forearm flap in orofacial reconstruction. *Int J Oral Maxillofac Surg.* 1994;23:194-204.
10. Wei FC, Seah CS, Tsai YC, Liu SJ, TSAI MS. Fibula osteoseptocutaneous flap for reconstruction of composite mandibular defects. *Plast Reconstr Surg.* 1994;93:294-304.
11. Urken ML. Composite free flaps in oromandibular reconstruction: review of the literature. *Arch Otolaryngol Head Neck Surg.* 1991;117:724-732.
12. Urbani G, Lombardo G, Santi E, Consolo U. Distraction osteogenesis to achieve mandibular vertical bone regeneration: a case report. *Int J Perio Rest Dent.* 1999;19:321-331.
13. Chiapasco M, Brusati R, Galimoto S. Distraction osteogenesis of a fibular revascularized flap for improvement of oral implant positioning in a tumor patient: a case report. *J Oral Maxillofac Surg.* 2000;58:1434-1440.
14. Stellingsma C, Meijer HJA, Raghoebar GM. Use of short endosseous implants and an overdenture in the extremely resorbed mandible: a five-year retrospective study. *J Oral Maxillofac Surg.* 2000;58:382-387.
15. Kovacs AF. A follow-up study of orbital prostheses supported by dental implants. *J Oral Maxillofac Surg.* 2000;58:19-23.
16. Saadoun AP, LeGall ML. Clinical results and guidelines on Steri-Oss endosseous implants. *Int J Periodontol Restor Dent.* 1992;12:487-499.