

# ACCURACY OF CLINICAL AND RADIOLOGICAL CLASSIFICATION OF THE JAWBONE ANATOMY FOR IMPLANTATION—A SURVEY OF 374 PATIENTS

*Gintaras Juodzbalyis, DMS, PhD*  
*Aune M. Raustia, DDS, PhD*

## KEY WORDS

**Jaw atrophy**  
**Endosseous implants**  
**Guided bone regeneration**  
**Bioresorbable membrane**  
**Deproteinized bovine bone**  
**Sinus augmentation**

*Gintaras Juodzbalyis, DMS, PhD, is associate professor in the Department of Oral and Maxillofacial Surgery, Kaunas University of Medicine, Vainiku 12, LT-3018 Kaunas, Lithuania. Correspondence should be addressed to Dr juodzbalyis.*

*Aune M. Raustia, DDS, PhD, is professor in the Department of Prosthetic Dentistry and Stomatognathic Physiology, Institute of Dentistry, University of Oulu, and is chief dentist in the Oral and Maxillofacial Department, Oulu University Hospital, Oulu, Finland.*

The aim of this study was to investigate the anatomical features of edentulous jaw dental segments (eJDS) in order to offer the most reliable clinical and radiological classification of such segments in planning for implant treatment. A total of 374 patients, 156 men and 218 women, participated in the investigation. The mean age of the patients was 46 years (SD 12.7), ranging between 17 and 73 years. The eJDS were estimated by means of orthopantomogram, computerized tomography, and intraorally with special ridge-mapping callipers for measurement of alveolar process width. A total of 792 screw-shaped and 1-stage Osteofix Dental Implant System (Oulu, Finland) implants were inserted. Dental segments were divided according to the results of the commonly accepted eJDS assessments into 3 clinical-anatomical types. Type I indicated insignificant or no atrophy of eJDS (232 patients with 476 implant sites; 60.1% of the total number). Type II indicated mild to moderate vertical or horizontal atrophy of eJDS (100 patients with 222 sites; 28% of the total number). Type III indicated significant vertical or horizontal atrophy of eJDS (42 patients with 94 sites; 11.9% of the total number). The accuracy of the clinical and radiological classification was adjudged to have been 95.8%. By the process of establishing clinical and radiological classification of the jawbone segments, more reliability was anticipated regarding the insertion of implants both in maxillae and mandibles.

## INTRODUCTION

The new era of modern implantology began in 1969 upon the publication of the first results of using titanium dental implants.<sup>1</sup> Since that time, the shapes and surfaces of these implants have changed. Nevertheless, this method still ranks as the most popular and reliable. The mean implantation success rate is higher than 90%.<sup>2</sup> The estimated cumulative implant survival rates 10 years after implantation were reported as 89.9% for the maxilla and 93.3% for the mandible.<sup>3-4</sup> The results remained unchanged after 16.6 years. The success of implantation depends on a variety of factors, 1 of which is the selection of patients.<sup>5</sup> After accepting the patient's state of health, the anatomical features of the jaw must be evaluated so that proper treatment may evolve.

Atrophy of the alveolar processes is expressed as reduction of height and width. This frequently occurs after the loss of teeth. New treatment methods, such as guided bone regeneration (GBR),<sup>6-10</sup> sinus floor augmentation with bone or bone substitutes,<sup>11-16</sup> and horizontal and vertical osteoplasty,<sup>17</sup> have contributed to the reconstruction of atrophic jaws, thereby permitting a more liberal use of endosseous implants.

There is a wide choice of screw-type implant systems. Therefore, it is important to measure the alveolar process precisely so that the proper system may be chosen.<sup>18</sup> There are many classifications suggested for assessment of the degree of atrophy of partially edentulous jaws.<sup>19-24</sup> One of the most popular classifications of the quality and quantity of the jawbones was

established in 1985.<sup>25</sup> However, this classification, like many others, described changes only of jaw shapes in general and failed to indicate precise measurements of potential operative sites.<sup>26</sup> In the system described in this paper, bone atrophy is evaluated according to analyses of jaw cross-sections. Jaw cross-sections consist of alveolar and basal bone. Usually, vertical and horizontal measurements of these are recorded when implant operations are planned. Vertical measurements involve the planned implant site and usually correspond to the basal bone. For example, the vertical distance from the crest of the ridge to the mandibular canal is important information for surgeons. Because the term cross-section does not correspond exactly with the implant position, the delineation of implant site is not strictly anatomical and therefore cannot be used in assigning clinical-anatomical classifications. Some authors have used terms such as the triangle of bone and bone profile at implant site.<sup>27-28</sup> These terms lack relevance, as do the others. It is much more accurate to use the term jaw dental segment (JDS). This is defined as a vertically cut jaw segment with tooth, alveolar bone, and all or part of the basal bone. The location of bone suitable for implantation is identical with the former location of a tooth in the jaw. The number of the JDS describing the position of a planned implant in the jaw can be shown. If the JDS is edentulous, the term edentulous jaw dental segment (eJDS) is used. In view of these considerations, the purpose of this study was to offer the most reliable clinical and radiological information of potential eJDS in order to optimize prognoses for implant surgery.

## MATERIALS AND METHODS

### *Patients*

Three hundred seventy-four patients, 156 men and 218 women, were enrolled in the investigation. They were consecutive patients treated with dental implants in the Department of Maxillofacial Surgery, University of Kaunas. Their mean age was 46 years (SD = 127), ranging between 17 and 73 years (Table 1). Three hundred fifty patients (93.6%) were partially edentulous. Only 22 patients were fully edentulous; 10 had edentulous maxillae and 12 had edentulous mandibles. The implantations were performed only after the general health status of all patients had been deemed satisfactory. Contraindications for implantation were disorders of the immune system, uncontrolled diabetes mellitus, significant osteoporosis, the presence of oncologic problems, the use of chemotherapy and radiotherapy, alcohol abuse, and heavy smoking.

### *Clinical and radiological assessments*

To obtain clinical and radiological assessments of the eJDS, evaluation was begun at the widest point of each segment. Because the crest of the alveolar process was often thin, it was necessary to shave it and thus produce a plane surface for the planned implant installation. In such cases, the heights of eJDS would have been shortened by 1 to 3 mm; this change had to be considered when performing dental segment height evaluation.

The width of the alveolar process was estimated intraorally with ridge-mapping callipers.<sup>29</sup> This ridge-mapping method is simple to use and avoids exposure to radiation. The tech-

TABLE 1

Edentulous jaws dental segments height and width measurements (mm) depending on localization

Dental Segments (maxilla)	18	17	16	15	14	13	12	11	21	22	23	24	25	26	27	28
Width																
Mean	7	7.5	6.6	6.1	5.6	4.9	4.6	4.5	4.6	4	5.1	5.8	6.2	6.8	7.6	7
SD	2.8	2.4	2.5	2.0	1.8	1.4	1.3	0.7	1.1	0.8	1.2	1.4	2.3	2.2	2.7	2.4
Height																
Mean	9.7	11.5	11	12.8	13.7	14.6	13.8	14.1	14	13.9	14.8	14	13.1	11.1	11.7	9.8
SD	3.7	5.2	4.9	5.8	5.6	4.7	5.3	4.8	5.2	4.9	5.2	5.7	5.6	5.0	4.2	3.2
Dental Segments (mandible)	48	47	46	45	44	43	42	41	31	32	33	34	35	36	37	38
Width																
Mean	7.8	6.9	6.6	5.4	5.3	5.3	4.5	4.4	4.4	4.6	5.6	5.4	5.5	6.7	7	8
SD	2.9	3.2	3.0	1.5	1.4	1.3	1.0	1.0	1.0	1.1	1.3	1.4	1.2	3.0	2.9	2.6
Height																
Mean	7.6	10.6	11.2	13.5	14	...	...	...	...	...	...	13.8	12.7	11.1	11.1	7.5
SD	3.2	3.7	3.8	4.1	7.6	...	...	...	...	...	...	7.1	4.7	4.1	4.1	2.7

nique was modified by making measurements in a vertical plane in the eJDS at points 3, 4, 5, and 6 mm from the alveolar bone crest. This technique minimized discrepancies. The smallest measurement was accepted as the width of the eJDS (Figure 1).

The height of the alveolar process was estimated by the orthopantomogram and the stencil of the Osteofix dental implant system (Oulu, Finland), taking into consideration the average X-ray magnification of 20% (Cranex-3, Soredex, Finland). Spiral computerized tomography (CT) scans (Somatom Plus, Siemens, Erlangen, Germany) were used in cases of significant jaw atrophy, when particularly high-precision measurements of the jaws were necessary. The CT scans were derived following the standard exposure and patient positioning protocol of the Department of Radiology of the University Hospital of the Kaunas Medical School. Scanning was performed with a software program for soft and hard tissues of the maxillofa-

cial region in slices of 2-mm thickness and in a 3-mm table step at 140 kV 130 mA, Kernel AH60, with the "head-legs" direction. The height measurements were taken in a vertical plane at the points of the eJDS from the tip of the alveolar bone to the maxillary sinus and nasal sinus in the upper jaw and mental foramen and mandibular canal in the lower jaw.

*Edentulous jaw segment parameters*

The minimal heights and widths of eJDS for proper implantation were estimated according to the principles of threaded implant insertion. Recommendations for successful results ideally require at least 1 mm of bone surrounding each implant.<sup>30</sup> The diameters of Osteofix implants require that the minimal width of the alveolar process be 5.8 to 6.2 mm. Most implant systems require bone widths of 5 to 7 mm.<sup>8,25</sup> We estimated that for proper implan-

tation, the minimal width of an alveolar ridge should be 6 mm.

Several factors are considered when estimating the minimal height of an alveolar process. In areas where esthetic results were important (anterior parts of mandible and maxilla), the measurements were made with the implant head 2 mm lower than the necks of the adjacent teeth.<sup>31</sup> If the operation was planned according to the orthopantomogram, implantation in the areas of the mandibular canal or the maxillary sinus mandated that the apices be at least 2 mm away from those vital structures. A minimum of 1 mm was demanded if the operation was planned with CT.<sup>32</sup> When shorter implants were required, they were used in conjunction only with longer ones. When this was not feasible, sites of only the higher levels of bone density were selected.<sup>18,33</sup> Essentially, the minimal height of the eJDS measured in orthopantomograms was at least 10 mm.

Patients whose dimensions satisfied these requirements were

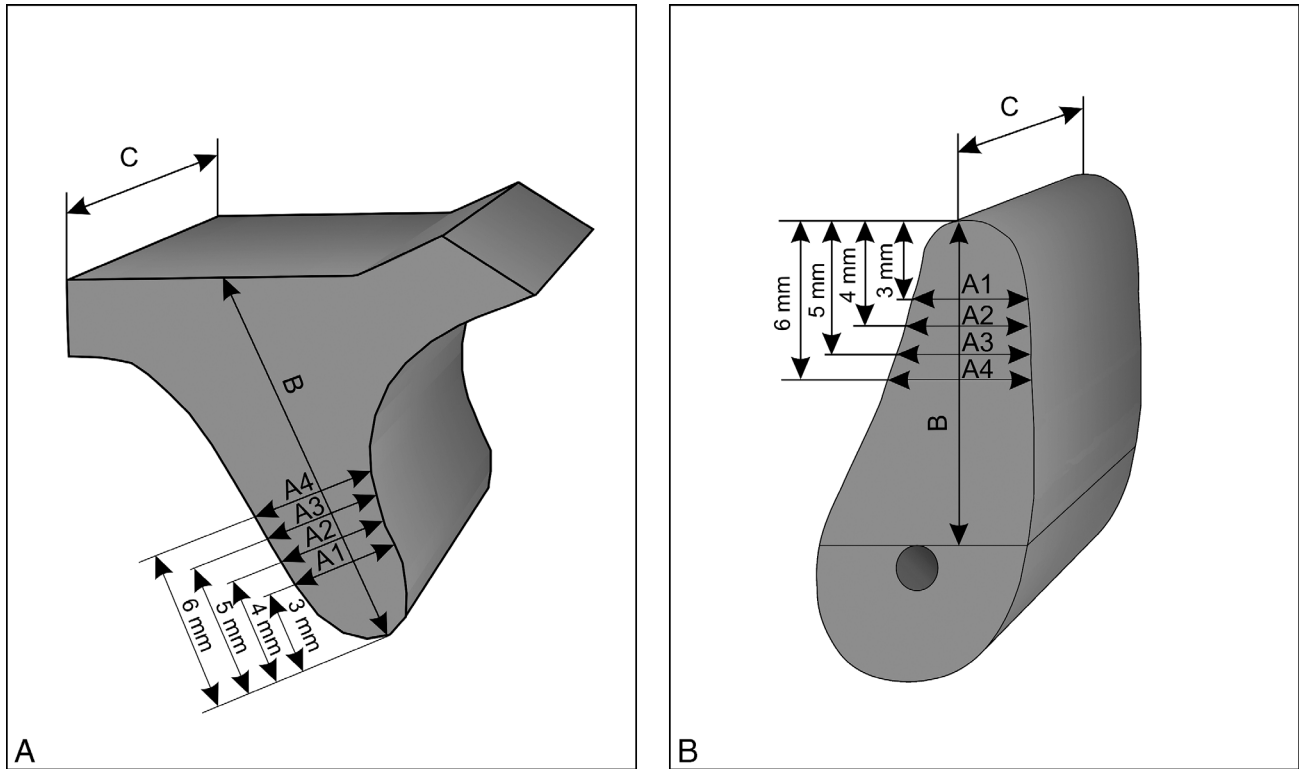


FIGURE 1. Edentulous jaw segments: (A) upper jaw, (B) lower jaw (A<sub>1</sub>, A<sub>2</sub>, A<sub>3</sub>, A<sub>4</sub>: width; B: height; C: length).

considered Type I. Patients with the less height (4–8 mm) were considered to be Type II. However, such heights were found to be sufficient to ensure primary stability of implants. Alveolar ridges with widths of 4 to 5 mm were deemed insufficient for proper implantation. Despite such deficiencies, it was expected that the wider parts of the implants would be covered by bone after insertion and that primary stability would be achieved. Patients whose eJDS ridge heights and widths were less than 4 mm were categorized as Type III. These measurements were considered to be insufficient for primary stability of implants.

Another important factor for proper implantation was the (anteroposterior) length of the eJDS. The minimal distance between 2 implants should be at least 3 mm<sup>34</sup>, and minimal distances between implants and natural roots should be at least 1.5 mm.<sup>35</sup>

Considering that the minimal recommended diameter of implants is 3 mm, all eJDS must have been at least 6 mm in length. This dimension was required in all cases irrespective of the degree of jaw atrophy.

#### *Clinical and radiological classification of jawbone anatomy*

The following clinical and radiological classification of alveolar bone is suggested in dental implantation, taking into consideration similar sizes of most screw-type implant systems and the traditional methods and principles of making measurements for their insertion.

##### *Type I*

The height of the eJDS is  $\geq 10$  mm and the width is  $\geq 6$  mm. Vertical defects in the anterior region must be  $\leq 3$  mm from the crest

of alveolar bone to the necks of the adjacent teeth. In Type I areas, there is little or no atrophy of the jaws; therefore, sound principles of implant surgery may be practiced.

##### *Type II, A, B, C, D*

In Type IIA, the height of the eJDS is  $\geq 10$  mm and the width is 4 to 5 mm (narrow eJDS). In Type IIB, the height of the eJDS is 4 to 9 mm and the width is  $\geq 6$  mm (shallow eJDS). In Type IIC, the height of the eJDS is 4 to 9 mm and the width is 4 to 5 mm (shallow and narrow eJDS). In Type IID, the height of the eJDS is  $\geq 10$  mm and the width is  $\geq 6$  mm; the vertical cosmetic defect in an anterior region is more than 3 mm from the crest of alveolar bone to the necks of the adjacent teeth (Figure 2).

Immediate implantation in such cases is possible only with (1) horizontal alveolar augmentation

with GBR, (2) vertical alveolar augmentation with GBR or sinus floor augmentation, (3) vertical alveolar augmentation with GBR or sinus floor and horizontal alveolar augmentation with GBR, or (4) horizontal alveolar augmentation with GBR.

### Type III

The height of the eJDS is  $<4$  mm and the width is  $<4$  mm (eJDS is both too shallow and too narrow for dental implantation). Implantation can be performed as a second stage only after augmentation or reconstruction of the potential host site has been completed (Figure 3).

### Implant placement

Implantation was performed with Osteofix implants, which were of 8, 10, 12, and 14 mm in length and 3.8 and 4.2 mm in diameter. The implantation was performed according to a standard protocol.<sup>36</sup> The patients were given 2 g of VK-penicillin 1 hour before the surgery and 2 g twice a day for 7 days postoperatively. Chlorhexidine gluconate 0.2% (Adams Healthcare) oral rinses were prescribed twice a day for 2 weeks. The sutures were removed after 10 days.

### Intraoperative evaluation of surgery

The accuracy of the planning classifications was compared with the clinical and radiological eJDS assessments. Insufficient accuracy was noted for the following parameters: (1) implant threads were not completely covered after implantations, (2) bony walls of the implant host sites fractured during the drilling procedures or implant insertions, and (3) insufficient primary implant stability.

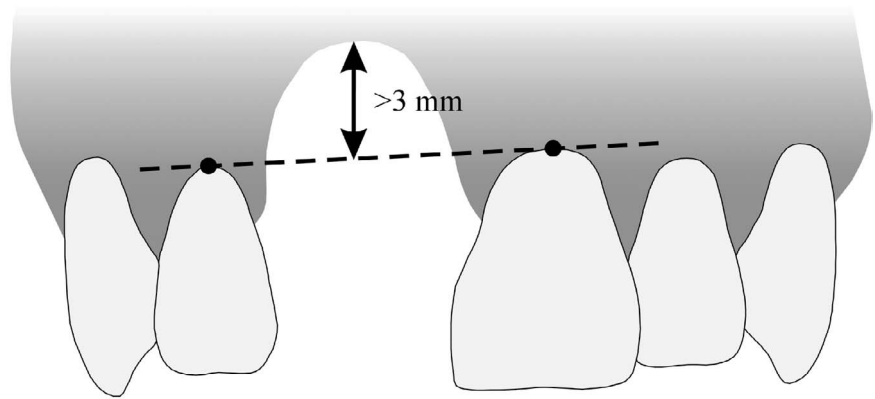


FIGURE 2. The vertical component of the alveolar bone defect is measured from the lowest point of the defect to an imaginary tangent running through the necks of the adjacent teeth. A distance of  $>3$  mm constitutes a significant cosmetic defect.

### Statistical analysis

Statistical analyses were performed with the SPSS/PC+ version 10.0.1 program (SPSS, Inc, Chicago, Ill). Standard deviations of the means were calculated. The accuracy of the clinical and radiological classifications was calculated as the number of properly installed implants divided by the total number of implants, and the resulting number was multiplied by 100. This yielded the results in percentages.

## RESULTS

### Implant installation based on clinical and radiological classification of jawbone anatomy

The height and width assessments of eJDS measured clinically and radiologically in different segments of maxillae and mandibles are presented in Table 1. When analysing the results of the measurements, we found that proper implantation was possible at 476 implant sites (60.1% of the total number) for 232 patients (96 men and 136 women) in the Type I group (Table 2). Patients within the age range of 17 to 45 years (mean 40.9 years, SD 11.8) domi-

nated this group (50% of the total). The distribution of the defects of the arch according to defect localization is shown in Figure 4.

The Type II group consisted of 100 patients, and eJDS with insufficient measurements for proper implantation were found in 222 implant sites (28% of the total number) (Table 2). The mean age of the individuals in this group was 45.8 (SD 13.4) years.

In 52 patients of the Type II group for whom GBR was applied, we found vertical atrophy in 48 segments, horizontal atrophy in 53 segments, and both vertical and horizontal atrophy in 19 segments (Table 3). If sufficient primary stability of the implant was achieved, the remaining bone defects around the implant were filled by using GBR<sup>10</sup> with deproteinized bovine bone mineral (Bio-Oss, Geistlich AG, Wolhusen, Switzerland) and covered with a collagen membrane (Bio-Gide, Geistlich AG, Wolhusen, Switzerland). The membrane was extended onto the intact bony walls around the defect and fixed in place with resorbable pins (Resor Pin, Geistlich AG, Wolhusen, Switzerland).

In the anterior region, vertical defects of more than 3 mm from

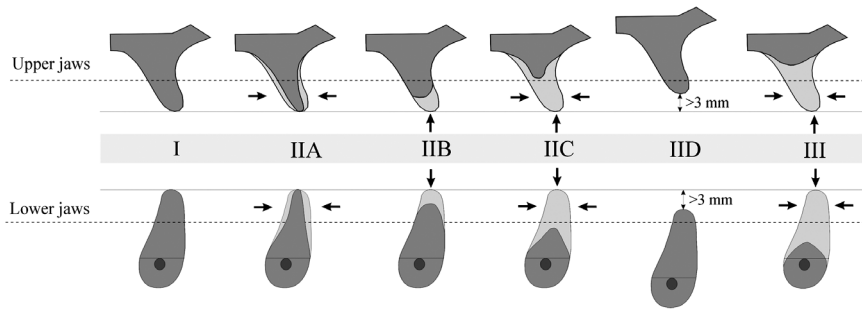


FIGURE 3. A proposed classification of jaw anatomy based on edentulous jaw dental segments clinical-anatomical types. The interrupted lines indicate the approximate demarcation between alveolar and basal bone. Straight lines indicate alveolar ridge crest levels. Type I: height of the eJDS is 10 mm, width 6 mm. Type IIA: height of the eJDS is 10 mm, width 4 to 5 mm (narrow eJDS); IIB: height of the eJDS is 4 to 9 mm, width 6 mm (low eJDS); IIC: height of the eJDS is 4 to 9 mm, width 4 to 5 mm (low and narrow eJDS); IID: height of the eJDS is 10 mm, width 6 mm, the vertical defect in anterior region is  $>3$  mm from the alveolar bone crest to the adjacent teeth necks. Type III: height of the eJDS is  $<4$  mm, width  $<4$  mm (eJDS is too low and narrow for dental implantation).

the alveolar bone margin to the necks of the adjacent teeth had been noted for 11 patients (12 implants). To obtain better cosmetic results, these implants were inserted with their shoulders placed 2 mm below the necks of the adjacent teeth. Guided bone regeneration was used for the filling of accompanying bone defects.

Forty-eight patients (91 implants) with 4 to 8 mm of bone height from the alveolar crest to the maxillary sinus floor were assigned to a separate group of Type II patients. Immediate implant insertion accompanied by maxillary sinus floor augmentation (with autogenous bone graft taken from the chin) was performed for 8 patients (16 implants). Xenogenic bone (Bio-Oss, Osteohealth, Shirley, NY) had been used for 40 patients (86 implants).<sup>11,12</sup> Autogenous bone was used for patients with low eJDS (4–5 mm). However, after the insertion of the implants into the sinus floors, sufficient primary stability was noted. Implantations in the region of premolars and molars of both jaws were the most common sites for the Type II patients (Figure 5).

The Type III group consisted of 42 patients, 12 men and 30 women (94 implants, 11.9% of the total number), with a mean age of 46.6 years (SD = 12.9). Immediate implantation, including bone grafting, was not available for these patients (Table 2). Primary stability of these implants could not be assured because of shallow, narrow alveolar (less than 4 mm). Therefore, grafting of these defects followed by later implantation was the universal approach for Type III patients (Figure 6). The site most frequently used in maxillae was the anterior region. Immediate implantation was not possible because of the severe deficiencies. Augmentation with later implantation was performed in these cases to preserve the thin, shallow alveolar processes.

#### Evaluation of immediate implantation

When comparing the preoperative clinical and radiological eJDS measurements with the intraoperative observations for the Type I patients, we found that implant thread coverage was incomplete in 14 cases. In 6 cases,

lateral surfaces of the implants were exposed in the posterior maxillae eJDS. We noted significant buccal concavities in all those 6 cases. After analysis of possible causes of this complication, we concluded that, despite cases that showed minimal thicknesses of 6.0 to 6.7 mm with implant diameters of 3.8 mm, poorly made osteotomies were responsible for exposure and the need for unanticipated GBR surgery.

Nonetheless, the accuracy of matching preoperative findings with those observed intraoperatively for the patients of Type I was 95.8%.

Comparing the pre- and intraoperative assessments for the Type II group was less satisfactory. Primary implant stability failed in 7 of the cases. The main reason for this was fracture of the walls of the shallow and narrow alveolar processes. It was estimated that the bony walls of host sites were fractured during the drilling procedures in 3 cases and during implant insertion in 4 cases. Insufficient primary implant stability was noted in 2 cases when an implant was inserted into an eJDS in the maxillary sinus region. In all these failures, the widths of eJDS were from 4 to 5 mm and the heights were from 5 to 6 mm.

Despite the higher percentage of failures and complications, the accuracy of the clinical and radiological classifications among the Type II patients was established intraoperatively at 95.9%. The accuracy of clinical and radiological classification for the patients of Type III was not assessed.

#### DISCUSSION

Most of the known classifications used to characterize the degree of

TABLE 2  
Distribution of the patients and implants according to the measurements of the jaws

Group	Sex				Age (y)						Age Mean		Total Implants	
	Male		Female		17-44		45-59		≥60		Years	SD	n	%
	n	%	n	%	n	%	n	%	n	%				
Type I	96	41	136	59	116	50	72	31	44	19	40.9	11.8	476	60.1
Type II	48	48	52	52	48	48	34	34	18	18	45.8	13.4	222	28
Type III	12	25	30	75	6	14	27	64	9	22	46.6	12.9	94	11.9
Total	156		218		170		133		71		46.0	12.7	792	

jaw atrophy are based on schematic terms of the jaw: jaw cross-section,<sup>25</sup> "the triangle of bone,"<sup>28</sup> and bone profile at implant site. However, these terms are not anatomical. As compared with these previously published delineations, eJDS are most readily identified references assigning anatomical areas to implant sites because they consist of the alveolar bone and a part of the basal bone. These anatomic sites can be established when teeth are present or soon after tooth extraction when immediate implant insertion has been performed. The exception is in the region of the lower incisors, where the tooth roots are very narrow. To do so here is to couple 2 incisor sites.<sup>37</sup> The mesiodistal diameters of the mandibular central and lateral incisor roots at the cemento-enamel junction are 3.5 and 4.0 mm, respectively.

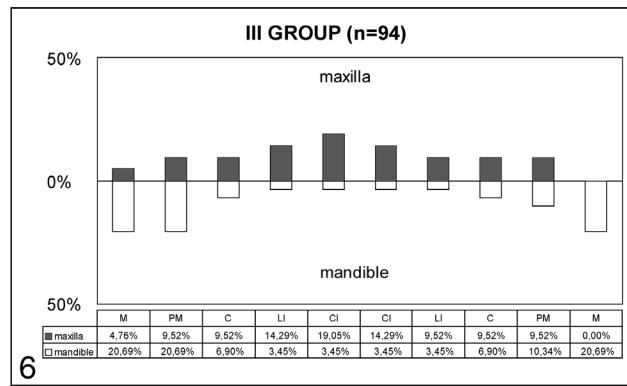
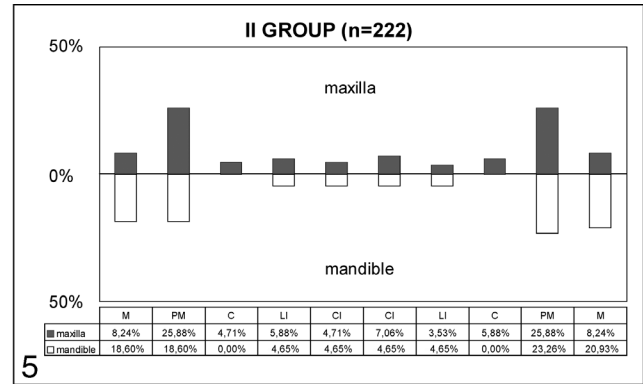
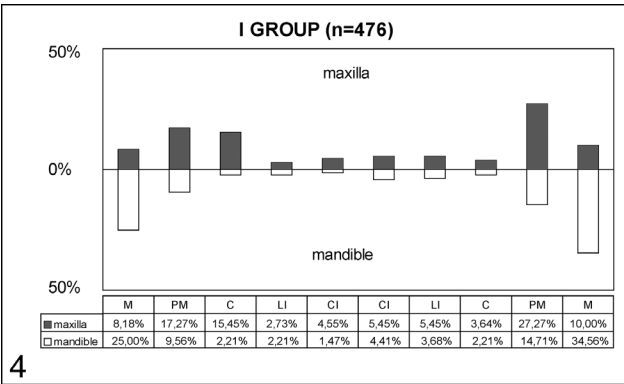
The requirements for the height of the alveolar and basal bone of the jaw as well as the optimal length of the screw-type implant necessary for successful implantation have been described in the past decade.<sup>26-29</sup> Implants of 8 mm or longer were chosen in our study.<sup>18,33</sup> Requirements for the necessary width of the host bone and the minimal diameter of the implant were reported as well.<sup>18,21,25</sup> Some systems have very small (3-mm diameter) or very large (5-mm diameter) im-

plants. Indications for use of the smaller implants are restricted because of poor biomechanics. Implants of large diameter are rarely used because alveolar ridges can rarely accommodate them.<sup>38,39</sup> The literature indicates that the minimal distance between implants or between an implant and an adjacent tooth should be at least 3 mm and 1.5 mm, respectively. When all the anatomic requirements for the implant site are known, it is possible to establish the real anatomic eJDS status and characterize it with certain measurements for proper implantation. If both, or only 1, of the measurements of eJDS are insufficient, it becomes necessary to determine the minimal values of eJDS width and height in order to ensure the primary stability of the implant. If the implant is stable, the missing amount of bone can be restored by various methods of jaw augmentation. When measurements of eJDS cannot ensure the primary stability of the implant, the same methods of augmentation are used initially with the intention to perform implantation at a later date. To be sure in the efficacy of our methods, we examined 374 patients and installed 792 screw-shaped Osteofix implants. The well-known techniques of orthopantomograms,

spiral CTs, and clinical examination with special ridge-mapping callipers for measurement of alveolar process widths were used to establish alveolar bone anatomy. All these methods are required to establish dimensions. Unanticipated supplementary surgical procedures such as GBR augmentation may be required, but they do inconvenience the patient.

According to the results of measurements, proper implantations were made at 476 (60.1%) implant sites for 232 (72.4%) Type I patients (96 men and 136 women). The results agreed with a past study that estimated that proper implantation was possible for 80% of the patients.<sup>15</sup> Implantation was most common in the regions of premolars and molars (Figure 4). The Type I patients were younger than those in the other groups.

The cervical threads were not completely covered in 14 cases in Type I patients. In 6 other cases, the lateral surfaces were dehiscient in the regions of the buccal concavities. It is also possible that bone width had been overestimated by improper use of the ridge-mapping callipers. Finally, we concluded that in all borderline cases that involved thread exposure, the small differences between ridge width and implant diameter (0.7 mm) had been re-



FIGURES 4–6. FIGURE 4. Implant locations in Type I (n indicates number of implants; M, molars; PM, premolars; C, canines; LI, lateral incisors; CI, central incisors). FIGURE 5. Implant locations in Type II (n indicates number of implants; M, molars; PM, premolars; C, canines; LI, lateral incisors; CI, central incisors). FIGURE 6. Implant locations in Type III (n indicates number of implants; M, molars; PM, premolars; C, canines; LI, lateral incisors; CI, central incisors).

sponsible for cervical exposure. The best results for implant placement were achieved with the following rule: eJDS width = dental implant diameter + 3 mm.

The alveolar processes were of insufficient height or width for implantation in the patients of the Type II group. When such deficiencies were present, augmentation of the jaws with immediate

implantation was performed. GBR was used to cover the implants and bone defects. The therapy used deproteinized bovine bone mineral, bioresorbable membrane, and resorbable pins.

Sinus floor augmentation with autologous bone or bone restitution with Bio-Oss were used in cases when the height of the alveolar process was insufficient

in the posterior maxilla. We noted that primary stability of the implants was achieved by sinus grafting with Bio-Oss in cases where the alveolar process were 4 to 5 mm in height. This finding met the opinion of some authors who have noted that the minimal height of the alveolar process for primary stability of an implant should be at least 4 mm.<sup>40</sup> In 2 cases, insufficient primary stability was reported when immediate implantation with sinus floor augmentation had been performed. In both cases, the alveolar process was 4 mm in height. In such cases, primary stability was realized when autogenous bone derived from the chin was used.

The number of men (48) and women (52) was almost equal in the Type II group. The mean age

TABLE 3

Simultaneous and later implantation for the patients of Type II group with different jaw augmentation methods\*

Group	Guided Bone Regeneration						Sinuslift				Total	
	Vertical		Horizontal		Vertical/horizontal		With Bio-Oss		With autobone		P	I
	P	I	P	I	P	I	P	I	P	I		
Type II	21	48	23	53	8	19	40	86	8	16	100	222

\*P indicates patients; I, implants.



was 45.8 years (SD = 13.4) years, which was higher than in the Type I group. Alveolar bone defects in the premolar and molar areas were noted, and implantation was performed at these sites with augmentation as they had been in the Type I population (Figure 5).

The patients of the Type III group had significant atrophy of the jaw, and primary stability of the implants could not be achieved. The number of women (30) in this group was larger than the number of men (12). The more frequently noted atrophy in the female jaws may be caused by physiological and endocrine factors.<sup>5,41</sup> The patients in this group were older than in the Type I and Type II groups; the mean age was 46.6 years (SD = 12.9). Guided bone regeneration and other jaw augmentation and reconstruction methods were performed before implant placements for all the patients in the Type III group.

Clinical and radiological investigation of the jaws and the benefits accrued from the surgery may be considered as clinical advantages of establishing the classifications cited in this article. We demonstrated that the selection of patients by using the system in this study led to successful implantation. Treatment strategy and collaboration among specialists would be facilitated by the uniform criteria of measurements as described herein.

#### CONCLUSION

The main anatomic characteristics that determine implant operative decisions are height, width, and length of eJDS in prospective site regions. In this study, 3 anatomic types of alveolar bone were shown to define some of the criteria governing implantation. Classifications for management

were derived for Types I, II, and III as interpreted by the anatomic characteristics classified as eJDS.

#### REFERENCES

1. Branemark P-I, Breine BE, Adell R, Hansson BO, Lindstrom J, Olsson A. Intraosseous anchorage of dental prostheses. I. Experimental studies. *Scand J Plast Reconstr Surg.* 1969;3:81-100.
2. Freiberg B, Jemt T, Lekholm U. Early failures in 4,641 consecutive placed Branemark dental implants: a study from stage 1 surgery to the connection of complete prostheses. *Int J Oral Maxillofac Implants.* 1991;6:142-416.
3. Naert I, Koutsikakis G, Quirynen M, Duyck J, van Stynberghe D, Jacobs R. Biologic outcome of implant-supported restorations in the treatment of partial edentulism. Part 2: a longitudinal radiographic evaluation. *Clin Oral Implants Res.* 2002;13:390-395.
4. Naert I, Koutsikakis G, Quirynen M, Duyck J, van Stynberghe D, Jacobs R. Biologic outcome of implant-supported restorations in the treatment of partial edentulism. Part 1: a longitudinal clinical evaluation. *Clin Oral Implants Res.* 2002;13:381-389.
5. Tallgren A. The continuing reduction of the residual ridges in complete denture wearers: a mixed-longitudinal study covering 25 years. *J Prosthet Dent.* 1972;27:120-132.
6. Buser D, Bragger U, Lang NP, Nyman S. Regeneration and enlargement of jaw bone using guided tissue regeneration. *Clin Oral Implants Res.* 1990;1:22-32.
7. Jovanovic S, Buser D. *Guided Bone Regeneration in Implant Dentistry.* 1st ed. Chicago, Ill: Quintessence; 1994:155.
8. Hardvick R, Scantlebury VT, Sanchez R, Whitely N, Ambruster J. *Guided Bone Regeneration in Implant Dentistry.* 1st ed. Chicago, Ill: Quintessence; 1994:101.
9. Huxeler MB, Strub JR. Guided bone regeneration around exposed implants: a new bioresorbable device and bioresorbable membrane pins. *Practical Periodontol Aesthetic Dent.* 1995;7:37-47.
10. Buser D, Dula K, Hirt HP, Schenk RK. Lateral ridge augmentation using autografts and barrier membranes: a clinical study with 40 partially edentulous patients. *J Oral Maxillofac Surg.* 1996;54:420-432.
11. Boyne PJ, James RA. Grafting of the maxillary sinus floor with autogenous marrow and bone. *J Oral Surg.* 1980;38:613-616.
12. Tatum H. Maxillary and sinus implant reconstructions. *Dent Clin North Am.* 1986;30:207-229.
13. Chanavaz M. Maxillary sinus: anatomy, physiology, surgery, and bone grafting related to implantology—eleven years of surgical experience (1979-1990). *J Oral Implant.* 1990;16:199-209.
14. Moy PK, Lundgren S, Holmes RE. Maxillary sinus augmentation: histomorphometric analysis of graft materials for maxillary sinus floor augmentation. *J Oral Maxillofac Surg.* 1993;51:857-862.
15. Piatelli M, Favero GA, Scarano A, Orsini G, Piatelli A. Bone reactions to anorganic bovine bone (Bio-Oss®) used in sinus augmentation procedures: a histologic long-term report of 20 cases in humans. *Int J Oral Maxillofac Implants.* 1999;14:835-840.
16. Yildimir M, Spiekerman H, Biesterfeld S, Edelhoff D. Maxillary sinus augmentation us-

- ing xenogenic bone substitute material Bio-Oss in combination with venous blood. *Clin Oral Implants Res.* 2000;11:217–229.
17. Peterson A, Lindh C, Carlsson L-E. Estimation of the possibility to treat the edentulous maxilla with osseointegrated implants. *Swed Dent J.* 1992;16:1–6.
18. Oikarinen K, Raustia AM, Hartikainen M. General and local contraindications for endosseal implants—an epidemiological orthopantomogram study in 65-year-old subjects. *Community Dent Oral Epidemiol.* 1995;23:114–118.
19. Mercier P, Lafontant R. Residual alveolar ridge atrophy: classification and influence of facial morphology. *J Prosthet Dent.* 1979;41:90–100.
20. Seibert JS. Reconstruction of deformed, partially edentulous ridges, using full thickness onlay grafts. Part I. Technique and wound healing. *Compendium Continuing Educ Dent.* 1983;4:437–453.
21. Allen EP, Gainza CS, Farthing GG, Newbold DA. Improved technique for localized ridge augmentation. A report of 21 Cases. *J Periodontol.* 1985;56:195–199.
22. Cawood JI, Howell RA. A classification of the edentulous jaws. *Int J Oral Maxillofac Surg.* 1991;17:232–236.
23. Eufinger H, Gellrich NC, Sandmann D, Dieckmann J. Descriptive and metric classification of jaw atrophy. *Int J Oral Maxillofac Surg.* 1997;26:23–28.
24. Meyer U, Vollmer D, Runte C, Bourauel C, Joos U. Bone loading pattern around implants in average and atrophic edentulous maxillae: a finite element analysis. *J Craniomaxillofac Surg.* 2001;29:100–112.
25. Lekholm U, Zarb GA. *Tissue-Integrated Prosthesis: Osseointegration in Clinical Dentistry.* 3rd ed. Chicago, Ill: Quintessence; 1985:199.
26. Jensen O. Site classification for the osseointegrated implant. *J Prosthet Dent.* 1989;61:228–234.
27. Misch CE. Divisions of available bone in implant dentistry. *Int J Oral Implantol.* 1990;7:9–17.
28. Ganz SD. What is the most important aspect of implant dentistry? *Implant Soc Inc.* 1994;5:2–4.
29. Wilson DJ. Ridge mapping for determination of alveolar ridge width. *Int J Oral Maxillofac Implants.* 1989;4:41–43.
30. Allen F, Smith DG. An assessment of the accuracy of ridge mapping in planning implant therapy for the anterior maxilla. *Clin Oral Implant Res.* 2000;11:34–38.
31. Rosenquist B, Ahmed M. The immediate replacement of teeth by dental implants using homologous bone membranes to seal the sockets: clinical and radiographic findings. *Clin Oral Implant Res.* 2000;11:572–582.
32. Dula K, Mini R, van der Stelt PF, Buser D. The radiographic assessment of implant patients: decision making criteria. *Int J Oral Maxillofac Implants.* 2000;16:80–90.
33. Nomura T, Shingaki S, Nakajima T. Current evaluation of dental implants: a review of the literature. *J Long Term Effects Med Implants.* 1998;8:175–192.
34. Hobo S, Ichida E, Garcia LT. *Osseointegration and Occlusal Rehabilitation.* 1st ed. Chicago, Ill: Quintessence; 1989:55.
35. Bauman GR, Mills M, Rapley JW, Hallmon WH. Clinical parameters of evaluation during implant maintenance. *Int J Oral Maxillofac Implants.* 1992;7:220–227.
36. Adell R, Lekholm U, Rockler B, Branemark P-I. A 15-year study of osseointegrated implants in the treatment of the edentulous jaw. *Int J Oral Surg.* 1981;10:387–416.
37. Palacci P, Ericsson I, Engstrand P. *Optimal Implant Positioning and Soft Tissue Management for the Branemark System.* 1st ed. Chicago, Ill: Quintessence; 1995:41.
38. Davarpanah M, Martinez H, Tecucianu JF, Celletti R, Lazara R. Small-diameter implants: indications and contraindications. *J Aesthetic Dent.* 2000;12:186–194.
39. Aparicio C, Orozco P. Use of 5-mm-diameter implants: periosteal values related to a clinical and radiographic evaluation. *Clin Oral Implants Res.* 1998;9:398–406.
40. Watzek G. *Endosseous Implants: Scientific and Clinical Aspects.* 1st ed. Chicago, Ill: Quintessence; 1996:29.
41. Kribbs PJ, Chesnut CH, Ott SM, Kilcoyne RF. Relationship between mandibular and skeletal bone in an osteoporotic population. *J Prosthet Dent.* 1989;62:703–707.