

EDITOR'S NOTE: As of the printing date of this publication, the Ankylos SynCone and Cercon abutments were not yet approved for use in the United States. Ankylos implants are approved for single stage surgical placement and immediate loading in the United States, but immediate loading is restricted to the anterior mandible, based on 4 intraforaminal placed implants, and is not indicated for single, unsplinted implants.

# FUNCTIONAL AND ESTHETIC CONSIDERATIONS FOR SINGLE-TOOTH ANKYLOS IMPLANT-CROWNS: 8 YEARS OF CLINICAL PERFORMANCE

Katrin Döring, DMD  
Eduard Eisenmann, DMD  
Michael Stiller, DMD, MD

## KEY WORDS

Osseointegration  
Single-tooth implants  
Esthetic implant restorations  
New implant design

*Katrin Döring, DMD, and Eduard Eisenmann, DMD, are at the Department of Restorative Dentistry and Michael Stiller, DMD, MD, is at the Clinic for Maxillofacial Surgery, Department of Oral Surgery, University Hospital Benjamin Franklin, Free University of Berlin, Assmannshauer Str. 4-6, 14197 Berlin, Germany.*

**Problem:** Following the loss of an anterior natural tooth, the mucogingival complex begins to collapse. The early placement of endosseous dental implants can prevent or reduce the extent of this collapse. If there is a long interval between the loss of the natural tooth and the placement of the implant prosthetic replacement, this collapse tends to increase significantly. **Purpose:** This paper will report on the clinical success of this implant product in the fabrication of esthetic, functional, and harmonious replacements for missing single, natural teeth for a period of 8 years. **Method:** A total of 275 single Ankylos implant tooth restorations in the anterior and posterior jaw regions were placed and monitored for 8 years. Of these, 264 implants were restored using the titanium Balance abutments, and only 11 were restored using ceramic abutments. The final restorations were either metal-ceramic or full-ceramic crowns and were cemented with glass ionomer cement. **Results:** The survival rate was 98.2%, with only 5 implants being lost during the healing phase. There were no other implant losses in the postloading period that averaged 3.2 years. To date, there have been no mechanical complications associated with the prosthetic components (ie, screw loosening, screw breaking, or crown breaking) for either the titanium or the ceramic abutments. **Conclusions:** Experience with the Ankylos system with single-tooth replacement indications may be considered positive with regard to the esthetic and functional results of the treatment. The lack of mechanical complications and problems with the hard and soft tissue in the loading phase of the implants suggests the functional safety of the tapered connection between implant and abutment.

## INTRODUCTION

**T**he loss of a single tooth in the anterior region of the maxilla represents a particularly difficult clinical situation for the placement of a single-implant restoration that is both esthetically and functionally acceptable. The success of the single-implant restoration depends not only on restoring clinical function, but also on integrating the restoration harmoniously into the patient's overall appearance. The loss of a natural tooth is often followed by the collapse of the hard and soft tissues that make up the mucogingival complex. This results in hard and soft tissue relationships that are rarely favorable for the insertion of a single-implant restoration.

The esthetics associated with the final implant restoration are greatly affected by both the shrinkage of the adjacent interdental papillae and the loss of the scalloped tissue contour around the implant restoration. These structures are very important to the esthetics of the final restoration because of the visibility of the mucogingival complex during laughter.<sup>1</sup> The shape, color, and surface structure of any replacement for missing natural teeth must be optimal. The extensive loss of supporting tissue contours may require grafting of the hard and/or soft tissue in order to achieve a restoration that is symmetric and harmonious with its neighboring teeth and the contralateral tooth.<sup>2</sup> The immediate placement of implants has gained considerable popularity in recent years because this procedure preserves the height and volume relationships of bone structure.<sup>3-5</sup>

In actual clinical cases, however, esthetic and functional restora-

tions are difficult to implement successfully without endangering the success of the final implant restoration. This is especially true if tissue atrophy is well advanced.

In spite of the excellent survival rate of 97.2% during a period of 6 years for single-implant restorations that has been reported by Lindh et al,<sup>6</sup> the success of the implant restoration should be measured not only by the survival rate but also by how well it has satisfied the success criteria that are internationally accepted.<sup>7</sup> These widely accepted criteria include data related to the degree of change in the peri-implant bone level during a specific period<sup>8</sup> and data related to patient satisfaction.<sup>9,10</sup> Patient satisfaction with any dental procedure is a major consideration in dentistry. This is particularly true when the implant restoration is located in the frontal (anterior) region.<sup>11,12</sup>

The literature contains numerous reports of complications that have been associated with the prosthetic components of various implant systems during the loading phase. These complications can have a negative influence on the patient's comfort<sup>13</sup> and appearance. The potential for such problems should always be considered when planning implant treatment and when selecting an implant system. Complications associated with implants frequently involve abutments that become loose from the implant<sup>14-18</sup> or crowns that become detached because of the loosening or breakage of the retaining screws.<sup>19</sup> These complications can be as high as 43% after only 3 years<sup>20</sup> of clinical function. Soft tissue problems such as the formation of fistulas are also possible.<sup>21-23</sup>

Technical and prosthetic complications have been related to

designs of different implants and abutments.<sup>24</sup> From a biomechanical point of view, the major difference in implant systems available to dentists today is the type of implant-abutment connection used. Mechanical failures—such as the loosening or breakage of occlusal screws for the screw-retained restorations, abutment screws, or abutments—are directly related to the type of implant-abutment connection.<sup>25</sup> Precisely machined, internal-tapered implant-abutment connections have been reported to provide more mechanical stability than either the external hex connections or butt-joint designs. The precision-fit tapered abutment-implant connection of the Ankylos implant has been shown to provide better short-term and long-term clinical performance.<sup>26-29</sup>

At the Free University of Berlin, the authors have been using the Ankylos implant system (Friadent GmbH, Mannheim, Germany) for single-tooth replacements since 1995. It has provided highly functional restorations that are esthetically and functionally very similar to the natural tooth when a strict clinical procedure is carefully followed. The procedure is based on system-specific features of the Ankylos implant (ie, the progressive thread design of the implant [Figure 1], the internal-tapered connection between the implant and abutment, and the reduced sulcus emergence region of the abutment [Figures 2 and 3] with its special shape<sup>30</sup>). The procedure described in this paper makes it possible to achieve optimal treatment results while restoring a high level of esthetics and clinical function for missing single, natural teeth using implant restorations. This is based on successful outcomes that have




FIGURE 1. The new Ankylos implant design. The innovative features of this implant include a progressive thread design, a surface that is slightly roughened, and a coronal portion that is machined and does not have threads; this directs the functional stresses away from the crestal bone and onto the trabecular bone. Trabecular bone is more resilient and resists damage due to repetitive microstains and, if damaged, repairs more rapidly than crestal bone.

been documented for 275 single-tooth implants in the anterior and posterior jaw regions during a period of 8 years.

**PROSTHETIC AND SURGICAL CONSIDERATIONS**

The following points must be carefully considered in order to achieve maximum esthetics and function for single-implant tooth restorations: (1) every case must be precisely diagnosed and the treatment procedures planned; (2) tissue deficits must be analyzed before placement of the implant, and these deficits must be satisfactorily corrected—using hard or soft tissue grafts, if necessary; (3) the implant must be inserted in the correct position



FIGURE 2. Precision-machined, internal-tapered abutment connection (Morse Taper) provides effective “anti-rotation” and eliminates micromovement during clinical function. The precise fit of this connection eliminates the microgap found in most 2-stage implant systems as well as food debris and bacteria that are often found in this microgap. Bacteria and micromovement are believed to be associated with crestal bone loss.

to allow the fabrication of an esthetic and functional single-tooth implant restoration; (4) the implant components must be mechanically stable and biocompatible; and (5) the abutments must be anatomically shaped to allow a customized design for each specific clinical situation so that a natural emergence profile for the crown can be formed within the peri-implant soft tissue.

**SPECIAL SURGICAL AND PROSTHETIC ASPECTS FOR SINGLE-TOOTH RESTORATIONS USING THE ANKYLOS IMPLANT SYSTEM**

The spatial position of an implant is determined by the angulation, inclination, and depth that the implant is placed in the crestal bone when compared with the adjacent natural teeth. A wax

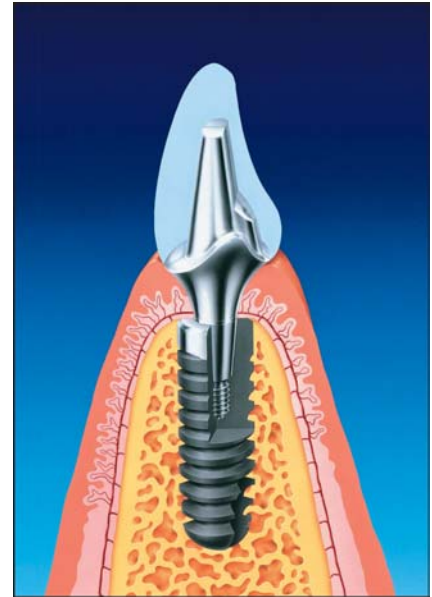


FIGURE 3. Schematic drawing of the Ankylos implant and its relationship to the hard and soft supporting tissues. Note: The narrow tapered design of the implant abutment from the crown restoration to the integrated implant body—this allows a dense layer of soft tissue to form around the neck of the abutment. This dense tissue prevents food debris from accumulating in this region, and it eliminates the “gray discoloration” in the cervical region that is common with other abutment designs.

reproduction of the missing tooth and a surgical guide (stent) can help define the final position of the single-implant restoration, from both an esthetic and functional point of view (Figure 4A).

Vertically, the Ankylos implant must be positioned with reference to system-specific requirements of the internal-tapered connection between the implant and the abutment. Because the emergence area of the shoulder region of the Ankylos implant is considerably less than that in other implant systems (Figure 3) that use conventional implant-abutment connections, the shoulder is positioned 1.5 to 2 mm deeper into the bone to produce an optimal emergence profile. The cemento-enamel junction of the neighboring teeth

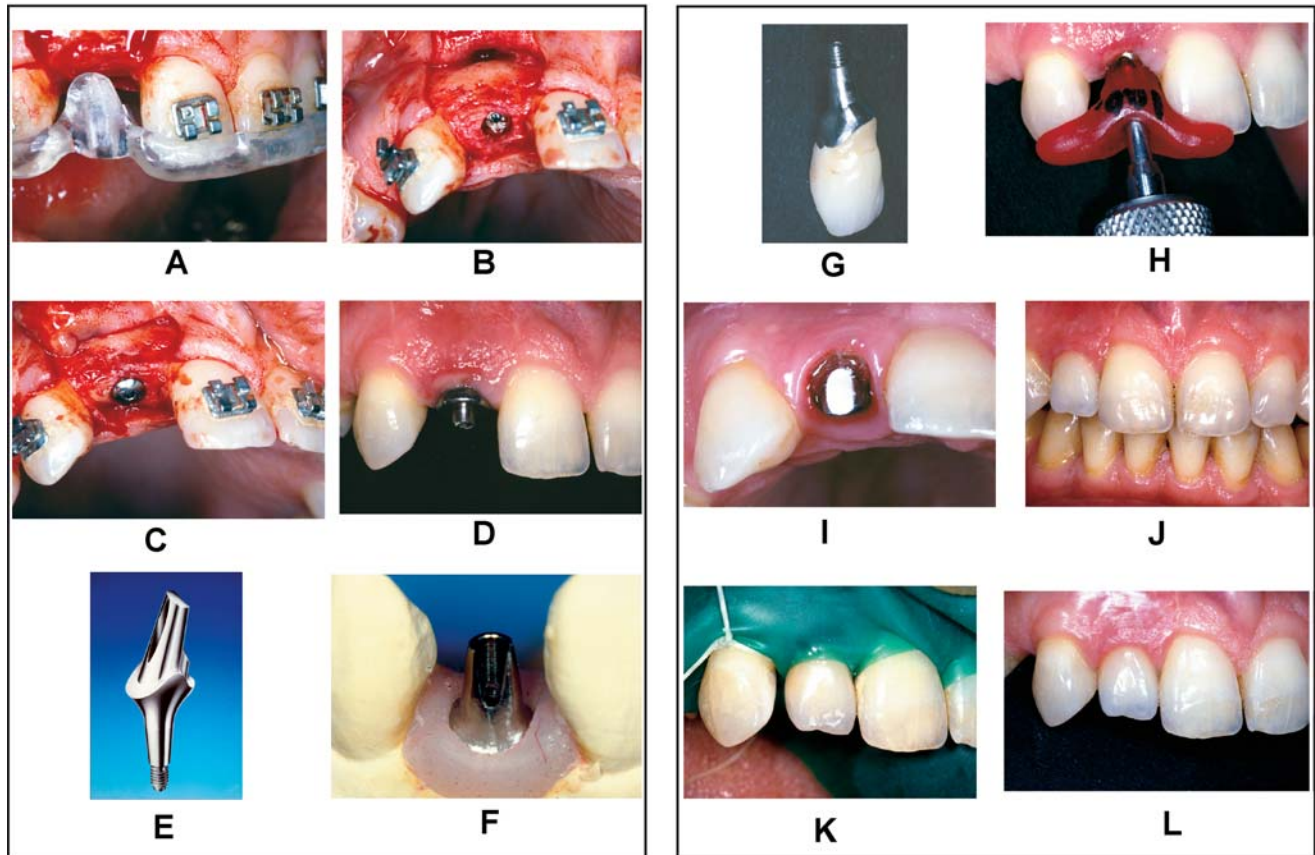


FIGURE 4. (A) Surgical stent aids in the correct positioning of the implant. (B) The implant is placed slightly below the crestal bone level. (C) A sulcus former can be placed and used to support any augmentation materials. (D) A larger sulcus former is in place, following uncovering, to establish the emergence profile within the soft tissue. (E) "Balance Anterior Abutment." The thin neck of the abutment and the preformed margin can be modified for custom crowns. (F) Customized balance abutment modified on laboratory cast so that final restoration provides a harmonious relationship with natural teeth. (G) Precise fit of crown on customized Balance abutment. (H) Relationship of customized abutment and crown to be transferred to mouth with customized transfer stent (key). Transfer stent is made of self-curing acrylic resin. (I) Balance abutment has been seated in implant. (J) The final esthetic crown is cemented to the customized Balance abutment. (K) Excessively wide space evident between natural right cuspid (tooth #6) and implant-supported crown (#7). (L) Adhesive composite material is applied to the mesial surface to eliminate the gap; note the natural esthetics and healthy tissue around restoration and the interdental papillae.

provides an important point of reference for implant placement. When planning the depth for implant placement, the diameter of the single-tooth restoration in the area of the mucous membrane emergence region should be compared to the cross section of the width of the implant shoulder area. Large discrepancies between these 2 fixed quantities could result in an unfavorable mucous membrane emergence profile and create a problem maintaining oral hygiene. It may, therefore, be advisable to insert the implant somewhat deeper to

avoid a steep ascent angle. Because of the density of the internal-tapered connection,<sup>31</sup> there is also the option of grafting bone over the top of the Ankylos implant shoulder (Figure 3) to provide increased support and stability to the implant. This is not possible with other conventional 2-stage implant systems.

The crestal bone in the region of the implant shoulder generally remains in place during the functional loading phase or may even increase in density, as confirmed by various reproducible X-ray exposures. Therefore, the

Ankylos implant can be set slightly deeper into the bone, or bone can be grafted above the level of the implant shoulder to achieve an esthetically favorable ascent (emergence) profile (Figure 4B). A sulcus former can be inserted during implant placement and used as support for the grafted material (Figure 4C). When the implant is uncovered, the sulcus former, used to stabilize the grafted bone, can be replaced with another sulcus former that is customized for the specific esthetic situation (Figure 4D).

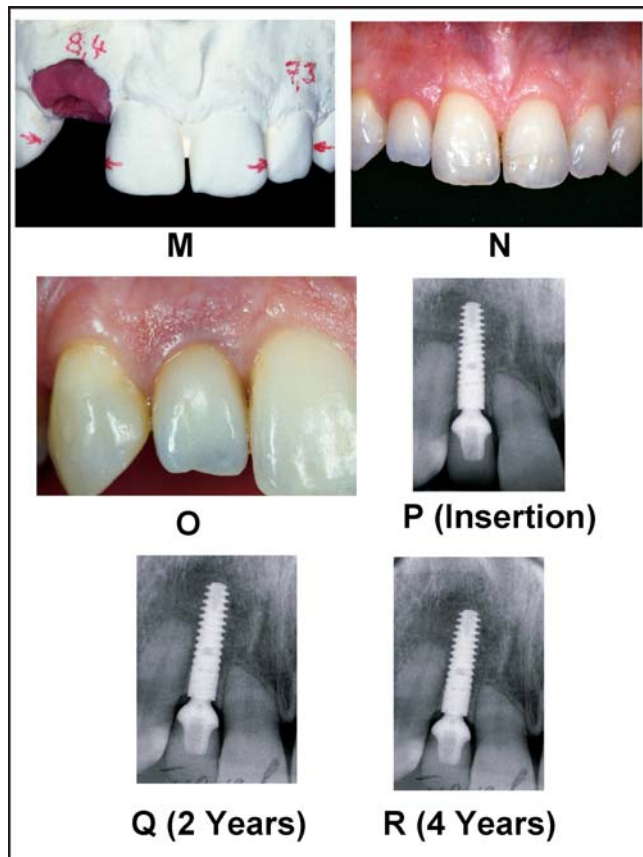


FIGURE 4. (cont.) (M) Lack of symmetry is evident on study cast. (N) Esthetic and functional restoration blends well with natural teeth. (O) A close-up view of implant restoration (tooth #7) demonstrating excellent esthetics. (P) Crestal bone level at time of insertion of final restoration. (Q) Crestal bone level after 2 years of clinical function: note that crestal bone level does not show any loss. (R) Crestal bone level after 4 years of clinical function: note that crestal bone level does not show any reduction in height.

The complete removal of the dense tissue over the Ankylos implant shoulder is not required to connect the abutment. Using a tissue punch, a small amount of soft tissue is removed to provide access to the narrow covering screw that protects the internal opening for the tapered abutment connection within the implant. The uncovering of the Ankylos implant is a very simple procedure because of its internal conical abutment connection and abutment connections. Following the removal of the soft tissue that protects the internal conical abutment threads with the tissue punch, the cover screw is removed, and a tapered sulcus former (tapered healing abut-

ment) is screwed into place (Figure 4B and C). Following the healing and removal of the sulcus former, there is a small opening in the dense soft tissue collar surrounding the sulcus region (Figure 5E). This dense soft tissue layer serves to protect the underlying peri-implant bone (Figures 3 and 5E) when the final prosthetic abutments are connected at a later appointment.

In the frontal (anterior) maxillary region, the incision for the uncovering should be made slightly palatal (lingual) to achieve a labial soft tissue overlap, which provides an improved ascent profile for the final restoration. If necessary, this labial soft tissue can be contoured step by

step for a garlandlike gingival contour. Reduced-diameter sulcus formers are used initially to shape the peri-implant soft tissue (Figures 5A through E and 6A). After about 5 days, the reduced-diameter sulcus formers can be replaced with sulcus formers of a larger diameter to match the thickness of the mucous membrane. The formers can be replaced several times, if needed, depending on the clinical situation, to form an emergence profile within the soft tissues. The sulcus formers provide tissue support and apply pressure to the soft tissues to contour a scalloped soft tissue seam (Figure 5C and D). Laser techniques, electrosurgical techniques, or diamonds can be used for fine shaping the buccal soft tissue (Figure 6A and B) for a more esthetically acceptable tissue form. This step-by-step procedure for soft tissue treatment enables optimum shaping of the soft tissue contours (Figure 5F) so that a temporary crown and second abutment are frequently unnecessary (Figure 5G and H).

Once the peri-implant tissues have stabilized, their contour and the precise location and orientation of the implant can be transferred to a master laboratory working cast using a "pick-up impression." The coping (abutment) selection in the dental laboratory is strictly based on the anatomic requirements for the final crown restoration, since the tapered implant-abutment connection for the Ankylos implant system is identical for all implants and abutments. This allows the appropriate abutment size to be selected regardless of the diameter of the implant placed.

The innovative "Balance Anterior Abutments" are specifically designed for use in the restora-

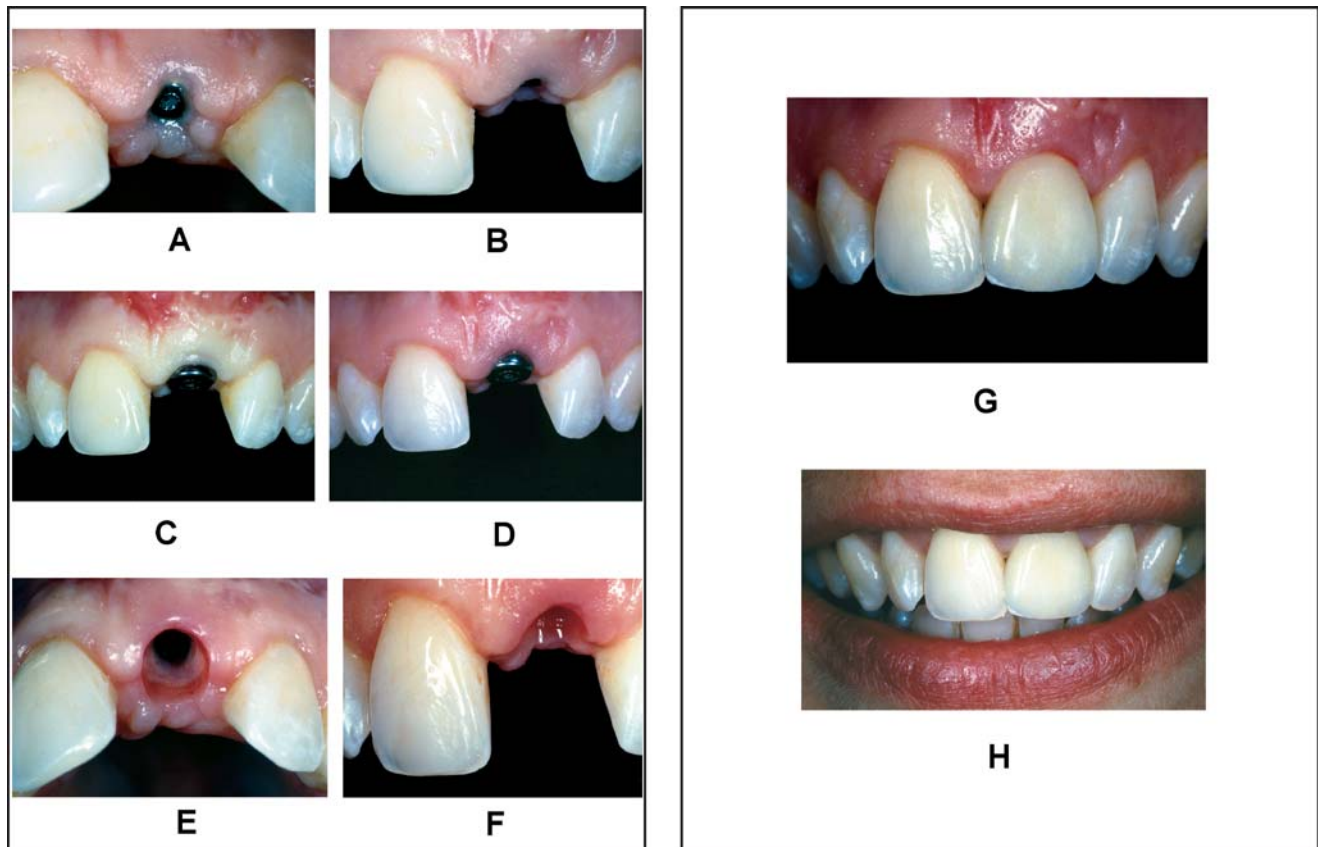


FIGURE 5. (A) Small sulcus former (incisal view). (B) Small sulcus former (frontal view). (C) Pressure shaping of emergence profile within soft tissue with large sulcus former: note blanching of tissue. (D) Shaping of tissue margin: note healthy tissue color. (E) Emergence profile formed within soft tissue: note that thick dense tissue covers the coronal portion (shoulder) of implant. (F) Healthy, well-formed soft tissue following removal of sulcus former. (G) Esthetic crown cemented on abutment. (H) Final esthetic crown closely follows the patient's "smile line."

tion of anterior (front) teeth. They are fabricated using either titanium (Figure 4E) or zirconium-oxide (Figure 6C through E) and have the following unique features: (1) their shape corresponds to that of a natural tooth that has been prepared for an esthetic crown restoration, (2) the abutment shoulder conforms to the natural gingival contour, (3) a 1-mm-wide chamfer allows the fabrication of an esthetic crown design, (4) the reduced sulcus region aids in the formation of a healthy, dense gingival collar around the small diameter of the abutment, which provides protection for the underlying bone, and (5) the balance abutments can be easily customized by grinding to make it possible to fabricate

an esthetic and functional final restoration that harmoniously blends with the remaining natural teeth for each clinical case (Figure 4F).

The thickness of the mucous membrane, the axial inclination of the implant, and the cervical crown diameter must all be considered when selecting the abutment to be customized. The superstructure of the final restoration is fabricated on the customized abutment. The final esthetic crown can be formed very precisely to the abutment to maximize esthetics and function (Figure 4G). The tapered abutment connection allows the abutment coping to be rotated and positioned on the implant to obtain the best position. A cus-

tomized transfer key (index) must therefore be fabricated to facilitate the accurate transfer of the relationships between the new implant restoration and the remaining teeth, from the working laboratory cast to the mouth (Figure 4H). The index can be fabricated from self-curing resin (Pattern Resin, GC, Tokyo, Japan). The exact procedure has been described by the authors in a previous publication.<sup>32</sup> After installation of the abutment with a torque of 15 Ncm, the crown is initially cemented in place with provisional cement and is then permanently cemented at a later date (Figure 4I and J). If esthetics are required to be improved further, some localized shaping of neighboring teeth with abra-

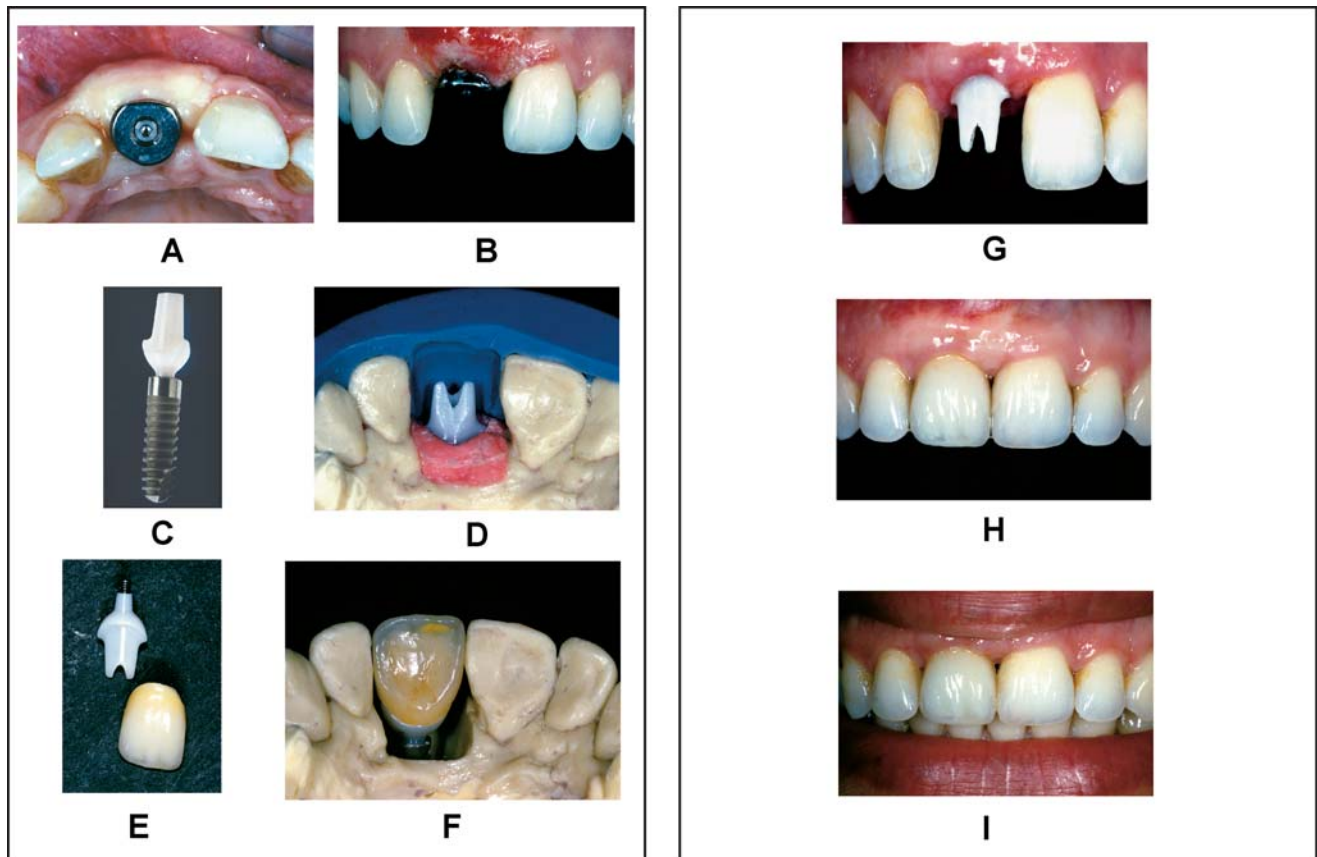


FIGURE 6. (A) Implant following uncovering; note sulcus former. (B) The soft tissues have been shaped to provide natural contours. (C) Ankylos implant with the Cercon ceramic abutment. (D) Cercon abutment has been customized on laboratory cast. (E) Cercon abutment with full-ceramic crown. (F) Esthetic ceramic crown: note the emergence profile from shoulder of implant analog. (G) Cercon abutment in place (tooth #8). (H) Cemented final crown. (I) Patient's high smile line: note healthy soft tissue around implant-crown restoration.

sive instruments and adhesive restorative materials can be performed in conjunction with the actual crown restoration. This improves the contour to compensate for gap asymmetries and to support the papillae (Figure 4K through O).

Conventional metal abutments often produce a blue-gray shadowing effect in the cervical region of the restoration, which can be visible in patients with very thin soft tissue. An important prosthetic option of the Ankylos implant system is the addition of a full-ceramic abutment for anterior teeth—the Cercon abutment made of zirconium oxide (Y-TZP) (Figure 6C through E). This esthetic option makes it

possible to improve the esthetic color of final ceramic crowns and the esthetic appearance of the surrounding healthy gingival tissues. The white coloring of the Cercon zirconium oxide abutments eliminates this blue-gray coloring and makes it possible to improve the esthetic natural tooth appearance of the final ceramic crown restoration. A full-ceramic crown with the Cercon ceramic abutment system provides natural translucence, which is impossible with metallic structures. While the Cercon abutment has excellent optical properties, it also has high mechanical strength. The bending resistance and fracture toughness values are significantly higher than those of

aluminum oxide ceramics.<sup>33</sup> Cercon abutments can also be customized and are manufactured with the same precisely tapered abutment connection as that found in the titanium abutment. In addition to its excellent biocompatibility, the zirconium ceramic abutment does not promote bacterial accumulation when compared to titanium abutments<sup>34</sup> (Figure 6C through I).

## RESULTS

A total of 275 single Ankylos implant tooth restorations in the anterior and posterior jaw regions were placed and monitored for 8 years. Of these, 264 implants were

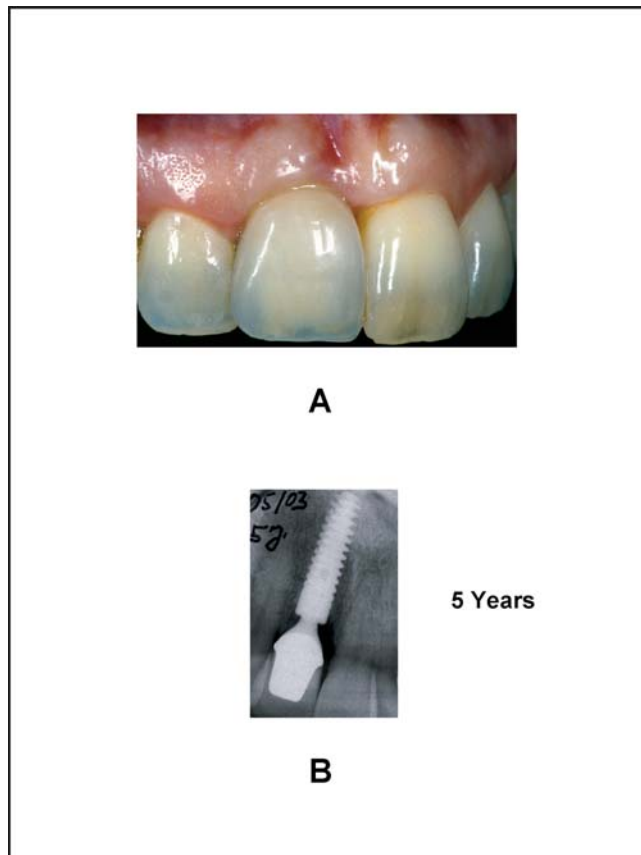


FIGURE 7. (A) Implant restoration (tooth #8): note the healthy tissue and contours around implant restoration. (B) Implant restoration after 5 years of clinical function: note that there is no detectable loss of crestal bone surrounding implant restoration.

restored using the titanium Balance abutments, and only 11 were restored using ceramic abutments. The final restorations were either metal-ceramic or full-ceramic crowns and were cemented with glass ionomer cement. The survival rate was 98.2%, with only 5 implants being lost during the healing phase. There were no other implant losses in the post-loading period that averaged 3.2 years. To date, there have been no mechanical complications associated with the prosthetic components (ie, screw loosening, screw breaking, or crown breaking) for either the titanium or the ceramic abutments. Two Procera crowns on posterior dental implants were replaced because the ceramic material had been chipped.

The peri-implant soft tissues were extremely stable, with no evidence of fistulas, recession, or infections. A slight increase in the height of the papillae was seen; however, no sign of clinical inflammation was observed. In one prospective and one retrospective study, no measurable losses of crestal bone were recorded during the functional prosthetic period for a total of 72 single-tooth implants, either in the anterior or posterior region for this type of restoration. In our study, in 50% of the cases, X-ray examination after 1 year of prosthetic loading showed crestal bone at or slightly above the level of the implant shoulder. 8 years of scientific data (Figures 4P through R, 7A and B, and 8A through C) confirm the clinical performance and

crestal bone changes observed by the authors in this study. Patient satisfaction with the esthetics and comfort of the single-implant restorations that were performed ranged from “good” to “excellent.”

## DISCUSSION

In agreement with previous general experience with single-tooth implants,<sup>6</sup> the authors were able to achieve a success rate of 98.2% with the Ankylos implant system after 8 years of use and an average observation period of 38 months. The literature describes some general mechanical complications that exist during the functional loading phase for other implant systems with butt-joint connections (eg, the frequent loosening of abutments or abutment-retaining screws).<sup>15-17,19</sup> Our experience with the Ankylos implant system is in contrast to this, and we did not experience these problems in our patient group. Soft tissue complications such as fistulas,<sup>14,35</sup> which often coexist with loosening problems, were not observed in the clinical study database. Our data indicated that the loosening or breakage of Ankylos prosthetic components is not a problem with implant-supported restorations. Such complications are described in the literature but are associated with other implant designs that feature different diameters of implants and abutments. This appears to be particularly true with molar replacements.<sup>15</sup>

Our results with the Ankylos system show that mechanical complications with single-tooth implants can be prevented, even in the molar region. This agrees with the retrospective study by Romanos and Nentwig<sup>29</sup> on single-tooth restoration of molars with this system, although the



occlusal loading for molar teeth is significantly higher than the loading of the anterior teeth. The authors did not observe an increase in mechanical problems in the posterior jaw region with single-tooth implants as described by Jemt et al,<sup>14</sup> Rangert et al,<sup>36</sup> and others. This appears to be related to specific implant systems and certain features of their design—particularly the implant-abutment connection.<sup>24,25</sup> The Balance abutments of the Ankylos system require a torque of only 15 Ncm to establish a secure implant-abutment connection, while the retaining screws of implants with butt-joint connections must be fastened with more than double this force. The high mechanical stability of the internal-tapered connection allows the cementation of the superstructure (crown or bridge) without a risk of the abutment loosening or the screw breaking. This makes fabrication of the final restoration easier and the superstructure more esthetic and economical. Compared to the use of retaining screws for restorations, cementation has fewer complications,<sup>37,38</sup> since the detachment of crowns by a loosening or breakage of the retaining screws is nonexistent. Levine et al<sup>20</sup> reported that this eliminated 22% of the complications found during a multicenter clinical study.

There is a commonly accepted perception that the peri-implant bone response is very similar to the response found around natural teeth that have been restored with crowns or bridges. The mucogingival complex tends to adapt to functional stress by establishing a biologic width of about 2 mm below the junction of the implant and abutment.<sup>39</sup> An inflammatory infiltration of 0.6 mm in the apical and coronal direction has regularly been

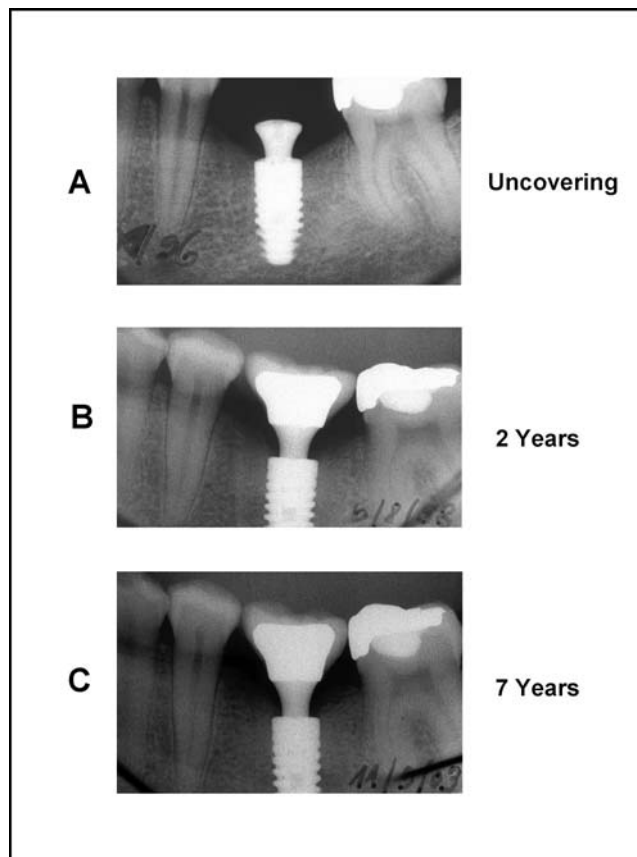


FIGURE 8. (A) Bone response to mandibular posterior molar Ankylos implant-crown at time of uncovering. (B) Bone response, 2 years postinsertion of crown. (C) Bone response 7 years, postinsertion of crown. Crestal bone has remained at the same level at all stages of implant treatment.

found around the gap between the abutment and the implant when conventional implant systems with an internal or external hex connection have been used. A 1- to 1.5-mm-wide zone of connective tissue that is not affected by inflammation separates the apical section of the infiltrate from the bone. This response has been considered a cost to the host in order to repel bacteria or is explained as the cost of establishing the so-called biologic width.<sup>40-42</sup> Hämmerle et al<sup>43</sup> has reported that when an ITI implant is placed below the normal crestal bone level, the bone atrophy after 1 year of loading is twice as high as when conventionally inserted implants of this system are used. Our experience

with the Ankylos system is in direct contrast to this data. After 1 year of loading, the crestal bone height was frequently found at the height of the implant shoulder or even slightly higher. For Ankylos implants that were inserted more deeply into the bone, crestal bone was often deposited above the shoulder of the implant. In agreement with the literature,<sup>44,45</sup> the absence of crestal bone atrophy during the first year after functional loading of the Ankylos implant can be explained by the lack of an external microgap between the abutment and the implant.

Placement of the Ankylos implant deeper into the bone does not necessarily result in complications of the hard and soft tissue,

as is frequently assumed.<sup>43,46</sup> In addition to the positive effects of a favorable load transmission to the bone via the special thread of the Ankylos implant<sup>29,30,47</sup> and a stable internal-tapered abutment connection, the lack of complications can be attributed to the thick deposition of soft tissue in the narrowed neck of the abutment. This collar of soft tissue, which appears wedge shaped in cross section, seems to provide a supplementary protective function for the peri-implant bone.<sup>48,49</sup>

### CONCLUSION

Experience with the Ankylos system with single-tooth replacement indications may be considered positive with regard to the esthetic and functional results of the treatment. The lack of mechanical complications and problems with the hard and soft tissue in the loading phase of the implants suggests the functional safety of the tapered connection between implant and abutment.

### ACKNOWLEDGMENT

The authors thank Michael Krause, master dental technician (Dentallabor Krause, Berlin), for carrying out the dental technical work.

### REFERENCES

1. Studer S, Naef R, Schärer P. Die Korrektur des lokalen Alveolarkammdefekts mittels Weichgewebetransplantation zur Verbesserung der mucogingivalen Ästhetik. *Parodontologie*. 1996; 3:187–212.
2. Phillips K, Kois JC. Aesthetic periimplant site development. *Dent Clin North Am*. 1998;42:57–69.
3. Lazzara RJ. Immediate implant placement into extraction sites: surgical and restorative advantages. *Int J Periodont Restorative Dent*. 1989;9:332–343.
4. Werbitt MJ, Goldberg PV. The immediate implant: bone preservation and bone regeneration. *Int J Periodont Restorative Dent*. 1992;12:206–217.
5. Ericsson I, Nilson H, Lindh T, Nilner K, Randow K. Immediate functional loading of Branemark single tooth implants. An 18 months' clinical pilot follow-up study. *Clin Oral Implants Res*. 2000;11:26–33.
6. Lindh T, Gunne I, Tillberg A. A meta-analysis of implants in partial edentulism. *Clin Oral Implants Res*. 1998;9:80–90.
7. Albrektsson T, Zarb GA, Worthington P. The long-term efficacy of currently used dental implants: a review and proposed criteria of success. *Int J Oral Maxillofac Implants*. 1986;1:11–25.
8. Norton MR. Marginal bone levels at single tooth implants with a conical fixture design. The influence of surface macro- and microstructure. *Clin Oral Implants Res*. 1998;9:91–99.
9. Smith DE, Zarb GA. Criteria for success of osseointegrated endosseous implants. *J Prosthet Dent*. 1989;62:567–572.
10. Zarb GA, Albrektsson T. Towards optimized treatment outcomes for dental implants. *J Prosthet Dent*. 1998;80:639–640.
11. Carlson B, Carlsson GE. Prosthodontic complications in osseointegrated dental implant treatment. *Int J Oral Maxillofac Implants*. 1994;9:90–94.
12. Carr AB, McGivney GP. Measurement in dentistry. *J Prosthet Dent*. 2000;83:266–271.
13. Levi A, Psoter WI, Agar IR, Reisine ST, Taylor TD. Patient self-reported satisfaction with maxillary anterior dental implant treatment. *Int J Oral Maxillofac Implants*. 2003;18:113–120.
14. Jemt T, Laney WR, Harris D, et al. Osseointegrated implants for single tooth replacement: a 1-year report from a multicenter prospective study. *Int J Oral Maxillofac Implants*. 1991;6:29–36.
15. Becker W, Becker BE. Replacement of maxillary and mandibular molars with single endosseous implant restorations: a retrospective study. *J Prosthet Dent*. 1995;74:51–55.
16. Engquist B, Nilson H, Astrand P. Single-tooth replacement by osseointegrated Branemark implants. A retrospective study of 82 implants. *Clin Oral Implants Res*. 1995;6:238–245.
17. Lazzara R, Siddiqui AA, Binon P, et al. Retrospective multicenter analysis of 3i endosseous dental implants placed over a five-year period. *Clin Oral Implants Res*. 1996;7:73–83.
18. Scheller H, Urgell JP, Kultje C, et al. A 5-year multicenter study on implant-supported single crown restorations. *Int J Oral Maxillofac Implants*. 1998;13:212–218.
19. Levine RA, Clem D, Beagle J, et al. Multicenter retrospective analysis of the ITI implant system used for single-tooth replacements: results of loading for 2 or more years. *Int J Oral Maxillofac Implants*. 1999; 14:516–520.
20. Ekfeldt A, Carlsson GE, Borjesson G. Clinical evaluation of single-tooth restorations supported by osseointegrated implants: a retrospective study. *Int J Oral Maxillofac Implants*. 1994; 9:179–183.
21. Jemt T, Pettersson P. A 3-year follow-up study on single implant treatment. *J Dent*. 1993; 21:203–208.
22. Henry PJ, Rosenberg IR, Bills IG, et al. Osseointegrated

- implants for single tooth replacement in general practice: a 1-year report from a multicentre prospective study. *Aust Dent J*. 1995;40:173–181.
23. Avivi-Arber L, Zarb GA. Clinical effectiveness of implant-supported single-tooth replacement: the Toronto Study. *Int J Oral Maxillofac Implants*. 1996;11:311–321.
24. Mericske-Stern R, Grutter L, Rosch R, Mericske E. Clinical evaluation and prosthetic complications of single tooth replacements by non-submerged implants. *Clin Oral Implants Res*. 2001;12:309–318.
25. Akca K, Cehreli MC, Iplikcioglu H. Evaluation of the mechanical characteristics of the implant-abutment complex of a reduced-diameter Morse-taper implant. A nonlinear finite element stress analysis. *Clin Oral Implants Res*. 2003;14:444–454.
26. Sutter F, Weber HP, Sorensen J, Belser U. The new restorative concept of the ITI dental implant system. Design and engineering. *Int J Periodont Restorative Dent*. 1993;13:409–431.
27. Norton MR. An in vitro evaluation of the strength of an internal conical interface compared to a butt joint interface in implant design. *Clin Oral Implants Res*. 1997;8:290–298.
28. Merz BR, Hunenbart S, Belser UC. Mechanics of the implant-abutment connection: an 8-degree taper compared to a butt joint connection. *Int J Oral Maxillofac Implants*. 2000;15:519–526.
29. Romanos GE, Nentwig GH. Single molar replacement with a progressive thread design implant system: a retrospective clinical report. *Int J Oral Maxillofac Implants*. 2000;15:831–836.
30. Nentwig GH, Moser W, Mairgünther R. Das Ankylos-Implantatsystem—Konzept, Klinik, Ergebnisse. *Implantologie*. 1993;3:225–237.
31. Mairgünther R, Nentwig G-H. Das Dichtigkeitsverhalten des Verbindungssystems beim zweiphasigen NM-Implantat. *Z Zahnärztl Implantol*. 1992;8:50–53.
32. Eisenmann E, Stiller M, Döring K, Fritz H, Freesmeyer WB. Das Ankylos-Balance-Aufbausystem. *Quintessenz*. 1999;50:583–592.
33. Willmann G, Fruh HJ, Pfaff HG. Wear characteristics of sliding pairs of zirconia (Y-TZP) for hip endoprostheses. *Biomaterials*. 1996;17:2157–2162.
34. Rimondini L, Cerroni L, Carrassi A, Torricelli P. Bacterial colonization of zirconia ceramic surfaces: an in vitro and in vivo study. *Int J Oral Maxillofac Implants*. 2002;17:793–798.
35. Malevez C, Hermans M, Daelemans P. Marginal bone levels at Branemark system implants used for single tooth restoration. The influence of implant design and anatomical region. *Clin Oral Implants Res*. 1996;7:162–169.
36. Rangert B, Krogh PH, Langer B, Van Roekel N. Bending overload and implant fracture: a retrospective clinical analysis. *Int J Oral Maxillofac Implants*. 1995;10:326–334.
37. Wannfors K, Smedberg JI. A prospective clinical evaluation of different single-tooth restoration designs on osseointegrated implants. A 3-year follow-up of Branemark implants. *Clin Oral Implants Res*. 1999;10:453–458.
38. Vermylen K, Colleart B, Linden U, Bjorn AI, DeBruyn H. Patient satisfaction and quality of single-tooth restorations. *Clin Oral Implants Res*. 2003;14:119–124.
39. Gargiulo AW, Wetz F, Orban B. Dimensions and relations of the dentogingival junction in humans. *J Periodontol*. 1961;32:261–266.
40. Cochran DL, Hermann JS, Schenk RK. Biologic width around titanium implants. A histometric analysis of the implantogingival junction around unloaded and loaded nonsubmerged implants in the canine mandible. *J Periodontol*. 1997;68:186–198.
41. Abrahamsson I, Berglundh T, Wennstrom J, Lindhe J. The peri-implant hard and soft tissues at different implant systems. A comparative study in the dog. *Clin Oral Implants Res*. 1996;7:212–219.
42. Berglundh T, Lindhe J. Dimension of the periimplant mucosa. Biological width revisited. *J Clin Periodontol*. 1996;23:971–973.
43. Hammerle CH, Bragger U, Burgin W, Lang NP. The effect of subcrestal placement of the polished surface of ITI implants on marginal soft and hard tissues. *Clin Oral Implants Res*. 1996;7:111–119.
44. Beniashvili R, Heymann C, Parsanejad HR, Nentwig GH. Zahn-implantat- und rein implantat-getragene Rekonstruktionen. *Z Zahnärztl Implantol*. 1999;15:87–91.
45. Weng D, Nagata M, Melo L, Leite C, Bosco A, Richter EJ. Influence of microgap design on periimplant bone. Poster presented at: EuroPerio; May 5, 2003; Berlin.
46. Haessler D, Kornmann F. Die naturanaloge Einzelzahnimplantation. *Quintessenz*. 2003;54:129–138.
47. Moser W, Nentwig GH. Finite-Elemente-Studie zur Verbesserung des Implantatschraubendesigns. *Z Zahnärztl Implantol*. 1989;1:29–32.
48. Nentwig GH, Romanos G, Strate J. Die transmucosale Schranke bei zweiphasigen, subgingival einheilenden Implantatsystemen und ihr biologisches

Potential. *Parodontologie*. 1998;3: 215–226.

49. Siar CH, Toh CH, Romanos GE, et al. Peri-implant soft tissue integration of immediately loaded implants in the posterior macaque mandible: a histomor-

phometric study. *J Periodontol*. 2003;74:571–578.

NOTE

The results and opinions presented are those of the author

and do not necessarily reflect the opinions of the American Academy of Implant Dentistry. This manuscript does not represent an endorsement of the evaluated implant by the American Academy of Implant Dentistry.