

BONE GRAFTING PROCEDURES FOR OSSEOUS DEFECTS ASSOCIATED WITH DENTAL IMPLANTS

Gagik Hakobyan, DDS, PhD

KEY WORDS

Bone quality
Success of implantation
Risk factors
Regenerative biomaterial
Cyst-removal sites
Augmentation procedure
Osseous defects

The purpose of this study was to clinically and radiographically evaluate the use of bone grafting therapy for treatment of osseous defects before implant surgery. After bone graft reconstruction, implants may be placed in previous areas of osseous defect with the expectation of long-term positive results.

INTRODUCTION

The success of dental implants to osseointegrate is highly predictable. Clinical efforts to achieve osseointegration are directed toward maximizing vital bone at the implant-surgical interface, limiting inflammation, and preventing micromotion at the implant-tissue interface. Two main aberrations may result in defective osseointegration. First, during the healing phase, the inability of the bone bed to establish adequate mechanical contact with the implant surface results in a layer of intervening connective tissue. Second, the development of a pathological process similar in principle to periodontitis leads to an accelerated loss of supporting structure via a centripetal path of infection.¹⁻³

Bone quality plays a major role in determining the success of the dental implant. Poor-quality bone and some diseases are universally recognized as risk factors. Radiolucent areas, draining fistulas,

symptoms of osteomyelitis, fracture sites less than 1 year old, metabolic bone disease, and clotting disorders all are contraindications for implant placement.⁴

Implant failures as a result of overload or infection give rise to bone loss. The 3 identifiable types of failure are (1) biological, or the inability of the host to establish or maintain osseointegration, which could result in early or late failures; (2) biomechanical, from prosthetic or functional overload; and (3) iatrogenic, from poor implant position or proximity to anatomic structures. Early implant failures are most commonly related to surgical trauma or inadequate bone quality or volume, whereas late failures are determined more by functional loads in relation to the quality of the supporting hard tissues and any tendency toward chronic or untreated infections.^{5, 6} Failure is caused by an infectious process that most likely started along the midportions and apical portions of the implant body. The organism could have been introduced into

Gagik Hakobyan, DDS, PhD, is director of the Medical Center Prometey and associate professor in the Department of Surgical Stomatology, State Medical University of Yerevan, Yerevan, Armenia. Correspondence should be addressed to Dr G. Hakobyan, Medical Center Prometey, 375028 Kievyan 14A, Yerevan, Republic of Armenia (e-mail: prom_hg@yahoo.com).

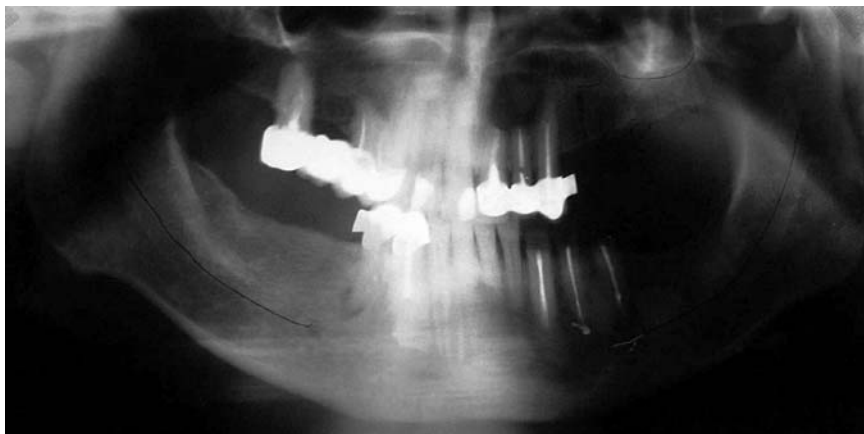


FIGURE 1. A panoramic radiograph shows a cystic radiolucency from the right central and lateral incisors to the right canine (tooth #11) region of the maxilla. The right mandibular first premolar (tooth #28) is present with a large endodontic-periodontal lesion, and the left mandibular canine and first and second premolars are present with remaining restorable roots (teeth #20–#22).

the site either at a later time of surgery or at a later time via a hematogenous route. These lesions differ from peri-implantitis in that the infectious process originates at the implant interface within the alveolar bone.^{7–9}

The search for an effective regenerative biomaterial to restore bone loss associated with periodontal disease, trauma, and neoplasms and to function with dental implant reconstruction has been a focal point for dental practitioners. A variety of biologically and synthetically derived bone augmentation materials have been used for the therapeutic repair and restoration of osseous defect sites, posttooth extraction, before and during implant placement, periodontal reconstruction, sinus augmentation procedures, and cyst-removal sites. These materials have given clinicians the ability to offer patients alternative treatment modalities that can restore missing bone anatomy for ridge maintenance or preservation and ridge augmentation and enhance bone foundation for endosseous implant placement.^{10–25}

Different clinical situations merit careful consideration of the surgical and restorative ap-

proaches taken during the process of tooth replacement with dental implants. Radicular jaw cysts occupy an essential place in the practice of oral and maxillofacial surgery. Regarding large cysts, the remaining cavity must be filled with bone-substitute materials to obtain a correct anatomic form and satisfactory mechanical strength.

The purpose of this study was to clinically and radiographically evaluate the use of bone grafting therapy for treatment of osseous defects before implant surgery.

MATERIALS AND METHODS

This clinical study involved 18 patients and the repair of 26 defects that comprised apical resection areas, cystic defects, extraction sites, and alveolar ridge defects requiring augmentation before implant surgery.

The presurgical work-up consisted of an oral examination; health history; various clinical and laboratory assessments (blood clinical and biochemical analysis); study models; and clinical examination involving probing pocket depths, bleeding on probing, plaque index, and im-

plant stability tests. The radiographic evaluation (qualification and quantification) of bone density should be accomplished during patient assessment after implant placement. The treatment plans were finalized after discussion with the patients regarding the option, risks, and benefits.

Surgical procedure

Treatment of osseous cysts requires intraosseous access obtainable at the expense of removing cortical bone formation, necessitating reconstructive procedures with grafts. This technique obviates the use of biocomposit preparats, barrier membranes in the treatment of large cysts, and apical resection areas and facilitates the dental rehabilitation with the osseointegrated implant in the second surgery.

Osteoplastic technique for the treatment of large osseous cysts involves the use of a fine bur and osteotome. After an appropriate surgical incision is made and access to the lesion is obtained, the cyst or granuloma is to be thoroughly enucleated. Root resection and apical retrograde fill should be performed, if necessary. The bone wall of the defect is then decorticated with a round bur. Large cystic bone defects are filled with biocomposit preparats. After bone graft reconstruction, the flaps are completely closed. Resorbable or nonresorbable membranes may also be used to achieve closure. A synthetic 3.0 or 4.0 suture material with a vertical mattress or interrupted closure is recommended. Appropriate postoperative antibiotic, analgesic, and home-care regimen should be prescribed. The patient should be cautioned against chewing or brushing the area for least 1 to 2 weeks and should use antibacterial rinses during this period.

Histological investigation was performed with trephines 6 months after grafting in 2 patients to remove a core of material from the augmented areas during second-stage implant surgery. Biopsies were fixed and embedded for serial sectioning and staining with toluidine blue and basic fuchsin.

Implant placement

Implants coated with hydroxyapatite (HA) have been identified as a potential method for optimizing early osseointegration by means of ionic bonding, even in poor-quality bone.²⁶⁻²⁸ Overall, 61 HA-coated titanium endosseous implants (44 screw and 17 blade-form implants, CISIT-SSTU-01, Saratov State Technical University, Saratov, Russian Federation) were used for implantation. Qualitative and quantitative classification of bone were used for selection of implants size and types for placement.^{29,30}

Selection of implant size and location was based on clinical and radiographic evaluation to place the longest and widest implant. Blade-form implants were commonly used in cases of a narrow alveolar ridge (<4 mm) at the distal part of mandible. All implants were inserted by recognized surgical procedures and according to manufacturer's protocol.³¹⁻³³ Maxillary screw implants were left for 6 months and mandibular screw implants were left for 3 months, after which they were exposed and restored according to conventional implant protocol. Blade-form implants were loaded 1 month postoperatively.

CASE REPORT

History and clinical examination

A 45-year-old man seeking implant rehabilitation presented

with partial maxillary and mandibular edentulosity. He had used partial dentures for 2 years without satisfaction.

Clinical and radiographic examinations were conducted. An updated health history was reviewed to evaluate his present health condition and to rule out diseases or other factors that would contraindicate bone graft or dental implant surgery. His medical history was negative for cardiovascular disease, renal disease, endocrine disorders, and hematological disorders. His laboratory data of routine blood and serum biochemical analysis were within normal limits. A panoramic radiograph showed cystic radiolucencies from the left central and lateral incisors (teeth #9 and #10) to the left canine (tooth #11) region of the maxilla. The right mandibular first premolar (tooth #28) presented with a large endodontic-periodontal lesion, but the left mandibular canine and first and second premolars presented with remaining restorable roots (teeth #20-#22) (Figure 1). Clinical and radiographic examination revealed adequate bone height and width in the maxillary edentulous region for screw implant placement and a narrow alveolar ridge (<4 mm) at the distal edentulous region of mandible.

Treatment plan

After diagnostic records and patient consultation, cystectomy and apicoectomy procedures were planned with the bone graft material Collapan (HA combined with collagen and antibiotic linkomycin; Intermediapatit, Moscow, Russian Federation) before implant surgery. One month postoperatively, the replacement plan included the use of 2 HA-coated titanium endosseous 2-stage screw implants in the #13 to #14 teeth regions of the maxilla and 2

HA-coated blade-form implants in the #19 to #31 teeth regions of the mandible were placed.

An initial treatment plan was presented to the patient. The plan included the restoration of teeth #20 to #22, surgical removal of the maxillary cyst, and apicoectomy of tooth #28 with subsequent bone grafting of the defect.

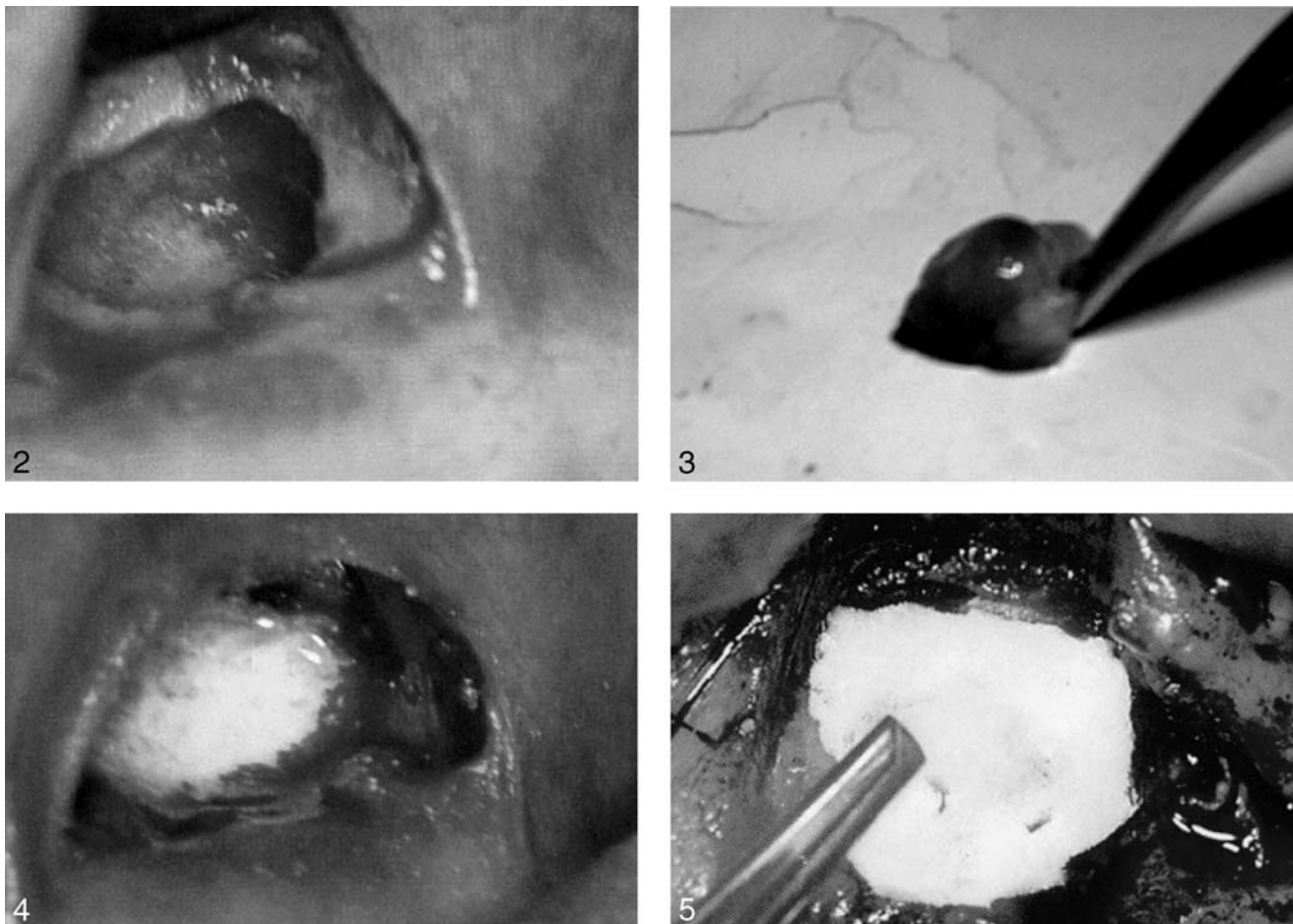
Surgical procedure

The patient was orally premedicated with 2 g of amoxicillin 1 hour before the procedure and was orally sedated with 10 mg of diazepam and prophylactic antibiotics 6 days postoperative. He was anesthetized with local anesthesia that included Ultracain D-S Forte (Hoechst Marion Roussel, Frankfurt, Germany) in the maxilla and with nerve block anesthesia in the inferior alveolar. After incision and elevating a mucoperiosteal flap, a fissure bur was then used to section the vestibular wall osseous cyst. Granulation tissue was removed from the cyst cavity (Figures 2 and 3) with a titanium curette, and the site was irrigated with saline and antibiotics. After degranulation and antiseptic preparation, the bone defect was filled with particles of gel of Collapan (Intermediapatit; Figure 4). It was then covered with a Capset Calcium Sulfate bone graft barriers membrane (Lifecore Biomedical Inc, Chaska, Minn) (Figure 5). The area was closed by continuous cross sutures with a 3-0 material (Vicryl, Ethicon Inc, Somerville, NY). The patient was instructed to use chlorhexidine mouth rinses twice daily for 2 weeks to reduce the risk of infection. Seven days later, the sutures were removed.

Implant placement

First-Stage Implant Surgery

Implants were placed 1 month postoperatively. The patient rinsed



FIGURES 2–5. FIGURE 2. After incision and elevating a mucoperiosteal flap, a fissure bur was used to section the vestibular wall osseous cyst. Granulation tissue was removed from the cyst cavity. FIGURE 3. Cyst removed from cyst cavity. FIGURE 4. After degranulation and antiseptic preparation, the bone defect was grafted with granules of gel Collapan (Intermediapatit, Moscow, Russian Federation). FIGURE 5. The defect was then covered with a Capset Calcium Sulfate (Lifecore Biomedical Inc, Chaska, Minn) bone graft barriers membrane.

his mouth with chlorhexidine 0.1% for 1 minute before being fully draped. He was administered local anesthesia that included Ultracain D-S Forte (Hoechst Marion Roussel) in the left maxilla, bilateral inferior alveolar nerve block in the mandibula, and additional buccal and lingual injections. Additionally, 8 mg of dexamethasone was injected intraorally via the intramuscular route. A number 15 blade was used to make a crystal incision. A full-thickness mucoperiosteal flap was elevated and the host bone site was exposed. The implant sites were prepared with drills of increasing diameter. Implant osteotomies were sequentially prepared

with externally irrigated drills of increasing diameter according to implant systems protocol. Two titanium HA-coated screw implants (3.5 × 13 mm) were inserted at the implant site for the #13 and #14 maxilla and 2 blade-form implants were placed at #18 and #31 mandible. Healing plugs were inserted in the screw implants and flaps were repositioned and sutured (Figures 5 through 9). X rays were performed postoperatively (Figure 10). The healing phase was uneventful.

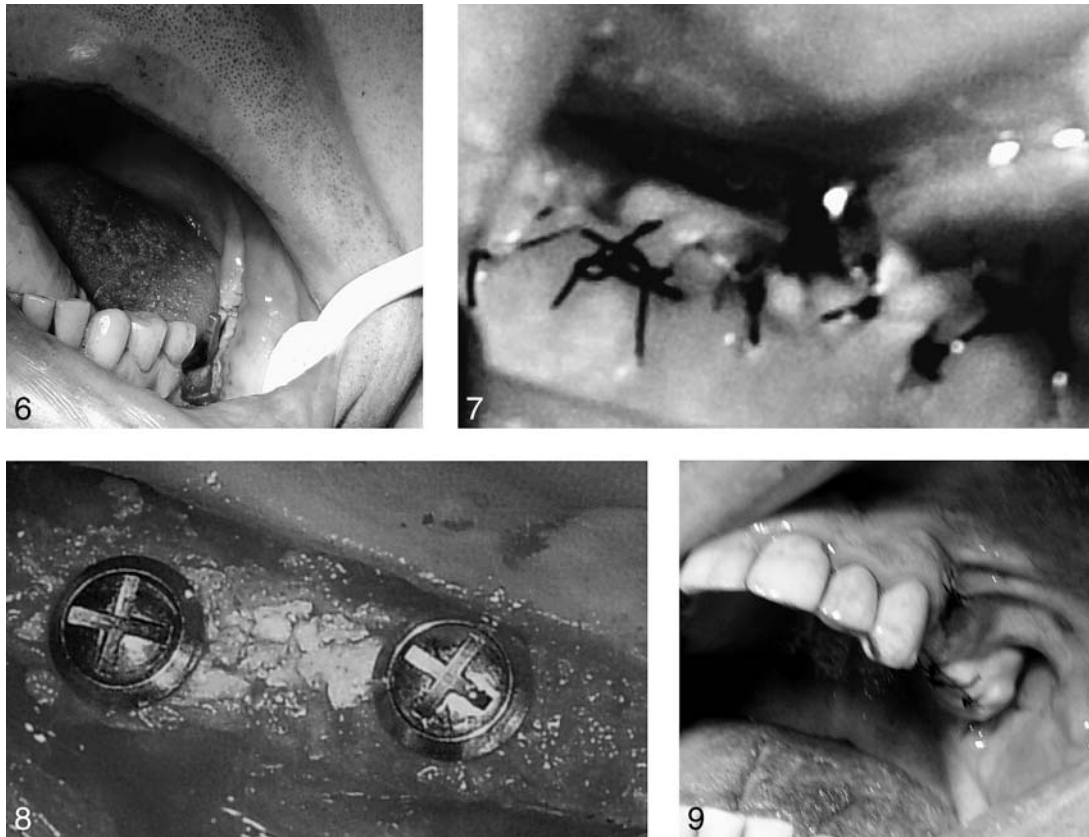Second-Stage Implant Surgery

Second-stage implant surgery in the maxilla was performed after 5 months of healing. The area was

anesthetized with local anesthesia. An incision was made on ridge crests of #13 and #14 maxilla, and mucoperiosteal flaps were reflected. The implants were embedded in healthy bone and were clinically stable. The healing plugs of the implants were replaced with prosthetic abutments. The flaps were approximated and sutured. After 2 weeks of soft-tissue healing, the prosthetic phase of treatment was initiated.

Prosthetic procedure

The treatment plan included the restoration of the left maxilla defect and bilateral mandibular dis-



FIGURES 6–9. FIGURE 6. Titanium hydroxyapatite-coated blade-form implants were inserted at the left second molar mandible. FIGURE 7. Flaps were repositioned and sutured at the right blade-form implant. FIGURE 8. Healing plugs were inserted in the screw implants. FIGURE 9. Flaps were repositioned and sutured.

tal defects with a tooth- and implant-supported fixed prosthesis. Metaloceramic reconstruction was fabricated and fixed in the teeth and abutments (Figures 11 through 16).

RESULTS

Successful implantation was established by using parameters established by Albrektsson et al.³⁴ All surgical sites healed uneventfully both at time of grafting and at implant installation. No immediate postoperative complication (eg, infection, persistent pain, bleeding) occurred after any of the bone graft procedures. No foreign-body reaction occurred with the materials within the bone. Histology demonstra-

ted all particles of Collapan (Intermediapatite) were surrounded by newly formed bone (Figure 17). The results showed that in all cases the defect was eventually filled with newly formed bone, although at a very slow rate. Tissues appeared to be normal in color and consistency, and all implants were clinically integrated. When comparing clinical parameters (ie, plaque index, gingival index, probing depths, and gingival recession), no significant differences were among the implant types. Failure criteria included mobility, pain, implant loss, and peri-implant radiolucency.

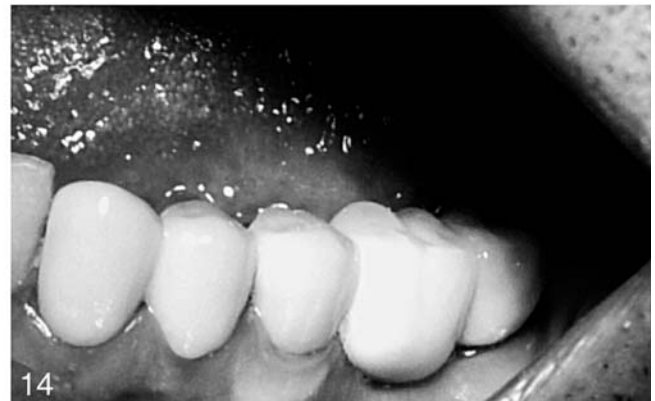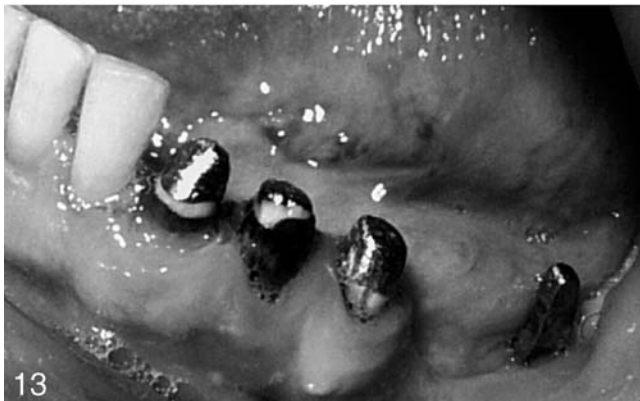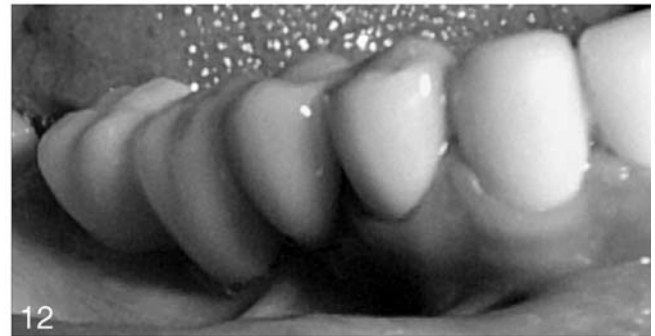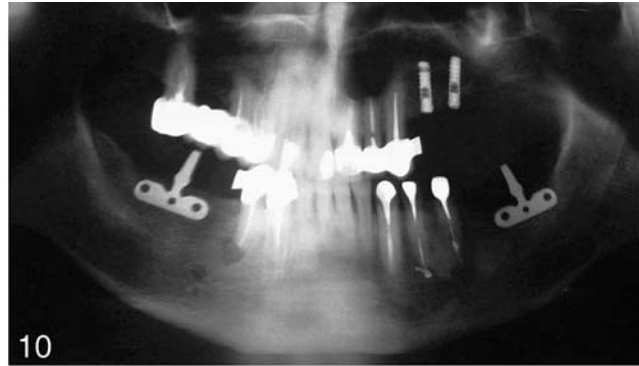
One blade-form implant failed after 2 years of loading because its neck fractured, and 2 failed between the second and third year

after surgery because of peri-implantitis. Five-year follow-up results revealed implant stability, good quality of underlying bone, absence of inflammation at the peri-implant zone, and positive osseointegration dynamics.

DISCUSSION AND CONCLUSIONS

The presence of bony defects often precludes the surgical placement of implants, and the need for grafting is indicated. Implants should be placed in healthy bone; there should be no signs or symptoms of any disease that might interfere with the bonding of bone to the implant.⁴

Presence of a chronic infection in periapical fabrics will cause infringement of blood circulation



FIGURES 10–14. FIGURE 10. X rays were performed after implantation. FIGURE 11. Right blade-form implant before reconstruction. FIGURE 12. Metalceramic reconstruction was fabricated and fixed in teeth and right blade-form implant abutment. FIGURE 13. Restored teeth #20 to #22 and left blade-form implant before reconstruction. FIGURE 14. Metalceramic reconstruction was fabricated and fixed in teeth #20 to #22 and left blade-form implant abutment.

and hypoxia, and will change the general reaction of an organism and may cause a sensitization.

Periapical lesions around an implant (retrograde peri-implantitis) may be caused by bacterial contamination from extracted or still-present teeth, excessive bone heating during osteotomy preparation, microfractures from bone overloading, residual bone cavi-

ties when short implants are placed into long osteotomies, and preexisting infection in the bone.^{35,36}

Root cysts and periapical destructive processes are among the chief inflammatory diseases of the maxillofacial area. It is important to remove the bone defect after the operation, depending on the duration of healing and the

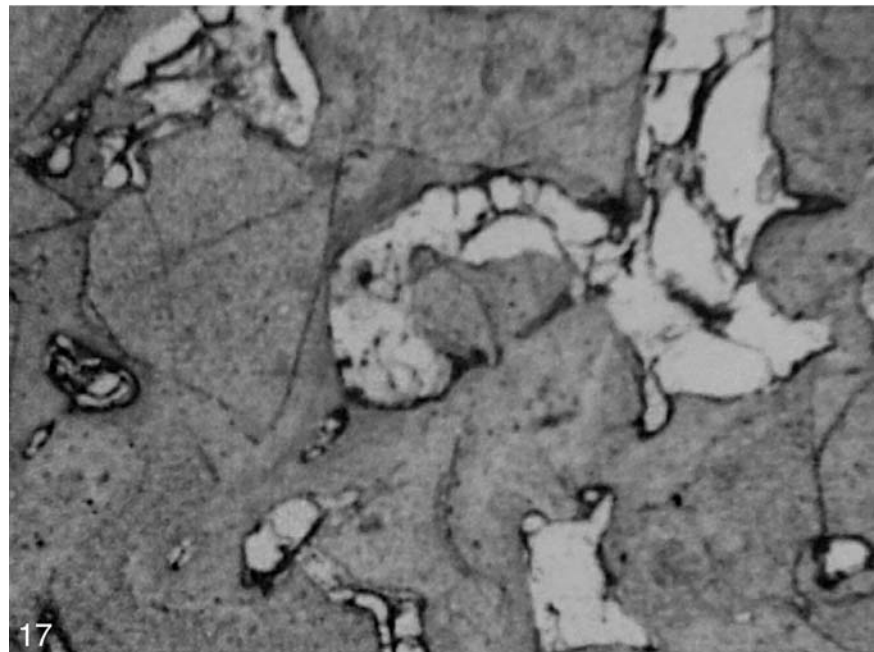
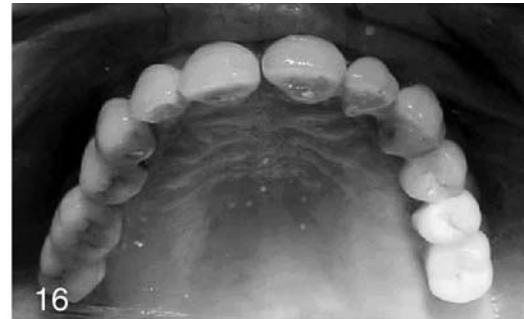
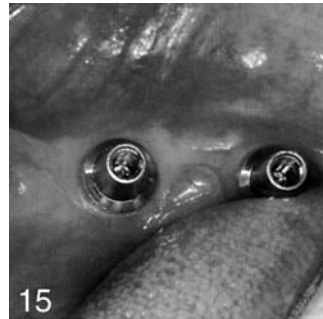
rather high frequency of purulent complications of bone wounds. After removing an average-sized or large cyst during a healing of a bone wound, no filled bone defect is present under the bloody clot, which reduces the durability of a bone and the thickness of an alveolar ridge. Infection implies the presence of virulent microorganisms that are plentiful

enough to overwhelm the local defense mechanisms of the host. The process is fostered by factors such as necrosis, compromised blood supply, and hypoxia, that tend to favor local concentrations of organisms and spread via the Haversian and Volkmann canal systems.³⁷⁻³⁹

Several factors are critical to the success of the bone grafting procedures: (1) good isolation of the surgical site to prevent contamination, (2) a traumatic handling of the soft tissue, (3) reflection of full mucoperiosteal flaps, (4) good compression of the bone graft material to eliminate voids, (5) ensuring hemostasis with intraoral pressure dressings for 10 to 15 minutes, (6) proper suturing techniques to provide good apposition of the soft tissue, and (7) thorough postoperative instructions to the patient.⁴⁰

This study presents a method combining techniques to replace missing teeth in patients with osseous defects. Positive surgical results are related directly to factors of patient cooperation, surgical technique, proper case selection, and diligent home-care practices.

The higher efficiency and osteoconductive properties of Collapan (Intermediapatite) for repairing intrabony defects are demonstrated in this study. The medical effect of Collapan is caused by its osseogenic properties: the preparation contains high-purity collagen and HA, which is a matrix for re-formed bone fabric, possesses anti-inflammatory action, and creates an antiseptic background in a wound with prolonged allocation of an antibiotic within 20 days. The results show high efficiency of methods of bone grafts at the stages of preparation, which carry out the dental im-



FIGURES 15-17. FIGURE 15. The healing plugs of the implants were replaced with prosthetic-type abutments. FIGURE 16. Metaloceramic reconstruction was fabricated and fixed in teeth and screw implants abutments. FIGURE 17. The histological section revealed mature bone surrounding the remaining crystals of particles of Collapan (Intermediapatite).

plantations and essentially expand the indications of given kind of treatment. Bone grafting therapy for osseous defects reduces the risk of implant failure and provides the success of implantation. This procedure is simple, safe, and effective for treatment of osseous defects before implant surgery.

REFERENCES

1. Probst A, Spiegel HU. Cellular mechanisms of bone repair. *J Invest Surg.* 1997;10:77-86.
2. Mombelli A, van Oosten MA, Schurch E Jr, et al. The microbiota associated with successful or failing osseointegrated titanium implants. *Oral Microbiol Immunol.* 1987;2:145-151.
3. Meffert RM. How to treat ailing and failing implants. *Implant Dent.* 1992; 1:25-33.
4. Caswell CW, Clark AE. *Dent Implant Prosthodont.* 1991;113:105-174.
5. Esposito M, Hirsch JM, Lekholm U, et al. Biological factors contributing to failures of osseointegrated oral implants. (II). Etiopathogenesis. *Eur J Oral Sci.* 1998;106:721-764.
6. Esposito M, Hirsch J, Lekholm U, et al. Differential diagnosis and treatment strategies for biologic complications and failing oral implants: a review of the

- literature. *Int J Oral Maxillofac Implants*. 1999;14:473-490.
7. Quirynen M, De Soete M, van Steenberghe D. Infectious risks for oral implants: a review of the literature. *Clin Oral Implants Res*. 2002;13:1-19.
 8. Ayangco L, Sheridan PJ. Development and treatment of retrograde peri-implantitis involving a site with a history of failed endodontic and apicoectomy procedures: a series of reports. *Int J Oral Maxillofac Implants*. 2001;16:412-417.
 9. Reiser GM, Newins M. The implant periapical lesion: etiology, prevention, and treatment. *Compend Contin Educ Dent*. 1995;16:768-772.
 10. Shaffer MD, Juruaz DA, Haggerty PC. The effect of peri-radicular endodontic pathosis on the apical region of adjacent implants. *Oral Surg Oral Med Oral Pathol Oral Radiol Endod*. 1998;86:578-581.
 11. Ong M, Eber RM, Korsnes MI, et al. Evaluation of a bioactive glass alloplast in treating periodontal intrabony defects. *J Periodontol*. 1998;69:1346-1354.
 12. Ayangco L, Sheridan P. Development and treatment of retrograde peri-implantitis involving a site with a history of failed endodontic and apicotomy procedures: a series of reports. *Int J Oral Maxillofac Implants*. 2001;16:412-417.
 13. Szaby G, Suba Z, Barabos J. Use of bioplastic HTR synthetic bone to eliminate major jawbone defects: long-term human histological examinations. *J Craniomaxillofac Surg*. 1997;25:63-68.
 14. Litsrom RD, Symington JM. Osseointegrated dental implants in conjunction with bone grafts. *Int J Oral Maxillofac Surg*. 1988;17:116-118.
 15. Hakobyan G. Immediate implantation with autogenous osseous particles and preparation Collapan. *Int J Oral Maxillofac Surg*. 2001;30:s13.
 16. Hakobyan G. Augmentation of narrow alveolar ridge by a green stick fracture with subsequent dental implantation. *J Craniomaxillofacial Surg*. 2002;30:153.
 17. Corsair A. A clinical evaluation of resorbable hydroxylapatite for the repair of human intraosseous defects. *J Oral Implantol*. 1990;16:125-128.
 18. Stahl SS, Froum SJ. Histologic and clinical responses to porous hydroxylapatite implants in human periodontal defects. Three to twelve months postimplantation. *J Periodontol*. 1987;58:689-695.
 19. Valen M, Ganz SD. A synthetic bioactive resorbable graft for predictable implant reconstruction: part one. *J Oral Implantol*. 2002;28:167-177.
 20. Vlassis JM, Hurzeler MB, Quirynen CR. Sinus lift augmentation to facilitate placement of nonsubmerged implants: a clinical and histological report. *Pract Periodont Aesthetic Dent*. 1993;5:15-23.
 21. Duncan JM, Westwood RM. Ridge widening for the thin maxilla: a clinical report. *Int J Oral Maxillofac Implants*. 1997;12:224-227.
 22. Laurell L, Gottlow J, Zybutz M, Persson R. Treatment of intrabony defects by different surgical procedures: a literature review. *J Periodontol*. 1998;69:303-313.
 23. Valen M, Ganz SD. A synthetic bioactive resorbable graft for predictable implant reconstruction: part one. *J Oral Implantol*. 2002;28:167-177.
 24. Fukuda M, Iino M, Ohnuki T, Nagai H, Takahashi T. Vertical alveolar distraction osteogenesis with complications in a reconstructed mandible. *J Oral Implantol*. 2003;29:185-188.
 25. Lundgren S, Rasmusson L, Sjöstrom M, Sennerby L. Simultaneous or delayed placement of titanium implants in free autogenous iliac bone grafts. Histologic analysis of the bone graft-titanium interface in 10 consecutive patients. *Int J Oral Maxillofac Surg*. 1999;28:31-37.
 26. Kenney EB, Lekovic V, Sa Ferreira JC, Han T, Dimitrijevic B, Carranza FA Jr. Bone formation within porous hydroxylapatite implants in human periodontal defects. *J Periodontol*. 1986;57:76-83.
 27. Gottlander M, Albrektsson T. Histomorphometric analyses of hydroxylapatite-coated and uncoated implants. The importance of the implant design. *Clin Oral Implants Res*. 1992;3:71-76.
 28. Jansen JA, van der Waerden JPSM, Wolke JGC. Histological and histomorphometrical evaluation of the bone reaction to three different titanium alloy and hydroxylapatite coated implants. *J Appl Biomater*. 1993;4:213-219.
 29. Misch CE, Judy KWM. Classification of partially edentulous arches for implant dentistry. *Int J Oral Implantol*. 2000;26:127-128.
 30. Lekholm U, Zarb GA. Patient selection and preparation. In: Branemark P-I, Zarb GA, Albrektsson T, eds. *Tissue-Integrated Prosthesis Osseointegration in Clinical Dentistry*. Chicago, Ill: Quintessence; 1985:199-209.
 31. Weiss CH. A comparative analysis of fibro-osteal and osteal integration and other variables that affect long term bone maintenance around dental implants. *J Oral Implantol*. 1987;13:467-487.
 32. Adell R, Lekholm U, Rockler B, Branemark P-I. A 15-year study of osseointegrated implants in the treatment of the edentulous jaw. *J Oral Maxillofac Surg*. 1981;10:387-416.
 33. Bolender C. Indications and contraindications for different types of implant therapy. *J Dent Educ*. 1988;52:1987-1990.
 34. Albrektsson T, Zarb G, Worington P, Ericsson AR. The long-term effect of currently used dental implants: a review and proposed criteria for success. *Int J Oral Maxillofac Implants*. 1996;11:379-386.
 35. Ratner EJ, Langer B, Evins ML. Alveolar cavitation osteopathosis. Manifestations of an infectious process and its implication in the causation of chronic pain. *J Periodontol*. 1986;57:593-603.
 36. Piattelli A, Scarano A, Piattelli M. Abscess formation around the apex of a maxillary root form implant: clinical and microscopical aspects. A case report. *J Periodontol*. 1995;66:899-903.
 37. Cortellini P, Bartolucci E, Clauser C, Pini Prato GP. Localized ridge augmentation using guided tissue regeneration in humans: a report of nine cases. *Clin Oral Implants Res*. 1993;4:203-209.
 38. Sandberg E, Dahlin C, Linde A. Bone regeneration by the osteopromotion technique using bioabsorbable membranes: an experimental study in rats. *J Oral Maxillofac Surg*. 1993;51:1106-1114.
 39. Wiskott HWA, Dubrez B, Belsler UC. Reversible and irreversible peri-implant lesions: report and etiopathogenic analyses of 7 cases. *J Oral Implantol*. 2004;30:255-266.
 40. Callan DP. Guided tissue regeneration without a stage 2 surgical procedure. *Int J Periodont Restor Dent*. 1993;13:173-179.