

ELEVATION OF THE MAXILLARY SINUS FLOOR WITH HYDRAULIC PRESSURE

Emmanouil G. Sotirakis, DDS
Aron Gonshor, PhD, DDS

KEY WORDS

Maxillary sinus elevation
Sinus lift
Hydraulic pressure
Osteotomes

This study describes a new method using hydraulic pressure to elevate the antral floor for bone grafting between the sinus floor and the schneiderian membrane before placement of endosseous osseointegrated implants. The method was first modeled experimentally in hen eggs, acting as a surrogate sinus, and then in human cadaver preparations. Several clinical case reports are also presented. This technique successfully combines the advantages of the Caldwell-Luc window approach, which permits the placement of high bone graft volume, and the simplicity of the osteotome technique by way of the alveolar ridge crest.

INTRODUCTION

The insertion of osseointegrated implants in the posterior maxilla, in patients who have lost their posterior maxillary teeth, often presents difficulties for the following 3 reasons: (1) deficient alveolar bone width, (2) increased pneumatization of the maxillary sinus resulting in (3) close approximation of the sinus to crestal bone.¹ Alveolar bone loss that calls for elevation of the sinus floor to generate sufficient bone volume for implants at least 10 mm long² can be categorized by the following: (1) an alveolar ridge of 5 to 10 mm, (2) an alveolar ridge equal to or less than 5 mm,³ and (3) a complete absence of alveolar bone between the sinus floor and alveolar crest. The first category is the most common and often per-

mits simultaneous floor elevation and implantation.⁴

In 1970, Tatum developed the method of antral floor grafting, based on a modified Caldwell-Luc lateral approach to the antrum, through the creation of a window in the maxillary bone.⁵⁻⁶ In 1980, Misch⁷ performed an augmentation of the sinus with simultaneous implant placement.² Today the modified Caldwell-Luc approach is the most generally accepted method, allowing for the benefit of ready access to the sinus, significant elevation of the floor, and thus creation of sufficient bone volume to support the placement of implants. Another benefit of this method is the broad surgical field visibility it provides. The disadvantages of this technique are the relatively large surgical operation required, need for specialized instrumentation, risk of perforation of the schneiderian

Emmanouil G. Sotirakis, DDS, is in private practice in Athens, Greece. Address correspondence to Dr Sotirakis at Omirou 50 Street, 17121 New Smirni, Athens, Greece (e-mail: emmsotir@ipnet.gr).

Aron Gonshor, PhD, DDS, is in private practice and is a lecturer at McGill University, Oral and Maxillofacial Surgery, Montreal, Canada.

membrane, postoperational symptoms, and cost.

In 1994, Summers⁸⁻¹⁰ presented a method that consisted of a crestal approach to the sinus. Beginning with the creation of a cylindrical osteotomy by means of both drills and osteotomes, a fracture is created in the bone of the sinus floor, being careful not to perforate the overlying membrane. Implantation follows, with the implant being advanced forward into the sinus and the membrane being lifted in a tenting fashion. Later, this method was enhanced to include the placement of graft material beneath the membrane, allowing for the creation of at most up to 3 to 4 mm of graft height in the sinus.² As a surgical technique it possesses the advantage of simplicity, avoiding a second surgical site for the upward displacement of the schneiderian membrane. Moreover, it results in a minimum of postsurgical symptoms. However, disadvantages of this method include the production of a limited amount of augmentation and no visual access to the site.

The question that arises is, "How, with the Summers method, can we achieve greater elevation of the sinus membrane, approximating the result achievable with the more invasive Tatum technique?" The method described in this study will endeavor to answer this question by detailing the use of controlled hydraulic pressure to lift the sinus floor membrane.

MATERIALS AND METHODS

Broadly speaking, the hydraulic pressure technique follows the Summers method to reach the sinus bone floor and fracture it, applying osteotomes in a specific sequence, to both deepen and

widen the osteotomy site and create an in-fracture of the sinus floor. Next, injecting normal saline solution under hydraulic pressure beneath the schneiderian membrane with a suitably fitted syringe creates simultaneous detachment and elevation of the membrane. Before human clinical application, the method was modeled in a series of studies.

The first studies were performed on hen's eggs. It is well known that the sinus cavity, with its membrane lining in a compact enclosure of surrounding bone, can be likened, for didactic purposes, to that of the interior of a hen's egg. A small hole is made in 1 of the 2 poles of the egg and its contents emptied so that it approximates the anatomical condition encountered in the sinus. Next, from the opposite pole, the shell is carefully broken, being careful not to damage the internal membrane. The aperture created is 3.5 to 4 mm in diameter. The membrane is gently pushed with suitable instrumentation, within the limits of its elasticity, until it comes away from the circumference of the aperture over as large an area as possible and to the extent permitted by the diameter of the aperture. An airtight rubber bladder is then attached around the orifice and pressure applied, releasing air from the bladder into the egg interior. In this controlled way, up to 50% of the membrane can be predictably detached without membrane dehiscence. This same technique can be used to inject a fluid by means of hydraulic pressure (injection), with the same effect observed. The success of this model led to the next step in testing the technique.

The second series of tests were performed on human cadaver preparations at the Maximilians-

Ludwig Institute of Anatomy in Munich, Germany. The method was applied on a number of different sinuses in a variety of anatomical conditions, which can be divided into 3 primary categories: (1) sinuses with a relatively thick schneiderian membrane, (2) sinuses with a thin membrane, and (3) sinuses in which bone septa are encountered while creating the osteotomy sites for elevation and placement of an implant. The cadaver surgery involves opening the roof of the sinus, which is also the floor of the orbital rim, to have access from the orbit to the floor of the sinus. An incision is then made along the alveolar crest, along with buccal and palatal flap retraction. The floor of the sinus is then approached, with the aid of osteotomes (with the convex working edge) or drills, depending on the bone density of the remaining alveolar crest. The height of the residual alveolar crest is determined either radiographically or by internal illumination of the sinus. Cadavers were chosen with a residual alveolar crest of approximately 4 mm. The osteotomies from the crest to the sinus floor were performed to diameters between 3.3 and 4 mm. Diameters over 4 mm were created if a broader alveolar crest existed at the start. The osteotomes (ACE Surgical, Brockton, Mass) consisted of both the step osteotomes, Nos. 1.6 (2 mm), 2 (2.8 mm), 2.8 (3.3 mm), and 3.3 (4 mm), with a graduated working edge, and the straight-edged, 3.3- or 4-mm final osteotomes (Figure 1A). By using these osteotomes in a series of increasing diameters, the bone of the sinus floor was gently fractured, and the lifting completed with a final 3.3- or 4-mm diameter (Figure 1A).

To achieve a full opening of the osteotomy along its whole

diameter, as well as to protect the membrane from excess swelling (green stick technique),¹¹ which at this phase could create perforation, the corresponding lateral bone-concentrating osteotomes, with a concave edge, were used to enlarge the aperture. Through gentle tapping, cleaning, and lightly pushing the membrane along its flexible edges, the membrane was detached from the aperture at the edges (Figure 1A). In this phase a small amount of elasticity of the membrane can be seen from above in cadaver preparations. Owing to the effect of the embalming medium, the elasticity is much less than that in living organisms.¹²

The next step consists of detaching and lifting the membrane with hydraulic pressure. A plastic syringe with a curved nozzle (ACE Surgical), suitable for socket irrigation following tooth extraction, was used. The nozzle of the syringe can easily be cut to the desired length with a scalpel. For an osteotomy aperture of 4 mm, the nozzle tip is cut to slightly less than 4 mm. The nozzle is applied to the bone cavity, keeping the connection airtight. After filling the syringe with normal saline solution and completely extracting the air, the plunger of the syringe is depressed slowly. Normal isotonic saline solution is chosen, given the possibility that the fluid could penetrate some small blood vessels in the cancellous bone or on the membrane. The fluid will seep under the membrane and detach it from the bony floor of the sinus and, because of the hydraulic pressure, will start to create lift (Figure 1B). When the hydraulic elevating syringe is withdrawn from the bone, the fluid comes through the osteotomy site into the oral cavity. With administration of 3 mL of normal saline solution,

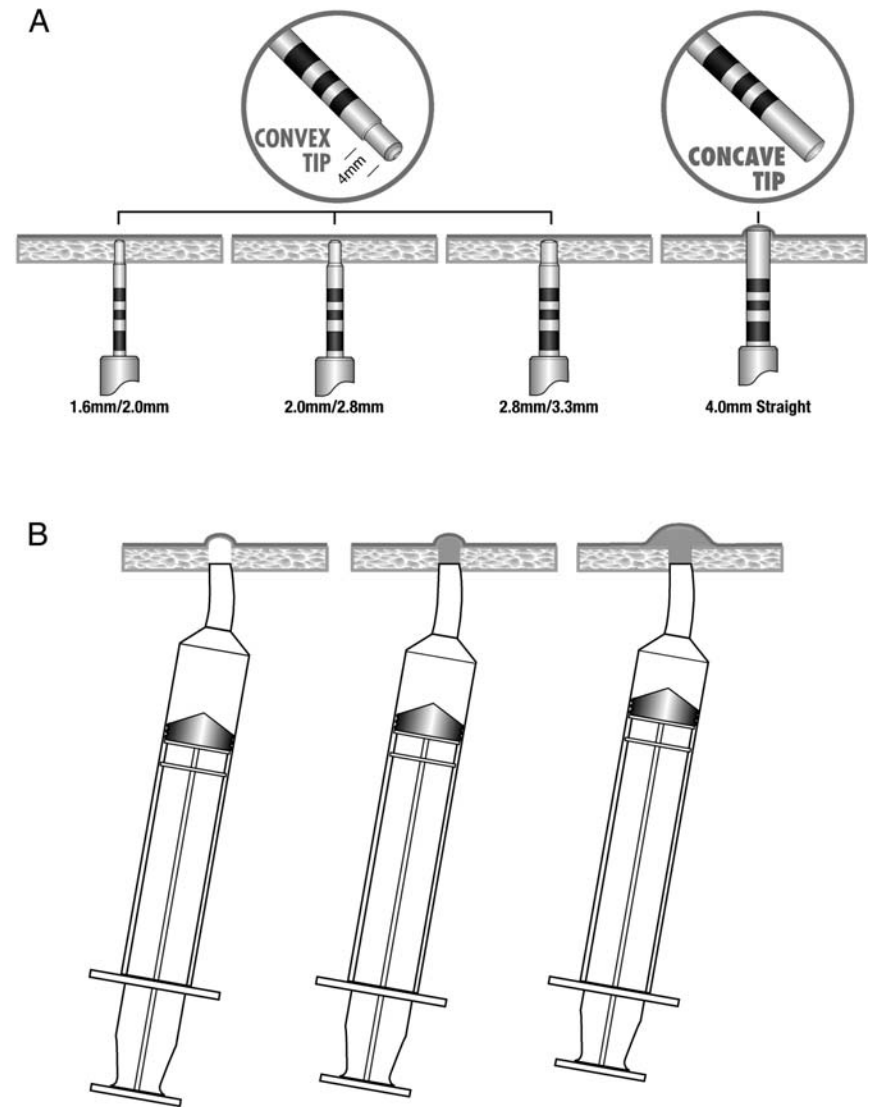
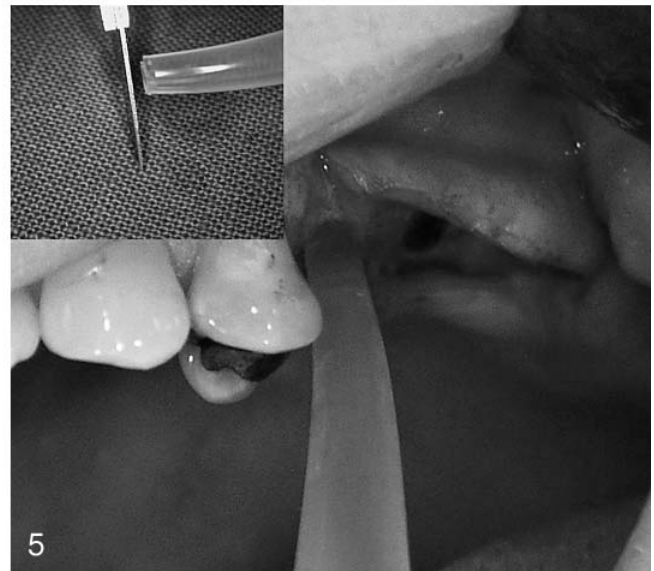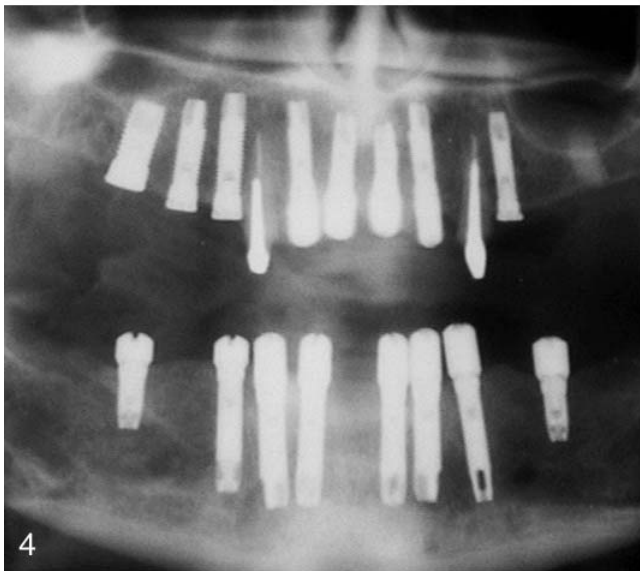
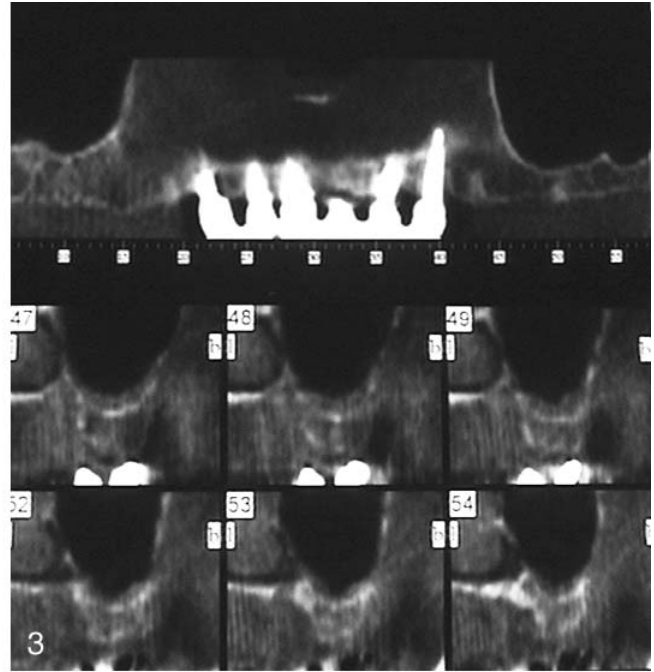
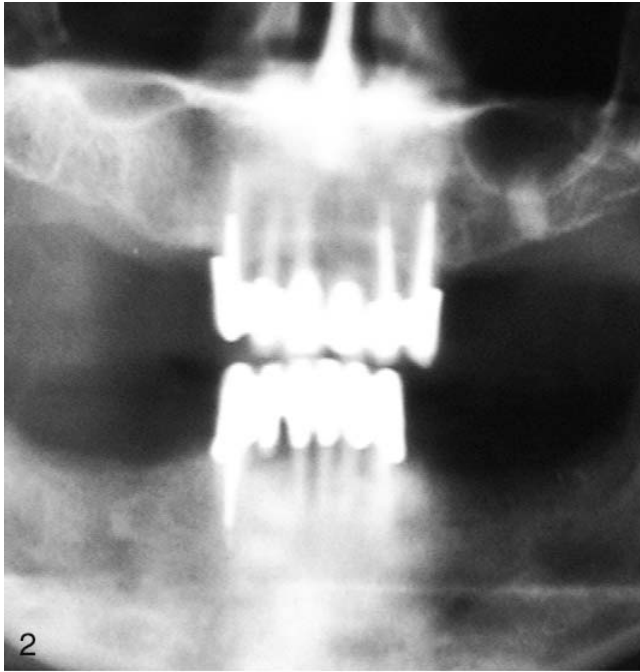


FIGURE 1. Schematic representations of (A) osteotomes of increasing diameter, leading to in-fracture of the sinus osseous floor, and (B) a modified syringe injecting fluid into an osteotomy site and under the schneiderian membrane, creating a tenting result.

sufficient elevation occurs for the placement of graft material and implants from 10 to 13 mm in height. The grafts, either autogenous or in combination with allograft, must be sufficiently fine in texture to allow for their easy introduction through the bone cavity into the submembrane space.

In cadaver preparations, the elevation of the membrane is visible from above and resembles a balloon being inflated around the opening in the bone floor. In

cadavers, the method is successful as long as the fluid is administered slowly and steadily. In 2 cases the membrane ruptured when sudden pressure was applied to the plunger of the syringe. In both instances the sinuses were in the thin-membrane category. In cases with sinus septa, the osteotomy can easily be moved to the side of the septum, and the elevation can proceed normally. The radiographic pictures of the sinus, which are always taken before



FIGURES 2–5. FIGURE 2. Clinical case 1. Preoperative panoramic radiograph showing upper left posterior edentulism and sinus pneumatization. Note residual root in the first molar position. FIGURE 3. Clinical case 1. Computerized tomography scans showing panoramic view in upper portion and 6 sectional cuts in the upper left second premolar and first molar positions in lower portion. FIGURE 4. Clinical case 1. Panoramic view after bimaxillary placement of 16 implants. FIGURE 5. Syringe tip in osteotomy and fluid being injected. Insert shows the tip of the syringe cut by a scalpel to conform to osteotomy and create airtight interface.

this stage, are also helpful to determine if there is a septum in the sinus.

CLINICAL CASE 1

A 60-year-old woman sought care for full oral rehabilitation. Her

medical history was normal, and examination revealed generalized periodontal disease in the bone of her remaining anterior dentition. A diagnostic procedure was initiated with periapical and panoramic radiography, as well as computerized tomography (CT)

scans (Figures 2 and 3). A diagnostic wax-up was performed, with a plan to place 18 implants. The underlying bone was adequate where 16 of the implants were to be placed. For the remaining 2 implants, the floor of the left sinus would require ele-

vation. In this latter area the residual alveolar crest was 5 mm in height, and the decision was to apply the method described herein for elevating the sinus floor. Sixteen implants were placed, 8 in each jaw (Figure 4). The remaining 2 were to go into the maxillary left second premolar (#25) and first molar (#26) positions. At #25 the height of the residual alveolar crest was 8 mm, and at #26 it was 5 mm, with a residual root (Figure 2), which was extracted. The alveolar bone was allowed to heal for 10 weeks, at which time there was to be simultaneous sinus floor elevation and implant placement. As can be seen in the panoramic radiograph, #25 is at the anterior corner of the sinus (Figure 2). The CT scan permitted the following to be verified: the height and thickness of the residual alveolar crest, the thickness of the membrane, and the health of the sinus cavity. If in this case, or any of the others, sinus membrane inflammation was suspected, the patient had to undergo antibiotic treatment for at least 2 weeks.¹³

Using the technique outlined herein, the fracture of the sinus floor bone for both implants was created with the 4-mm final osteotome. The membrane was elevated and detached after adjusting the syringe to the bone osteotomy at #26. It is imperative that the bone to syringe interface be airtight so that no lateral leakage of the saline occurs, as is shown in a photograph from another clinical case (Figure 5).

As detachment and simultaneous lifting of the membrane took place around #26, the normal saline solution began to exit into the oral cavity through the osteotomy site at #25, showing that the membrane did not rupture. Any significant membrane tear would have resulted in diversion of the

fluid into the sinus cavity and eventual nasal exudation. This, however, did not occur, and the membrane was successfully detached with the fluid pressure head, demonstrating the flexibility of the membrane in the living organism. A 3.75 by 10-mm implant with a Restorable Blast Media textured surface (ACE Surgical) was then placed in #25. The same implant type was used in all the cases discussed in this study. With the #25 osteotomy site now blocked to fluid passage, membrane elevation was continued, using estimates derived from cadaver preparations (ie, a provision for approximately 3 mL of normal saline solution injection). This also depends on the height of the residual alveolar crest and the volume of bone one wishes to obtain. No problems have occurred with larger fluid input for greater elevation.

The next stage involved placement of the bone graft. An inorganic bone mineral xenograft (BioOss, Geistlich Biomaterials Inc, Wolhusen, Switzerland) was put into position. It was mixed with autogenous bone¹³ and collected intraorally through trephining and bone trap filtering. The graft mixture was carefully compacted into the bone cavity so that the membrane did not rupture. Next, a 4 by 10-mm implant was inserted and the flap sutured.

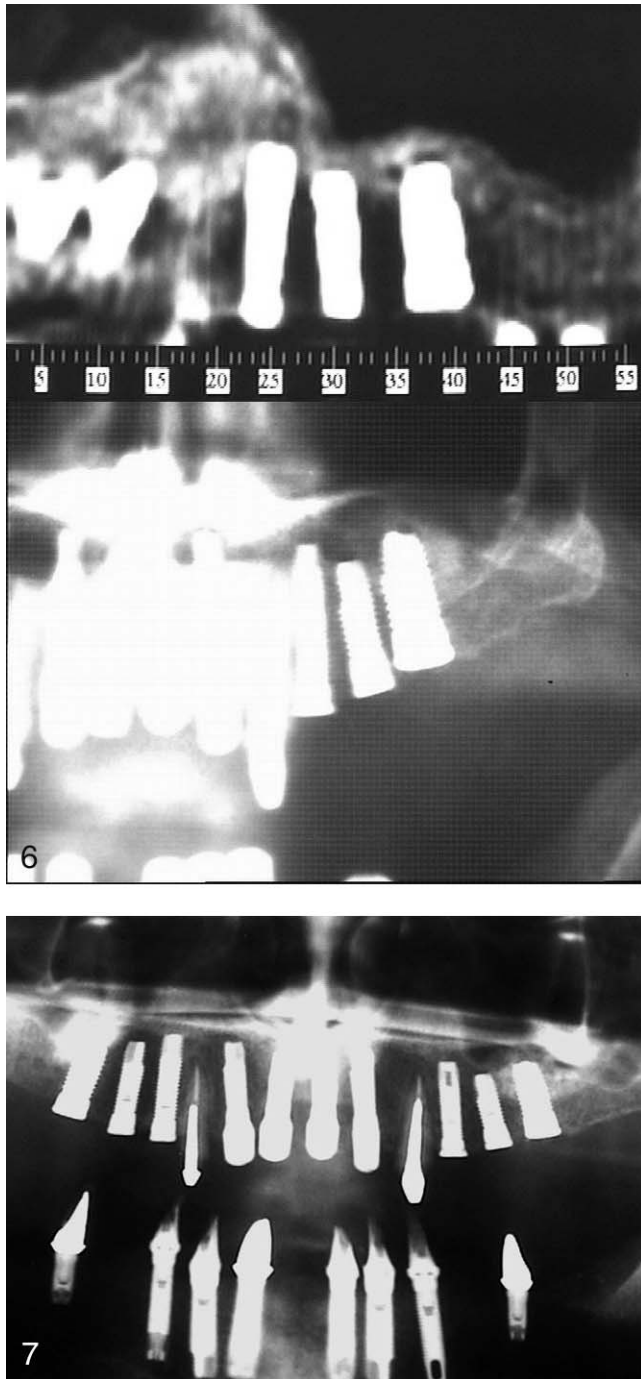
Antibiotic treatment was administered, but the patient was not given analgesics, so the postoperative symptoms could be observed. During the following 2 days, the patient was checked for bleeding or fluid exudate from the nose, which would have signified rupture of the membrane. Neither occurred. The subjective symptoms were mild, with a slight sense of swelling felt diffusely over the area for several hours.

The mild symptoms were easily tolerated by the patient. Immediately after surgery, a panoramic radiograph and CT scan were performed to ascertain if the membrane was intact and if there was leakage of graft material into the sinus cavity above the membrane (Figure 6).

The surgical area was reopened 9 months later. The implants were osseointegrated, and rehabilitation was completed with the installation of a fixed prosthesis. It is notable that in the panoramic radiography and CT scan performed immediately after the placement of the implants some gaps show up in various portions of the graft material, perhaps due to inadequate compacting (Figure 6). In the panoramic radiograph taken 9 months later these gaps appeared to have closed (Figure 7). The abutment on the implant was installed with a torque setting of 32 Ncm.

CLINICAL CASE 2

A 46-year-old woman came to the office with multiple missing and periodontally involved teeth (Figure 8). The treatment plan included implant placement in the maxillary right first molar position (#16), which would require, as an initial step, the elevation of the floor of the sinus. The CT scan of #16 showed an alveolar height of 8 mm. Following extraction of the periodontally compromised upper right first premolar (#14) and #16 and a waiting period of 8 weeks, the implants were placed. The relevant osteotomes were used, ending with a 3.3-mm final osteotome width in location #16, and a 3.75 by 11.5-mm implant was then placed (Figure 9).



FIGURES 6 and 7. FIGURE 6. Clinical case 1. Immediate postoperative radiographic view of implants in #25 and #26. (A) Computerized tomography scan and (B) panoramic view. Note the gaps in the graft at the apical of #26. FIGURE 7. Clinical case 1. Nine-month postoperative panoramic view.

CLINICAL CASE 3

A 70-year-old patient sought care for multiple periodontally involved teeth. The plan was for ex-

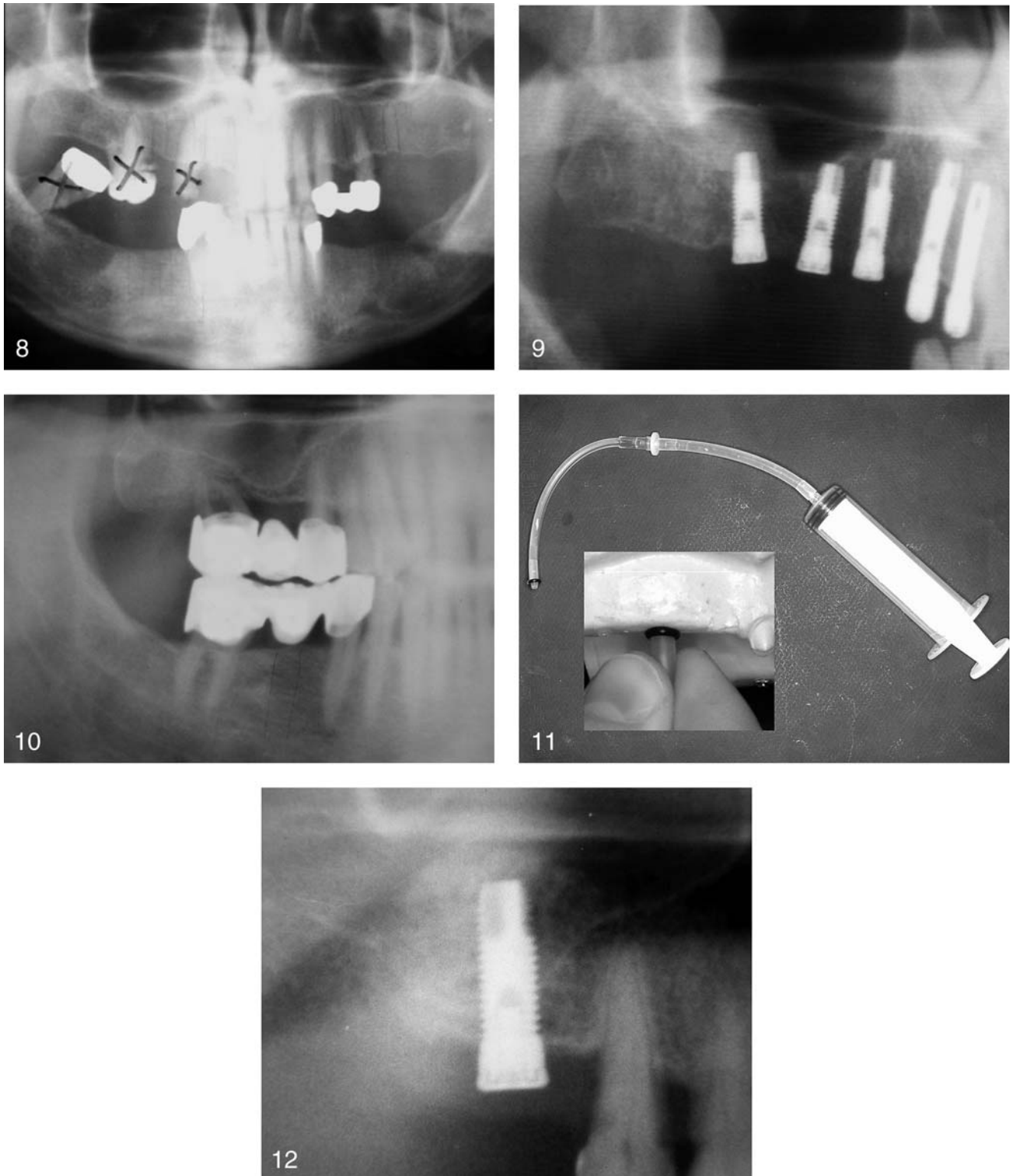
tensive reconstruction, including an implant in the area of the maxillary right first molar (Figure 10). The elevation of the sinus floor was performed simulta-

neously with implant placement, the implant size being 3.75 by 11.5 mm. The elevation of the membrane was achieved with a modified tip of silicon tubing (Figure 11). Autogenous bone collected from the lower right second molar site, after the extraction of the first molar tooth, was mixed with a xenograft bone mineral (BioOss) and grafted onto the sinus floor (Figure 12). Nine months later the implants were loaded and crowns cemented in place.

RESULTS

In 20 detachments and elevations of the schneiderian membrane in 10 human cadaver sinus preparations, the membrane ruptured in 2 instances. In both of these cases the rupture followed excessive irrigation pressure with the normal saline solution. After determining the required hydraulic force for membrane elevation, the clinical cases were begun.

There were 11 clinical cases in all (6 women and 5 men; age range, 24–70 years; average age, 50 years). The average preoperative residual alveolar ridge height was 4 mm, and the average postoperative height elevation into the sinus was 6 mm. Elevation with additional bone grafting occurred in 7 cases, and elevation without additional bone grafting occurred in 4 cases. There were 16 implants placed, with 13 in elevated and grafted sinuses. In 9 cases there was a single implant placed, with 2 cases having 2 implants in the grafted site. Three of the cases have not been loaded as of February 2005. The remaining cases have been loaded from 2 months to as long as 30 months. There has been no implant loss in any of the cases.



FIGURES 8–12. FIGURE 8. Clinical case 2. Preoperative panoramic view. FIGURE 9. Clinical case 2. Postoperative panoramic radiograph showing tented graft and implant in position No. 16. FIGURE 10. Clinical case 3. Preoperative panoramic view. FIGURE 11. Clinical case 3. Modified silicon tubing with syringe. Black grommet (seen in close-up) permits creation of airtight seal in osteotomy site during hydraulic injection. FIGURE 12. Clinical case 3. Postoperative panoramic view of an autogenous and xenograft bone graft mixture and implant at the upper first molar position.

In all cases the integrity of the membrane was confirmed by the following: (1) the absence of fluid exudate through the nasal cavity following the surgical intervention; (2) in the cases where 2 implants were placed and fluid was injected into 1 osteotomy site, it exited from the second osteotomy cavity; and (3) confirmation from periapical and panoramic radiography, as well as CT scan.

CONCLUSIONS

This study details a new method for separating and elevating the schneiderian membrane from the bone of the sinus floor for the purpose of bone grafting and implant placement, without the use of conventional curetting instrumentation. The method possesses the advantage of being a simple and fast surgical technique, avoiding large flap retraction or the creation of a buccal bone window. It has the added advantage of minimal postoperative symptoms for the patient. The procedure is in its early stage of development, having been applied only in cases where 4 to 8 mm of residual alveolar crest is

available, making it possible to do simultaneous membrane lifting and implant placement. The results of the human cadaver preparations, as well as the first series of clinical cases, led to the conclusion that the smaller the amounts of remaining residual alveolar crest, the easier it is for this method to be performed with a successful outcome. Clinical cases using specially designed fluid injectors are now under way, and these results will be elaborated in a coming article.

ACKNOWLEDGMENTS

Thanks to Professor Klaus Benner of the Anatomy Department, Institute of Anatomy at the Maximilians-Ludwig University of Munich, for his invaluable contribution.

REFERENCES

1. Tatum OH Jr. Maxillary and sinus implant reconstruction. *Dent Clin North Am.* 1986;30:207-229.
2. Summers RB. The osteotome technique, part 3: less invasive methods of elevating the sinus floor. *Compend Contin Educ Dent.* 1994;15:698-708.

3. Smiler DG, Johnson PW, Lorada JL, et al. Sinus lift grafts and endosseous implants: treatment of the atrophic posterior maxilla. *Dent Clin North Am.* 1992;36:151-186.

4. Misch CE. Maxillary sinus augmentation for endosteal implant: organized alternative treatment plans. *Int J Oral Implant.* 1987;4:49-58.

5. Tatum OH Jr. Maxillary implants. *Florida Dent J.* 1989;60:23-27.

6. Tatum OH Jr. Endosteal Implants. *CDA J.* 1988;16:71-76.

7. Misch CE. Maxillary sinus lift and elevation with subantral augmentation. In: *Contemporary Implant Dentistry.* St Louis, Mo: CV Mosby Co; 1993: 545-574.

8. Summers RB. A new concept in maxillary implant surgery: the osteotome technique. *Compend Contin Educ Dent.* 1994;15:152-162.

9. Summers RB. The osteotome technique, part 3: less invasive methods of elevating the sinus floor. *Compend Contin Educ Dent.* 1994;15:698-706.

10. Summers RB. The osteotome technique, part 4: future site development. *Compend Contin Educ Dent.* 1995; 16:1090-1099.

11. Glauser R, Naef R, Schärer P. The osteotomy technique: a different method of preparation of the bone site, in the posterior areas of the maxilla. *Greek J Implantol.* 1999;4:275-291.

12. Reiser MG. Evaluation of maxillary sinus membrane response following elevation with the crestal osteotome technique in human cadavers. *Int J Oral Maxillofac Implants.* 2001;16:833-840.

13. Garg KA. *Practical Implant Dentistry.* New York: Taylor Publishing; 1999.