

SCREW- VS CEMENT-IMPLANT-RETAINED RESTORATIONS: AN EXPERIMENTAL STUDY IN THE BEAGLE. PART 1. SCREW AND ABUTMENT LOOSENING

Bartolomeo Assenza, MD, DDS
Antonio Scarano, MD, DDS
Giulio Leghissa, MD, DDS
Giorgio Carusi, MD, DDS
Ulf Thams, MD, DDS
Fidel San Roman, MD
Adriano Piattelli, MD, DDS

KEY WORDS

Abutment
Implant failures
Mechanical failures
Screw loosening

Bartolomeo Assenza, MD, DDS, is a visiting professor and Antonio Scarano, DDS, MD, is a researcher in the Dental School, University of Chieti-Pescara, Chieti, Italy.

Giulio Leghissa, MD, DDS, has a private practice in Milano, Italy.

Giorgio Carusi, MD, DDS, is a visiting professor University of Pisa, Pisa, Italy.

Ulf Thams, MD, DDS, has a private practice, in Madrid, Spain.

Fidel San Roman, MD, is director of Veterinary Teaching Hospital, Complutense University, Madrid, Spain.

Adriano Piattelli, MD, DDS, is a professor of Oral Medicine and Pathology, Dental School, University of Chieti-Pescara. Address correspondence to Dr Piattelli at Via F. Sciucchi 63, 66100 Chieti, Italy (e-mail: apiattelli@unich.it).

The causes of implant failures can be biological or mechanical. The mechanical causes include fracture of the implant, fracture of the abutment, and loosening of the abutment. Numerous studies show that abutment loosening constitutes one of the marked implant postsurgery complications requiring clinical intervention. The aim of the present study was to evaluate the incidence of the screw loosening in screwed or cemented abutments. Six adult male Beagles were used. In each dog, the first molars and 2 premolars were extracted. The sutures were removed after 7 days. After 3 months, 10 implants were placed in each dog, 5 in the right mandible and 5 in the left mandible. The abutments either were screwed in ($n = 30$) by applying a total strength of 30 N/cm or were cemented ($n = 30$). After 12 months, 8 (27%) loosened screws were present in screwed abutments, whereas no abutment loosening was observed in cemented abutments ($P = .0001$). Screwed abutments are often submitted to nonaxial loads that determine screw and abutment loosening.

INTRODUCTION

Numerous studies have reported that the success of dental implants is highly dependent on integration between implant and the surrounding bone,¹⁻³ without considering the biological aspects concerning implant-abutment connections and prosthetic structure.⁴ The focus of implant research has shifted from descriptions of clinical success to the identification of factors associated with failure.⁵

An improved understanding of the factors associated with implant failures may provide useful data for the clinicians.⁵ The success of the implant-retained rehabilitations has been reported to be 95% after 5 years and 90% after 10 years; in the maxilla, the success percentages are lower.^{6,7}

However, technical problems continue to frustrate clinicians, such as the inability to achieve an intimate fit of the prosthetic framework, the inability to correct the misfits, and difficulty in developing an occlusal scheme

without overloading the implant-retained restorations.⁴ Misfits or pre-existing deformations among the different components will produce more screw loosening.⁸ A poor interface fit between implant components will increase the initial displacement and cause a wear of the contact area with an increase of the gap in the screw joint.⁸

Implant failures can be biological or mechanical. The biological causes can determine the loss of osseointegration or peri-implant crestal bone loss. The mechanical causes include fracture of the implant, fracture of the abutment, and loosening of the abutment.^{9,10} Numerous studies have shown that screw loosening constitutes one of the complications that require a reintervention from the clinicians.^{8,11-13} According to Duncan et al,¹⁴ the most common complication reported in the literature is loosening of abutment and occlusal screws. From a theoretical point of view, the screw is the smallest part and the weakest link between the implant components; it may loosen or fracture before failure of other components.⁸ Besides the preloading and the torque, another factor that influences the stability of the implant abutment connection is the adaptation between the abutment and the internal part of implant.¹⁵

Tightening ill-fitting superstructures produces high preload stress in the prosthetic superstructure, the implant abutment, and the supporting structures.¹⁶ Increased preload stresses can be attributed to a lack of accurate fit between implant superstructure and abutments.¹⁶ Behr et al¹⁷ analyzed the prosthetic complications such as fracture or loosening of the abutment in 2 different implant systems, ITI and IMZ. In a 3½-year period, they observed

percentages of prosthetic complication of 28.8% with the ITI system and 77.4% with the IMZ system. Ekfeldt et al¹⁸ noted that the most common complication was the abutment loosening.

This loosening can jeopardize the success of the prosthetic rehabilitation.¹⁹⁻²⁴ Zarb and Schmitt²⁵ reported a 21% incidence of fracture of the occlusal screw thread. Bianco et al²⁶ reported that abutment screw loosening amounted to 35% of all complications, whereas Simon²⁷ reported a 7.4% incidence of abutment screw loosening. Despite some reports that the incidence of screw loosening is low, it is time consuming for clinicians to manage this problem.⁸ When functional loading exceeds preload stresses, it can contribute to the loosening or fracturing of the implant and prosthetic components.^{10,16} Moreover, if the occlusal forces exceed the capability of the interface to absorb the stresses that are generated, the implant will fail.²⁸

The aim of the present study was to clinically evaluate the incidence of screw loosening in implants with screwed or cemented implant-abutment connections.

MATERIALS AND METHODS

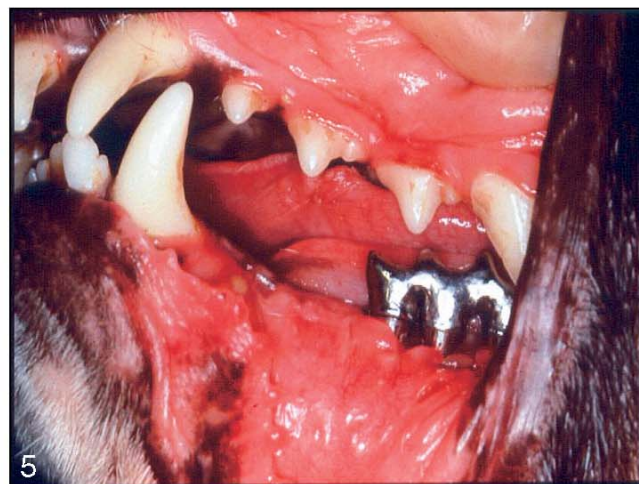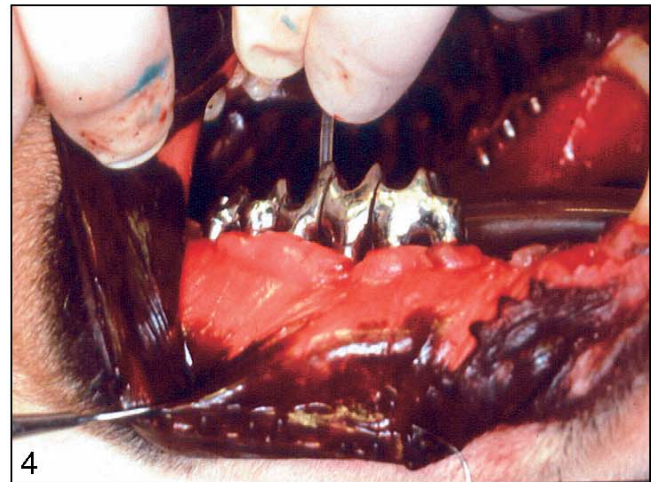
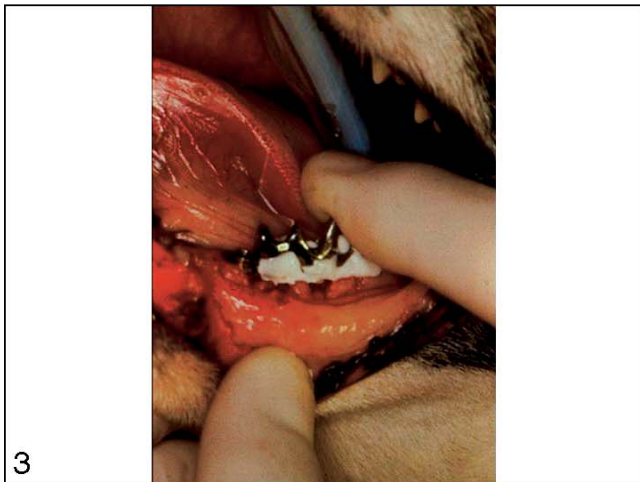
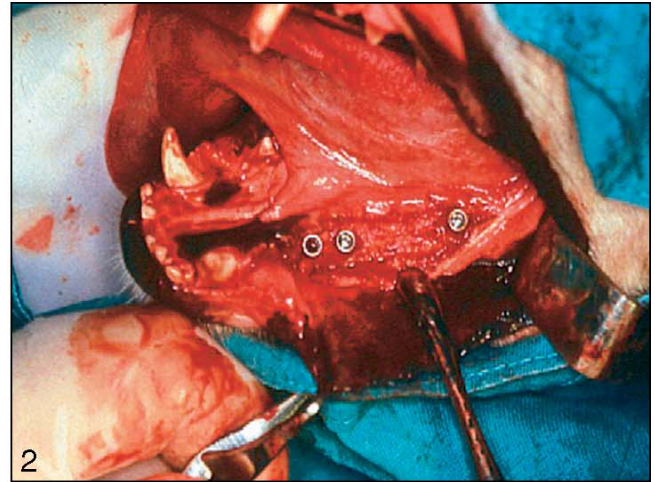
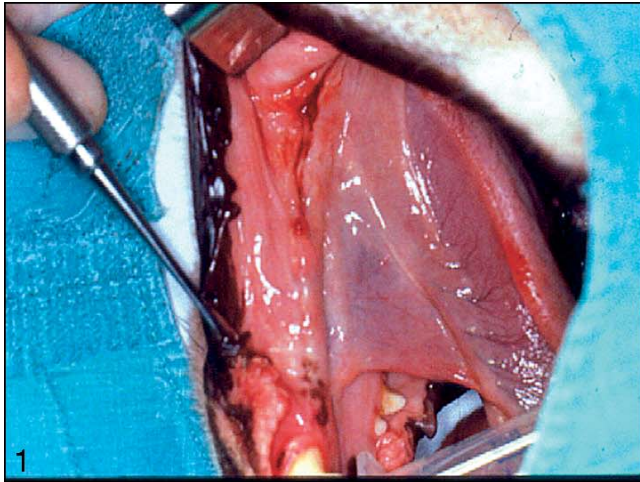
Sandblasted and acid-etched implants (Bone System, Milano, Italy) were placed in the mandible of 6 male Beagles of at least 2 years of age. The Ethics Committee of the University of Madrid, Spain, approved the protocol. The 2 premolars and the first molars had been extracted 3 months previously (Figure 1). Each dog received 10 implants in the mandible, 5 on the right side and 5 on the left side. All surgical procedures were performed with the dogs under general anesthesia (premedication with

acepromazine 0.5 mg/kg subcutaneously; nembutal 15 mg/kg intravenously) and antibiotic prophylaxis (Figure 2). The implant sites were prepared with drills under generously chilled saline irrigation.

The implants were then inserted with a tapping instrument. All implants were placed by a submerged approach, and the top of the implant (microgap) was located clinically at the alveolar crest. The mucosal tissues were sutured with 3-0 silk sutures. In the first 2 postsurgical weeks, the oral cavities were rinsed daily with chlorhexidine-digluconate 0.12% (Peridex, Procter & Gamble, Cincinnati, Ohio). In addition, the dogs were fed a soft diet.

The sutures were removed after 1 week. Three months after implantation, second-stage surgery was performed for abutment connection (Figures 3 and 4). After a midcrestal incision, the peri-implant soft tissues were evaluated with exposure of the peri-implant bone crest, and abutments were inserted in all implants. A total of 60 implants were inserted, 30 with cemented abutments and 30 with screwed abutments. The abutments either were screwed in by applying a total strength of 30 N/cm or were cemented with Panavia 21 (J. Morita USA Inc, Tustin, Calif). The cement was mixed according to the manufacturer's recommendations and was applied on the axial surface of the internal portion of the implants to minimize hydrostatic pressure during seating. Abutments were cemented on the implant with a load of 5 kg maintained for 10 minutes. Excess cement was removed with a scaler. One investigator (B.A.) carried out mixing and cementing procedures at room temperature.

After cementation of the implant-abutment connection, a



FIGURES 1–5. FIGURE 1. The edentulous area after extraction of the 2 premolars. FIGURE 2. Implant insertion under general anesthesia. FIGURE 3. Second-stage surgery was performed for abutment connection. FIGURE 4. Second-stage screwed abutments connection. FIGURE 5. A loosened screwed abutment after 12 months.

bridge made of 6 artificial teeth was cemented with a load of 5 kg maintained for 10 minutes. After cementation of the bridge, the excess cement was removed with a scaler.

After 12 months, all the bridges were removed and all screwed and cemented abutments were checked clinically for mobility by alternately pressing the facial and lingual surfaces of the abutments with the nonworking ends of 2 instrument handles. No postoperative complications or deaths occurred.

RESULTS

After 12 months, 8 (27%) loosened screws were present in screwed abutments (Figure 5), whereas no loosening was observed in cemented abutments. A statistically significant difference was present between the incidence of the loosening in the screwed and cemented abutments ($P = .0001$).

DISCUSSION

Masticatory forces and parafunctions generate functional stresses in implant-supported restorations.¹⁶ It has been widely documented that it is possible to observe a loosening or fracturing of the abutment screw in prosthetic restorations with screwed abutments, especially in the first year of loading of single implants.²⁹ Instability of the prosthetic superstructure is expressed by difficulty in chewing and functioning, as well as peri-implant soft tissue inflammation and swelling.^{24,30}

The act of tightening a screw joint serves to achieve stability with the use of an optimum preload stress to improve the fatigue life and to counter the possibility of loosening.¹⁶ Screw tightening

has been reported to be necessary, especially in the first year of functional loading.³¹⁻³⁴ The connection of the abutment to the implant with a screw produces gaps at the interface, from which can originate biological complications (permeability to fluids and bacteria with a possible involvement of the peri-implant soft tissues)³⁵⁻³⁷ and mechanical complications (fracture or loss of the screw).^{9,10,38-41}

The gap between the implant abutment and the prosthesis has been demonstrated to undergo significant changes under loading.⁴ Once a screw is loosened it should be replaced, because if it is used again there is a risk of fracture if the same preload stress is applied.¹⁰ Preload stresses are produced with the screw joints that clamp the restorative unit together before function.¹⁶ Preload stresses in the mating screw-joint components and the superstructure are generated by closing torque and influenced by component and superstructure misfit.¹⁶ The screw-joint preload is influenced by the geometry of the screw, the contact between the components, friction, and the properties of the different materials.¹⁶ The loosening of the abutment produces wider spaces between implant and abutment, with an increase of the mobility of the whole prosthetic restoration and of the presence of bacterial colonization inside the implant, causing a possible increase in the resorption of the crestal bone.⁴²

It is clear that it is necessary to check and to prevent the loosening of the abutment to avoid devoting too much time to the maintenance of prosthetic restorations. Alternative systems, including cementation of the restoration, have been developed.⁴³ In a previous study, we found that the cement forms

a solid and very resistant film between implant and abutment, preventing any relative movement of the abutment inside the implant. The cement used for fixing the abutment completely filled the interstices within the abutment-implant interface, preventing the relative movements and the colonization by fluids and bacteria.^{35,36}

ACKNOWLEDGMENTS

This work was partially supported by the National Research Council (CNR), Rome, Italy; by the Ministry of Education, University, Research (MIUR), Rome, Italy; and by Research Association for Dentistry and Dermatology (AROD), Chieti, Italy.

REFERENCES

1. Adell R, Eriksson B, Lekholm U, Brånemark P, Jemt T. A long-term follow-up study of osseointegrated implants in the treatment of totally edentulous jaws. *Int J Oral Maxillofac Implants.* 1990;5:347-359.
2. Albrektsson T, Bergman B, Folmer T. A multicenter study of osseointegrated oral implants. *J Prosthet Dent.* 1988;60:75-84.
3. Buser D, Mericske-Stern R, Bernard JP, et al. Long-term evaluation of non-submerged ITI A implants. Part 1: 8-year life table analysis of a prospective multi-center study with 2359 implants. *Clin Oral Implant Res.* 1997;8:161-172.
4. Hecker DM, Eckert SE. Cyclic loading of implant-supported prostheses: changes in component fit over time. *J Prosthet Dent.* 2003;89:346-351.
5. Chuang SK, Wei LJ, Douglass CW, Dodson TB. Risk factors for dental implant failure: a strategy for the analysis of clustered failure-time observations. *J Dent Res.* 2002;81:572-577.
6. Albrektsson T, Zarb G, Worthington P, Eriksson AR. The long-term efficacy of currently used dental implants: a review and proposed criteria of success. *Int J Oral Maxillofac Implants.* 1986;1:11-25.
7. Jemt T. Consecutively inserted fixed prostheses supported by Brånemark implants in edentulous jaws: a

study of treatment from the time of prosthesis placement to the first annual check-up. *Int J Oral Maxillofac Implants.* 1991;6:270-276.

8. Lee J, Kim YS, Kim LW, Han JS. Wave analysis of implant screw loosening using an air cylindrical cyclic loading device. *J Prosthet Dent.* 2002;88:402-408.

9. Goodacre CJ, Bernar G, Rungcharassaeng K, Kan JYK. Clinical complications with implants and implant prostheses. *J Prosthet Dent.* 2003;90:121-132.

10. Schwarz MS. Mechanical complications of dental implants. *Clin Oral Implant Res.* 2000;11 (suppl):156-158.

11. Jemt T, Linden B, Lekholm U. Failures and complications in 127 consecutively placed fixed partial prostheses supported by Brånemark implants: from prosthetic treatment to first annual check-up. *Int J Oral Maxillofac Implants.* 1992;7:40-44.

12. Quirynen M, Naert I, van Steenberghe D, et al. The cumulative failure rate of the Brånemark A system in the overdenture, the fixed partial, and the fixed full prostheses design: a prospective study on 1273 fixtures. *J Head Neck Pathol.* 1991;10:43-53.

13. Zarb GA, Schmitt A. The longitudinal clinical effectiveness of osseointegrated dental implants: the Toronto study. Part III: problems and complications encountered. *J Prosthet Dent.* 1990;64:185-194.

14. Duncan JP, Nazarova E, Vogiatzi T, Taylor TD. Prosthodontic complications in a prospective clinical trial of single-stage implants at 36 months. *Int J Oral Maxillofac Implants.* 2003;18:561-565.

15. Binon P. The role of screws in implant systems. *Int J Oral Maxillofac Implants.* 1994;9:48-51.

16. Nissan J, Gross M, Shifman A, Assif D. Stress levels for well-fitting implant superstructures as a function of tightening force levels, tightening sequence, and different operators. *J Prosthet Dent.* 2001;86:20-23.

17. Behr M, Lang R, Leibrock A, Rosentritt M, Handel G. Complication rate with prosthodontic reconstructions on ITI and IMZ dental implants. Internationales Team für Implantologie. *Clin Oral Implant Res.* 1998;9:51-58.

18. Ekfeldt A, Carlsson GE, Borjesson G. Clinical evaluation of single-tooth restorations supported by osseointegrated implants: a retrospective study.

Int J Oral Maxillofac Implants. 1994;9:179-183.

19. Jemt T, Pettersson P. A 3-year follow-up study on single implant treatment. *J Dent.* 1993;21:203-208.

20. Haas R, Mensdorff-Puilly N, Mailath G, Watzek G. Brånemark single tooth implants: a preliminary report of 76 implants. *J Prosthet Dent.* 1995;73:274-279.

21. Worthington P, Bolender CL, Taylor TD. The Swedish system of osseointegrated implants: problems and complications encountered during a 4-year trial period. *Int J Oral Maxillofac Implants.* 1987;2:77-84.

22. Carlson B, Jonsson G, Sandahl L, et al. A 1-year clinical report of a one-piece implant abutment. *Int J Prosthodont.* 2001;14:159-163.

23. Boggan RS, Strong JT, Misch CE, Bidez MW. Influence of hex geometry and prosthetic table width on static and fatigue strength of dental implants. *J Prosthet Dent.* 1999;82:436-440.

24. Tripodakis AP, Strub JR, Kaffert HF, Witkowski S. Strength and mode of failure of single implant all ceramic abutment restorations under static load. *Int J Prosthodont.* 1995;8:265-272.

25. Zarb GA, Schmitt A. The longitudinal clinical effectiveness of osseointegrated dental implants: problems and complications encountered. *J Prosthet Dent.* 1990;64:185-194.

26. Bianco G, Di Raimondo R, Luongo G, et al. Osseointegrated implant for single-tooth replacement: a retrospective multicenter study on routine use in private practice. *Clin Implant Dent Relat Res.* 2000;2:152-158.

27. Simon RL. Single implant-supported molar and premolar crowns: a ten year retrospective clinical report. *J Prosthet Dent.* 2003;90:517-521.

28. Eskitascioglu G, Usumez A, Sevimay M, Soykan E, Unsal E. The influence of occlusal loading location on stresses transferred to implant-supported prostheses and supporting bone: a three-dimensional finite element study. *J Prosthet Dent.* 2004;91:144-150.

29. Kallus T, Bessing C. Loose gold screws frequently occur in full-arch fixed prostheses supported by osseointegrated implants after 5 years. *Int J Oral Maxillofac Implants.* 1994;9:169-178.

30. Artzi Z, Dreifangel A. A screw lock for single-tooth implant superstructures. *J Am Dent Assoc.* 1999;130:677-682.

31. Jemt T, Pettersson P. A 3-year follow-up study on single implant treatment. *J Dent.* 1993;21:203-208.

32. Enquist B, Nilson H, Åstrand P. Single-tooth replacement by osseointegrated Brånemark implants. A retrospective study of 82 implants. *Clin Oral Implant Res.* 1995;6:238-245.

33. Henry PJ, Laney WR, Jemt T, et al. Osseointegrated implants for single-tooth replacement: a prospective 5-year multicenter study. *Int J Oral Maxillofac Implants.* 1996;11:450-455.

34. Tzenakis GK, Nagy WW, Fournelle RA, Dhuru VB. The effect of repeated torque and salivary contamination on the preload of slotted gold implant prosthetic screws. *J Prosthet Dent.* 2002;88:183-191.

35. Piattelli A, Scarano A, Paolantonio M, et al. Fluids and microbial penetration in the internal part of cement-retained versus screw-retained implant-abutment connections. *J Periodontol.* 2001;72:1146-1150.

36. Orsini G, Fanali S, Scarano A, Petrone G, Di Silvestro S, Piattelli A. Tissue reactions, fluids, and bacterial infiltration in implants retrieved at autopsy: a case report. *Int J Oral Maxillofac Implants.* 2000;15:283-286.

37. Sutter F. The role of screws in implant systems. *Int J Oral Maxillofac Implants.* 1994;9:51-52.

38. Binon PP. Evaluation of three slip fit hexagonal implants. *Implant Dent.* 1996;5:235-248.

39. Binon PP. The effect of implant/abutment hexagonal misfit on screw joint stability. *Int J Prosthodont.* 1996;9:149-160.

40. Binon PP. The Spline Implant: design, engineering and evaluation. *Int J Prosthodont.* 1996;9:419-433.

41. Yokoyama K, Ichikawa T, Murakami H, Miyamoto Y, Asaoka K. Fracture mechanisms of retrieved titanium screw thread in dental implant. *Biomaterials.* 2002;23:2459-2465.

42. Piattelli A, Vrespa G, Petrone G, Iezzi G, Annibaldi S, Scarano A. Role of the microgap between implant and abutment: a retrospective histologic evaluation in monkeys. *J Periodontol.* 2003;74:346-352.

43. Hebel KS, Gajjar RC. Cement-retained versus screw-retained implant restorations: achieving optimal occlusion and esthetics in implant dentistry. *J Prosthet Dent.* 1997;77:28-35.