

THE USE OF PREFABRICATED TITANIUM TISSUE ABUTMENTS FOR THE CONSTRUCTION OF A MAXILLARY SUBPERIOSTEAL IMPLANT

Engin Aras, DDS, PhD
 Mehmet Sönmez, DDS, PhD
 Muammer Zora, DDS, PhD
 Meral Basarir, DDS, PhD
 Hüseyin Kurtulmus, DDS, PhD

KEY WORDS

Subperiosteal
 Prefabricated
 Abutments
 Titanium

Engin Aras, DDS, PhD, is a professor with the Department of Prosthodontics and Maxillofacial Prosthetics, Faculty of Dental Medicine, Ege University, 35100 Bornova, Izmir, Turkey. Address correspondence to Dr Aras (e-mail: aras@dent.ege.edu.tr).

Mehmet Sönmez, DDS, PhD, and Muammer Zora, DDS, PhD, are with the Department of Prosthodontics and Oral Implantology, State Dental Hospital, Izmir, Turkey.

Meral Basarir, DDS, PhD, is a maxillofacial prosthetics and oral implantologist with the Dental Department, Izmir Free Zone (ISB) Health Service Dental–Oral Health Department, Prosthodontics, Izmir, Turkey.

Hüseyin Kurtulmus, DDS, PhD, is a research assistant with the Department of Prosthodontics and Maxillofacial Prosthetics, Faculty of Dental Medicine, Ege University, Bornova, Izmir, Turkey.

This article presents a bimodal procedure for a patient with an implant-supported fixed partial denture (FP2 class of Misch) where endosteal implants (EOIs) and a subperiosteal implant (SPI) were indicated in different sections of the same arch. In edentulous patients, heterogeneous bone volume and density may be encountered in different regions of the same arch. When the available bone is favorable, the use of EOIs is simpler and less time consuming. An SPI is indicated when the available bone is severely resorbed, as in the type I division C, type II divisions C and D, and type III divisions C and D. The main advantage of the described combined technique is that it offers an alternative to invasive surgeries such as iliac crest bone grafts or various surgical augmentation procedures. The second advantage is the very brief healing period after insertion of the SPI before prosthetic loading. Planning, design, laboratory construction, surgical application, and prosthetic rehabilitation for bimodal implant treatment are described. Prefabricated titanium tissue abutments are used in the fabrication of the posts of the anterior titanium SPI. Titanium tissue abutments are placed in the waxup stage of the SPI before the casting of the titanium SPI. Posterior fixtures are EOIs. An anterior SPI with 4 posts and 4 posterior EOIs provides a combination of support for the screw-retained fixed maxillary denture of Misch's FP2.

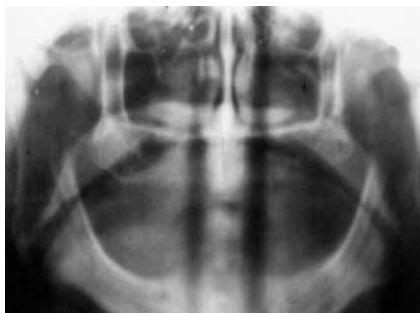

FIGURE 1. Fully edentulous upper and lower arches.

INTRODUCTION

In cases where bone is deficient in some areas of the arch and severe bone atrophy, narrow bone width, or inadequate bone height is encountered over the mandibular canal or below the maxillary sinus, the clinician may have to consider alternative plans.¹⁻¹¹ Surgical solutions^{6,12,13} or combined implant modalities¹³⁻¹⁹ should be considered. In cases where surgical compensatory procedures such as onlay or sandwich bone grafts, sinus-lifting procedures, or bone-spreading augmentations are used, the loading period is lengthened as much as twice the regular osteointegration period. The technique described in this article decreases the healing period before prosthetic loading.

CLINICAL REPORT

A 60-year-old fully edentulous man presented to our prosthodontics clinic for implant-supported prosthodontic rehabilitation (Figure 1). He was 174 cm tall and weighed 75 kg. His chief complaint was that he was unable to wear and use his

complete dentures. His ortopantomography showed no evidence of bone pathology or impacted teeth, and his vital signs and medical history did not contraindicate implant therapy. He lost his teeth 10 years earlier because of rapidly progressive periodontal infection and bone loss. Multiple attempts at complete dentures were unsuccessful, and he now desired implant-supported dentures.

Treatments

In the first attempt at treatment, 2 implants were positioned immediately anterior to the mental foramen on each side of the mandible, and 2 implants were positioned bilaterally at the level of the maxillary tuberosities. It was not possible to position any endosteal implants (EOIs) on the anterior maxilla because of the knife-edge shape of the alveolar process. A bar-and-clips-retained complete denture was fabricated for the lower jaw. Posterior O-rings retained a complete denture for the edentulous maxilla. The patient used the prostheses for 2 years but was not satisfied with the maxillary denture, for the anterior part was not stable and dropped during function. At the end of the second year, the implant at the level of mandibular left second premolar failed and was removed. An anterior partial-arch subperiosteal implant (SPI) was planned for the anterior maxilla with 4 posterior EOIs to support full-arch crown and bridge restorations.

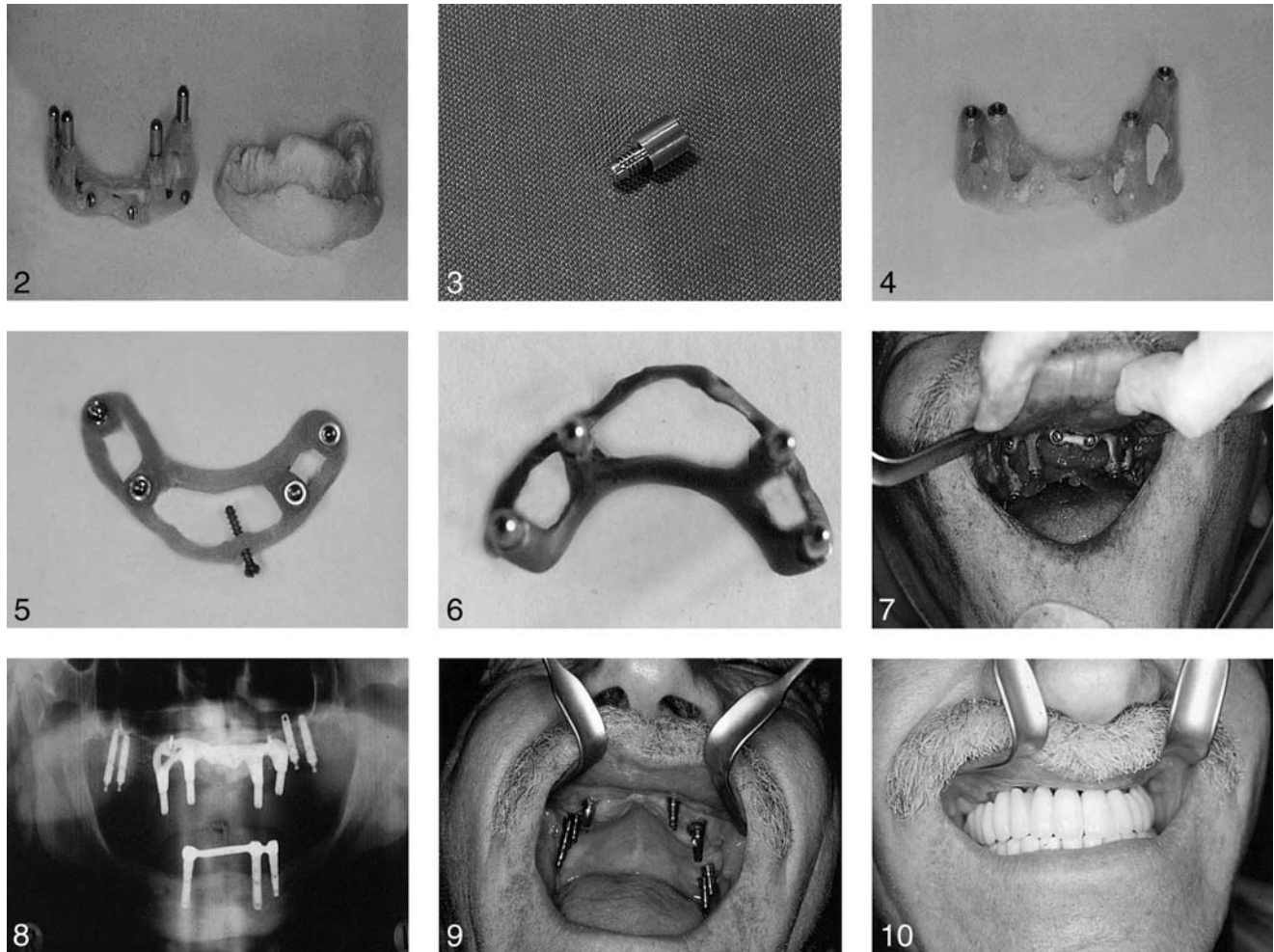
After a midcrestal incision, the maxillary arch was fully exposed from the deepest portion of the vestibular sulcus to 2

cm palatally. Heavy bodied silicone material, sterilized with ethylene oxide, was used to obtain an exact bone impression. The surface of the silicone impression was painted lightly with Vaseline. A model of polysiloxane condensation silicone (Speedex putty, Coltène, Switzerland) was obtained by forcing the material into the impression (Figure 2).

An SPI was designed with self-curing resin on the silicone model. The vestibular major connector, palatal major connector, and fixation sections for the miniscrews were fabricated with the self-curing resin. Tissue abutments (Figure 3) were used as anterior posts.

The internally threaded end was positioned toward the oral cavity. Next, the titanium tissue abutments were positioned in the self-curing resin at the desired levels for the posts. Labial and palatal major connectors, minor connectors supporting the posts, and fixation rings on the buccal major connector were all sculpted in self-curing acrylic (Figures 4 and 5). The resin pattern was cast in titanium and then sandblasted (Figure 6). Only the tissue abutments were finely polished. After sterilization, the SPI was fixed in the mouth with 2-mm diameter miniscrews (Figures 7 and 8).

Two weeks later, the impression pins were positioned (Figure 9) and the impression was taken with silicon material. After the metal try-in, the ceramic try-in, and the necessary occlusal adjustments, the full-arch fixed bridge was glazed and screwed in situ over the maxillary implants (Figure 10). A bar-supported mandibular removable partial denture was constructed over the mandibular implants.



FIGURES 2–9. FIGURE 2. Silicone model and the subperiosteal implant designed in self-curing acrylic resin with healing abutments. FIGURE 3. Four-millimeter tissue abutment (SteriOss, Anaheim, Calif, Cat. No. 2061). FIGURES 4 and 5. Subperiosteal implant in self-curing acrylic resin. FIGURE 6. Subperiosteal implant cast in titanium and sandblasted. FIGURE 7. Subperiosteal implant fixed on the anterior maxilla with titanium miniscrews. FIGURE 8. Orthopantomography of the subperiosteal implant and endosteal implant. FIGURE 9. Patient with the impression pins. FIGURE 10. Glazed full-arch Misch's FP2 in mouth.

CONCLUSION

It is apparent that the indications for an SPI begin where the indications for an EOI end. In this case it was possible to rehabilitate the patient with implant-supported crown-and-bridge restorations over his partial-arch SPI with internally threaded tissue abutments. Laser welding the tissue abutments to the titanium casting to eliminate further abutment detachments from the casting

should be considered as a precautionary measure.

REFERENCES

1. Aras E et al. Diagnosis and treatment planning in EO and SPI. *Turk J Oral Rehabil.* 1992;94:5–10.
2. Amet ME. Computerized tomography with CT models for contemporary ramus frame implant planning and construction. *J Oral Implantol.* 1998;24:152–158.
3. Cranin AN, Klein M, Ley PJ, Andrews J, DiGregorio R. An in vitro

comparison of the computerized tomography/cad-cam and direct bone impression techniques for subperiosteal implant model generation. *J Oral Implantol.* 1998; 24:74–79.

4. Jemt T. Implant treatment in resorbed edentulous upper jaws. A three year follow up study on 70 patients. *Clin Oral Implant Res.* 1993;4:187–194.

5. Linkow LI, Ghalili R. Critical design errors in maxillary subperiosteal implants. *J Oral Implantol.* 1998;24:198–205

6. Misch CE. *Diagnosis and Treatment Planning. Implant Symposium* [videotape]. Core-Vent: London; 1989.

7. Misch CE. Endosteal implants for posterior single tooth replacement: alter-

natives, indications, contraindications and limitations. *J Oral Implantol.* 1999;25:80–94.

8. Misch CE. Diagnosis and treatment planning. Paper presented at World Congress XIII. International Congress of Oral Implantologists and Turkish Society of Oral Implantology; August 20–22, 1993:20–21; Istanbul, Turkey.

9. Sconzo J. The complete mandibular subperiosteal implant: an overview of its evolution. *J Oral Implantol.* 1998;24:14–15.

10. Shen TC. The use of different implant modalities in the atrophied ridge. *J Oral Implantol.* 1999;25:109–113.

11. Sirbu I. Subperiosteal implant technology: report from Roumania. *J Oral Implantol.* 2003;29:189–194.

12. Campbell AL. Use of bone grafting in the management of a troublesome operative site planned for future implant restoration. *J Oral Implantol.* 1998;24:97–100.

13. Minichetti CJ. Analysis of HA coated subperiosteal implants. *J Oral Implantol.* 2003;29:111–119.

14. Aras E et al. Subperiosteal implants. Clinical and laboratory procedures. A five year retrospective study on thirty six patients. *Turk J Oral Implantol.* 1995;November:75–79.

15. Demirdjan E. The complete maxillary subperiosteal implant: an overview

of its evolution. *J Oral Implantol.* 1998;24:196–197.

16. Josefovici, N. Report from Israel. *J Oral Implantol.* 1998;24:133–135.

17. Linkow LI, Wagner RJ, Chavanaz M. Tripodal mandibular subperiosteal implant: basic sciences, operational procedures, and clinical data. *J Oral Implantol.* 1998;24:16–36.

18. Linkow LI, Ghalili R. Ramus hinges for excessive movements of the condyles: a new dimension in mandibular tripodal subperiosteal implants. *J Oral Implantol.* 1999;25:11–16.

19. Mansueto RF. Replacement of mandibular subperiosteal implant. *J Oral Implantol.* 1999;25:199–202.